

A quantitative approach to shortening the levator palpebrae superioris to correct congenital ptosis in children

Xin-Yu Huang¹, Xing-Xing Wang¹, Hui-Zhen Huang², Yuan-Yuan Du²

¹Department of Ophthalmology, Second Hospital of Jilin University, 4026 Yatai street, Nangan District, Changchun 130000, Jilin Province, China.

²Mylike Medical Cosmetic Hospital, Mylike Tower, 789 West Yan'an Road, Changning District, Shanghai 200050, China.

Correspondence to: Yuan - Yuan Du. Mylike Medical Cosmetic Hospital, Shanghai 200050, China. 18686623812@163.com

Received: 2018-01-29 Accepted: 2018-07-27

全身麻醉下行儿童先天性上睑下垂提上睑肌缩短术的量化研究

黄鑫宇¹, 王星星¹, 黄惠真², 杜园园²

(作者单位:¹130000 中国吉林省长春市, 吉林大学第二医院眼科中心;²200050 中国上海市, 美莱医疗美容医院)

作者简介:黄鑫宇, 毕业于吉林大学, 硕士。研究方向:眼表疾病与眼整形美容。

通讯作者:杜园园, 博士, 副主任医师, 硕士研究生导师。研究方向:眼整形美容。18686623812@163.com

摘要

目的:探寻一种全身麻醉下行提上睑肌缩短术时术前量化的方法。

方法:收集 64 例 102 眼儿童上睑下垂患者, 根据上睑下垂的程度将其分为三组:轻度(<2 mm), 中度(3~4 mm)及重度(>4 mm)。所有病例均采用提上睑肌缩短术, 术前采集标准照片, 并通过 Image J 软件测量患眼上睑缘至角膜下缘的高度, 利用公式计算出术中上睑缘需达到的高度, 并根据计算结果实施手术。术后评价标准包括上睑缘高度, 巩膜暴露度以及暴露性角膜炎的发生情况。所有患者均于术后 1wk, 1mo, 6mo 时进行随访。

结果:在术后早期阶段, 轻、中度组各 1 眼出现过矫情况, 轻度组和中度组所有患者的上睑缘位置均位于正常高度。术后 6mo 时, 中度组的过矫眼有所提高, 轻度组的过矫眼仍处于过矫状态, 重度组中有 7 例出现了不同程度的欠矫。术后眼睑闭合良好, 未出现暴露性角膜炎。

结论:这种术前通过公式计算全身麻醉下上睑下垂患者术中需要达到的上睑缘高度的方法, 不仅为全身麻醉下行提上睑肌缩短术提供更为准确的依据, 同时也提高了全身麻醉下行提上睑肌缩短术的成功率。

关键词:先天性上睑下垂; 提上睑肌; 上睑缘高度; 软件应用

引用:黄鑫宇, 王星星, 黄惠真, 杜园园. 全身麻醉下行儿童先天性上睑下垂提上睑肌缩短术的量化研究. 国际眼科杂志 2018; 18(10):1767-1773

Abstract

• **AIM:** To develop a feasible method to correct congenital ptosis in children.

• **METHODS:** Sixty - four patients (102 eyelids) were divided into three groups based on the degree of ptosis: mild (<2 mm); moderate (3-4 mm) and severe (>4 mm). All patients underwent the same levator resection surgery in which the suspensory system of the LPS is retained. After capturing a standard photograph of primary position, the height of the superior palpebral margin was measured preoperatively by using Image J software to calculate its ideal height required during surgery. Postoperative outcome measures included upper eyelid margin height, degree of scleral exposure and exposure keratitis. The patients were followed-up at 1wk, 1mo and 6mo postoperatively.

• **RESULTS:** In the early postoperative period, except two cases with overcorrection, the positions of the eyelid upper margins were normal in all cases in the mild and moderate groups. Six months postoperatively, the eye with overcorrection in the moderate group showed improvement, while the eye in the mild group did not. Seven eyes in the severe group exhibited residual ptosis to varying degrees. The eyelids exhibited appropriate closing functionality; exposure keratitis was absent.

• **CONCLUSION:** Using this preoperative quantification technique to guide surgery not only provided a gauge for LPS shortening under general anesthesia, but also increased the success rate of surgery.

• **KEYWORDS:** congenital ptosis; palpebralis; palpebral fissure height; software application

DOI:10.3980/j.issn.1672-5123.2018.10.03

Citation: Huang XY, Wang XX, Huang HZ, Du YY. A quantitative approach to shortening the levator palpebrae superioris to correct congenital ptosis in children. *Guoji Yanke Zazhi(Int Eye Sci)* 2018;18(10):1767-1773

INTRODUCTION

Ptosis is a condition involving the covering of the superior corneal limbus by the upper margins of the eyelids (>2 mm), which often leads to a drowsy appearance. In serious

Table 1 Preoperative patient data

n

Degree of ptosis	Sex		Eyelids				Total
	Male	Female	Eye		Age (y)		
			Right	Left	2-12	13-17	
Mild	9	6	10	5	15	0	15
Moderate	40	22	29	33	57	5	62
Severe	22	3	13	12	21	4	25
Total	71	31	52	50	93	9	102

cases, the development of visual function is affected when the pupils are obstructed for an extended period. Thus, the timely and effective treatment of ptosis is necessary to protect the patient's health, both physiologically and psychologically^[1]. There are two primary types of surgical procedures to correct ptosis: levator shortening and frontalis suspension procedures. The levator shortening procedure is the most ideal method for correcting ptosis because it is consistent with original physiological function. In recent years, we have achieved good results by using levator resection surgery, in which the suspensory system of the levator palpebrae superioris (LPS) is retained in various degrees of ptosis^[2]. However, it is difficult to control the amount of levator shortening in procedures for patients who are under general anesthesia because they are unable to open their eyes during the operation. Moreover, many children cannot cooperate during the preoperative examination; therefore, accurately estimating the degree of ptosis preoperatively, and exactly grasping the required amount of LPS shortening during general anesthesia, has become an important topic. Accordingly, we have attempted to resolve these problems by collecting accurate measurements of the primary position of eye in preoperative examination(s), and calculating the height of upper eyelids we expect to achieve in surgery using Image J software (National Institutes of Health, Bethesda, MD, USA). In clinical practice, we have confirmed this method to be accurate and effective for the correction of ptosis through follow-up from one week to six months postoperatively. In this article, we introduce this method, and summarize its advantages and disadvantages through our clinical experience.

SUBJECTS AND METHODS

Between September 2015 and December 2016, 64 patients (102 eyelids; age 2 to 17y) with varying degrees of congenital ptosis were recruited from the Second Hospital of Jilin University. All study participants provided written informed consent and didn't receive any stipends. The study was approved by the Institutional Review Board of the Second Hospital of Jilin University and performed in accordance with the tenets of the Declaration of Helsinki. There are no conflicts of interest to declare. Among them, nine teenagers were operated under general anesthesia due to their fear of local anesthesia. Standard photographs of primary position of the eyelid were captured and loaded into the Image J software. At this point, the height of the upper eyelid could be

accurately measured. The height of a normal upper eyelid is 1 mm to 2.0 mm below the superior limbus in primary gaze. Participants were divided into three groups based on the degree of ptosis: mild (<2 mm); moderate (3-4 mm) and severe (>4 mm). Patients with a history of eyelid surgery, absence of Bell's phenomenon, associated ocular motility disturbance, accompanied ocular deformity, or jaw-winking phenomenon were excluded from this study. Initial eyelid condition and preoperative examination results of the patients are summarized in Table 1.

Pre- and postoperative photographs of each individual were captured, and outcomes were assessed at 1wk, 1mo and 6mo postoperatively. The feasibility of this measurement method was analyzed based on these data. The postoperative detection index included the upper margin height of the eyelid and degree of scleral exposure after closing the eyes.

Software Application Methods

Preoperative preparation Standard photographs capturing primary position without raising the eyebrow were collected previously and were loaded into the Image J software. The position and radian of the inferior limbus that was covered by the lower eyelid was assigned according to normal keratometry. The reference baseline was the transverse diameter of the cornea, which has a mean value of 11 mm. The height between eyelid upper margins and inferior limbus was then measured using this software (Figure 1). According to the formula, the height of eyelid upper margins could be calculated, and was the expected outcome in the operation. The formula was $Z = X - Y$ (in which X represents the longitudinal diameter of cornea that we set. Because the average longitudinal diameter of the cornea is 10.11 mm^[20-21], we set the value of X to 12 mm in consideration of postoperative retroversion; Y represents the longitudinal height between the eyelid upper margins and inferior limbus of the cornea through the pupil center before operation, and the muscle force of levator palpebrae superioris is in effect at this time; and Z represents the projected height in the operation between the eyelid upper margins and inferior limbus of the cornea. Because the patient is under general anesthesia, there is no involvement of the levator palpebrae superioris). Y' represents the longitudinal height between eyelid upper margins and superior limbus at the end of operation, it is also refers to the height upper eyelid can lift by muscle force of levator palpebrae superioris of the patient after operation. It is equal to the height (Y) that can be lifted by the upper eyelid

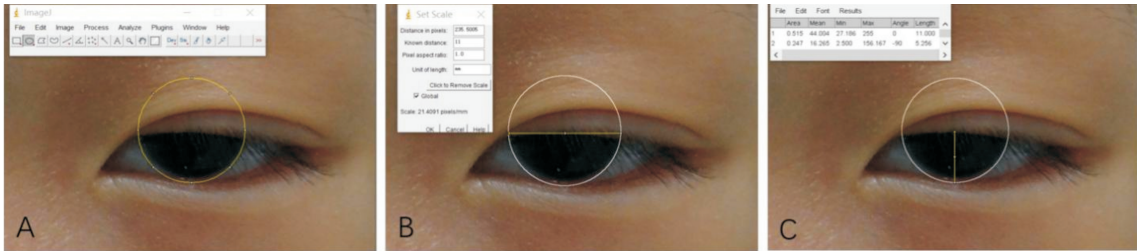

Figure 1 Using the software to measure the height of upper eyelid margin before operation A: Sign the radian of limbus; B: Set the transverse diameter of cornea; C: Measure the height between eyelid upper margins and inferior limbus.

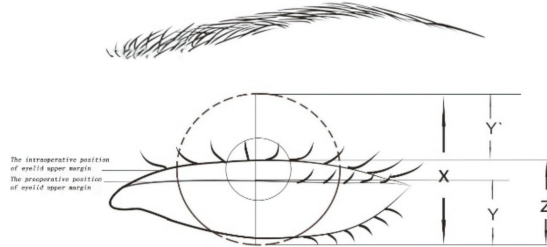


Figure 2 Diagrammatic sketch of the formula.

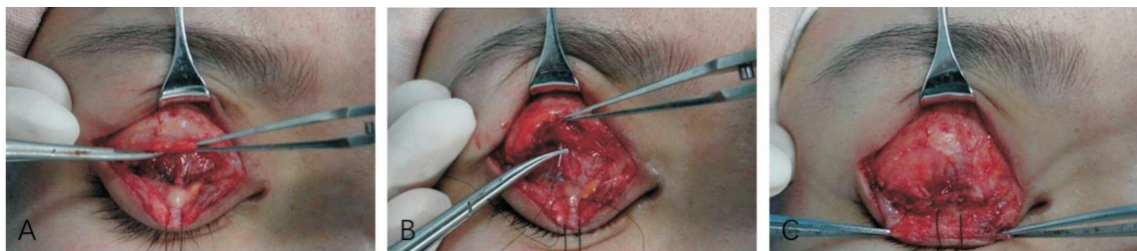

Figure 3 Operating procedure A: The process of dissecting the levator aponeurosis-Mueller's muscle composite flap (LAMCF) from the superior tarsal border; B: The fixation method of the LAMCF; C: Exhibiting the intact septa orbitale, and medial and lateral horns of the levator aponeurosis after the completion of levator aponeuroses repair.

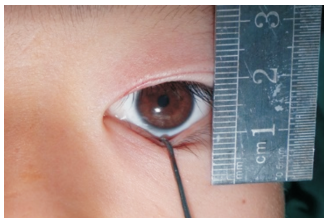


Figure 4 The height between eyelid upper margins and inferior limbus can be measured after three mattress sutures were tied.

before operation. In order to conveniently calculate and express, we use $Y' = Y$ to represent. (Figure 2).

Surgical Technique

The surgery was performed under general anesthesia in all patients. The double eyelid incision line was marked on the upper eyelid 4 mm to 8 mm above the lid margin, depending on the personal preference of the patient. An incision was then made along the double eyelid mark. A small quantity of orbicularis oculi muscle and pretarsal tissue were removed to expose the junction between the upper edge of the tarsus and levator aponeurosis. The levator aponeurosis-Müller's muscle composite flap (LAMCF) was separated from the superior tarsal border and dissociated from conjunctival lamina (Figure 3A). Dissection continued between the space of the

conjunctiva lamina and Müller's muscle to an appropriate position, according to the degree of ptosis and levator function. Based on experience, 2 mm to 3 mm of levator muscle resection should be performed for each millimeter of ptosis. Three 6-0 nylon sutures with needles were passed through the upper third of the tarsus at the center position and then through the detached LAMCF at the appropriate position from the undersurface (Figure 3B). The entire separation process is gentle, without damaging the orbital septum, the lateral and medial horns of the LPS, as well as the both ends of Whitnall's ligament (WL) (Figure 3B). The height between eyelid upper margins and inferior limbus is measured after three mattress sutures are tied (Figure 4). According to the computational formula ($Z = X - Y$), the height (Z) must be in accordance with this computed result. A height adjustment was needed if there was a difference with computed result. At this stage, proper trimming of the distal redundant portion of the advanced composite flap was performed. The double eyelid was created using stitches of 6-0 nylon between the dermomuscular portion of the inferior skin flap margin and the distal edge of the manicured levator aponeurosis. Finally, a frost suture was placed in the lower limbi palpebralis to close the fissure using a 5-0 silk suture during the first week after surgery.

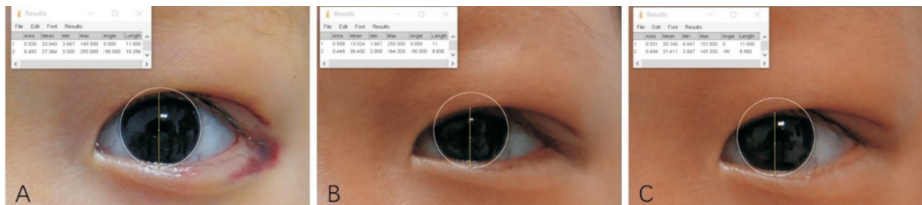


Figure 5 Measurement of the height between eyelid upper margins and inferior limbus through pupil center at every follow-up stage A: One week after surgery; B: One month after surgery; C: Six months after surgery.

It was important to provide postoperative care because these were young (*i. e.* children) patients. Postoperative bandage compression was typically 48h. The medical prescription was changed on postoperative day 3. The frost suture in the lower limbi palpebralis was removed according to an assessment of eye closure. Application of ointment to the operated eye at bedtime was continued to prevent exposure keratitis until the eyelids could close.

Postoperative Data Collection

One week after surgery, standard photographs of primary position and closing eyes were captured and loaded into the Image J software. The position and radian of the inferior limbus that was covered by the lower eyelid was marked. The reference baseline was the transverse diameter, as described. Then, the height between eyelid upper margins and inferior limbus, through the pupil center at every follow-up stage, was measured using the software (Figure 5). Meanwhile, the degree of scleral exposure (*i. e.* the height between the upper and lower margins of the eyelid when closing the eyes) was measured. Because no single cornea could be used as a reference standard, a ruler was used to measure scleral exposure. Assessment standards of the height of the eyelid upper margins were as follows: an upper eyelid margin located 1 mm to 2 mm below the superior corneal limbus, without eyebrow lift, was considered successful; an upper eyelid margin located 2 mm below the corneal margin, but better than preoperative location was regarded as undercorrection; and an upper eyelid margin located in the corneal margin or above was considered an overcorrection. Recurrence of ptosis is defined when the upper eyelid margin is located at the preoperative level.

RESULTS

By one week after surgery, two eyelids in patients in the mild and moderate groups were overcorrected (measured value 11 mm). In addition, the upper margins of the eyelid were 8 mm to 10 mm from the inferior corneal limbus in all other cases among the varying degrees of ptosis except the two. However, the change in the degree of scleral exposure was relatively large due to the variation in degrees of ptosis when the eyes were closed. By one month after surgery, one overcorrected eyelid in the mild group was still in its original state; the others in this group remained at 8 mm to 9 mm from the inferior corneal limbus. The overcorrected eyelid in the moderate group improved to a normal degree; the others in this group remained at 8 mm to 9 mm from the inferior corneal limbus. However, in the severe group, there was a recurrent

tendency in seven eyelids. The height was 7 mm and 8 mm, between the upper margin and inferior limbus, respectively; others were maintained within the normal range. In mild cases, the eyelids could be completely closed. There was 1 mm to 2 mm of scleral exposure when the eyes were closed in moderate cases, and 2 mm to 4 mm of scleral exposure in severe cases.

Six months after surgery, the overcorrected eyelid in the mild group remained in the original state; others remained at 8 mm to 9 mm from the inferior corneal limbus, and the eyelid could still be closed in the mild and moderate groups. This, however, was different in severe cases. Among the 25 eyes with severe ptosis, 18 were still at 8 mm to 9 mm from the inferior corneal limbus, and the remaining seven were 6 mm to 7 mm from the inferior corneal limbus, although the pupils were still exposed. Among the patients with severe ptosis, approximately one-half experienced persistence of scleral exposure (1 mm to 2 mm) postoperatively; however, no exposure keratitis occurred in any case (Figures 6-8; Table 2).

DISCUSSION

Surgical techniques for ptosis have advanced in recent years, and multiform surgical methods have been developed and implemented. In general, however, surgical methods for ptosis can be summarized into two major categories: enhancing the strength of the LPS; and using the frontalis for succedaneous strength^[3-4]. Using the traditional theory, the former method is always used in mild or moderate ptosis (when the degree of ptosis is ≥ 4 mm), while the latter is used in severe ptosis (when the degree of ptosis is < 4 mm). Regarding severe ptosis, a surgical method that strengthens the frontalis is widely used, especially in pediatric patients^[5-12]. Although this particular surgical method could enable the upper eyelids to open, it can impact other eye functions such as the vertical motion of the upper eyelid, changes in local anatomical relationship^[13-14], a shallower orbit of the upper eyelid, and changes in eyelid morphology due to scarring of the frontalis; consequently, the aesthetic effect cannot be achieved^[15]. Therefore, the surgical method most consistent with physiological function enhances the strength of the LPS to correct ptosis (*i. e.* LPS resection). Traditionally, a degree of ptosis ≥ 4 mm is an indication for LPS resection. However, some investigators have advocated that LPS resection should also be used to treat severe ptosis^[13,16-17]. Although controversy remains, we have applied LPS resection in severe cases with satisfactory results^[2].

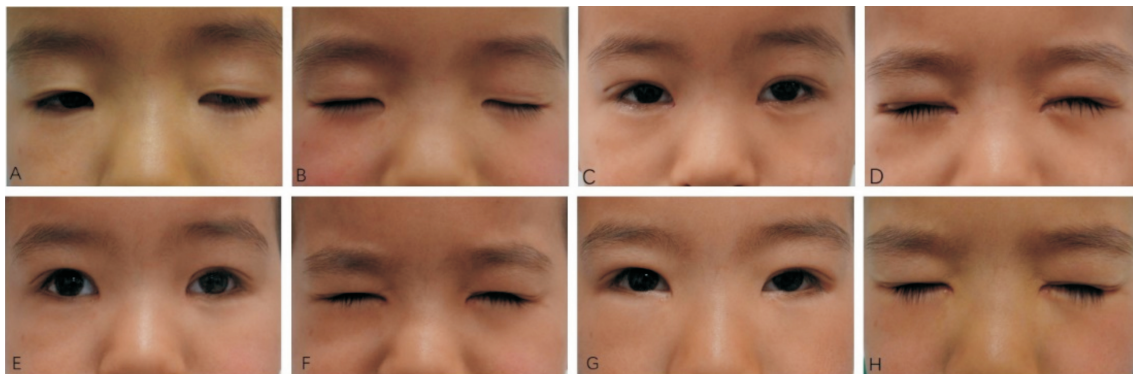


Figure 6 Preoperative and postoperative data at different stages in a 5-year-old male patient with bilateral congenital ptosis
A-B; Preoperative photograph of opened and closed eyes, revealing a degree of ptosis >8 mm and good eyelid function for closing; C-D; Photograph at 1wk postoperatively revealing the position of both upper eyelids 2 mm below the superior corneal limbus and exposure degree of sclera <3 mm when the eyes are closed; E-F; Photograph at 1mo postoperatively revealing the position of both upper eyelids, still 2 mm below the superior corneal limbus and exposure degree of sclera <2 mm when the eyes are closed; G-H; Photograph at 6mo postoperatively revealing that the eyelid contour and plumpness of the operative eye is symmetrical and the eyelid can almost completely close.

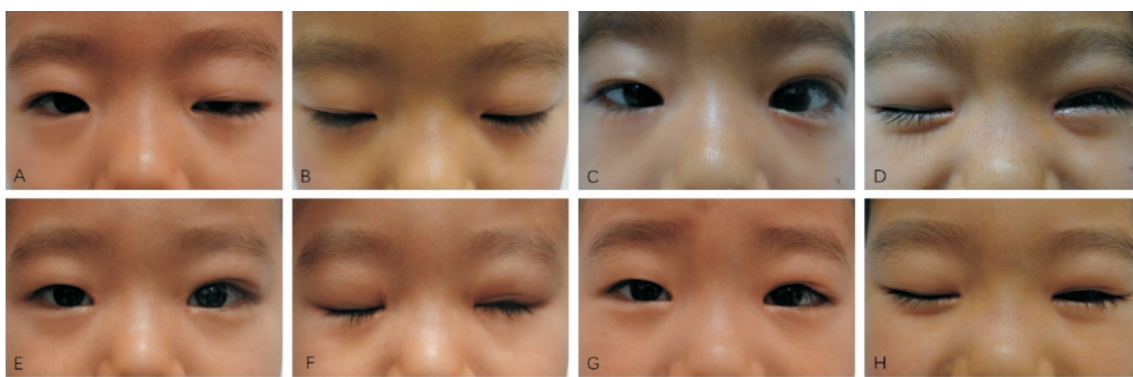


Figure 7 Preoperative and postoperative data at different stages in a 4-year-old male patient with unilateral congenital ptosis
A-B; Preoperative photograph of opened and closed eyes, which reveals a degree of ptosis >7 mm and good eyelid function for closing; C-D; Photograph at 1wk after operation revealing the position of both upper eyelids 2 mm below the superior corneal limbus and exposure degree of sclera <3 mm when the eyes are closed; E-F; Photograph at 1mo postoperatively revealing the position of both upper eyelids, still 2 mm below the superior corneal limbus and exposure degree of sclera <2 mm when the eyes are closed; G-H; Photograph at 6mo postoperatively revealing that the eyelid contour and plumpness of the operative eye is symmetrical and the eyelid can almost completely close.

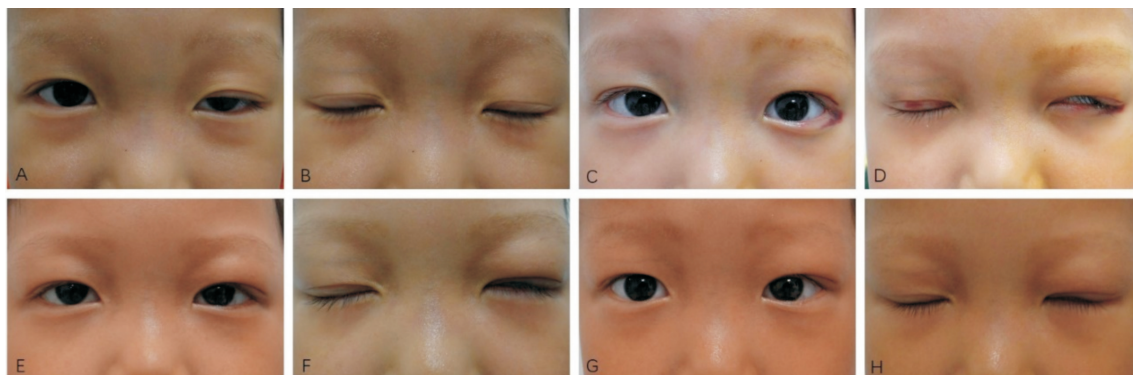


Figure 8 Preoperative and postoperative data at different stages in a 5-year-old female patient with unilateral congenital ptosis
A-B; Preoperative photograph of opened and closed eyes, revealing a degree of ptosis >5 mm and good eyelid function for closing; C-D; Photograph at 1wk postoperatively revealing the position of both upper eyelids 2 mm below the superior corneal limbus and exposure degree of sclera <3 mm when the eyes are closed; E-F; Photograph at 1mo postoperatively revealing the position of both upper eyelids, still 2 mm below the superior corneal limbus and exposure degree of sclera <1 mm when the eyes are closed; G-H; Photograph at 6mo postoperatively revealing that the eyelid contour and plumpness of the operative eye is symmetrical and the eyelid can almost completely close.

There are some disadvantages to traditional methods in deciding on the amount of LPS shortening according to muscle force of the LPS alone. Poorly compliant patients, especially children who are unable to cooperate during examination, can introduce large errors in the measurement of LPS muscle force

before surgery. This will add difficulty to preoperatively estimating the amount of shortening of the LPS^[18]. The height of the upper margins of the eyelid is difficult to determine in general anesthesia because patients cannot open their eyelids during surgery, which will also contribute to difficulty in implementing

Table 2 Preoperative, intraoperative and postoperative results

Degree of ptosis	Height of eyelid upper margins ^a (mm)					Scleral exposure		
	Preoperative	Intraoperative	Postoperative			Postoperative (mm)		
			1wk	1mo	6mo	1wk	1mo	6mo
Mild	6-7	5-6	8-11	8-11	8-11	1-2	0	0
Moderate	4-5	7-8	8-11	8-9	8-9	2-4	1-2	0
Severe	2-3	9-10	8-10	7-9	6-9	2-6	2-4	1-2

^aThe height of eyelid upper margins refers to the longitudinal height between the eyelid upper margins and inferior limbus through pupil center.

shortening of the LPS. Relevant research has shown that LPS muscle power is not positively correlated with the elastic force of the integral LPS. There will also be some error in determining the amount of LPS shortening during the operation by measuring LPS muscle force before surgery^[18]. There are some other factors that influence decision-making during the operation including swelling of the eyelid resulting from the operative procedure or hemorrhage; and the pulling force of the LPS in measuring muscle length when attempting to shorten it. These will contribute to a certain degree of error in estimating the required amount of shortening the LPS. To achieve better surgical results, therefore, accurate preoperative and intraoperative measurement, and a reliable judgment method, are needed to assess the extent of LPS shortening.

Based on these reasons, there was no need to consider and measure the force of the LPS preoperatively. Alternatively, we captured standard photographs of the primary position of the eyeball without the eyebrows raised. The collected photographs were imported into Image J software, and the position and radian of the inferior limbus that was covered by the lower eyelid was marked. The reference baseline was the transverse diameter of the cornea, which has a mean value of 11 mm. The height between eyelid upper margins and inferior limbus was then measured using the software. According to the formula $[Z = X - Y$ (explained in the Methods section)], the value of Z is the height of eyelid upper margins that could be calculated and expected to achieve in the operation. The height of the eyelid upper margins was evaluated in advance by objective measurement and calculations performed before the operation, which guided the surgery (shortening of the LPS) executed under general anesthesia. Compared with traditional methods of preoperative LPS strength measurement and the intraoperative measurement of shortened length of the LPS^[7,19], this reformative method has several advantages. Because the transverse and longitudinal diameter of the human cornea is static, the measurement data are stable. Generally, development of the cornea occurs most rapidly in the first six months after birth, and is usually stable from 1 to 6 years of age. Research has confirmed that the average transverse diameter of the male cornea is 11 mm, while in females it is 10.95 mm. Therefore, we regarded 11 mm as the criterion of corneal transverse diameter. The average longitudinal corneal diameter in males is 10.13 mm, while in females it is 10.08 mm (average value 10.11 mm)^[20-21]. Taking into account

postoperative regression, we provide 12 mm as the standard value to use in the calculation. More specifically, the sum of the heights of preoperative and intraoperative eyelid upper margins to the inferior limbus is 12 mm.

The objectivity of preoperative examinations was improved. Although the collection of standard photographs of primary position for child patients was moderately difficult, controllability and precision were significantly better than traditional methods of LPS strength measurement before the operation, and the observation indicators were more reliable during surgery. Because some immediate interference factors of LPS are avoided, such as hemorrhage, swelling and myotaxis, the numerical value was more accurate using methods of measuring the height between eyelid upper margins and inferior limbus intraoperatively than measuring LPS itself under general anesthesia. The modified levator resection technique avoids opening the septa orbitale, and cutting the medial and lateral horns of the LPS and WL^[22-24]; in addition, orbital fat can also be preserved. This method not only retains stable function, but also bypasses its limitation^[25-26], so as to minimize injury to the LPS and surrounding tissue structure, which is beneficial to the recovery of eyelid closure function. Less severe tissue damage and swelling contribute to ensuring the accuracy of measurement(s).

Shortening the LPS was more accurate according to a method involving measuring and calculating the height of upper eyelid margins before and during surgery. Consequently, error in measuring LPS strength before the operation and measuring the truncated length of LPS during surgery was avoided. It made the shortening of the LPS a more accurate and objective detection index in the correction of ptosis in children under general anesthesia. The patients were followed-up for 1wk, 1mo and 6mo, except for two eyelids with overcorrection in the mild and moderate group at 1wk. Seven eyelids in the severe group were undercorrected at 1mo; the positions of the eyelid upper margins were normal in all other cases in the early stages after surgery. The instance of overcorrection possibly occurred because of eyelid swelling in the process of measuring the upper eyelid margin during the operation. Undercorrection occurred mainly in the severe group; thus, the reason for undercorrection was mainly because the strength of LPS is too weak to retain the height of upper eyelid margin. We summarize this innovative measurement method and analyze the possible problems. First, for severe ptosis, if

there was a problem with the elasticity and tension of the aponeurosis itself, the deviation between the measurement/calculation result and postoperative effect would be exposed. Moreover, compared with the traditional method, although there was less influence from soft tissue swelling using this innovate method, it is also a factor that should not be ignored. To improve the accuracy of measurement and intraoperative judgment, surgical skill is required, and edema of the soft tissue should be kept to a strict minimum.

In conclusion, we used this accurate, preoperative quantification technique to guide surgery for LPS shortening under general anesthesia in children with ptosis. Not only was the reliability and practicability of this method confirmed, the increased success rate of the operation was supported by a detailed analysis of data and results. This method provides a more effective objective basis for the implementation of LPS shortening under general anesthesia in children with ptosis.

REFERENCES

- 1 Mai GH, Jin LS, Yan JH, Chen GC, Yang SM. Surgical correction of blepharoptosis in children under general anesthesia. *Chinese Journal of Practical Ophthalmology* 1994;12(3):174-176
- 2 Zuo L, Wang XX, Huang XY, Zhang JL, Du YY. A modified levator resection technique involving retention of the levator palpebrae superioris muscle suspension system for treatment of congenital ptosis. *Aesthetic Plast Surg* 2017;41(4):856-862
- 3 Park DD, Ramadhan A, Han DG, Shim JS, Lee YJ, Ha WH, Lee BK. Comparison of blepharoptosis correction using müller-aponeurosis composite flap advancement and frontalis muscle transfer. *Plast Reconstr Surg Glob Open* 2014;2(8):e200
- 4 SooHoo JR, Davies BW, Allard FD, Durairaj VD. Congenital ptosis. *Surv Ophthalmol* 2014;59(5):483-492
- 5 Li DM. Eyelid Surgery Atlas. *Beijing: Beijing Science and Technology Press* 2009;102
- 6 Fan JF, Yue JL. Progress in basic research and surgical treatment of congenital ptosis. *Chinese Journal of Plastic Surgery* 2003; 19(3): 223-226
- 7 Fan XQ. Ophthalmic Plastic and Reconstructive Surgery. *Beijing: Beijing Science and Technology Press* 2009;110-114
- 8 Thapa R. Refractive error, strabismus and amblyopia in congenital ptosis. *JNMA Nepal Med Assoc* 2010;49(177):43-46
- 9 Nerad, Jeffrey A. Oculoplastic surgery: the requisites (requisites in ophthalmology). *Requisites in Ophthalmology Series*. Michigan; Mosby 2001;511
- 10 Finsterer J. Ptosis: causes, presentation, and management. *Aesthetic Plast Surg* 2003;27(3):193-204

- 11 Marengo M, Macchi I, Macchi I, Galassi E, Massaro-Giordano M, Lambiase A. Clinical presentation and management of congenital ptosis. *Clin Ophthalmol* 2017;11:453-463
- 12 Ungerechts R, Grenzebach U, Harder B, Emmerich KH. Causes, diagnostics and therapy for paediatric ptosis. *Klin Monbl Augenheilkd* 2012;229(1):21-27
- 13 Lin MC. The selection and evaluation of ptosis surgical method. *Chinese Journal of Aesthetic Medicine* 2006;15:(1)46-47
- 14 Wei X, Yang L, Liu Y, Liu P. Suspension of check ligament for the treatment of congenital severe blepharoptosis. *Chinese Journal of Plastic Surgery* 2016;32(6):410-413
- 15 Guan XR, Dong YX, Zhang SH, Lai K, Pu XL, Fu F, Du JY. Efficacy comparison of severe congenital ptosis treated with excessive levator shortening and frontalis muscle flap suspension. *International Eye Science* 2015;15(11):2015-2017
- 16 Göncü T, Çakmak S, Akal A, Karaismailoğlu E. Improvement in levator function after anterior levator resection for the treatment of congenital ptosis. *Ophthalmic Plast Reconstr Surg* 2015;31(3):197-201
- 17 Cruz AA, Akaishi PM, Mendonca AK, Bernadini F, Devoto M, Garcia DM. Supramaximal levator resection for unilateral congenital ptosis: cosmetic and functional results. *Ophthal Plast Reconstr Surg* 2014;30(5):366-371
- 18 Kang WX, Zheng DW, Ren XX, Ji CX. Study on the mechanism and surgical design of congenital ptosis. *Journal of Injuries and Occupational Diseases of the Eye with Ophthalmic Surgeries* 2002;24(1):23-25
- 19 Yin SG, Pang CY. A Study on operative quantity of levator palpebrae superioris muscle resection. *Chinese Journal of Experimental Ophthalmology* 1987;1:12-15
- 20 Bao SC. The measurement of normal corneal transverse diameter in 717 preschool children. *Chinese Journal of Ophthalmology* 1981; 17(5): 286-288
- 21 Sun SM, Bi XL, Chen J, Zhang FH, Zhai Y. The determination of normal corneal size in Chinese. *Chinese Journal of Ophthalmology* 1960; 3:151-156
- 22 Anderson RL, Jordan DR, Dutton JJ. Whitnall's sling for poor function ptosis. *Arch ophthalmol* 1990;108(11):1628-1632
- 23 Anderson RL, Dixon RS. The role of Whitnall's ligament in ptosis surgery. *Arch ophthalmol* 1979;97(4):705-707
- 24 Ng SK, Chan W, Marcet MM, Kakizaki H, Selva D. Levator palpebrae superioris: an anatomical update. *Orbit* 2013;32(1):76-84
- 25 Kakizaki H, Zako M, Ide A, Mito H, Nakano T, Iwaki M. Causes of undercorrection of medial palpebral fissures in blepharoptosis surgery. *Ophthalmic Plast Reconstr Surg* 2004;20(3):198-201
- 26 Jones LT. The anatomy of the upper eyelid and its relation to ptosis surgery. *Am J Ophthalmol* 1964;57:943-959