

Characterization of the geometric properties of the sclero-conjunctival structure: a review

Laurent Bataille^{1,2}, David P Piñero²

¹Research and Development Department, VISSUM, Alicante 03016, Spain

²Group of Optics and Visual Perception, Department of Optics, Pharmacology and Anatomy, University of Alicante, Alicante 03690, Spain

Correspondence to: David P Piñero. Department of Optics, Pharmacology and Anatomy, University of Alicante, Crta San Vicente del Raspeig s/n, San Vicente del Raspeig 03690, Alicante, Spain. david.pinyero@ua.es; Laurent Bataille. Vissum Innovation, C/Cabañal, 1, Alicante 03016, Spain. lbataille@vissum.com

Received: 2019-12-04 Accepted: 2020-07-06

Abstract

• To revise the peer-reviewed literature on geometric properties of the scleral-conjunctival structure in order to define their clinical relevance and the potential relationship between their changes and myopia development or progression. A bibliographic search focused on the study of the geometry of conjunctiva and/or sclera as well as those studies evaluating the relationship between geometric changes in the scleral-conjunctival structure and myopia was carried out. Several studies have been performed with different diagnostic technologies, including optical coherence tomography, profilometry and Scheimpflug imaging, to detect geometric changes of the scleral-conjunctival tissue in different physiological conditions of the eye, after use of contact lenses and in different ocular pathologies. Likewise, these technologies have been shown to be a valuable clinical tool to optimize scleral contact lens fitting. Future studies should investigate new potential clinical applications of such technologies, including the evaluation of anterior scleral changes related to myopia, as well as to define standardized clinical standard operating procedures for obtaining accurate and reproducible clinical measurement of the scleral-conjunctival morphology.

• **KEYWORDS:** conjunctiva; sclera; profilometry; myopia; scleral topography

DOI:10.18240/ijo.2020.09.22

Citation: Bataille L, Piñero DP. Characterization of the geometric properties of the sclero-conjunctival structure: a review. *Int J Ophthalmol* 2020;13(9):1484-1492

INTRODUCTION

The conjunctiva is the transparent, thin membrane that covers a great portion of the anterior surface of the ocular globe and the internal surface of the eyelids. It has two segments: palpebral conjunctiva, which is the portion that covers the internal surface of both the lower and upper eyelids, and bulbar conjunctiva, which is the portion that covers the front part of the sclera, stopping at the junction between sclera and cornea^[1]. These two portions of conjunctiva are continuous and have several relevant functions: to maintain the front surface of the eye lubricated and moist as well as the internal surface of the eyelids. Thus, they eyelids open and close without friction or inducing eye irritation, protecting the eye from dust, debris and infection-causing microorganisms. A great variety of small blood vessels are present in the conjunctiva that provide nutrients. Likewise, there are also special cells in this structure that secrete components of the tear film^[1]. In spite of the large quantity of studies that have been performed about anatomical and histological aspects of this structure^[2-4], there was a scarce peer-reviewed literature about their geometry which has been suggested to be mostly influenced by scleral geometry.

More than 80% of the surface of the eyeball is covered by the sclera, which is below the bulbar conjunctiva, extending from the optic nerve to the corneal area^[5]. The junction area between cornea and sclera is called limbus. The thickness of the sclera is very variable, ranging from about 0.3 to 1.0 mm. The structure of this fibrous layer consists of collagen fibrils that are small fibers with an arrangement in irregular and interlacing bundles. This interweaving of fibers with random arrangement is the main factor accounting for the mechanical strength of the eyeball. As the sclera has a limited blood supply, it is almost inactive metabolically and can be considered as an avascular structure^[5]. In conjunction with the intraocular pressure (IOP), the scleral structure is the main responsible for the maintenance of the shape of the eyeball, protecting the eye from damage, such as that produced by laceration or rupture

as a consequence of an external trauma. This structure is also a sturdy attachment for the extraocular muscles allowing the movement and alignment of both eyes^[5]. As happened with the conjunctive, few studies have been conducted to analyse the geometry of this structure mainly due to the complexity of obtaining an *in-vivo* measurement of such geometry.

The objective of this study was to revise the peer-reviewed literature on geometric properties of the scleral-conjunctival structure in order to define their clinical relevance and the potential relationship between their changes and myopia development or progression.

METHODS

A bibliographic search was carried out using the Medline Mesh Database. The following publications were obtained and selected for these keywords: sclera, including the subgroups diagnosis, diagnosis imaging, growth and development: 41 articles; limbus cornea, including the subgroups diagnosis, diagnosis imaging, growth and development: 3 articles; corneoscleral topography: 6 articles; eye surface profiler: 8 articles. Furthermore, the following search equations were additionally used: sclera AND myopia: 74 articles; review AND myopia: 10 articles. From these 142 articles, 56 articles were confirmed to be repeated for the different search strategies used. Therefore, a total of 86 different articles were finally obtained.

Selection Criteria From the 86 articles found, a total of 38 articles were specifically selected for the current study. The selection criteria were articles in English focused on the study of the geometry properties of conjunctiva and/or sclera as well as those studies evaluating the relationship between geometric changes in the conjunctival-scleral structure and myopia. Articles in Chinese, Russian and German were excluded as well as articles focused on computer assisted modelization. Finally, a total of 26 articles corresponding to scleral analysis in human patients were obtained (Table 1). Likewise, a total of 8 articles corresponding to scleral analysis in human cadaveric eyes or animals were obtained (Table 2).

RESULTS

Measurement Methods of the Scleral-conjunctival Geometry Different technologies have been used to study the geometry of the sclera (Table 3). Several experimental methods like the electron and light microscopy, uniaxial mechanical tests, second harmonic generation imaging and the histomorphometric analysis have been used with cadaveric eyes and/or animals to define the scleral-conjunctival geometry, its evolution with age and its relationship with different ocular pathologies. Despite the important and accurate information obtained with these experimental methods, these last are not clinically applicable. Norman *et al*^[6] analysed the thickness of the sclera by micro-magnetic resonance imaging.

This is an effective and accurate technique to obtain the scleral radius (SR), but it is an expensive technique and somewhat impractical for a general clinical use. The Scheimpflug camera technology has also been used to measure SR, but Tiffany *et al*^[7] showed that this methodology is not the best for this measure as it reaches an average error of 9.2%. The most recent technologies of anterior segment optical coherence tomography (AS-OCT) allow obtaining a 3D reconstruction of the anterior segment, but the acquisition is always done through a sequence of multiple scans that cover a limited area of the anterior segment of the eye (Figure 1)^[8-10]. This technology has been shown to be valid for a precise characterization of the corneoscleral limbal junction in different meridians, allowing an estimation of scleral toricity and helping in the selection of the most optimum design of scleral lens to fit in each specific case^[11]. Likewise, the optical coherence tomography (OCT) is also useful for the evaluation of the ocular response to scleral lens wear^[11]. However, these types of devices are not currently providing elevation maps of the whole anterior surface and do not include advanced modules of simulation of scleral contact lens fit. One problem associated to the measurement with this technology as well as with the rest of devices evaluating the sclero-conjunctival geometry is that the manual retraction of the eyelids to obtain a larger area of analysis may induce a distortion of the original front anterior segment shape due to the effect of traction of the extraocular muscles (flattening of the curvature of the anterior sclera) and a non-controlled pressure on the eyeball.

Unlike OCT technology, the sMap3D system is based on multi-gaze profilometry using fluorescence staining for the detection of the ocular surface, with potentially less limitation by a scanty tear film, ocular surface anomalies, or corneal scarring or irregularities (Figure 2)^[12]. The sMap3D measurements of scleral toricity and sagittal height (SAG) for a chord of 16 mm of diameter are repeatable, which suggests that they may be suitable to use for scleral lens fitting^[13]. This system has been shown to be accurate for measuring the actual surface topography (elevation of the ocular surface) even with irregular corneas, but could be more imprecise in the measurement of corneal power in normal corneas compared to systems based on Placido disc. Another potential problem with this technology is that in order to get accurate measurements of the scleral-conjunctival tissue, several images at different sight positions must be acquired and integrated using a computer program. Specifically, the measurement requires an image with a central sight, another with a downward sight and also with an upward sight with all the difficulties and potential deformations that this entails due to the pressure performed by the upper and lower eyelids over the eye and the eye muscles that deform the scleral structure by the tractions they produce during these measures.

Table 1 Summary of the main findings and characteristics of clinical studies evaluating the scleral-conjunctival geometry in healthy eyes

First author, year	Eyes, patients	Method used for the scleral-conjunctival measurement	Findings
Tiffany ^[7] , 2004	12 eyes from 6 patients	Scheimpflug camera	Values of curvature of cornea and sclera can ideally be determined separately for each individual subject but with mean error of 9.2%
Bandlitz ^[8] , 2017	30 patients	Optos OCT/SLO and Oculus Keratograph	Scleral radii are independent of corneal topography
Choi ^[9] , 2014	24 patients	AS-OCT	AS-OCT is a very useful tool for the measurement of the radii of the anterior scleral surface after image processing and specific mathematical calculations
Kasahara ^[10] , 2014	34 patients	AS-OCT	More gradual scleral gradient in the superonasal quadrant compared with the superotemporal quadrant
DeNaeyer ^[12] , 2017	25 eyes of 23 patients	sMap3D	Significant measurement inaccuracy affecting scleral lens fitting is associated to the use of a single straight-gaze image using the sMap3D profilometer. In contrast, this limitation is not observed when using a 3-gaze stitched image
DeNaeyer ^[13] , 2018	25 eyes of 23 patients	sMap3D	Repeatable measurements in terms of scleral toricity and sagittal height values for a diameter of 16 mm
Jesus ^[16] , 2017	32 human eyes	ESP	Precise topographical limbus demarcation from the 3D topographical information of corneoscleral region
Iskander ^[17] , 2016	Test surfaces and 6 human eyes	ESP	The topography of the anterior surface of the eye including cornea, limbus and sclera can be measured with accuracy
Piñero ^[15] , 2019	21 keratoconus eyes and 88 normal eyes	ESP	Higher levels of corneal-scleral asymmetry in eyes with moderate and advanced keratoconus compared to healthy eyes
Macedo-de-Araújo ^[14] , 2019	18 patients	ESP	Differences in scleral shape between eyes with regular and irregular corneas using the ESP technology was found to be mild. The mechanical impact of scleral contact lens wear on the anterior eye surface can be also evaluated with this technology
Consejo ^[18] , 2019	90 eyes from 45 patients	ESP	Human sclera is rotationally asymmetric, having a subject-dependent shape. This asymmetry increases with radial distance from corneal apex. No significant differences were found in scleral shape between right and left eye in normal healthy eyes
Jesus ^[19] , 2017	23 emmetropic eyes	ESP	The SR can be calculated with high precision using three-dimensional topography of front ocular surface acquired with ESP in combination with a given estimation of the ocular axial length
Consejo ^[20] , 2016	4 eyes	ESP	The anterior limbus position can be determined precisely in a non-invasive and precise mode using tridimensional height data obtained by profilometry of the front eye surface
Consejo ^[21] , 2017	74 patients	ESP	The human limbus has an asymmetrical shape which is person-dependent, although not age-related or correlated with the eye refractive power
Consejo ^[24] , 2018	44 eyes from 22 adults	ESP	There is a correlation of corneal and scleral shapes in eyes with astigmatism. Therefore, astigmatism does not seem to be restricted to the cornea and may be considered a property of the ocular globe
Kuroda ^[26] , 2017	14 patients	AS-OCT	The AS-OCT can be used to evaluate inflammation activity and therapeutic effects in diffuse scleritis
Mohamed-Noor ^[37] , 2009	124 patients (31 with OHT, 31 with POAG, 31 with NTG, and 31 normal individuals)	UBM	CCT and ST are correlated in NTG eyes, but they are not among OHT, POAG, and controls
Oliveira ^[38] , 2006	140 patients	UBM	Correlation between CCT and ST only is present at the scleral spur. This correlation is not associated to axial length or refractive error
Hall ^[24] , 2013	204 human	AS OCT and MS300 topographer	Age is the main factor influencing corneo-scleral profile
Read ^[27] , 2016	111 subjects aged between 10 and 31 years of age	AS-OCT	Scleral and conjunctival thickness change with age and gender as well as according to the measurement location in healthy young adults and children
Tan ^[28] , 2014	48 patients (16 Asian, 16 Caucasian, and 16 Latino)	AS-OCT	CSJ differ significantly among quadrants and between ethnic groups
Hall ^[29] , 2011	50 patients	Videokeratometry and OCT	OCT extra peripheral corneoscleral data provide valuable data to analyse soft contact lens fit dynamics
Woodman-Pieterse ^[39] , 2018	40 patients (20 myopes and 20 emmetropes)	AS-OCT	The anterior sclera experienced a small but statistically significant thinning during accommodation. These changes were especially significant in myopes. Particularly, changes are the highest at 3 mm posterior to the scleral spur
Consejo ^[21] , 2017	44 eyes from 22 healthy adults	Eye Surface Profiler	There are changes in scleral shape with accommodation, being more pronounced in myopes than emmetropes
Read ^[23] , 2016	19 patients	AS-OCT	The anterior sclera and conjunctiva thickness experience diurnal variations
McBrien ^[33] , 2009	172 eyes from 86 subjects	Ultrasound biometry immersion technique; A-scan device (the Biometer AL-1000-TOMEY)	Stiff sclera in hyperopic and emmetropic eyes; biomechanically weakened scleral shell in most of myopic eyes

OCT: Optical coherence tomography; AS-OCT: Anterior segment optical coherence tomography; SLO: Scanning laser ophthalmoscopy; 3D: Three dimensions; ESP: Eye Surface Profiler; UBM: Ultrasound biomicroscopy; CCT: Central corneal thickness; ST: Scleral thickness; SR: Scleral radius; NTG: Normal tension glaucoma; OHT: Ocular hypertension; POAG: Primary open angle glaucoma; CSJ: Corneo-scleral junction.

Table 2 Summary of the main findings of experimental studies in human cadaveric and animal eyes

First author, year	No. of eyes	Method used for scleral measurement	Type	Findings
Norman ^[6] , 2010	11 enucleated human globes	MRI	Human	Significant intra-individual and inter-individual variation in human ST related to axial length
Shen ^[23] , 2016	225 explanted human globes	Histomorphometric analysis	Human	An increase in scleral volume is associated to primary eye growth up to an age of 2 years. After this age, scleral and choroidal volume remain constant, with a thinning of both structures associated to longer axial lengths
Wang ^[26] , 2018	18 ocular globes from white albinus rabbits	Electron microscopy and Instron 5565 universal testing machine	Animal	Constant changes in the structure of different scleral regions, with an increase of the diameters of collagen fibrils during the post-embryonic early growth stage The elastic modulus of the posterior sclera is lower compared to those values corresponding to equatorial and anterior sclera The structure of equatorial and anterior sclera is more stable compared to the posterior sclera
McBrien ^[33] , 2009	Postmortem human eyes	Different methods (review)	Human	Changes in scleral mechanical properties facilitates the increase in axial length occurring in myopia
Wu ^[42] , 2018	Mouse model of myopia	Single cell RNA sequencing	Animal	Myopia is promoted by HIF-1 α signalling through myofibroblast trans-differentiation These HIF-1 α -associated molecular changes can be prevented with antihypoxic treatments, thus avoiding myopia progression

ST: Scleral thickness; MRI: Magnetic resonance imaging; RNA: Ribonucleic acid; HIF: Hypoxia-inducible factor.

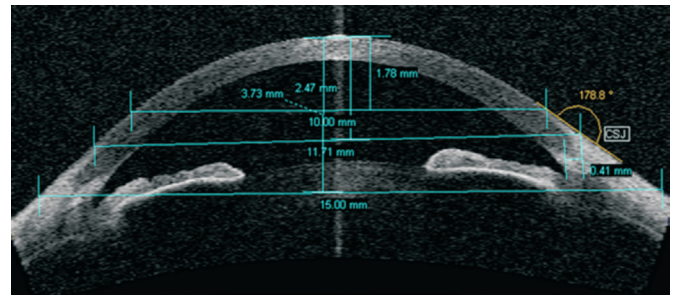


Figure 1 Characterization of the corneo-scleral transition using OCT, showing that only a limited area of sclera can be visualized.

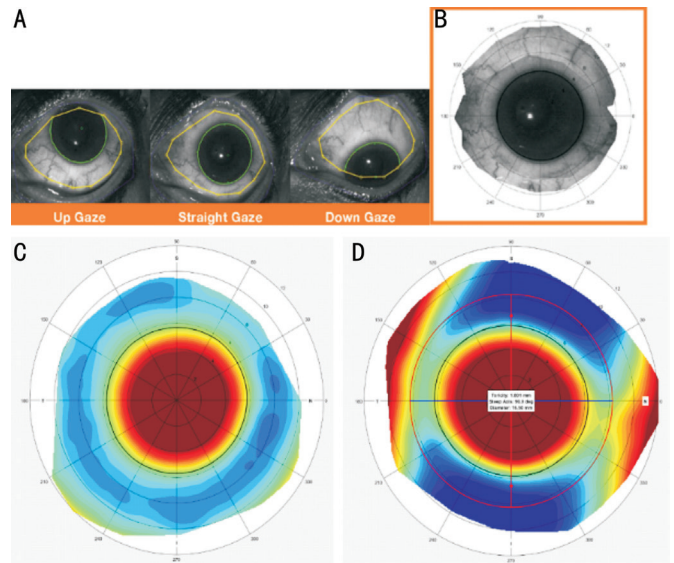


Figure 2 Characterization of the corneal-scleral surface with the sMap3D profilometer A: Gaze images acquisition; B: 3 gazes stitched together; C: Normal 2D scleral elevation map; D: Keratoconus 2D scleral elevation map.

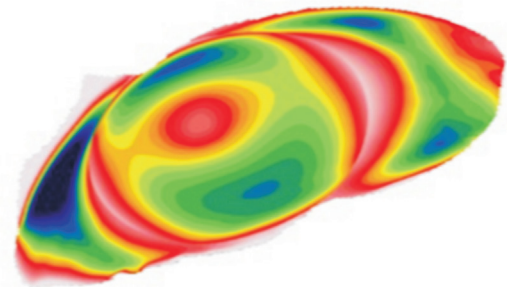


Figure 3 Characterization of the corneo-scleral surface with the ESP profilometer.

The Fourier domain profilometry with the Eye Surface Profiler (ESP) System consists of two blue-band projectors and a central camera with a yellow filter that captures an image of the front surface of the eye. The great advantage of this system is that it simultaneously analyzes an area of up to 20 mm diameter including more than 250 000 points the supposes the covering of all corneal tissue, limbus and large part of the sclera. This system allows obtaining a precise corneo-scleral topography (Figure 3)^[14-17]. The full 3D scleral maps obtained with the

Table 3 Summary of the mean values of different geometric parameters corresponding to the scleral-conjunctival profile in healthy eyes

First author, year	No. and type of eyes	Method used for the scleral measurement	Geometric data
Shen ^[23] , 2016	225 explanted human globes	Histomorphometric analysis	Mean computed scleral volume 648±136 mm ³ ; mean choroidal volume, being calculated from or a serrata to the posterior pole 44.1±14.1 mm ³
Hall ^[24] , 2013	204 patients	AS-OCT and MS300 topographer	Nasal horizontal CSJ 173.9°±3.4°; temporal horizontal CSJ 177.0°±2.4°; superior vertical CSJ 178.1°±1.9°; inferior vertical CSJ 177.7°±1.6°; nasal horizontal SR 35.5±39.4 mm; temporal horizontal 22.4±12.7 mm; superior vertical 29.3±17.4 mm; inferior vertical 33.5±29.6 mm
Wang ^[26] , 2018	18 ocular globes from white albinus rabbits	Electron microscopy and Instron 5565 universal testing machine	1mo age group: diameters of collagen fibrils in anterior sclera ranged from 35.7 to 171.2 nm, from 21.4 to 156.9 nm in the equatorial sclera, and from 14.3 to 99.9 nm in the posterior sclera; 2mo age group: diameters of collagen fibrils in anterior sclera from 42.8 to 242.5 nm, from 42.8 to 228.2 nm in the equatorial sclera, and from 42.8 to 228.2 nm in the posterior sclera; 3mo age group: diameters of collagen fibrils in anterior sclera from 42.8 to 272.5 nm, from 42.8 to 242.5 nm in the equatorial sclera, from 42.8 to 242.5 nm in the posterior sclera
Read ^[27] , 2016	111 subjects aged between 10 and 31 years of age	AS-OCT	Mean ST across all locations (270±90 µm), nasal meridians (506±72 µm), temporal meridians (504±93 µm); thickness at the scleral spur location: temporal (653±54 µm), nasal (606±42 µm)
Hall ^[29] , 2011	50 patients	Videokeratoscopy and OCT	Nasal horizontal CSJ 173.7°±3.1°; temporal horizontal CSJ 177.6°±1.6°; superior vertical CSJ 178.3°±1.7°; inferior vertical CSJ 177.74°±1.4°; nasal horizontal SR 45.0±41.4 mm; temporal horizontal SR 25.3±14.8 mm; superior vertical SR 43.1±32.2 mm; inferior vertical SR 42.2±30.1 mm
Woodman-Pieterse ^[30] , 2018	40 patients (20 myopes and 20 emmetropes)	AS-OCT	Anterior ST: at 3-mm location (543±67 µm), at 2-mm location (504±60 µm), at 1-mm location (512±52 µm); total anterior wall thickness: at 3-mm location (752±91 µm); at 2-mm location (730±87 µm); at 1-mm location (751±81 µm); mean change in anterior ST with accommodation: 6 D, mean change: -8±21 µm; 3 D, mean change: -6±20 µm
Consejo ^[31] , 2017	44 eyes from 22 healthy adults	ESP	A mean scleral change at the nasal area of 390±330 µm was found in the young group when using a 4.0 D stimulus. This modification was more prominent in myopic eyes (nasal part: 560±350 µm vs emmetropes nasal part: 220±120 µm)
Read ^[32] , 2016	19 patients	AS-OCT	Mean conjunctival thickness: 249±42 µm; mean diurnal amplitude: 69±29 µm; mean ST: 519±42 µm; mean diurnal amplitude: 21±8 µm
Piñero ^[35] , 2019	21 keratoconus eyes and 88 healthy eyes	ESP	SR healthy eyes: 13.35±1.29 mm; SR keratoconus eyes: 13.40±1.21 mm (right eye 14.03±1.31 mm and left eye 12.69±0.53 mm)
Kuroda ^[36] , 2017	14 patients	AS-OCT	Significantly thicker conjunctival stroma/episclera could be observed in eyes with diffuse anterior scleral compared to healthy eyes (403.0 vs 288.0 µm); scleral stroma thickness did not differ significantly among anterior scleral inflammation and healthy eyes (464.7 vs 434.2 µm, P=0.11)
Mohamed-Noor ^[37] , 2009	124 human (31 with OHT, 31 with POAG, 31 with NTG, and 31 normal individuals)	UBM	ST: OHT 755.03±69.58 µm, POAG 738.45±66.83 µm, NTG 708.74±71.58 µm, Controls 724.45±73.27 µm
Oliveira ^[38] , 2006	140 patients	UBM	Mean ST: at 1 mm 699±65 µm, at 2 mm 510.5±62 µm, at 3 mm 506.9±65 µm; Caucasians 692.8±56.9 µm, non-Caucasians 718.0±62.4 µm

CSJ: Corneo-scleral junction; SR: Scleral radius; AS-OCT: Anterior segment optical coherence tomography; ST: Scleral thickness; ESP: Eye Surface Profiler; OCT: Optical coherence tomography; UBM: Ultrasound biomicroscopy; NTG: Normal tension glaucoma; OHT: Ocular hypertension; POAG: Primary open angle glaucoma.

ESP profilometer provides a very complete analysis of the shape of the human sclero-conjunctival surfaces. According to the measurements obtained with this device, human sclera has been shown to be rotationally asymmetric, showing a subject-dependent geometry. The nasal area of the sclera is less elevated than the temporal area. Furthermore, there is an increase of the asymmetry of the sclera considering a radial distance from corneal apex to periphery^[18]. Furthermore, for healthy subjects, no statistically significant differences in scleral shape were present between right and left eyes^[18]. With a specific estimate of the axial length, these scleral maps can be used to obtain a precise measurement of the SR^[19]. The ESP device also allows characterizing the anterior limbus in a non-invasive and precise mode by processing the tridimensional anterior eye height data obtained with this device^[20]. This topographical information of limbus is not strictly coincident with the maximum rate of colour change from iris to sclera that can be observed in en-face imaging^[20]. Likewise, the human limbus has an asymmetrical person-dependent shape, which is not related to age or the ocular refractive power^[21].

All these devices allow a characterization of any type of ocular surface contour and therefore an appropriate selection of the most optimal landing zone design of a scleral lens for its optimal fitting, adequate vaulting over cornea and limbus, and ideal alignment on the sclero-conjunctival surface^[22].

Geometric Variations in the Scleral-conjunctival Profile

Several authors have analysed the geometric changes of the scleral-conjunctival tissue in different physiological conditions of the eye (age, gender, measurement location, accommodation, diurnal changes), after contact lens wear and in the cases of different ocular pathologies (keratoconus, glaucoma, scleritis). Shen *et al*^[23] demonstrated with the histomorphometric analysis of explanted eyes of children with retinoblastoma as well as eyes from adults with malignant melanomas or end-stage glaucoma that there is an increase of scleral volume associated to primary eye growth up to 2 years of age. After this age, scleral and choroidal volume remain constant, with thinning of scleral and choroidal layers especially at the posterior pole in those eyes with longer axial length. Hall *et al*^[24] demonstrated in subjects of age between 18 and 65y that age is the main factor influencing corneo-scleral profile. Variations of this ocular topography also with height, gender, ethnicity and refractive error have been also found. Similar trends have been recently reported using Fourier-domain OCT in a sample of healthy eyes^[25].

Wang *et al*^[26] reported a constant change of the structure of different scleral regions. The diameter of collagen fibrils experienced a relevant increase during the post-embryonic early growth stage, which was found to improve the elastic modulus of the scleral tissue. Looser arrangement of scleral

collagen fibrils has been observed in the posterior sclera compared to those that are present in equatorial and anterior sclera during the growth and development process, with the posterior sclera also showing a large number of small diameter collagen fibrils. Thus, the posterior scleral elastic modulus was found to be lower than that of the equatorial and anterior sclera. Considering that the structure of the anterior and equatorial sclera tends to be more stable than that of the posterior sclera, it may be more likely to change in some scleral-related diseases or alterations, such as in high myopia and scleral ectasia. These experimental findings are consistent with the results obtained by Read *et al*^[27] in human subjects aged between 10 and 31y. Scleral and conjunctival thickness experience significant age and gender-related variations as well as changes according to the measurement location. Refractive error, however, does not appear to significantly influence the anterior scleral (or conjunctival) thickness in this population of young subjects.

Concerning the corneoscleral junction, Tan *et al*^[28] demonstrated that the angle and topography of the corneoscleral junction is different between ethnic groups (Asian, Caucasian, and Latino). Caucasians showed significantly higher angle and rougher surface of the corneoscleral junction than Asians and Latinos. Some differences among ethnic groups have been found, although these ethnic differences are not the same for all quadrants. The nasal quadrant has a much more pronounced corneoscleral angle and/or rougher corneo-scleral junction (CSJ) profile. These results agree with the results obtained from Hall *et al*^[29] who found a tendency of mean CSJ angle to be sharpest at the nasal area, becoming progressively flatter at the temporal, inferior, and superior areas. Steepest mean scleral curvature was also observed in the temporal sclera, with more similar curvature in the superior, inferior and nasal scleral planes.

Besides all this research, there are also some scientific evidence about changes occurring in the scleral-conjunctival structure with accommodation. Woodman-Pieterse *et al*^[30] were the first in providing evidence of the presence of a significant anterior scleral thinning associated to the process of accommodation. These changes were found to be especially significant at 3 mm posterior to the scleral spur in myopic eyes. These regional differences may be associated with regional variations among refractive error groups of the thickness of ciliary body reported previously by other authors, regional differences in the ciliary muscle contraction with accommodation, or differences in the scleral response to these mechanical forces^[30]. Another research group have also demonstrated recently that the scleral shape experiences changes with accommodation, being more pronounced these changes in myopic eyes compared to emmetropes^[31]. All these evidences suggest that the geometry of the anterior sclera may change due to the action

of ocular muscles (extraocular and ciliary muscles) during the accommodation process. In eyes that can accommodate, the mechanical effects of accommodative convergence dominate over those induced by the ciliary muscle, although both effects can occur simultaneously. Considering the location of the 'anchor point' of the main extraocular muscles responsible for accommodative convergence on the sclera, a more significant change could be expected in the horizontal meridian than in the vertical. The uniform effect of the ciliary muscle is present but somehow 'masked', as the not uniform contribution of extraocular muscles is more relevant^[31].

Read *et al*^[32] provided the first evidence of diurnal variations of anterior scleral and conjunctival thicknesses. This confirms that studies requiring precise measures of the thickness of these anatomical layers should be performed considering a specific period of day to take the measurements. Most of changes in these thicknesses occurred in the early morning immediately after waking, with a larger magnitude for those occurring in the conjunctiva. Thickness changes at other times of the day were of lower magnitude and not representing in most of cases a statistically significant change.

Concerning myopia, loss of scleral tissue and subsequent scleral thinning have been found to occur rapidly during axial myopic development^[33]. However, this initial tissue loss experience a progress without significant alterations to the collagen fibril diameter distribution associated. In the long term, an increased number of small diameter collagen fibrils is present in the sclera of highly myopic eyes, which is consistent with findings in humans and is likely to contribute to the weakened mechanical properties of the sclera^[31]. Additionally, corneal and scleral shapes have been found to be correlated in eyes with astigmatism, which suggests that astigmatism is not restricted to the corneal structure and could be considered a property of the entire eye globe^[34].

In the field of ocular pathology, some studies have been conducted to characterize changes occurring in the scleral-conjunctival geometric profile in different diseases. Piñero *et al*^[35] detected in moderate and advanced stages of keratoconus a significantly more asymmetric anterior scleral-conjunctival geometric profile rather than in healthy eyes. These results suggest that a potential geometric alteration exists in both the diseased cornea and the anterior sclera of the moderate and advanced stages of keratoconus. Kuroda *et al*^[36] demonstrated that the swelling of diffuse scleritis occurred within the episclera rather than in the scleral stroma. Since OCT visualises the morphology of the episclera and sclera, it can be useful for evaluating inflammation activity and therapeutic effects in diffuse scleritis. Mohamed-Noor *et al*^[37] reported a correlation between central corneal thickness (CCT) and scleral thickness (ST) among eyes with normal tension

glaucoma (NTG), but no correlation was seen among groups of eyes with ocular hypertension (OHT), primary open angle glaucoma (POAG) and controls. Likewise, Oliveira *et al*^[38] demonstrated that the CCT only correlated with the ST at the scleral spur, with no relationship to axial length or refractive error. This study did not support the hypothesis that a thin CCT was a surrogate marker for abnormal scleral or lamellar thickness as an independent cause of increased glaucoma risk.

Anterior Sclero-conjunctival Geometric Changes and Myopia Several studies have been conducted in the last years to analyse alterations of scleral structure in myopia due to an increasing interest of clinicians and researchers in this issue. These researches are crucial for new developments in scleral surgery and emerging minimally invasive therapies to treat scleral-related vision disorders and to reverse myopia-associated scleral extracellular matrix (ECM) remodelling events. It should be considered that the sclera does not behave as a static container of the eye content, being a dynamic tissue, with capacity of altering its ECM composition due to visual environmental changes to regulate ocular globe size and refraction^[39].

Scleral changes in myopic eyes have been linked to altered expression of several genes, such as matrix metalloproteases (MMPs), fibroblast growth factor receptor-1 (FGF receptor-1), collagen (predominantly type-I), tissue inhibitors of MMPs (TIMPs), transforming growth factor β (TGF β), and integrins^[40]. Myopia has been linked to a reduction in the collagen subtype ratio (V/I), with some speculations about the relevance of this reduction on the alterations of the fibril diameter in myopic eyes. The active form of an enzyme associated with the breakdown of collagen and proteoglycans, MMP-2, is highly present in myopic scleras as well as reduced levels of TIMP-1. Furthermore, myopia development has been linked to the downregulation of collagen binding integrin subunits $\alpha 1$, $\alpha 2$, and $\beta 1$ as well as TGF β isoforms, particularly TGF $\beta 1$. Likewise, the upregulation of FGF receptor-1 have been also associated to the eye elongation development. Two second messengers have been implicated in studies based on the guinea pig model. In form deprivation myopia, scleral cyclic AMP and cyclic GMP levels have been also found to be increased^[40]. Myopic eyes are characterized by scleral ECM remodelling, but the initiators and signalling pathways underlying scleral ECM remodelling in myopia are not well understood.

According to Harper and Summers^[41], therapies promoting a slow ECM loss in the human sclera, through stimulation of proteoglycan and collagen synthesis, MMP activity inhibition, or collagen crosslinking procedures may be adequate therapeutic approaches to reduce the progression of myopia. The retinaldehyde dehydrogenase 2 (RALDH2) has been

identified as a visually regulated enzyme, being a potent scleral ECM remodelling regulator through its synthesis of all-trans-retinoic acid. This is another relevant evidence for creating new approaches to slow or prevent the myopia progression in children. Wu *et al*^[42] have demonstrated that hypoxia-inducible factor-1 α (HIF-1 α) signalling promoted myopia through myofibroblast trans differentiation. In addition, HIF-1 α -associated molecular changes can be prevented by antihypoxic treatments, thus avoiding myopia progression. These findings defined the relevance of hypoxia in scleral ECM remodeling and their relationship with myopia development. Scleral hypoxia identification in myopia is not only a concept for understanding the mechanisms of myopia development, but also promotes the design and development of new viable therapeutic approaches to control myopia progression in humans.

Despite all this evidence of structural scleral changes related to myopia, there are no scientific studies to this date reporting and defining the real relationship between anterior sclero-conjunctival geometry and myopia. Hu *et al*^[43] demonstrated that the average axial length/horizontal corneal radius of curvature ratio in eyes with pathological myopia decreased significantly after posterior scleral reinforcement. More studies are required to characterize this relationship between the geometry of the sclero-conjunctival and that corresponding to the posterior sclera.

CONCLUSION

Several studies have permitted to evaluate the accuracy of different diagnostic technologies for the measurement of the morphogeometric properties of the scleral-conjunctival structure, including OCT, profilometry and Scheimpflug imaging analysis, in different physiological condition of the eye as well as different ocular pathologies. The scleral-conjunctival morphology is an important parameter to define the SAG of the scleral lens to fit as well as its most adequate landing zone. Likewise, the measurements provided by these technologies allow the practitioner to define the level of peritricity required if necessary, in each specific case. However, this is not the only potential use of this type of analysis, being also useful for the confirmation of some diagnoses and for the control of the development and treatment of different pathologies and myopia. All this research has been complemented with experimental studies demonstrating important morphological differences in myopic eyes compared to control eyes as well as morphological modification of the sclera during the myopia development. The use of profilometry, OCT and Scheimpflug imaging for the analysis of the sclero-conjunctival geometry should be studied further in order to find new potential clinical applications for this type of analysis as well as to define standardized clinical standard operating procedures for

obtaining accurate and reproducible clinical measurement of the scleral-conjunctival morphology. Likewise, more studies are needed to characterize the relationship between the scleral-conjunctival morphology and posterior scleral geometry in order to define the potential usefulness of the measurements obtained with the technologies prescribed to monitor and predict myopic changes.

ACKNOWLEDGEMENTS

Foundations: Supported by the Project UAIND18-06B of the University of Alicante within the program “Ayudas destinadas a la formación predoctoral en colaboración con empresas 2018” supported by the Vicerrectorado de Investigación y Transferencia de Conocimiento. Piñero DP has been also supported by the Ministry of Economy, Industry and Competitiveness of Spain within the program Ramón y Cajal, RYC-2016-20471.

Conflicts of Interest: Bataille L, None; Piñero DP has been supported by the Ministry of Economy, Industry and Competitiveness of Spain within the program Ramón y Cajal, RYC-2016-20471.

REFERENCES

- 1 Rocher N. Anatomy and physiology of the human eye. *Soins* 2010;55(744):30-31.
- 2 Shumway CL, Wade M. Anatomy, head and neck, eye conjunctiva. StatPearls. Treasure Island (FL): StatPearls Publishing; Jan-2019 Feb 7. <https://pubmed.ncbi.nlm.nih.gov/30137787/>.
- 3 Gipson IK. Goblet cells of the conjunctiva: a review of recent findings. *Prog Retin Eye Res* 2016;54:49-63.
- 4 Takahashi Y, Watanabe A, Matsuda H, Nakamura Y, Nakano T, Asamoto K, Ikeda H, Kakizaki H. Anatomy of secretory glands in the eyelid and conjunctiva: a photographic review. *Ophthalmic Plast Reconstr Surg* 1900;29(3):215-219.
- 5 McBrien NA, Gentle A. Role of the sclera in the development and pathological complications of myopia. *Prog Retin Eye Res* 2003;22(3):307-338.
- 6 Norman RE, Flanagan JG, Rausch SMK, Sigal IA, Tertinegg I, Eilaghi A, Portnoy S, Sled JG, Ethier CR. Dimensions of the human sclera: Thickness measurement and regional changes with axial length. *Exp Eye Res* 2010;90(2):277-284.
- 7 Tiffany JM, Grande EF, Todd BS. Measurement of scleral curvature by scheimpflug photography. *Investig Ophthalmol Vis Sci* 2004; 45(13):2389.
- 8 Bandlitz S, Bäumer J, Conrad U, Wolffsohn J. Scleral topography analysed by optical coherence tomography. *Cont Lens Anterior Eye* 2017;40(4):242-247.
- 9 Choi HJ, Lee SM, Lee JY, Lee SY, Kim MK, Wee WR. Measurement of anterior scleral curvature using anterior segment OCT. *Optom Vis Sci* 2014;91(7):793-802.
- 10 Kasahara M, Shoji N, Morita T, Shimizu K. Comparative optical coherence tomography study of differences in scleral shape between

- the superonasal and superotemporal quadrants. *Jpn J Ophthalmol* 2014;58(5):396-401.
- 11 Vincent SJ, Alonso-Caneiro D, Collins MJ. Optical coherence tomography and scleral contact lenses: clinical and research applications. *Clin Exp Optom* 2019;102(3):224-241.
- 12 DeNaeyer G, Sanders DR, Farajian TS. Surface coverage with single vs. multiple gaze surface topography to fit scleral lenses. *Cont Lens Anterior Eye* 2017;40(3):162-169.
- 13 DeNaeyer G, Sanders DR. sMap3D corneo-scleral topographer repeatability in scleral lens patients. *Eye Contact Lens* 2018;44: S259-S264.
- 14 Macedo-De-araújo RJ, van der Worp E, González-Méijome JM. *In vivo* assessment of the anterior scleral contour assisted by automatic profilometry and changes in conjunctival shape after miniscleral contact lens fitting. *J Optom* 2019;12(2):131-140.
- 15 Piñero DP, Martínez-Abad A, Soto-Negro R, Ariza-Gracia MA, Carracedo G. Characterization of corneoscleral geometry using Fourier transform profilometry in the healthy eye. *Eye Contact Lens* 2019;45(3):201-207.
- 16 Jesus DA, Iskander DR. On the methods for estimating the corneoscleral limbus. *IEEE Trans Biomed Eng* 2017;64(8): 1826-1833.
- 17 Iskander DR, Wachel P, Simpson PND, Consejo A, Jesus DA. Principles of operation, accuracy and precision of an Eye Surface Profiler. *Ophthalmic Physiol Opt* 2016;36(3):266-278.
- 18 Consejo A, Llorens-Quintana C, Bartuzel MM, Iskander DR, Rozema JJ. Rotation asymmetry of the human sclera. *Acta Ophthalmol* 2019;97(2):1-5.
- 19 Jesus DA, Kedzia R, Iskander DR. Precise measurement of scleral radius using anterior eye profilometry. *Cont Lens Anterior Eye* 2017;40(1):47-52.
- 20 Consejo A, Iskander DR. Corneo-scleral limbus demarcation from 3D height data. *Cont Lens Anterior Eye* 2016;39(6):450-457.
- 21 Consejo A, Llorens-Quintana C, Radhakrishnan H, Iskander RD. Mean shape of the human limbus. *J Cataract Refract Surg* 2017;43(5):667-672.
- 22 Fadel D. The influence of limbal and scleral shape on scleral lens design. *Cont Lens Anterior Eye* 2018;41(4):321-328.
- 23 Shen L, You QS, Xu XL, Gao F, Zhang ZB, Li B, Jonas JB. Scleral and choroidal volume in relation to axial length in infants with retinoblastoma versus adults with malignant melanomas or end-stage glaucoma. *Graefes Arch Clin Exp Ophthalmol* 2016;254(9):1779-1786.
- 24 Hall LA, Hunt C, Young G, Wolffsohn J. Factors affecting corneoscleral topography. *Invest Ophthalmol Vis Sci* 2013;54(5):3691.
- 25 Seguí-Crespo M, Ariza-Gracia MÁ, Sixpene NDL, Piñero DP. Geometrical characterization of the corneo-scleral transition in normal patients with Fourier domain optical coherence tomography. *Int Ophthalmol* 2019;39(11):2603-2609.
- 26 Wang CC, Xie YF, Wang GH. The elastic modulus and collagen of sclera increase during the early growth process. *J Mech Behav Biomed Mater* 2018;77:566-571.
- 27 Read SA, Alonso-Caneiro D, Vincent SJ, Bremner A, Fothergill A, Ismail B, McGraw R, Quirk CJ, Wrigley E. Anterior eye tissue morphology: scleral and conjunctival thickness in children and young adults. *Sci Rep* 2016;6:33796.
- 28 Tan B, Graham AD, Tsechpenakis G, Lin MC. A novel analytical method using OCT to describe the corneoscleral junction. *Optom Vis Sci* 2014;91(6):650-657.
- 29 Hall LA, Young G, Wolffsohn JS, Riley C. The influence of corneoscleral topography on soft contact lens fit. *Investig Ophthalmol Vis Sci* 2011;52(9):6801-6806.
- 30 Woodman-Pieterse EC, Read SA, Collins MJ, Alonso-Caneiro D. Anterior scleral thickness changes with accommodation in myopes and emmetropes. *Exp Eye Res* 2018;177:96-103.
- 31 Consejo A, Radhakrishnan H, Iskander DR. Scleral changes with accommodation. *Ophthalmic Physiol Opt* 2017;37(3):263-274.
- 32 Read SA, Alonso-Caneiro D, Free KA, Labuc-Spoors E, Leigh JK, Quirk CJ, Yang ZYL, Vincent SJ. Diurnal variation of anterior scleral and conjunctival thickness. *Ophthalmic Physiol Opt* 2016;36(3):279-289.
- 33 McBrien NA, Jobling AI, Gentle A. Biomechanics of the sclera in myopia: extracellular and cellular factors. *Optom Vis Sci* 2009;86(1):E23-E30.
- 34 Consejo A, Rozema JJ. Scleral shape and its correlations with corneal astigmatism. *Cornea* 2018;37(8):1047-1052.
- 35 Piñero DP, Martínez-Abad A, Soto-Negro R, Ruiz-Fortes P, Pérez-Cambrodi RJ, Ariza-Gracia MA, Carracedo G. Differences in corneo-scleral topographic profile between healthy and keratoconus corneas. *Cont Lens Anterior Eye* 2019;42(1):75-84.
- 36 Kuroda Y, Uji A, Morooka S, Nishijima K, Yoshimura N. Morphological features in anterior scleral inflammation using swept-source optical coherence tomography with multiple B-scan averaging. *Br J Ophthalmol* 2017;101(4):411-417.
- 37 Mohamed-Noor J, Bochmann F, Siddiqui MAR, Atta HR, Leslie T, Maharajan P, Wong YM, Azuara-Blanco A. Correlation between corneal and scleral thickness in glaucoma. *J Glaucoma* 2009;18(1):32-36.
- 38 Oliveira C, Tello C, Liebmann J, Ritch R. Central corneal thickness is not related to anterior scleral thickness or axial length. *J Glaucoma* 2006;15(3):190-194.
- 39 Rada JAS, Shelton S, Norton TT. The sclera and myopia. *Exp Eye Res* 2006;82(2):185-200.
- 40 Metlapally R, Wildsoet CF. Scleral mechanisms underlying ocular growth and myopia. *Prog Mol Transl Sci* 2015;134:241-248.
- 41 Harper AR, Summers JA. The dynamic sclera: Extracellular matrix remodeling in normal ocular growth and myopia development. *Exp Eye Res* 2015;133:100-111.
- 42 Wu H, Chen W, Zhao F, *et al.* Scleral hypoxia is a target for myopia control. *Proc Natl Acad Sci U S A* 2018;115(30):E7091-E7100.
- 43 Hu HL, Zhao GY, Wu RF, Zhong HH, Fang M, Deng HW. Axial length/corneal radius of curvature ratio assessment of posterior sclera reinforcement for pathologic myopia. *Ophthalmologica* 2018;239(2-3): 128-132.