

# Vitreous function and intervention of it with vitrectomy and other modalities

Yao Zong<sup>1</sup>, Qian-Ying Gao<sup>2</sup>, Yan-Nian Hui<sup>3</sup>

<sup>1</sup>Department of Ophthalmology, the Affiliated Hospital of Qingdao University, Qingdao 266003, Shandong Province, China

<sup>2</sup>Vesber Vitreous Institute, Guangzhou 510000, Guangdong Province, China

<sup>3</sup>Department of Ophthalmology, Eye Institute of PLA, Xijing Hospital, Fourth Military Medical University, Xi'an 710032, Shaanxi Province, China

**Correspondence to:** Qian-Ying Gao. Vesber Vitreous Institute, Guangzhou 510000, Guangdong Province, China. gaoqy@hotmail.com; Yan-Nian Hui. Department of Ophthalmology, Eye Institute of PLA, Xijing Hospital, Fourth Military Medical University, No.127 Changle West Road, Xi'an 710032, Shaanxi Province, China. ynlhui@163.com

Received: 2020-11-10 Accepted: 2021-05-14

## Abstract

• The vitreous body, the largest intraocular component, plays a key role in eye development, refraction, cell barrier function, oxygen metabolism and the pathogenesis of assorted diseases. Age, refraction and systemic diseases can cause vitreous metabolic abnormalities. With the continuous development of vitrectomy techniques and equipment, vitreous injections and vitrectomies have increased over the recent decades. However, the normal oxygen tension gradient in the vitreous helps to protect the lens and anterior chamber angle from oxidative stress damage, whereas the increased vitreous oxygen tension around lens and the trabecular meshwork after vitrectomy may lead to postoperative nuclear cataract and a high incidence of open angle glaucoma. As a conventional procedure, scleral buckling holds several advantages over vitrectomy in selected cases. This review raises concerns regarding the function of the vitreous, and encourages conducting vitreous interventions prudently.

• **KEYWORDS:** vitreous; function; oxygen metabolism; vitrectomy; scleral buckling

**DOI:**10.18240/ijo.2021.10.20

**Citation:** Zong Y, Gao QY, Hui YN. Vitreous function and intervention of it with vitrectomy and other modalities. *Int J Ophthalmol* 2021;14(10):1610-1618

## INTRODUCTION

The vitreous gel, which is mostly composed of water, is optically transparent, and has important roles in eye development, refraction, cellular barriers, and intraocular oxygen metabolism. The vitreous gel liquefies with aging, and the liquefaction process is involved in many vitreoretinal diseases, including rhegmatogenous retinal detachment (RRD). RRD is caused by the formation of retinal tears, allowing vitreous fluid into the subretinal space, which results in the separation of the retinal neuroepithelial layer from the retinal pigment epithelium (RPE). The reported incidence of RRD is 18.6 eyes per 100 000 person-years<sup>[1]</sup>. Scleral buckling (SB) is the traditional procedure for the treatment of RRD, and demonstrates favorable curative effect with few complications, such as scleral laceration, choroidal hemorrhage, epiretinal membranes, macular fold and buckle exposure<sup>[2]</sup>. However, with the continuous development of vitrectomy techniques and equipment, the use of SB is gradually declining and even facing the possibility of being eliminated. Some doctors choose intravitreal injection and pars plana vitrectomy (PPV) without the proper indications, because of inadequate knowledge of the vitreous body, leading to severe complications that could have been avoided, such as cataract, preretinal fibrosis, oil migration, corneal edema, oil emulsification and intraocular hypertension<sup>[3]</sup>. Studies show no significant difference in the achievement ratio of operations between PPV, SB, and the combined procedures for the treatment of RRD<sup>[1]</sup>. Unlike PPV, SB retains the intact vitreous body and reduces the interference of intraocular metabolism to the lowest level, in order to reduce the possibility of serious complications due to vitreous metabolic disturbance. Hence, we have emphasized the importance of recognizing the functions of the vitreous body and increasing the popularity of SB for treating suitable primary RRD, as well as advised caution in the use of more aggressive surgery such as PPV. Besides that, the traditional SB is also improved by several modifications, which reduce complications and surgical difficulty, and shorten the operation time<sup>[4]</sup>, increases the popularity of SB for treating primary RRD and maintain SB as an option for appropriate patients in the future<sup>[5]</sup>. It is time to recognize the functions of the vitreous, and the necessity for following strict surgical indications and careful assessment for vitrectomy procedures.

## COMPOSITION AND PHYSIOLOGY OF THE VITREOUS BODY

It was thought previously that the vitreous body had no well-substantiated physiological function, apart from giving the eye its shape and volume, so that the eye would not be adversely affected by vitreous gel removal<sup>[6]</sup>. However, the new understanding is that an intact vitreous gel is crucial for stable intraocular metabolism. The vitreous gel plays a major role in refraction, cellular barriers, participating in intraocular oxygen metabolism and the pathology of diseases. To understand the physiological function of vitreous body, we must first understand its structure, components, development, and metabolism.

The transparent, gelatinous vitreous makes up 80% of the intraocular volume, adjacent to the retina, lens and ciliary body. Vitreous gel is composed of the vitreous membrane, cortex and nucleus. The vitreous membrane, composed of dense collagen fibers, is located in the peripheral part of the vitreous. The vitreous cortex is located between the vitreous membrane and nucleus. The vitreous nucleus occupies most of the space in the middle, and in the center is the Cloquet canal, degenerated from the vascular primary vitreous. The vitreous is most-closely connected with the retina at the vitreous base, macula and optic disc<sup>[7]</sup>. The posterior vitreous boundary membrane and inner limiting membrane jointly constitute the vitreous-retina interface.

As the embryo develops, vitreous gel formation is a dynamic process in which the avascular transparent secondary vitreous gradually replaces the primary vitreous. The highly hydrated, almost acellular vitreous gel is composed mainly of collagen and hyaluronan, with water accounting for approximately 98%-99% of it. The 0.1% of the gel consisting of macromolecules is the most important for its matrix structure<sup>[8]</sup>, which is responsible for the gel's viscoelastic properties, and is composed of collagen fibrils and macromolecules (such as hyaluronan and versican) arranged in a network<sup>[9]</sup>. Collagen fibrils are composed of collagen types II, V/XI, and IX, of which type II accounts for three-quarters<sup>[10]</sup>. Type II collagen is transformed from a soluble precursor (type II procollagen) with an amino-propeptide terminus and a carboxy-propeptide terminus and is synthesized and excreted by cells<sup>[11]</sup>. It has also been shown to be synthesized in adult bovine eyes<sup>[12]</sup>. Hyaluronan fills the gaps in the collagen-fiber network to stabilize the structure. Versicans, such as proteoglycans and glycoproteins, bind to the components of the extracellular matrix and are interrelated<sup>[13]</sup>.

Vitreous gel is important in the development of the eyeball, in maintaining its elasticity and in reducing the scattering of light. Furthermore, the matrix, glue-like state of the vitreous gel acts as a barrier to cell invasion: it inhibits cell proliferation,

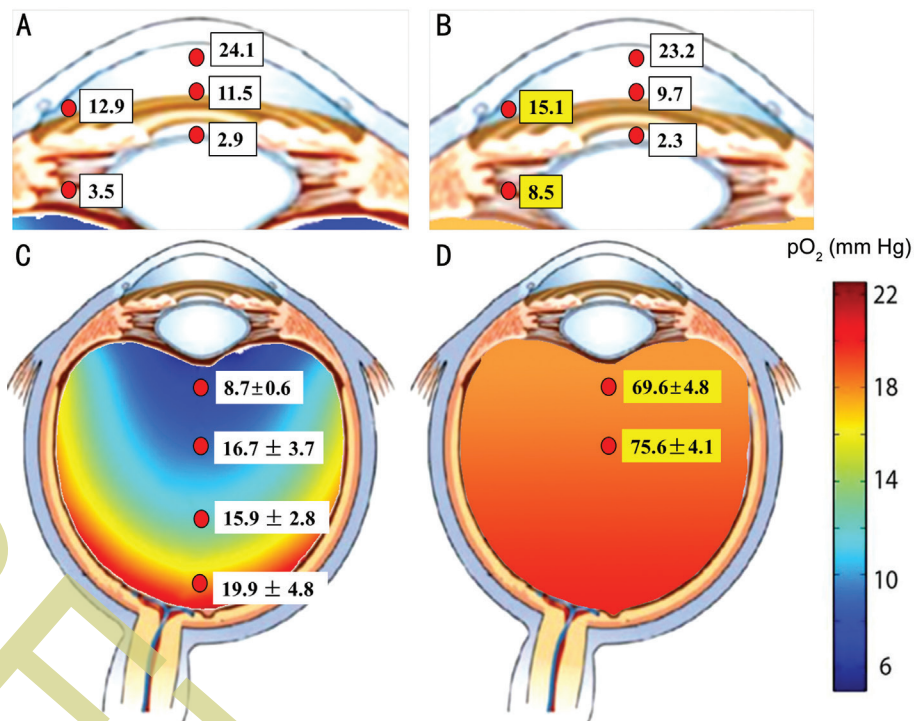
inflammatory responses and neovascularization. These actions may be related to the vital function of intraocular oxygen distribution and metabolism<sup>[14]</sup>.

## VITREOUS OXYGEN METABOLISM

It was suggested previously that the main metabolites in vitreous gel are glucose and lactic acid. The vitreous gel is also important for the regulation and distribution of oxygen. Vitreous oxygen is derived from retinal, choroidal, and iris vessels. Studies have shown that there is a gradient oxygen tension in the vitreous gel, which plays an important role in the protection of the lens and trabecular network from oxidative stress<sup>[14]</sup>. The oxygen distribution in human intraocular fluids has been reported as follows: oxygen levels are highest near the retinal and iris vessels and the corneal posterior surface; the oxygen levels of the aqueous humor decrease closer to the pars plicata of the ciliary body and the trabecular meshwork; and they generally decrease closer to the lens<sup>[15]</sup>. The rich retinal blood circulation increases the oxygen tension near the retina, so that the tension there is higher than the central vitreous oxygen tension. The preretinal oxygen tension of the detached retina is much higher (around 30.0±4.8 mm Hg). Human retinal vasculature aids in perfusing the detached retina with relatively high levels of oxygen<sup>[16]</sup>. Eyes without previous cataract surgery or vitrectomy exhibit a gradient oxygen tension in the aqueous humor. This is because oxygen consumption by the posterior lens is high (0.2-0.4 mL/h), with high oxygen permeability of the posterior capsule, and oxygen tension in the posterior chamber closely correlates with that in the trabecular meshwork<sup>[17]</sup>. For example, oxygen in the anterior chamber derives from the cornea and the vessels of the ciliary body, diffuses from the retinal vessels through the vitreous, and is consumed by the ciliary epithelium and lens<sup>[15]</sup>. The oxygen distribution in the human eye before and after vitrectomy is shown in Figure 1.

The excessive oxygen stress has been suggested to promote nuclear cataract formation<sup>[17]</sup>. In addition to oxygen, all molecules, for instance, vascular epithelial growth factor (VEGF), are transported relatively slowly through the viscous vitreous humor from the retinal vessels in the intact eye<sup>[18]</sup>.

The unique oxygen concentration gradient in vitreous gel results from the oxygen supply and oxygen-consumption rate balance in different parts of the vitreous gel. The maintenance of vitreous oxygen tension is mainly related to the oxygen consumption of vitreous ascorbate (vitamin C). In intact vitreous gel, the average vitamin C content is close to 2 mmol/L<sup>[19]</sup>, whereas in the blood it is approximately 50-60 pmol/L. In addition to the high oxygen demand and rich blood circulation of the retina, active vitamin C transporters of the retina and ciliary body pigment epithelium actively transport vitamin C by a temperature-sensitive and energy-dependent kinetic



**Figure 1 Oxygen distribution in the human eye before and after vitrectomy** A: Oxygen distribution in the anterior segment of the human eye with an intact vitreous body; B: Oxygen distribution in the anterior segment after vitrectomy; C: Oxygen distribution in the posterior segment of the human eye with intact vitreous body; D: Oxygen distribution in the posterior segment after vitrectomy.

mechanism, so the normal vitreous has a high amount of vitamin C and low vitreous oxygen tension<sup>[20]</sup>. The retina has the ability to regulate its own blood flow, and this self-regulation is largely controlled by retinal chemical conditions, especially oxygen tension. The variation in vitreous oxygen tension is closely related to intraocular diseases<sup>[21]</sup>.

### LIQUEFACTION, THE AGE-RELATED VITREOUS DEGENERATION

Vitreous gel is a homogeneous jelly inside infant eyes. The vitreous body condenses and degrades in a slow process, and collagenous condensation and liquefied cavities gradually form<sup>[8]</sup>. Vitreous gel liquefaction might be the initial factor in many vitreoretinal diseases. However, its pathogenesis is not well understood.

Aging vitreous collagen fibrils degrade, which may underlie vitreous liquefaction and the ensuing posterior vitreous detachment (PVD). Changes, with aging, in the collagen fibrils on the vitreous surface include a loss of type IX collagen and a fourfold increase in the exposure of type II collagen; these changes predispose the vitreous collagen fibrils to fusion, fusion and weakening of the vitreoretinal adhesion<sup>[22]</sup>. In PVD, the cortical vitreous pulls away from the retina. This can result in the formation of retinal tears, epiretinal membranes, and macular holes and the development of RRD, vitreomacular traction syndrome, and macular edema. Although vitreous liquefaction plays a major role in many vitreoretinal diseases, little is known about its pathogenesis. Advanced glycation

end products, proteoglycan, hyaluronic acid, and other macromolecules, gradually liquefy the vitreous, destroying the balance of oxygen distribution and disturbing the regulation of oxygen.

Vitreous-matrix status is also affected by the ascorbate content. The concentration of ascorbate in the aqueous vitreous of individuals with PVD is decreased, compared with that in vitreous in the gel state, and the oxygen consumption of the vitreous also decreases, indirectly increasing the oxygen tension of the vitreous. That can cause oxygen stress, but may be beneficial against ischemic retinal diseases<sup>[23]</sup>. The movement of oxygen in the vitreous gel is regulated by several mechanisms, including diffusion, convection, hydrostatic pressure, osmotic pressure, and active transport. After vitreous liquefaction or vitrectomy, the viscosity of the vitreous gel essentially disappears. Increased convection in aqueous vitreous bodies facilitates the diffusion of oxygen and other substances, including the transport of oxygen and nutrients<sup>[24]</sup>. The oxygen tension in the liquefied vitreous increases that in the whole vitreous because there is no diffusion barrier to oxygen in the inner retinal layer<sup>[25]</sup>.

Unlike PVD, incomplete PVD is a risk factor for many retinal diseases, including sight-threatening diabetic retinopathy<sup>[26]</sup>, because the attachment and traction of the vitreous cortex to the macula can induce chronic low-grade inflammation, which may also develop into wet age-related macular degeneration (AMD). The adherent posterior vitreous interferes with

oxygenation and nutrition of the macula and binds VEGF to the collagen fibers at the retinal vitreous interface, resulting in exacerbation of the retinal exposure to these cytokines, and promoting the formation of neovascularization. Inducing complete PVD might protect against wet AMD<sup>[27]</sup>. In a previous study, oxygen tension in the central part of the vitreous was 46% lower in diabetic retinopathy patients than in healthy controls, whereas oxygen tension anterior to the retina was 37% higher. The preretinal oxygen level was closely related to the vitreous VEGF concentration; for instance, retinal hypoxia or chronic inflammatory stimulus could increase the vitreous VEGF concentration in proliferative diabetic retinopathy (PDR)<sup>[28]</sup>. The concentrations of both VEGF and hypoxia-inducible factor-1 $\alpha$  (HIF-1 $\alpha$ ) are increased in the vitreous body in PDR and closely correlate with disease activity<sup>[29]</sup>. Substantial evidence suggests that VEGF plays a key role in the pathogenesis of neovascularization<sup>[30-31]</sup>, which is the primary cause of vision loss in PDR<sup>[32-33]</sup>. Neovascularization is the formation of new microvascular networks from existing blood vessels<sup>[34]</sup>, and is characterized by vasodilation, microvascular leakage, and abnormal proliferation of vascular endothelial cells. Gao *et al*<sup>[35]</sup> found that vitreous carbonic anhydrase increased in diabetic macular edema, caused a pH shift, and led to retinal vascular leakage. Successful vitrectomy for PDR stabilizes the oxygen levels, maintains the balance of oxygenation, and inhibits neovascularization<sup>[36]</sup>.

#### TRENDS IN VITREORETINAL PROCEDURES FOR RRD

RRD is a common, potentially blinding eye disease, caused by vitreous liquefaction and retinal tears<sup>[1]</sup>. Historically, SB surgery was the operation chosen as the treatment for RRD. Over the past decade, the PPV technique has developed rapidly and advanced in numerous ways. Studies of United States Medicare Part B Fee-for-Service data have shown that vitreoretinal procedures increased six-fold from 2000 to 2014; vitrectomy use for RRD increased from 13 814 to 19 288 surgeries, whereas SB sharply declined from 6502 to 1260 procedures. The percentages of different types of operations for retinal detachment repair were 83% vitrectomy, 5% SB and 12% pneumatic retinopexy in 2014<sup>[37]</sup>. A study analyzed data between 1997 and 2007, and found that vitrectomies for RRD increased 72%, and the quantity of intravitreal injections was more than doubling every year, whereas SBs performed without vitrectomy decreased 69% across the 10-year interval<sup>[38]</sup>. During 2003-2016, PPV became the most common operation, whereas the proportion of SB was only 10%, or less<sup>[39]</sup>. PPV was more common (49%) than SB (11%), especially in the pseudophakic patients and patients with vitreous hemorrhage<sup>[40]</sup>. Vitreous surgery is considered by American retinal surgeons to be the first choice for treatment of RRD<sup>[39]</sup>. A study in South Korea reported that no obvious

trend was observed in the surgical approaches from 2007 to 2011<sup>[41]</sup>. These results suggest that vitrectomy and intravitreal injection have been considered the mainstay of therapy instead of SB. Therefore, one could ask whether SB surgery has been replaced by vitrectomy. At least, the possible replacement of SB surgery by vitreous surgery is now a relevant question.

The main reasons why surgeons are reluctant to perform SB surgery are that the operative techniques are difficult to learn and indirect ophthalmoscopy is not easy to master. To solve such problems, novel techniques for SB have been developed, including sutureless buckling and suprachoroidal buckling, reshaping the silicone segment, modified needle drainage, laser choroidotomy, infusion-assisted drainage<sup>[42]</sup>, and chandelier-assistance SB<sup>[5]</sup>. These new techniques make the learning process easier and safer. No matter how exquisite the PPV surgical skill is, PPV will inevitably lead to damage in the vitreous structure and the intraocular environment. Therefore, we advocate that the ophthalmologists enhance their knowledge of SB surgery.

The surgeons should select the proper surgery for RRD based on the patient status. PPV was more likely to be performed on older patients, or those with pseudophakia and vitreous hemorrhage; young patients tended to undergo SB<sup>[39-41]</sup>. In older patients and those with pseudophakia and vitreous hemorrhage, RRD is usually caused by retinal tears, vitreoretinal traction induced by PVD, and extensive vitreous liquefaction. Vitreoretinal traction and extensive liquefaction reduce the reattachment rate of SB. In young patients without obvious PVD or extensive vitreous liquefaction, RRD is characterized by small atrophic holes, shallow detachment, and slow progression, which can usually be cured with SB alone. SB remains the first-choice surgical procedure in young phakic patients, as it retains the vitreous body intact and does not interfere with intraocular metabolism<sup>[43]</sup>. Therefore, SB still has its unquestionable indications, such as in young patients, or patients with an old retinal detachment or inferior retinal detachment caused by an atrophic hole.

#### COMPARISON OF OUTCOMES BETWEEN VITRECTOMY AND SB SURGERY

Studies have shown no significant differences in the achievement ratio of operation between PPV, SB and the combined surgery, with primary anatomical success rates of 89.0%, 87.0% and 85.7%, and final anatomical success rates at 6mo of 98.1%, 100% and 99.4%, respectively<sup>[1]</sup>. Another study, focused on pneumatic retinopexy performed for RRD at six academic centers in the United States, found that the single-procedure anatomic success rate was 66.8%<sup>[44]</sup>.

The relative efficacy of PPV and SB surgeries remains controversial, and there may be no differences in primary success rates, visual acuity improvement, final anatomical

reattachment, and incidence rates of repeated retinal detachment between PPV and SB in treating primary RRD. In terms of complications, a previous study found that cataract progression and iatrogenic tears were more common after PPV, whereas choroidal detachment was more common after SB<sup>[45]</sup>. The rate of cataract occurrence in young patients after PPV is as high as 60% and is closely related to intraocular gas<sup>[46]</sup>. The single-surgery anatomic success rates of SB and PPV/SB have been found to be higher than that of PPV, and SB has been shown to have better visual outcomes than PPV or PPV/SB, even after cataract extraction<sup>[47]</sup>. The largest randomized clinical trial showed that the mean best-corrected visual acuity (BCVA) change was significantly greater after SB of phakic patients, and the difference in re-detachment rates of SB and PPV in the phakic patients was not statistically significant<sup>[48]</sup>. The refractive error induced by the vitreous-gel substitutes causes the vision decline temporarily. For example, the refractive state of the eyes with silicone oil injection is a hyperopic shift of +4.0 to 7.0 D<sup>[49]</sup>. SB induces only a small refractive error and is beneficial to visual rehabilitation in the early postoperative period<sup>[50]</sup>. Thus, although the anatomic success rates of PPV and SB are similar, SB is superior to PPV for RRD in many respects, including early recovery of visual acuity and prevention of cataract progression<sup>[43]</sup>.

Proliferative vitreoretinopathy (PVR) occurs in 5%-10% of RRD cases and is the leading cause of surgical failure<sup>[51-52]</sup>. The frequency of PVR after PPV and SB is similar<sup>[45,53]</sup>. PVR is initiated by fibroblasts derived from RPE cells that are transformed into mesenchymal cells and begin the deposition of collagen and the extracellular matrix, arranged by disordered inflammatory chemokines and growth factors that induce excessive inflammation in the positions of retinal tears and detachment<sup>[51,54]</sup>.

A systematic and comprehensive review of the literature from 1980 to the present found that the development of PVR is closely associated with pre-existing PVR, extensive retinal detachment, vitreous hemorrhage, huge retinal breaks, pseudophakia, and surgical factors<sup>[55]</sup>. Hooymans *et al*<sup>[52]</sup> reviewed the rate of postoperative PVR of 186 consecutive patients with primary RRD repaired with SB combined with cryotherapy, and found that in 6% of the eyes with PVR, the PVR had presented preoperatively, and that pseudophakia may also be a risk factor. Therefore, careful preoperative physical examination and timely diagnosis of pre-existing PVR are effective ways to prevent PVR. Some studies have found several predictive biomarkers for determining the probability of PVR, which might be beneficial in choosing suitable operation techniques<sup>[51]</sup>.

Surgical factors include extensive laser retinopexy and cryopexy, unclosed retinal tears, scleral perforation, and vitreous

hemorrhage in the perioperative period<sup>[55]</sup>. Cryotherapy causes chorioretinal trauma, leads to alterations in the protein matrix, and results in the release of RPE cells throughout the ocular fluid<sup>[56-57]</sup>. Imprecise cryotherapy can result in increased risk of PVR<sup>[58]</sup>. Location of the break with a cryoprobe, adjuvant photocoagulation, and drainage of the subretinal fluids (SRF) followed by cryopexy ensures precise retinopexy and less release of RPE<sup>[42]</sup>.

Nevertheless, SB surgery can cause several complications during the discharge of fluid from the suprachoroidal cavity. The traditional SRF drainage through the incision may cause incomplete drainage, dry tap, choroidal hemorrhage, retinal incarceration, and retinal tears. Sudden hypotony due to copious drainage can cause choroidal detachment<sup>[42]</sup>.

To prevent such problems, novel techniques for SB have been introduced. First, the modified needle drainage is performed through a sclera puncture with a 26-gauge needle, which provides adequate drainage with a much lower complication rate (15%) than the traditional method (32.5%)<sup>[59]</sup>. In addition, an endolaser probe was applied to perform the choroidotomy after scleral cut-down in order to hemostasis by coagulating the choroidal vessels and prevent iatrogenic retinal break. Laser choroidotomy reduces the incidence of retinal perforation and bleeding at the time of drainage<sup>[60-61]</sup>. Infusion-assisted drainage can be placed to combat sudden hypotony due to copious drainage and to maintain intraocular pressure during drainage<sup>[42]</sup>.

Lincoff *et al*<sup>[62]</sup> discussed the advantages of cryotherapy and highlighted benefits of non-drainage of SRF, which remains relevant in RRD repair today. The operation includes three main procedures: occluding retinal hiatus by cryotherapy, placing a silicone sponge for each retinal break, and non-drainage of SRF. Minimal segmental buckling without drainage is an effective technique for repair of RRD with a single break or a few breaks within a few clock hours, and may result in less postoperative pain<sup>[63]</sup>. This technique of SB surgery simplifies the operative procedures, reduces the operation difficulty, shortens the operation time, and decreases the surgical trauma<sup>[64]</sup>.

Although, for those more complicated RRD cases, such as huge retinal tears, multiple breaks, PDR and PVR, PPV are much safer and more effective. However, SB remains a relevant surgery for the right cases, with better results and fewer complications.

### COMPLICATIONS AND VITREOUS METABOLIC DISTURBANCES OF PPV

PPV removes of all the natural vitreous resulting in metabolic disturbance of the vitreous, which leads to a high risk of complications<sup>[14,22]</sup>. Some adverse events appear to be more common in association with PPV than with SB, such as

cataract (46%), preretinal fibrosis (33%), recurrent traction retinal detachments (15%), oil migration to the anterior chamber (12%), corneal edema (12%), oil emulsification (9%)<sup>[3]</sup>, and new iatrogenic breaks (5.42%)<sup>[45]</sup>, whereas choroidal detachment was more commonly seen in SB than PPV<sup>[45]</sup>. Although there are many reasons for these complications, disturbance of oxygen metabolism in the natural vitreous may be one of the important factors.

The incidence of cataract, glaucoma or retinal disease is elevated after PPV, which may be related to vitreous oxygen distribution in patients. A clinical study compared the preoperative and postoperative vitreous oxygen tension: in eyes at baseline, the vitreous oxygen tension was low adjacent to the lens (8.7±0.6 mm Hg) and in the middle vitreous (7.1±0.5 mm Hg), immediately after vitrectomy, oxygen tension became higher adjacent to the lens (69.6±4.8 mm Hg) and in the middle vitreous (75.6±4.1 mm Hg). Thus, vitrectomy increases intraocular oxygen level significantly, by 7-8 times, and the oxygen tension was still maintained at a high level 2y later<sup>[65]</sup>. In a group of RRD patients after PPV, 56.5% had an increase in intraocular pressure (IOP) during the follow-up period<sup>[66]</sup>. The risk of open angle glaucoma increases after PPV, which is associated with increased oxygen stress potentially damaging trabecular-meshwork cells<sup>[15]</sup> (Figure 1).

The mechanism by which surgical excision of vitreous gel can increase oxygen tension is as follows. First, the concentration of ascorbate is reduced in a sodium-free medium after PPV, and the oxygen consumption of the vitreous also decreases, which indirectly increases the oxygen tension of the vitreous<sup>[19-21,23]</sup>. Second, after vitrectomy, the viscosity of the vitreous gel essentially disappears. Increased convection in an aqueous vitreous body facilitates the diffusion of oxygen and other substances, including the transport of oxygen and nutrients<sup>[24]</sup>. In vitrectomized eyes, VEGF production decreases due to increased oxygen diffusion, and the clearance of VEGF is faster. These two mechanisms combined inhibit retinal neovascularization and macular edema<sup>[18]</sup>. The oxygen tension in the liquefied vitreous increases uniformly because there is no diffusion barrier of oxygen in the inner retinal layer<sup>[25]</sup>.

Vitreous is non-renewable, and therefore vitreous replacements must be used after a PPV for RRD. Gases, silicone oil, heavy silicone oil and hydrogels, of which the gases and silicone oil are widely used clinically as vitreous substitutes. However, none of the current substitutes can completely replace the natural vitreous, as the substitutes lack the structure and function of the natural vitreous gel, so complications often occur<sup>[67]</sup>. A multicenter study between 2002 and 2016 found that the single-procedure anatomic success rate with pneumatic retinopexy was 66.8%, while the incidence of cataract was significantly increased<sup>[44]</sup>. Intraocular silicone

oil is associated with many complications, such as temporary high IOP, inflammation, cataract, emulsification, glaucoma, ocular hypotension, keratopathy and PVR<sup>[68]</sup>. There is often unexplained atrophy of the optic nerve after silicone-oil filling<sup>[69]</sup>. Silicone oil, as a foreign substance, was shown to aggravate chronic inflammation in eyes with chronic uveitis and phthisis bulbi that were enucleated from patients after vitrectomy with silicone-oil tamponade<sup>[70]</sup>.

#### COMPLICATIONS AND VITREOUS METABOLIC DISTURBANCES WITH LASER VAPORIZATION AND INTRAVITREAL DRUG INJECTION

In addition to vitrectomy, vitreous interventions include laser photocoagulation and intravitreal injections. Neodymium-doped yttrium aluminum garnet high-energy pulsed-laser ablation (Nd:YAG laser vitreolysis) has recently been applied to relieve vitreous floaters, whose prevalence may increase with a dramatically increased incidence of myopia<sup>[71]</sup>. In 1987, Hrisomalos *et al*<sup>[72]</sup> first reported Nd:YAG laser vaporization on six patients with floaters and transection of bands. Nd:YAG laser disrupts tissues through the formation of ionized gas that causes a shock wave to relieve vitreous floaters but may damage the adjacent lens and retina<sup>[73]</sup>. There has not been sufficient evidence to prove that Nd:YAG laser vitreolysis is a safe and effective therapy, although the incidence of complications has thus far been low. Moreover, Lim<sup>[74]</sup> suggested that there was only fragmentary evidence to support the visual improvement after Nd:YAG laser vitreolysis. A clinical study on 32 eyes reported that the laser produced significant improvement in near visual function and the visual disturbance rate, but not in distance visual function at 6-month follow-up<sup>[75]</sup>. A sham-controlled, randomized clinical trial found that the BCVA changed by -0.2 letters in the laser group, which was not significantly different from the result in the sham group<sup>[76]</sup>. The resolution of floaters by Nd:YAG laser ranges between 0 and 100%, but for young patients (<30 years old) with floaters, the chances of significant improvement of symptoms are not high<sup>[77]</sup>. A research study on rabbits, focused on the possible hazardous side effects of treating floaters with Nd:YAG laser, suggested that Nd:YAG laser treatment should be restricted to the anterior portion of the vitreous to avoid disturbing the state of the vitreous gel, as laser treatment in the middle and posterior vitreous can increase the protein content, refractive index, and viscosity<sup>[78]</sup>.

Intravitreal injections were the primary driving force for the growth of vitreous interventions<sup>[37]</sup>; the annual number of intravitreal injections has more than doubled since 2000<sup>[38]</sup>. Intravitreal drug injection is the main treatment for many retinal diseases. Repeated injections lead to increased risk of retinal detachment, retinal tear, increased IOP, cataracts, endophthalmitis, RPE atrophy and narrowing of the vascular

diameter<sup>[79]</sup>. There are also some rare complications, identified in recent years, such as RPE tear<sup>[80]</sup>, mycobacterium abscessus scleritis<sup>[81]</sup>, and corneal subepithelial infiltrates that are associated with the intravitreal injection of bevacizumab, because of an immune response to bevacizumab<sup>[82]</sup>. Eight of seventy-one eyes of patients with PDR developed ghost cell glaucoma after they underwent intravitreal injection of ranibizumab<sup>[83]</sup>.

## CONCLUSION

Vitreous gel plays a key role in ocular metabolism and in the pathological mechanisms of ocular disease. It is necessary to pay attention to vitreous metabolic function and conduct vitreous intervention prudently to better maintain the metabolic balance and visual function of the eye. SB surgery remains the preferred therapy in young phakic patients without PVD, particularly in maintaining the integrity of the vitreous gel, thus avoiding the complications of PPV. As we do not fully understand the function of vitreous gel, we should perform vitreous surgical intervention only after careful assessment.

## ACKNOWLEDGEMENTS

**Foundations:** Supported by the China Postdoctoral Science Foundation (No.2017M612214); the Natural Science Foundation of Shandong Province (No.ZR2018BH013).

**Conflicts of Interest:** Zong Y, None; Gao QY, None; Hui YN, None.

## REFERENCES

- Haugstad M, Moosmayer S, Bragadóttir R. Primary rhegmatogenous retinal detachment - surgical methods and anatomical outcome. *Acta Ophthalmol* 2017;95(3):247-251.
- Roca JA, Maia M, da Cruz NFS, Polizelli MU, Chhablani J, Gangakhedkar S, Morales-Cantón V, Lisker A, Guerrero-Naranjo JL, Gallego-Pinazo R, Diaz-Llopis M, Berrocal MH, Lasave A, Sabrosa NA, Rosendi E, Cubero-Parra JM, Alezzandrini A, Arevalo JF, Huaman N, Wu L. Non-contact wide-angled visualization with chandelier-assisted scleral buckling for primary uncomplicated rhegmatogenous retinal detachment. *Graefes Arch Clin Exp Ophthalmol* 2020;258(9):1857-1861.
- Parikh HA, Kalbag NS, Zarbin MA, Bhagat N. Characteristics, demographics, outcomes, and complications of diabetic traction retinal detachments treated with silicone oil tamponade. *Eur J Ophthalmol* 2016;26(5):497-502.
- Savastano A, Weinberg T, Faraldi F, Caporossi T, Rizzo S. Scleral buckling using chandelier and releasable suture: a useful surgical variant. *Retina* 2020.
- Seider MI, Nomides RE, Hahn P, Mruthyunjaya P, Mahmoud TH. Scleral buckling with chandelier illumination. *J Ophthalmic Vis Res* 2016;11(3):304-309.
- Macleod D. Vitreous and vitreoretinal disorders. In: Spalton DJ, Hitchings RA, Hunter PA. *Atlas of Clinical Ophthalmology*. 2nd ed. St Louis, Missouri: Mosby-Year Book; 1994:47-52.
- Donati S, Caprani SM, Airaghi G, Vinciguerra R, Bartalena L, Testa F, Mariotti C, Porta G, Simonelli F, Azzolini C. Vitreous substitutes: the present and the future. *Biomed Res Int* 2014;2014:351804.
- Ponsioen TL, Hooymans JM, Los LI. Remodelling of the human vitreous and vitreoretinal interface—a dynamic process. *Prog Retin Eye Res* 2010;29(6):580-595.
- Theocharis DA, Skandalis SS, Noulas AV, Papageorgakopoulou N, Theocharis AD, Karamanos NK. Hyaluronan and chondroitin sulfate proteoglycans in the supramolecular organization of the mammalian vitreous body. *Connect Tissue Res* 2008;49(3):124-128.
- Bishop PN, Crossman MV, McLeod D, Ayad S. Extraction and characterization of the tissue forms of collagen types II and IX from bovine vitreous. *Biochem J* 1994;299(Pt 2):497-505.
- Bishop PN. Structural macromolecules and supramolecular organisation of the vitreous gel. *Prog Retin Eye Res* 2000;19(3):323-344.
- Bishop PN, Reardon AJ, McLeod D, Ayad S. Identification of alternatively spliced variants of type II procollagen in vitreous. *Biochem Biophys Res Commun* 1994;203(1):289-295.
- Sharif-Kashani P, Hubschman JP, Sassoon D, Kavehpour HP. Rheology of the vitreous gel: effects of macromolecule organization on the viscoelastic properties. *J Biomech* 2011;44(3):419-423.
- Holekamp NM. The vitreous gel: more than meets the eye. *Am J Ophthalmol* 2010;149(1):32-36.
- Siegfried CJ, Shui YB, Holekamp NM, Bai F, Beebe DC. Oxygen distribution in the human eye: relevance to the etiology of open-angle glaucoma after vitrectomy. *Invest Ophthalmol Vis Sci* 2010;51(11):5731-5738.
- Sakaue H, Negi A, Honda Y. Comparative study of vitreous oxygen tension in human and rabbit eyes. *Invest Ophthalmol Vis Sci* 1989;30(9):1933-1937.
- Shui YB, Fu JJ, Garcia C, Dattilo LK, Rajagopal R, McMillan S, Mak G, Holekamp NM, Lewis A, Beebe DC. Oxygen distribution in the rabbit eye and oxygen consumption by the lens. *Invest Ophthalmol Vis Sci* 2006;47(4):1571-1580.
- Stefánsson E. Physiology of vitreous surgery. *Graefes Arch Clin Exp Ophthalmol* 2009;247(2):147-63.
- Ankamah E, Sebag J, Ng E, Nolan JM. Vitreous antioxidants, degeneration, and vitreo-retinopathy: exploring the links. *Antioxidants (Basel)* 2019;9(1):E7.
- Salceda R, Contreras-Cubas C. Ascorbate uptake in normal and diabetic rat retina and retinal pigment epithelium. *Comp Biochem Physiol C Toxicol Pharmacol* 2007;146(1-2):175-179.
- Shui YB, Holekamp NM, Kramer BC, Crowley JR, Wilkins MA, Chu F, Malone PE, Mangers SJ, Hou JH, Siegfried CJ, Beebe DC. The gel state of the vitreous and ascorbate-dependent oxygen consumption: relationship to the etiology of nuclear cataracts. *Arch Ophthalmol* 2009;127(4):475-482.
- Bishop PN, Holmes DF, Kadler KE, McLeod D, Bos KJ. Age-related changes on the surface of vitreous collagen fibrils. *Invest Ophthalmol Vis Sci* 2004;45(4):1041-1046.

- 23 Quiram PA, Leverenz VR, Baker RM, Dang L, Giblin FJ, Trese MT. Microplasmin-induced posterior vitreous detachment affects vitreous oxygen levels. *Retina* 2007;27(8):1090-1096.
- 24 Ung L, Pattamatta U, Carnt N, Wilkinson-Berka JL, Liew G, White AJR. Oxidative stress and reactive oxygen species: a review of their role in ocular disease. *Clin Sci (Lond)* 2017;131(24):2865-2883.
- 25 Blair NP. Ocular oxygen consumption during vitreoperfusion in the cat. *Trans Am Ophthalmol Soc* 2000;98:305-329.
- 26 Gella L, Raman R, Kulothungan V, Sharma T. Prevalence of posterior vitreous detachment in the population with type II diabetes mellitus and its effect on diabetic retinopathy: Sankara Nethralaya Diabetic Retinopathy Epidemiology and Molecular Genetic Study SN-DREAMS report no. 23. *Jpn J Ophthalmol* 2012;56(3):262-267.
- 27 Krebs I, Brannath W, Glittenberg C, Zeiler F, Sebag J, Binder S. Posterior vitreomacular adhesion: a potential risk factor for exudative age-related macular degeneration? *Am J Ophthalmol* 2007;144(5):741-746.
- 28 Lange CAK, Stavrakas P, Luhmann UFO, de Silva DJ, Ali RR, Gregor ZJ, Bainbridge JWB. Intraocular oxygen distribution in advanced proliferative diabetic retinopathy. *Am J Ophthalmol* 2011;152(3):406-412.e3.
- 29 Wang XQ, Wang GB, Wang Y. Intravitreal vascular endothelial growth factor and hypoxia-inducible factor 1 $\alpha$  in patients with proliferative diabetic retinopathy. *Am J Ophthalmol* 2009;148(6):883-889.
- 30 Adamis AP, Shima DT. The role of vascular endothelial growth factor in ocular health and disease. *Retina* 2005;25(2):111-118.
- 31 Binu S, Soumya SJ, Kumar VB, Sudhakaran PR. Poly-ADP-ribosylation of vascular endothelial growth factor and its implications on angiogenesis. *Adv Exp Med Biol* 2012;749:269-278.
- 32 Agarwal P, Jindal A, Saini VK, Jindal S. Advances in diabetic retinopathy. *Indian J Endocrinol Metab* 2014;18(6):772-777.
- 33 Zhang SX, Ma JX. Ocular neovascularization: implication of endogenous angiogenic inhibitors and potential therapy. *Prog Retin Eye Res* 2007;26(1):1-37.
- 34 Keane PA, Sadda SR. Development of anti-VEGF therapies for intraocular use: a guide for clinicians. *J Ophthalmol* 2012;2012:483034.
- 35 Gao BB, Clermont A, Rook S, Fonda SJ, Srinivasan VJ, Wojtkowski M, Fujimoto JG, Avery RL, Arrigg PG, Bursell SE, Aiello LP, Feener EP. Extracellular carbonic anhydrase mediates hemorrhagic retinal and cerebral vascular permeability through prekallikrein activation. *Nat Med* 2007;13(2):181-188.
- 36 Maeda N, Tano Y. Intraocular oxygen tension in eyes with proliferative diabetic retinopathy with and without vitreous. *Graefes Arch Clin Exp Ophthalmol* 1996;234(Suppl 1):S66-S69.
- 37 McLaughlin MD, Hwang JC. Trends in vitreoretinal procedures for medicare beneficiaries, 2000 to 2014. *Ophthalmology* 2017;124(5):667-673.
- 38 Ramulu PY, Do DV, Corcoran KJ, Corcoran SL, Robin AL. Use of retinal procedures in medicare beneficiaries from 1997 to 2007. *Arch Ophthalmol* 2010;128(10):1335-1340.
- 39 Reeves MG, Pershing S, Afshar AR. Choice of primary rhegmatogenous retinal detachment repair method in US commercially insured and medicare advantage patients, 2003-2016. *Am J Ophthalmol* 2018;196:82-90.
- 40 Vail D, Pershing S, Reeves MG, Afshar AR. The relative impact of patient, physician, and geographic factors on variation in primary rhegmatogenous retinal detachment management. *Ophthalmology* 2020;127(1):97-106.
- 41 Park SJ, Cho SC, Choi NK, Park KH, Woo SJ. Age, sex, and time-specific trends in surgical approaches for rhegmatogenous retinal detachment: a nationwide, population-based study using the national claim registry. *Retina* 2017;37(12):2326-2333.
- 42 Shanmugam PM, Ramanjulu R, Mishra KCD, Sagar P. Novel techniques in scleral buckling. *Indian J Ophthalmol* 2018;66(7):909-915.
- 43 Park SW, Lee JJ, Lee JE. Scleral buckling in the management of rhegmatogenous retinal detachment: patient selection and perspectives. *Clin Ophthalmol* 2018;12:1605-1615.
- 44 Emami-Naeini P, Deaneer J, Ali F, Gogte P, Kaplan R, Chen KC, Nudleman E, Grewal DS, Gupta M, Wolfe JD, Klufas M, Yiu G, Academic Vitreoretinal Training Centers Study Group. Pneumatic retinopexy experience and outcomes of vitreoretinal fellows in the United States: a multicenter study. *Ophthalmol Retina* 2019;3(2):140-145.
- 45 Znaor L, Medic A, Binder S, Vucinovic A, Marin Lovric J, Puljak L. Pars Plana vitrectomy versus scleral buckling for repairing simple rhegmatogenous retinal detachments. *Cochrane Database Syst Rev* 2019;3:CD009562.
- 46 Blodi BA, Paluska SA. Cataract after vitrectomy in young patients. *Ophthalmology* 1997;104(7):1092-1095.
- 47 Ryan EH, Ryan CM, Forbes NJ, Yonekawa Y, Wagley S, Mitra RA, Parke DW, Joseph DP, Emerson GG, Shah GK, Blinder KJ, Capone A, Williams GA, Elliott D, Gupta OP, Hsu J, Regillo CD. Primary retinal detachment outcomes study report number 2: phakic retinal detachment outcomes. *Ophthalmology* 2020;127(8):1077-1085.
- 48 Heimann H, Bartz-Schmidt KU, Bornfeld N, Weiss C, Hilgers RD, Foerster MH. Scleral Buckling versus Primary Vitrectomy in Rhegmatogenous Retinal Detachment Study Group. Scleral buckling versus primary vitrectomy in rhegmatogenous retinal detachment: a prospective randomized multicenter clinical study. *Ophthalmology* 2007;114(12):2142-2154.
- 49 Hotta K, Sugitani A. Refractive changes in silicone oil-filled pseudophakic eyes. *Retina* 2005;25(2):167-170.
- 50 Sharma YR, Karunanithi S, Azad RV, Vohra R, Pal N, Singh DV, Chandra P. Functional and anatomic outcome of scleral buckling versus primary vitrectomy in pseudophakic retinal detachment. *Acta Ophthalmol Scand* 2005;83(3):293-297.
- 51 Chaudhary R, Scott RAH, Wallace G, Berry M, Logan A, Blanch RJ. Inflammatory and fibrogenic factors in proliferative vitreoretinopathy development. *Transl Vis Sci Technol* 2020;9(3):23.
- 52 Hooymans JM, De Lavalette VW, Oey AG. Formation of proliferative vitreoretinopathy in primary rhegmatogenous retinal detachment. *Doc Ophthalmol* 2000;100(1):39-42.



- 53 Schaal S, Sherman MP, Barr CC, Kaplan HJ. Primary retinal detachment repair: comparison of 1-year outcomes of four surgical techniques. *Retina* 2011;31(8):1500-1504.
- 54 Baudouin C, Fredj-Reygrobellet D, Brignole F, Nègre F, Lapalus P, Gastaud P. Growth factors in vitreous and subretinal fluid cells from patients with proliferative vitreoretinopathy. *Ophthalmic Res* 1993;25(1):52-59.
- 55 Chaudhary R, Dretzke J, Scott R, Logan A, Blanch R. Clinical and surgical risk factors in the development of proliferative vitreoretinopathy following retinal detachment surgery: a systematic review protocol. *Syst Rev* 2016;5(1):107.
- 56 Bonnet M, Guenoun S. Surgical risk factors for severe postoperative proliferative vitreoretinopathy (PVR) in retinal detachment with grade B PVR. *Graefes Arch Clin Exp Ophthalmol* 1995;233(12):789-791.
- 57 Bonnet M. The development of severe proliferative vitreoretinopathy after retinal detachment surgery. Grade B: a determining risk factor. *Graefes Arch Clin Exp Ophthalmol* 1988;226(3):201-205.
- 58 Kreissig I, Rose D, Jost B. Minimized surgery for retinal detachments with segmental buckling and nondrainage. An 11-year follow-up. *Retina* 1992;12(3):224-231.
- 59 Azad R, Kumar A, Sharma YR, Rajpal. Modified needle drainage. A safe and efficient technique of subretinal fluid drainage in scleral buckling procedure. *Indian J Ophthalmol* 2004;52(3):211-214.
- 60 Bovino JA, Marcus DF, Nelsen PT. Argon laser choroidotomy for drainage of subretinal fluid. *Arch Ophthalmol* 1985;103(3):443-444.
- 61 Challa JK, Hunyor AB, Playfair TJ, Gregory-Roberts J, Lee LR. External argon laser choroidotomy for subretinal fluid drainage. *Aust N Z J Ophthalmol* 1998;26(1):37-40.
- 62 Lincoff H, Kreissig I, Uram D. Minor surgery for the repair of retinal detachment emanating from retinoschisis. *Acta Ophthalmol* 2009;87(3):281-284.
- 63 Kreissig I. View 1: minimal segmental buckling without drainage. *Br J Ophthalmol* 2003;87(6):782-784.
- 64 Jin HY, Zhang Q, Zhao PQ. Minimal *in situ* conjunctival incision for segmental scleral buckling surgery. *Ophthalmic Surg Lasers Imaging Retina* 2014;45(6):574-576.
- 65 Holekamp NM, Shui YB, Beebe DC. Vitrectomy surgery increases oxygen exposure to the lens: a possible mechanism for nuclear cataract formation. *Am J Ophthalmol* 2005;139(2):302-310.
- 66 Antoun J, Azar G, Jabbour E, Kourie HR, Slim E, Schakal A, Jalkh A. Vitreoretinal surgery with silicone oil tamponade in primary uncomplicated rhegmatogenous retinal detachment: clinical outcomes and complications. *Retina* 2016;36(10):1906-1912.
- 67 Gao QY, Fu Y, Hui YN. Vitreous substitutes: challenges and directions. *Int J Ophthalmol* 2015;8(3):437-440.
- 68 Baillif S, Gastaud P. Complications of silicone oil tamponade. *J Fr Ophthalmol* 2014;37(3):259-265.
- 69 Tavares RLP, Nóbrega MJ, Nóbrega FAJ, De Novelli FJ, de Oliveira CAC. Timing and outcomes after silicone oil removal in proliferative vitreoretinopathy: a retrospective clinical series. *Int J Retina Vitreous* 2015;1:2.
- 70 Solov'eva EP, Muslimov SA. Silicone oil tamponade as a risk factor of complications. *Vestn Oftalmol* 2013;129(3):28-31.
- 71 Katsanos A, Tsaldari N, Gorgoli K, Lalos F, Stefanidou M, Asproudis I. Safety and efficacy of YAG laser vitreolysis for the treatment of vitreous floaters: an overview. *Adv Ther* 2020;37(4):1319-1327.
- 72 Hrisomalos NF, Jampol LM, Moriarty BJ, Serjeant G, Acheson R, Goldberg MF. Neodymium-YAG laser vitreolysis in sickle cell retinopathy. *Arch Ophthalmol* 1987;105(8):1087-1091.
- 73 Noristani R, Schultz T, Dick HB. Cataract formation after YAG laser vitreolysis: importance of femtosecond laser anterior capsulotomies in perforated posterior capsules. *Eur J Ophthalmol* 2016;26(6):e149-e151.
- 74 Lim JI. YAG laser vitreolysis-is it as clear as it seems? *JAMA Ophthalmol* 2017;135(9):924-925.
- 75 Souza CE, Lima LH, Nascimento H, Zett C, Belfort R Jr. Objective assessment of YAG laser vitreolysis in patients with symptomatic vitreous floaters. *Int J Retina Vitreous* 2020;6:1.
- 76 Shah CP, Heier JS. YAG laser vitreolysis vs sham YAG vitreolysis for symptomatic vitreous floaters: a randomized clinical trial. *JAMA Ophthalmol* 2017;135(9):918-923.
- 77 Milston R, Madigan MC, Sebag J. Vitreous floaters: Etiology, diagnostics, and management. *Surv Ophthalmol* 2016;61(2):211-227.
- 78 Abdelkawi SA, Abdel-Salam AM, Ghoniem DF, Ghaly SK. Vitreous humor rheology after Nd: YAG laser photo disruption. *Cell Biochem Biophys* 2014;68(2):267-274.
- 79 Iwami H, Kohno T, Yamamoto M, Kaida M, Miki N, Ataka S, Shiraki K. Progression of cataracts following photodynamic therapy combined with intravitreal triamcinolone injection in cases of age-related macular degeneration. *Osaka City Med J* 2011;57(2):49-57.
- 80 Wu PC, Chen YJ, Kuo HK. Retinal pigment epithelial tear after intravitreal triamcinolone acetonide injection for fibrovascular pigment epithelial detachment. *Chang Gung Med J* 2011;34(3):320-325.
- 81 Golen JR, Espana EM, Margo CE. Mycobacterium abscessus scleritis following intravitreal injection of bevacizumab. *JAMA Ophthalmol* 2013;131(10).
- 82 Yamato F, Imai D, Mori K, Yoneya S. Corneal subepithelial infiltrates that developed following intravitreal injection of bevacizumab. *Nippon Ganka Gakkai Zasshi* 2013;117(7):558-560.
- 83 Xu J, Zhao M, Li JP, Liu NP. Ghost cell glaucoma after intravitreal injection of ranibizumab in proliferative diabetic retinopathy. *BMC Ophthalmol* 2020;20(1):149.