

# Efficacy and toxic effect associated with subretinal tissue plasminogen activator injection in treating submacular hemorrhage

Jia-Ning Ren, Jie Peng, Yu Xu, Qi Zhang, Shuang-Shuang Chen, Pei-Quan Zhao

Department of Ophthalmology, Xin Hua Hospital Affiliated to Shanghai Jiao Tong University School of Medicine, Shanghai 200092, China

**Co-first authors:** Jia-Ning Ren and Jie Peng

**Correspondence to:** Pei-Quan Zhao. Department of Ophthalmology, Xin Hua Hospital Affiliated to Shanghai Jiao Tong University School of Medicine, Shanghai 200092, China. zhaopeiquan@126.com

Received: 2020-08-28 Accepted: 2020-12-01

**DOI:10.18240/ijo.2021.07.23**

**Citation:** Ren JN, Peng J, Xu Y, Zhang Q, Chen SS, Zhao PQ. Efficacy and toxic effect associated with subretinal tissue plasminogen activator injection in treating submacular hemorrhage. *Int J Ophthalmol* 2021;14(7):1120-1121

**Dear Editor,**

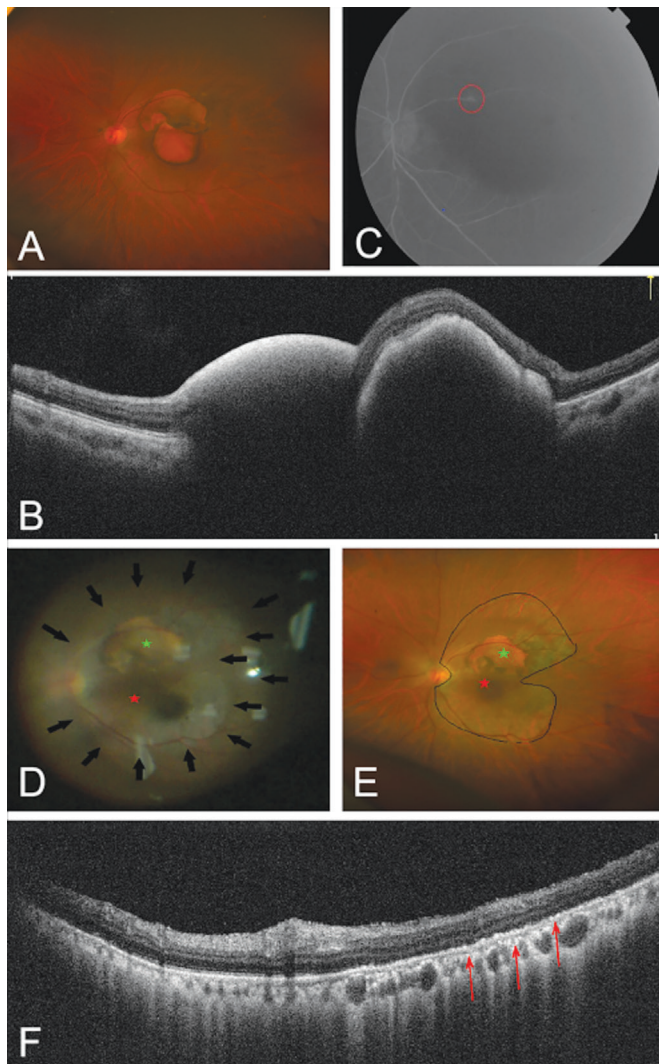
We write to present a case of a successful surgical management of submacular hemorrhage (SMH) by subretinal injection of 40 µg recombinant tissue plasminogen activator (r-tPA), finding a possible toxic effect associated with fundus atrophic changes. This study has been performed in accordance with the Declaration of Helsinki and was approved by the Ethics Committee of Xin Hua Hospital Affiliated to Shanghai Jiao Tong University School of Medicine. Written informed consent was obtained from the patient.

SMH secondary to varieties of chorioretinal degenerative disorders always leads to a poor visual restoration. Early removal of submacular clots has been recommended<sup>[1-2]</sup>. Subretinal injection of r-tPA without removal by retinotomy seems to be a handier operating treatment for SMH combined with pars plana vitrectomy (PPV) and gas tamponade<sup>[2-3]</sup>. Till now, toxic effects associated with r-tPA assisted treatment of SMH were rarely reported clinically. In this report, we describe a surgical management of SMH assisted by r-tPA using 42-gauge needle and relevant possible toxic effect. More experimental studies on concrete mechanisms are expected in the future.

A 73-year-old female with a history of hypertension over 10y developed sudden vision loss in the left eye 32d prior to her first visit. Her systolic blood pressure was controlled at 130 mm Hg by oral antihypertensive medications. Best-corrected visual acuity (BCVA) of her left eye was 20/2000 (Snellen) and intraocular pressure was 8.5 mm Hg. Fundus examinations showed SMH (Figure 1A, 1B). Fluorescence fundus angiography revealed a retinal arterial macroaneurysm (RAM) tiny in size and located in the superiotemporal to the macular (Figure 1C).

After confirmation of the diagnosis of SMH secondary to RAM rupture, standard 3-port 23-gauge PPV with subretinal r-tPA injection under peribulbar anesthesia after informed consent was performed. A totally dose of 40 µg (100 µg/mL) r-tPA (Alteplase for injection, Actilyse, Boehringer Ingelheim) was first injected using a 42-gauge subretinal needle (Medone, Sarasota, USA). The needle was inserted at two points successively on the edge of the clots to form dome-shaped retinal bullas to cover them and held in place for 10s after injection to discourage possible reflux. Phacoemulsification was then performed *via* limbal incisions because of lens opacity. Ten minutes after injection, no obvious clot dissolution was found. Complete fluid-gas exchange followed by C3F8 tamponade were applied. She was asked to maintain an intermittent supine and Fowler' position postoperatively to make a better dissolution and drive the dissolved blood away from the fovea. Two weeks after surgery, secondary intraocular lens (IOL) implantation was performed. By intraoperative fundus exploration, we observed completely dissolution and absorption of the submacular looser clot and significantly reduction of the upper denser clot (Figure 1D). Besides, marked postoperative atrophic fundus changes around the location of the original blood clots (Figure 1E, 1F) was confirmed. The size and shape of the atrophic area seemed to correspond to the bulla formed by injected r-tPA. BCVA three days after IOL implantation was 20/400 at the final visit.

Due to the three mechanisms (iron toxicity, a mechanical barrier and shearing forces) contributing to the poor outcome associated with submacular thick blood clots, removal of the submacular clots as early as possible was recommended.



**Figure 1** Fundus images before, during, and after the first surgery  
A: Color retinography image at first visit showed subretinal thick hemorrhages. The clot consisted of a more solid and denser one in the superior and a looser one in the inferior. B: Optical coherence tomography (OCT) images before surgery showed submacular high reflex masses. C: Fundus fluorescein angiography images revealed a tiny macroaneurysm located in the upper temporal part of the macula (red circle). D: The fundus condition 2wk after the first operation. Dissolution and reduction of the clots is marked by red and green stars. Atrophic changes around the location of the original blood clots are marked by solid black arrows. E: Postoperative ultra-wide field fundus image at last visit showed the upper solid clot dissolved more than 50% (green star) and the submacular one dissolved totally (red star). Atrophic changes could be observed clearly (black line). F: OCT images at last visit showed submacular granular changes of retinal pigment epithelium layer, outer retinal structural failure and upper subretinal residual blood clot.

Despite the long history, our patient still gained apparent functional improvement in visual acuity and restoration of

fundus anatomical structure. Therefore, subretinal injection of r-tPA combined with PPV and gas tamponade could be a potentially valid attempt relative to longstanding SMH. Atrophic fundus change around the location of original blood clots was noteworthy which could be perceived instantly after injection if we look back meticulously. The short half-life of r-tPA (around 5min)<sup>[4]</sup> indicates that the atrophic changes had nothing to do with leaving r-tPA without removal. The mechanisms of atrophic changes are irrelevant to the release of fibrin degradation products due to several aspects: 1) The size and shape of the atrophic area was correspond to the bulla formed by injecting r-tPA; 2) The occurrence of atrophic changes was observed instantly after r-tPA injection. Perhaps overdose of 40  $\mu$ g r-tPA was the chief culprit. Early studies indicated that any suggestion of retinal toxicity may relate to the L-arginine carrier vehicle rather than the enzyme itself<sup>[5]</sup>. In conclusion, subretinal injection of r-tPA can still improve anatomical and functional outcomes for SMH lasting for one month. Subretinal injection of a high dose of 40  $\mu$ g r-tPA may give rise to irreversible damage to retina. The dose of subretinal r-tPA injection should be individualized according to the size and thickness of the SMH, making the optimal dose hard to be conclude.

#### ACKNOWLEDGEMENTS

**Foundation:** Supported by Shanghai Sailing Program (No.20YF1429700).

**Conflicts of Interest:** Ren JN, None; Peng J, None; Xu Y, None; Zhang Q, None; Chen SS, None; Zhao PQ, None.

#### REFERENCES

- 1 Scupola A, Coscas G, Soubrane G, Balestrazzi E. Natural history of macular subretinal hemorrhage in age-related macular degeneration. *Ophthalmologica* 1999;213(2):97-102.
- 2 Novelli FJD, Preti RC, Monteiro MLR, Nóbrega MJ, Takahashi WY. A new method of subretinal injection of tissue plasminogen activator and air in patients with submacular hemorrhage. *Retina* 2017;37(8):1607-1611.
- 3 Ozkaya A, Erdogan G, Tarakcioglu HN. Submacular hemorrhage secondary to age-related macular degeneration managed with vitrectomy, subretinal injection of tissue plasminogen activator, hemorrhage displacement with liquid perfluorocarbon, gas tamponade, and face-down positioning. *Saudi J Ophthalmol* 2018;32(4):269-274.
- 4 Cohen A. Pharmacokinetics of the recombinant thrombolytic agents: what is the clinical significance of their different pharmacokinetic parameters? *BioDrugs* 1999;11(2):115-123.
- 5 Benner JD, Morse LS, Toth CA, Landers MB, Hjelmeland LM. Evaluation of a commercial recombinant tissue-type plasminogen activator preparation in the subretinal space of the cat. *Arch Ophthalmol* 1991;109(12):1731-1736.