

Flapless and transconjunctival double knot technique to repair iridodialysis

Xin Hu¹, Bo Zhao¹, Hai-Ying Jin^{2,3}

¹Department of Ophthalmology, Huaihe Hospital, Henan University, Kaifeng 475000, Henan Province, China

²Department of Ophthalmology, Shanghai East Hospital, Tongji University School of Medicine, Shanghai 200120, China

³Department of Ophthalmology, Tenth People's Hospital Affiliated to Shanghai Tongji University School of Medicine, Shanghai 200072, China

Co-first authors: Xin Hu and Bo Zhao

Correspondence to: Hai-Ying Jin. Department of Ophthalmology, Shanghai East Hospital, Tongji University School of Medicine, 150 Jimo Road, Shanghai 200120, China. jin_haiying@yahoo.com

Received: 2020-12-17 Accepted: 2021-06-11

DOI:10.18240/ijo.2022.03.23

Citation: Hu X, Zhao B, Jin HY. Flapless and transconjunctival double knot technique to repair iridodialysis. *Int J Ophthalmol* 2022;15(3):518-519

Dear Editors,

I am Dr. Hai-Ying Jin from Department of Ophthalmology, Shanghai East Hospital Affiliated to Tongji University School of Medicine, Shanghai, China. We write to present a flapless technique for iridodialysis repair that does not require conjunctival dissection. This study was approved by the Institutional Review Board of the Shanghai Tenth People's Hospital. Written informed consent was obtained from all patients.

The surgery was performed by the same surgeon (Jin HY) under retrobulbar anesthesia. Figure 1 and Supplemental Video 1 demonstrate the procedures. A 30-gauge needle was bent at its hub and was entered into the anterior chamber from the paracentesis opposite to area of iridodialysis. The needle was passed through the peripheral part of the iris and then further passed through the scleral wall at the level of the iris insertion. It was finally punctured out of the eye 1.5 to 2.0 mm behind the limbus transconjunctivally. A 10-0 double armed polypropylene suture (Prolene, Johnson & Johnson, New Jersey, USA) was cut at its middle. The end of one half

of the suture was inserted into the needle at a length of 3.0 to 4.0 mm. The other side with a curved needle was left outside the eye. The 30-gauge needle along with the suture was then recoiled into the eye. The *ab interno* penetrating procedure was repeated through a different spot, approximately 1.0 to 2.0 mm from the first one. This procedure can also be performed by *ab externo* approach using two needles described in our previously published method^[1]. When the tip of the 30-gauge needle was passed outside of the eye again, the end of the thread was pulled out with forceps. The peripheral iris was thus captured by the suture loop. The exterior curved needle connected to the suture was performed with an intrascleral pass from the first fixation site to the second one, parallel to the limbus. The tip of the needle was pulled out transconjunctivally. After adjusting the suture tension, a fixation knot was made in the fixation site to relocate the iris root. A second overhand knot was created 2.0 to 3.0 mm from the first knot. The curved needle connected to the suture was then performed an intrascleral pass from the second fixation site to the adjacent transscleral penetration site. The connected suture was further pulled to lead the second knot along with the suture ends anchored into the needle track. After cutting the exterior part of the suture, all suture ends were buried in the sclera. This technique was applied in five eyes (five patients) with traumatic iridodialysis. The mean age was 55y [\pm standard deviation (SD), 23.6; range, 13 to 69y]. The indications for surgery were the compliments of monocular diplopia and glare due to the iris defect. In all of the five eyes, the areas of iris defect were less than 3 clock hours. In 3 eyes, iridodialysis repair was combined with cataract extraction and intraocular lens implantation. Mean postoperative follow-up period was 12.3 \pm 7.6mo (range from 5 to 23mo). Visual impairment disappeared after surgical repair. No intraoperative or postoperative complications, including suture erosion, abnormal inflammation, hypotony, or retinal detachment occurred.

The techniques or repairing iridodialysis commonly involve suturing/knotting procedures. The exterior sutures and knots are normally covered by lamellar scleral tissue to prevent postoperative erosion and exposure of the suture ends and knot^[2-3]. Various scleral manipulations are available for the coverage, including scleral flap(s), groove(s), and pocket(s).

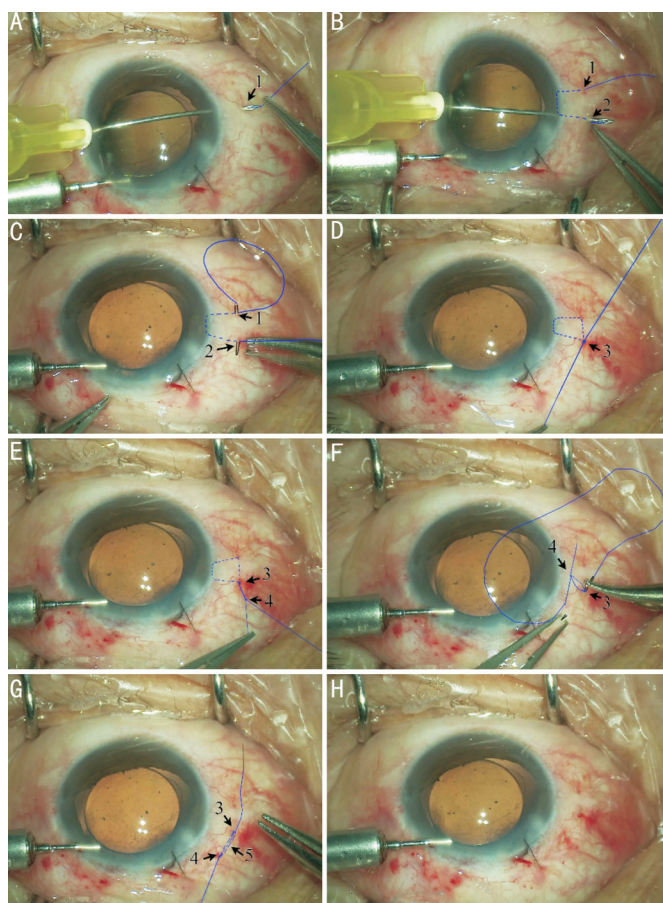


Figure 1 Intraoperative view of the flapless technique to repair iridodialysis A: After *ab interno* penetration of the 30-gauge needle from the eye transconjunctivally, the free end of the suture was inserted into the needle. The other side with a curved needle was placed outside the eye. B: The *ab interno* penetrating procedure is repeated through a second spot, 2.0 to 3.0 mm from the first one. The end of the thread was pulled out from the needle with forceps. C: Pass the curved needle attached to the exterior suture intrasclerally from the first fixation site (arrow 1) to the second one (arrow 2) parallel to the limbus. D: Knotting (arrow 3) the two ends of the suture in the second fixation site. E: Tie another knot (arrow 4) approximately 2.0 to 3.0 mm from the first knot. F: Perform the intrascleral pass of the curved needle from the second fixation site to the adjacent penetration site. G: Lead the second knot and the ends of the suture (arrow 5) entering the scleral tunnel. H: After cutting the ends of the exterior suture ends, all the exterior parts of the fixation suture are buried in the sclera.

Moreover, large conjunctival dissection is usually required^[3-9]. There are mainly three flapless techniques for iridodialysis repair: knotting on the surface of the sclera then rotate the knot into the scleral tissue^[7]; knotless technique using Z-suture^[9];

and riveting with a 6-0 double-flanged polypropylene suture^[10]. Each technique has limitations. Tying the suture loop over the sclera has potential risks of suture erosion and intraocular inflammation. A subconjunctival flange of 6-0 polypropylene suture has potential risks of postoperative erosion and intraocular inflammation. The Z-suture technique for iridodialysis repair requires a larger conjunctival dissection. Our technique avoids the creation of scleral flaps/grooves/pockets and can be performed without the requirement of conjunctival dissection. It provides minimally invasive surgical trauma and reduces the time of operation due to the avoidance of the creation of scleral flaps and conjunctival dissections.

ACKNOWLEDGEMENTS

Foundations: Supported by the Shanghai Municipal Planning Commission of Science and Research Fund (No.2019SY031); Shanghai Science and Technology Innovation Fund (No.20Y11910900); Clinical Research Plan of SHDC (No. SHDC2020CR4081).

Conflicts of Interest: Hu X, None; Zhao B, None; Jin HY, None.

REFERENCES

- 1 Zhang Q, Zhao PQ, Jin HY. Intraocular suture looping and overhand friction knot: a flapless technique to refixate dislocated intraocular lenses. *Retina* 2019;39(Suppl 1):S62-S67.
- 2 McCannel MA. A retrievable suture idea for anterior uveal problems. *Ophthalmic Surg* 1976;7(2):98-103.
- 3 Kervick GN, Johnston SS. Repair of inferior iridodialysis using a partial-thickness scleral flap. *Ophthalmic Surg* 1991;22(6):354-355.
- 4 Zeiter JH, Shin DH, Shi DX. A closed chamber technique for repair of iridodialysis. *Ophthalmic Surg* 1993;24(7):476-480.
- 5 Wachler BB, Krueger RR. Double-armed McCannell suture for repair of traumatic iridodialysis. *Am J Ophthalmol* 1996;122(1):109-110.
- 6 Brown SM. A technique for repair of iridodialysis in children. *J Am Assoc Pediatr Ophthalmol Strabismus* 1998;2(6):380-382.
- 7 Erakgun T, Kaskaloglu M, Kayikcioglu O. A simple closed chamber technique for repair of traumatic iridodialysis in phakic eyes. *Ophthalmic Surg Lasers* 2001;32(1):83-85.
- 8 Bardak Y, Ozerturk Y, Durmus M, Mensiz E, Aytuluner E. Closed chamber iridodialysis repair using a needle with a distal hole. *J Cataract Refract Surg* 2000;26(2):173-176.
- 9 Voykov B. Knotless technique for iridodialysis repair. *Clin Exp Ophthalmol* 2016;44(2):135-136.
- 10 Kusaka M, Miyamoto N, Akimoto M. Repairing iridodialysis by riveting with a double-flanged polypropylene suture. *J Cataract Refract Surg* 2019;45(11):1531-1534.