

# Purtscher-like retinopathy with macular ischemia as the initial presentation of Behcet's disease

Min Ho Shin<sup>1</sup>, Woong Sun Yoo<sup>2</sup>, Ji Sung Jung<sup>2</sup>, In Young Chung<sup>2</sup>

<sup>1</sup>Department of Ophthalmology, Chosun University Hospital, Gwangju 61453, Republic of Korea

<sup>2</sup>Department of Ophthalmology, Gyeongsang National University Hospital, Jinju 52727, Republic of Korea

**Correspondence to:** In Young Chung. Department of Ophthalmology, Gyeongsang National University Hospital, 79 Gangnam-ro, Jinju 52727, Republic of Korea. inyoung@gnu.ac.kr

Received: 2020-05-19 Accepted: 2021-11-06

**DOI:10.18240/ijo.2022.03.24**

**Citation:** Shin MH, Yoo WS, Jung JS, Chung IY. Purtscher-like retinopathy with macular ischemia as the initial presentation of Behcet's disease. *Int J Ophthalmol* 2022;15(3):520-522

## Dear Editor,

We would like to present a case report of Purtscher-like retinopathy (PLR) with macular ischemia as the initial presentation of Behcet's disease (BD).

BD is a multisystem inflammatory illness characterized by oral and mucosal ulcerations, intraocular inflammation, skin lesions, and a variety of other disorders involving almost every organ system in the body<sup>[1]</sup>. Oral ulcers are the most common manifestation, followed by genital ulcers, skin lesions, and articular and ocular involvement<sup>[2]</sup>. Ocular involvement can be present in 20% of BD cases, with higher prevalence in men than in women (24.5% vs 8.6%)<sup>[3]</sup>. Panuveitis associated with retinal vasculitis is the most frequent ocular manifestation in patients with BD-associated uveitis<sup>[1]</sup>. Diagnosis of PLR with macular ischemia without inflammation of the anterior chamber and vitreous body is very challenging. We report a case of BD-associated retinal vasculitis that initially presented as PLR with macular ischemia. We also report the differential diagnosis of PLR with macular ischemia.

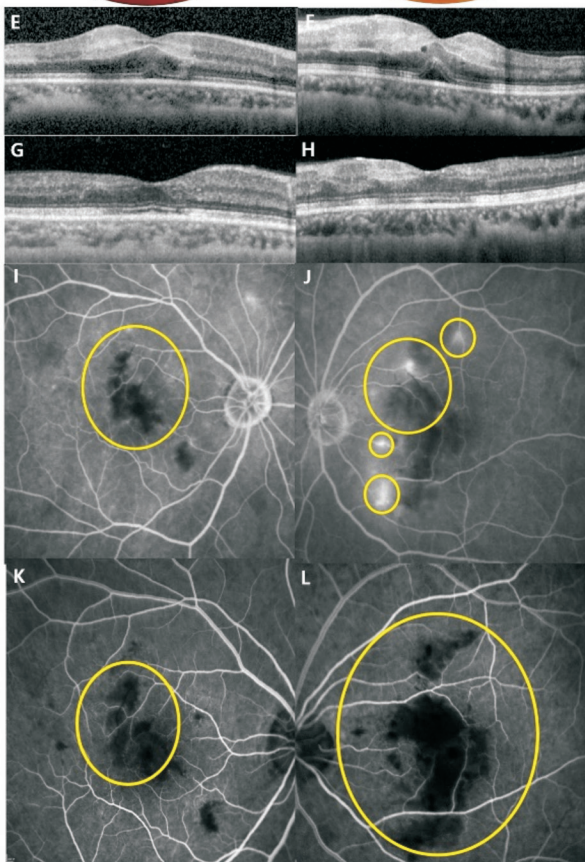
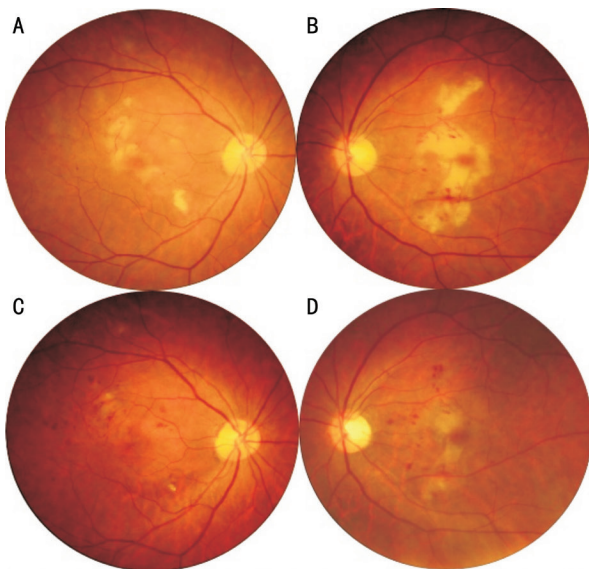
A 51-year-old woman visited an emergency room with blindness of both eyes for 3d. She had a fever since the past 10d. She had no remarkable medical history. Best-corrected visual acuity (BCVA) was counting finger in both eyes. Slit lamp examination showed no inflammation in the anterior chamber and vitreous in both eyes. Fundus photography (FP)

showed bilateral multiple and confluent white-yellowish patches and a few hemorrhages in posterior pole (Figure 1A, 1B). Spectral domain optical coherence tomography (SD-OCT) showed inner retinal thickening, hyperreflectivity of the inner layers and subfoveal fluid bilaterally (Figure 1E, 1F). Fluorescein angiography (FA) showed occluded multiple small branches of macular arterioles in both eyes, with perivascular leakage of some macular arterioles in the late phase in the left eye (Figure 1I, 1J).

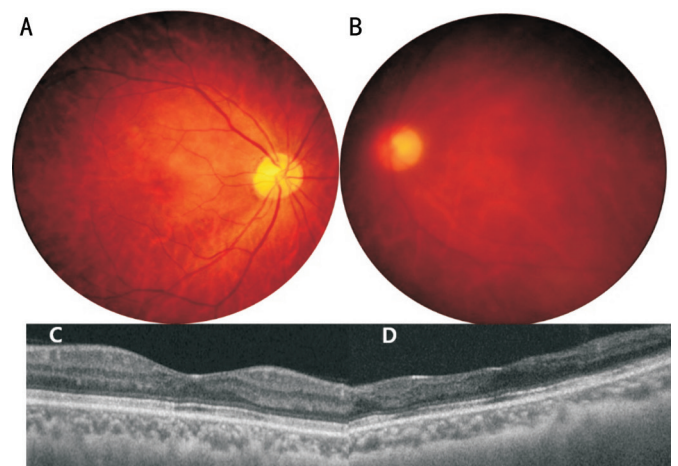
Our first impression was PLR with macular ischemia due to sepsis-related infectious emboli. However, additional tests in collaboration with the rheumatology department showed that the patient also had recurrent oral and genital ulcer, pathergy test positivity and skin folliculitis, nailfold capillary test positivity, human leukocyte antigen-B51 (HLA-B51) positivity, which led to the diagnosis of occlusive retinal vasculitis associated with BD. She was then administered posterior sub-tenon injections of triamcinolone acetonide (TA; 12 mg/0.3 mL) in the left eye.

Simultaneously, she was treated with intravenous high-dose methylprednisolone (1 g/d) for 3d, which was then tapered off to oral prednisolone and azathioprine for 3mo based on her response. She was discharged on oral prednisolone 60 mg for 2wk, which was subsequently tapered to 5 mg every week; azathioprine 25 mg was added 2wk after oral prednisolone treatment, to be tapered down to 2.5 mg every week.

Her BCVA gradually improved to 20/200 in the right eye and 16/200 in the left eye after 3mo of treatment. FP showed decreased white-yellowish ischemic patches and hemorrhages in both eyes (Figure 1C, 1D). OCT showed decreased inner retinal edema, hyperreflectivity of the inner layers and no subfoveal fluid in both eyes (Figure 1G, 1H). FA showed enlarged macular ischemia in both eyes and no perivascular leakage in the left eye (Figure 1K, 1L). One year after treatment, her BCVA was 20/50 in the right eye and 20/800 in the left eye. FP showed decreased white-yellowish ischemic patches and hemorrhages in both eyes. Hazy retina is seen in the left eye due to cataract progression (Figure 2A, 2B). OCT showed disappeared inner retinal edema and subfoveal fluid in the right eye. Inner retinal atrophy is still seen in the left eye (Figure 2C, 2D). Swept source optical coherence tomography



**Figure 1 FP, OCT and FA** A, B: FP at the initial visit shows bilateral multiple and confluent white-yellowish patches and a few hemorrhages; C, D: FP after 3mo shows decreased white-yellowish ischemic patches and hemorrhages in both eyes; E, F: OCT at the initial visit shows inner retinal edema, hyperreflectivity of the inner layers and subfoveal fluid bilaterally; G, H: OCT after 3mo shows decreased inner retinal edema, hyperreflectivity of the inner layers and no subfoveal fluid in both eyes; I, J: FA at the initial visit shows occluded multiple small branches of macular arterioles in both eyes (yellow circle), with perivascular leakage of some macular arterioles in the late phase in the left eye (yellow circle and small yellow circles); K, L: FA after 3mo shows enlarged macular ischemia in both eyes (yellow circle) and no perivascular leakage in the left eye (yellow circle).

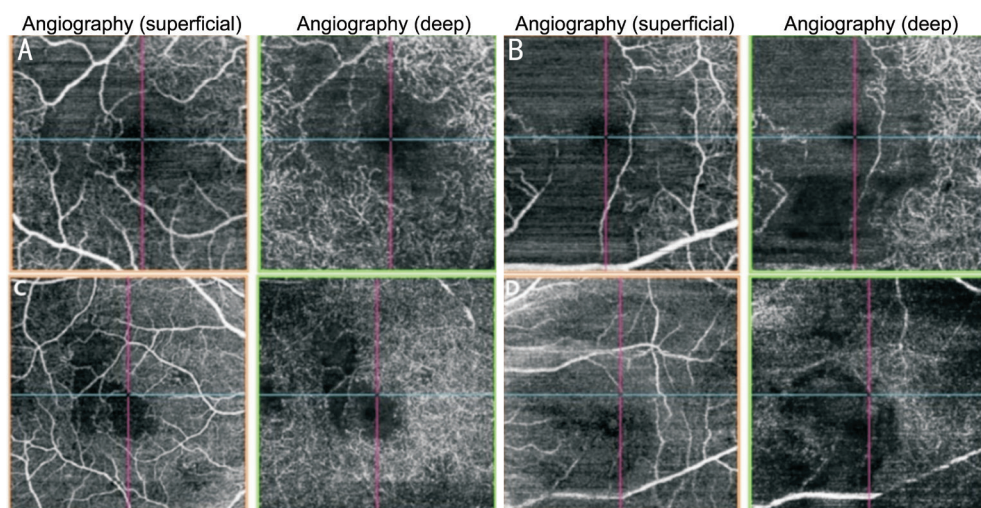


**Figure 2 FP and OCT** A, B: FP after 1y shows decreased white-yellowish ischemic patches and hemorrhages in both eyes. Hazy retina is seen in the left eye due to cataract progression. C, D: OCT 1y later shows disappeared inner retinal edema and subfoveal fluid in the right eye. Inner retinal atrophy is still seen in the left eye.

angiography (SS-OCTA) revealed marked improvement despite persistent foveal ischemia in both eyes (Figure 3).

BD is a multisystem inflammatory disease of unknown etiology, characterized by recurrent attacks of acute severe inflammation involving retinal arteries and veins. The classic finding in ocular BD is recurrent, sterile hypopyon, as described by Behcet. However, it occurs only in 1/3 of all BD cases<sup>[3]</sup>. Vitritis is almost always present during the acute phase of BD. However, our case showed neither inflammation in the anterior chamber nor vitritis. The patient showed unusual ocular findings of BD. In patients suspected with BD with the incomplete form or with an unusual presentation, it is important to consider other forms of uveitis in the differential diagnosis.

The appearance of the retina in this case can be similar to the appearance of viral retinitis with patchy retinal infarction, such as varicella zoster uveitis, Rift Valley fever, and West Nile fever<sup>[3]</sup>. Additionally, the etiologies of retinal vasculitis associated with vascular occlusion can be diverse, including systemic lupus erythematosus, syphilis, multiple sclerosis, intraocular tuberculosis, and ocular BD<sup>[4-7]</sup>. In our case, blood test revealed elevated erythrocyte sedimentation rate and C-reactive protein level, positive HLA-B51, negative antinuclear antibody, and negative venereal disease research laboratory test; hence, we could rule out systemic lupus erythematosus and syphilis. Because of non-specific findings of cerebrospinal fluid tapping and magnetic resonance imaging, we could rule out multiple sclerosis and varicella zoster uveitis. Rift Valley fever and West Nile fever may show fundus findings very similar to those of occlusive retinal vasculitis, but the patient had no history of visiting an endemic area of the viruses; thus, we could rule out these diseases as



**Figure 3 OCTA** A, B: OCTA at the initial visit shows bilateral macular ischemia (more prominent in the left eye); C, D: OCTA 1y later shows obvious improvement of macular ischemia despite persistent foveal ischemia in both eyes.

well. The patient had no symptoms of tuberculosis and chest radiology revealed no tuberculosis-specific lung findings, thus helping us rule out the diagnosis of intraocular tuberculosis.

Purtscher retinopathy (PR) generally occurs as a result of trauma or thoracic compression. A funduscopy picture virtually identical to that of PR may be seen with non-traumatic causes and labeled PLR<sup>[8-9]</sup>. PR is an occlusive microvasculopathy characterized by multiple retinal white areas around the optic nerve head and fovea with paravascular clearing, which may be associated with intraretinal hemorrhages. Purtscher flecken, cotton wool spots, and minimal intraretinal hemorrhage are the typical features. Management of the disease depends on the underlying etiology, and the role of systemic steroids needs further evaluation<sup>[8-9]</sup>.

Recently, corticosteroids and various immunosuppressive agents have been used as the main treatment modalities for BD. Posterior sub-tenon injection of TA, a long-acting corticosteroid, might be a good adjuvant treatment. Delivery of TA from the posterior sub-tenon space to the extracellular choroidal matrix through trans-scleral diffusion could boost the localized concentration of steroids lasting at least for 1mo<sup>[10]</sup>. Although the final visual acuity was relatively poor in this case, FP, OCT, FA, and OCTA showed significant improvement after systemic and local steroid treatment.

Male sex and a younger age at onset are associated with more severe disease<sup>[2]</sup>. In most female cases of BD, visual prognosis is relatively good. However, our case showed that even in women, an unusual and severe ocular complication of BD such as bilateral macular ischemia can result in poor visual outcome.

In conclusion, although the differential diagnosis of BD is challenging, PLR with macular ischemia can present as an initial ocular manifestation of BD and result in poor visual outcome.

#### ACKNOWLEDGEMENTS

**Conflicts of Interest:** Shin MH, None; Yoo WS, None; Jung JS, None; Chung IY, None.

#### REFERENCES

- 1 Arevalo JF, Lasave AF, Al Jindan MY, Al Sabaani NA, AL-Mahmood AM, AL-Zahrani YA, Al Dhibi HA, KKESH Uveitis Survey Study Group; KKESH Uveitis Survey Study Group. Uveitis in Behcet disease in a tertiary center over 25 years: The KKESH Uveitis Survey Study Group. *Am J Ophthalmol* 2015;159:177-184.
- 2 Ishido T, Horita N, Takeuchi M, *et al.* Clinical manifestations of Behçet's disease depending on sex and age: results from Japanese nationwide registration. *Rheumatology* 2017;56(11):1918-1927.
- 3 Mishima S, Masuda K, Izawa Y, *et al.* Behçet's Disease in Japan: Ophthalmologic aspects. *Trans Am Ophthalmol Soc* 1979;77:22.
- 4 El-Asrar AM, Herbot CP, Tabbara KF. A clinical approach to the diagnosis of retinal vasculitis. *Int Ophthalmol* 2010;30(2):149-173.
- 5 Poulaki V, Iliaki E, Mitsiades N, *et al.* Inhibition of Hsp90 attenuates inflammation in endotoxin-induced uveitis. *FASEB J* 2007;21(9):2113-2123.
- 6 Narayanan S, Gopalakrishnan M, Giridhar A, Anthony E. Varicella zoster-related occlusive retinal vasculopathy—A rare presentation. *Ocul Immunol Inflamm* 2016;24(2):227-230.
- 7 Figueras-Roca M, Rey A, Mesquida M, Pelegrín L, Llorens V, Fontenla JR, Adán A. Retinal vasculopathy in systemic lupus erythematosus: a case of lupus vasculitis and a case of non-vasculitis venous occlusion. *Arch Soc Esp Oftalmol* 2014;89(2):66-69.
- 8 Miguel AIM, Henriques F, Azevedo LFR, Loureiro AJR, Maberley DAL. Systematic review of purtscher's and purtscher-like retinopathies. *Eye (Lond)* 2013;27(1):1-13.
- 9 Tripathy K, Patel BC. Purtscher Retinopathy. USA:*StatPearls*; 2020.
- 10 Kovacs K, Wagley S, Quirk MT, *et al.* Pharmacokinetic study of vitreous and serum concentrations of triamcinolone acetonide after posterior sub-tenon's injection. *Am J Ophthalmol* 2012;153(5):939-948.