

Analysis of retinal vasculature changes in indirect traumatic optic neuropathy using optic coherence tomography angiography

Huan Ma, Yang Gao, Jin-Miao Li, Yue-Kun Bao, Cong Nie, Pan Yin, Xi Lyu, Xiao-Yan Ding, Rong Lu

State Key Laboratory of Ophthalmology, Zhongshan Ophthalmic Center, Sun Yat-sen University, Guangzhou 510060, Guangdong Province, China

Co-first authors: Huan Ma and Yang Gao

Correspondence to: Rong Lu. State Key Laboratory of Ophthalmology, Zhongshan Ophthalmic Center, Sun Yat-sen University, 54 Xianlie S. Road, Guangzhou 510060, Guangdong Province, China. lurong@gzzoc.com

Received: 2021-01-17 Accepted: 2021-08-20

Abstract

• **AIM:** To assess the retinal vasculature alterations in indirect traumatic optic neuropathy (ITON) patients following craniofacial trauma by optic coherence tomography angiography (OCTA).

• **METHODS:** Patients diagnosed of monocular ITON were recruited from August 2016 to May 2020. OCTA was performed using the AngioVue OCT-A system for two cube scans centered at the optic nerve head and fovea. OCTA data included thicknesses of peripapillary retinal nerve fiber layer (RNFL) and macular ganglion cell complex (GCC), as well as proportion of capillary perfusion and data were analyzed for correlation with post-injury timepoints: within 7, 8-30, 31-90, and 91-365d.

• **RESULTS:** A total of 73 ITON patients were studied. Significant thinning of RNFL and GCC layers and attenuation of microvascular perfusion were observed in ITON eyes as compared to contralateral unaffected eyes (for most of the analyzed sectors and quadrants, $P < 0.05$). Without respect to surgical intervention and vision recovery, the decrease in retinal layer thicknesses and microvascular perfusion was time-dependent, and most significant within three months ($P < 0.001$).

• **CONCLUSION:** ITON presents with time-dependent thinning of retinal layers and attenuation of microvasculature, indicating possible degeneration of retinal ganglion cells due to reduced retinal blood supply.

• **KEYWORDS:** optic coherence tomography angiography;

indirect traumatic optic neuropathy; macular capillary density; retinal nerve fiber layer thickness; optic nerve head peripapillary vessel density

DOI:10.18240/ijo.2022.08.18

Citation: Ma H, Gao Y, Li JM, Bao YK, Nie C, Yin P, Lyu X, Ding XY, Lu R. Analysis of retinal vasculature changes in indirect traumatic optic neuropathy using optic coherence tomography angiography. *Int J Ophthalmol* 2022;15(8):1344-1351

INTRODUCTION

Indirect traumatic optic neuropathy (ITON) refers to acute visual impairment due to optic nerve injury following remote forces applied to the head or face^[1]. Common causes include vehicle and bicycle accidents, falling, or hits^[2], and ITON occurs in 2% to 5% of facial and 0.5% to 2% of head traumas^[3]. Diagnostic characteristics of ITON include acutely decreased visual acuity (VA), change in color recognition, visual field defects, impaired visual evoked potentials (VEP) and relative afferent pupil defect (RAPD)^[1,4].

External concussive forces transmits shockwave to the optic nerve and causes indirect injuries^[5]. A highly recognizable report by Gross *et al*^[6] reported that the traumatic impact force may result in deformation of the ipsilateral orbital roof near the optic foramen, and such deformation could cause damage to the supporting vasculature and shear stress to the nerve^[6-8]. The subsequent vascular ischemia-induced optic nerve swelling and compression due to optic canal are causes of insufficient blood supply to retinal ganglion cell (RGC) leading to irreversible degeneration of RGC axons at the time of injury or progress within ensuing weeks, and present with optic disc pallor^[1,9-12]. This two-stage hypothesis is the basis for treatment of ITON with optic canal decompression^[13], among others such as steroid treatments and close observation with no interventions^[1,9]. It is important to evaluate the degree of injury for trauma-induced indirect damages to the retina and optic nerve, therefore, it is necessary to adopt an appropriate examination method.

Optical coherence tomography (OCT) was one of the biggest advances in ophthalmic imaging. Based on this technology, optical coherence tomography angiography (OCTA) was established in mid-2000's, offers non-invasive, depth-resolved images to access retinal and choroidal vasculature and layering details^[14-16]. It has been proven to show many important clinical findings in neovascularization, impaired perfusion, macular telangiectasia, and capillary remodeling^[17]. Also, OCTA is currently applied for diagnosing and evaluating a wide variety of ophthalmic conditions, including age-related macular degeneration^[18-19], glaucoma^[20-21] and diabetic retinopathy^[22-23], and some optic neuropathies^[24-25]. The underlying etiology in ITON remains unclear and may be multifactorial, and vascular insufficiency might be a vital causal factor as in other optic neuropathies^[26]. The emergence of OCTA provides the feasibility to explore the pathology and microvascular perfusion with the development of traumatic optic neuropathy. In this study, we have collected OCTA data from serial follow-up from ITON patients and performed in-depth analysis in order to clarify the time-course retinal vessel layer changes in ITON patients.

SUBJECTS AND METHODS

Ethical Approval This is a retrospective observational study. Ethical approval and patient consent were obtained before surgery and the procedures adhered to the tenets of the 1964 Declaration of Helsinki. For patients of age below 18, consent was obtained from their parents or legal guardians. Protocols were approved by the Institutional Ethics Committee (2019KYPJ155, Medical Ethics Committee, Zhongshan Ophthalmic Center, Guangzhou, Guangdong Province, China).
Patients A total of 73 patients who were diagnosed of monocular ITON in Zhongshan Ophthalmic Center (ZOC) from August 2016 to May 2020 were recruited in this study. The inclusion criteria were as follows: 1) diagnosed of ITON; 2) no history of other ophthalmic conditions or ocular surgeries apart from optic canal decompression. Patient details on age, gender, cause of injuries and time of visit after injury were recorded.

All patients had comprehensive systemic and ophthalmic examination. ITON was diagnosed according to patients' traumatic history and ophthalmic examination, including symptoms: 1) a close head injury with no direct force trauma made to the optic nerve; 2) decrease of VA; 3) positive of RAPD; 4) abnormal VEP with normal fundus examination.

Optical Coherence Tomography Angiography All subjects were examined under one OCTA system (AngioVue; Optovue Inc., Fremont, CA, USA), which scanned at speed of 70 000 A-scans per second, and wavelength of 840 nm. For each eye of all patients, 4.5×4.5 mm² cube angio scan was centered at the optic nerve head (ONH), and 3.0×3.0 mm² cube angio scan was centered at the fovea for macular region.

Vessel density was defined as the proportion (in percentage) of perfused vascular area in the whole selected region in en face views. OCTA output data from the 4.5×4.5 mm² ONH scan included readings for vessel densities of whole ONH image (onh-wiVD), inside-disc and peripapillary sectors. The 3.0×3.0 mm² macular scan included readings for vessel densities of whole macular image (m-wiVD), fovea, para-fovea and peri-fovea sectors. OCTA also provided automated measurements of retinal thickness parameters, which included retinal nerve fiber layer (RNFL) at the ONH and a complexed layer (GCC) at the macular B-scans. The latter is the combination of RNFL, RGC, and inner plexiform layers (IPL). Representative images of OCTA performed on both eyes of the same patient was shown in Figure 1. At very early stage of the disease (day 4 from injury), retina thickness and vessel density did not change greatly in the ITON eye as compared to the unaffected fellow eye. After approximately 3mo from injury, retina thickness and vessel density decreased significantly in the ITON eye, suggesting progression of RGC over time.

Statistical Analysis All statistical calculation and analysis were performed with IBM SPSS Statistics 24 software (IBM Corp., Armonk, NY, USA) and GraphPad Prism 8 (GraphPad Software, San Diego CA, USA). Alteration in retinal thickness and vasculature density were calculated as percentage of measurements in ITON eyes as compared to the contralateral unaffected eye. For continuous variables, data were presented as mean±standard deviation (SD) unless otherwise stated; parametric (*t*-tests or ANOVA) or non-parametric tests (Mann-Whitney *U* or Kruskal Wallis) for comparisons between groups (pairwise where appropriate); Pearson's correlation analysis was performed to reveal time-dependent changes in parameters where appropriate. Statistical significance was calculated for two-tail significance and was defined with *P*-value of less than 0.05.

RESULTS

A total of 73 patients diagnosed with monocular ITON were recruited in this study. Patient and clinical information were listed in Table 1.

Thinning of Retinal Layers in Indirect Traumatic Optic Neuropathy Eyes Thickness of RNFL and GCC were compared between ITON eyes and the unaffected fellow eyes (Table 2). Pair-wised statistical analysis revealed that RNFL was significantly thinner in ITON eyes for most of ONH sectors (all *P*<0.05) except for temporal quadrant. Meanwhile, for the macular region and quadrants, thinning of GCC was significant in ITON eyes for all sectors (all *P*<0.05) except the fovea.

Time-dependent correlation analysis on retinal thinning was performed with the inter-eye difference of retinal thickness between ITON and unaffected eyes. Data were acquired at

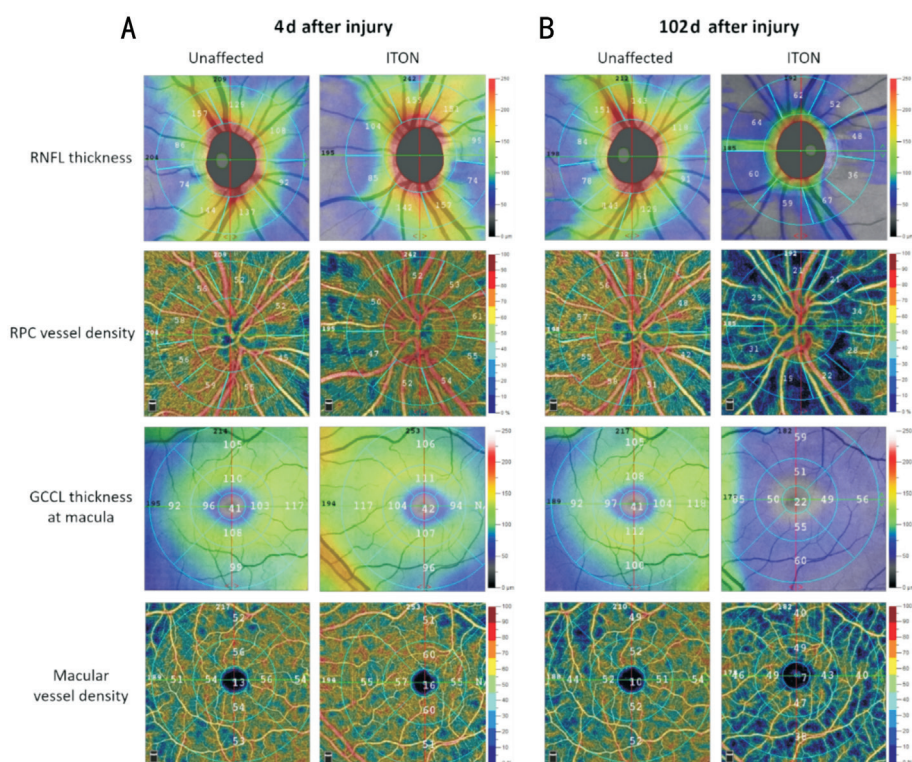


Figure 1 Representative optic coherence tomography angiography (OCTA) Of the same patient (female, 54-year-old), OCTA was performed on 4d (A) and 102d (B) after injury. OCTA data were acquired from: 4.5×4.5 cube scan centered at the optic nerve head, which gave details on thickness of retinal nerve fiber layer (RNFL) and microvascular perfusion of radial papillary capillary (RPC); and 3×3 cube scan centered at the fovea, which provided details on thickness of the macular ganglion cell complex (GCC) and microvascular perfusion of the macula.

different post-injury timepoints, at which the patients were examined with OCTA: within 7d, 8 to 30d, 31 to 90d, and 91 to 365d. Correlation analysis findings revealed that the change in retinal thickness, of both radial papillary capillary (RPC) and macular, were inversely time-dependent, *i.e.*, thinning of retina at the RPC and macular had been worsening with time after injury (all $P < 0.05$; Table 3). It was noteworthy that the thinning of retina was most significant during 31 to 90d and became stabilized after 3mo from injury.

Attenuation of Vessel Density in Indirect Traumatic Optic Neuropathy Eyes Vasculature perfusion in retina was presented as percentage of vessel densities per en face views. Vessel densities of the RPC and the macular for ITON eyes and the unaffected fellow eyes were listed in Table 4. Pair-wise statistical analysis revealed that RPC vessel density was significantly lower in ITON eyes for all RPC regions and quadrants (all $P < 0.05$). Meanwhile, for macular regions and quadrants, vessel density was significantly lower in ITON eyes for whole image, perifovea, superior, inferior and nasal quadrants (all $P < 0.05$).

Again, time-dependent correlation analysis on vessel density attenuation was performed with the inter-eye difference of vessel densities between ITON and unaffected eyes. The findings revealed that the change in vessel densities, of both

RPC and macular, were inversely time-dependent, *i.e.*, vessel density attenuation had been worsening with time after injury (all $P < 0.05$; Table 5). Similar to that of retina thickness, the decrease of vessel density was most significant during 31 to 90d and became stabilized after 3mo from injury.

Correlation of Retinal Thickness and Vessel Density with Severity of Preoperative Vision Recruited patients were categorized according to their preoperative vision: no light perception (NLP), light precepted (LP), hand movement (HM), finger count (FC), VA between 0.01 and 0.08, and VA between 0.1 and 0.3. For each group, time-dependent correlation analysis was performed for retinal layer thinning and vascular alteration. For NLP patients, retina thinning, and vessel density changes were time-dependent for all measured parameters and sectors. For non-NLP patients (*i.e.*, LP, HM, FC, 0.01-0.08, and 0.1-0.3), preserved vision was not associated with time-dependent alteration in retina thickness and vascular attenuation (Table 6).

Associated of Change in Retinal Vasculature with Age, Gender, and Cause of Injury Changes in vessel density and retinal layer thickness were analyzed for correlation with clinical parameters such as patient age, gender, and cause of injuries. For all these parameters, alterations in retinal vasculature parameters were not statistical significantly correlated.

Table 1 Patient and clinical information

| Variables | n=73 (%) |
|-----------------------------------|-----------------------|
| Male/female | 66 (90.4)/7 (9.6) |
| Left/right | 48 (65.8)/25 (34.2) |
| Lag-time (days from injury) | 31.93 (0 to 179) |
| Within 7d | 24 (32.9) |
| 8 to 30d | 25 (34.2) |
| 31 to 90d | 15 (20.5) |
| 91 to 365d | 9 (12.3) |
| Follow-up time (days from injury) | 83.32 (2 to 283) |
| Within 7d | 4 (5.5) |
| 8 to 30d | 17 (23.3) |
| 31 to 90d | 20 (27.4) |
| 91 to 365d | 32 (43.8) |
| Type of injury | |
| Car accident | 42 (57.5) |
| Fall | 20 (27.4) |
| Hit force | 10 (13.7) |
| Others | 1 (1.4) |
| Post-injury VA ^a | |
| NLP | 29 (39.7) |
| LP | 5 (6.8) |
| HM | 4 (5.5) |
| FC | 12 (16.4) |
| 0.01-0.08 | 16 (21.9) |
| 0.1-0.3 | 7 (9.6) |
| Age, y | 26.29±14.10 (5 to 56) |
| Under 18y | 26 (35.6) |
| Above 18y | 47 (64.4) |
| Blood pressures (mm Hg) | |
| Systolic | 121.5±9.1 (92 to 156) |
| Diastolic | 75.1±7.0 (56 to 95) |
| Intraocular pressure (mm Hg) | 14.6±3.7 (7.7 to 32) |

^aPost-injury vision taken before surgery. NLP: No light perception; LP: Light perceived; HM: Hand movement; FC: Finger count; VA: Visual acuity (converted decimal).

DISCUSSION

ITON is the commonest type of optic nerve injury related to orbital trauma. It often causes severe vision loss in patients who suffers from craniofacial trauma, which remotely induces indirect injuries to the optic nerve. With the advancement of neuroimaging in clinical practice, detailed ophthalmic examination are routinely necessitated by the requirement of indication for treatment. In the current study, we are the first to in-depth assess changes of retinal vasculature in ITON patients using the OCTA.

Axon degeneration has been demonstrated in rodent models as reported by several studies^[27]. Thinning of RNFL at the ONH region has shown to be strongly correlated with impaired visual

function and visual field loss in patients with compressive lesions, and suggest that damaging to the anterior pathways may occur before visual field loss^[28-29]. A report showed that a significant thinning of macular GCC (the combination of RGC and IPL) was observed in the outer nasal, superior and inferior field in early traumatic optic neuropathy, which implied that RGC loss may participate in the development of traumatic optic neuropathy^[30]. Hence, visual dysfunction might delay in up to 10% of patients, which is attributed to a deferred clinical diagnosis^[5]. Concordantly, we found significant thinning of macular GCC in all assessed sectors, and all patients presented with decreased VA and impaired visual functions assessed by VEP, suggesting that changes in retinal thickness had already occurred before their first visit to clinic. Yet, an interesting finding from our OCTA result demonstrated a slight increase in RNFL thickness within 7d after injury and followed by significant decrease from 7 to 30d, with observation in funduscopy examination, together suggested that acute edema at the ONH may have occurred immediately after injury and subsiding of RNFL swelling took place in the next few weeks. The OCTA also provides measurement of vessel density, which is evidential to the alteration of blood supply following traumatic impact to the optic nerve. To date, the discussion on vascular changes in optic neuropathies with OCTA has been scarce. Chan *et al*^[31] showed that significant decrease in blood suppl and oxygenation to the retina was associated with choroidal thinning in chronic ITON patients. Although a different OCTA platform was used, our OCTA findings showed apparent attenuation in microvasculature densities at the RPC region of the ONH cube scan, as well as the perifovea sectors at the macular, suggesting possible impaired perfusion to the retina.

It has been suggested by several studies that the retrograde degeneration of post-traumatic retinal vasculature is a time-dependent progress, and takes at least six weeks to complete^[12,28,32]. In concordance, we found that decrease in retinal layer thickness and vasculature were most significant within the first three months after injury. For OCTA examinations taken in follow-up timepoints after three months, alterations in retinal layer thickness and vasculature reached plateau with less progressive worsening.

In our study, when comparing preoperative macula retinal thickness and vessel densities between ITON and the good fellow eyes, GCC thinning was significant in all segments except the fovea, and vessel attenuation was significant in all segments except the fovea and temporal. Traumatic ischemia-induced optic nerve swelling and compression from optic canal are causes of insufficient blood supply in RGC, and degeneration of RGC axons starts from chiasma RNFL at the ONH in the earlier stage of the disease and extends

Table 2 Comparison of retinal thickness between ITON and the unaffected fellow eye (preoperative) mean±SD

| Parameters | ITON eye, μm | Unaffected eye, μm | <i>P</i> | ITON/unaffected ^a , % |
|-----------------------------|--------------|--------------------|----------|----------------------------------|
| Retinal nerve fiber layer | | | | |
| Peripapillary | 103.2±23.39 | 116.2±9.22 | 0.0004 | 91.0±21 |
| Superior | 124.3±34.57 | 140.1±16.70 | 0.0026 | 84.7±26 |
| Inferior | 131.9±33.66 | 149.5±14.88 | 0.0011 | 86.8±24 |
| Nasal | 92.10±22.66 | 99.82±15.9 | 0.0246 | 88.4±23 |
| Temporal | 74.88±29.88 | 80.68±9.26 | 0.2333 | 90.7±41 |
| Ganglion cell complex layer | | | | |
| Whole image | 86.80±21.34 | 99.52±6.071 | 0.0003 | 87.0±21 |
| Fovea | 46.68±18.01 | 56.17±21.11 | 0.1314 | 92.5±37 |
| Parafovea | 92.48±25.45 | 108.7±7.29 | 0.0001 | 84.9±22 |
| Perifovea | 91.49±19.79 | 102.2±6.80 | 0.0008 | 89.5±18 |
| Superior | 92.60±23.22 | 106.7±6.89 | <0.0001 | 84.6±20 |
| Inferior | 95.56±26.12 | 108.3±10.40 | 0.0094 | 89.8±24 |
| Nasal | 98.34±24.01 | 113.3±9.51 | 0.0002 | 86.9±20 |
| Temporal | 83.52±18.03 | 93.19±8.08 | <0.0001 | 87.4±18 |

^aRatio between ITON and fellow eye calculated by (ITON data)/(fellow eye data)×100%. ITON: Indirect traumatic optic neuropathy.

Table 3 Time-dependent change in retina thickness in ITON eyes after injury mean±SD, %

| Parameters | Time after injury | | | | <i>R^a, P</i> |
|-----------------------------|-------------------|---------|---------|---------|-------------------------|
| | ≤7d | 8-30d | 31-90d | 91-365d | |
| Retinal nerve fiber layer | | | | | |
| Peripapillary | 106.2±13 | 84.5±15 | 65.5±14 | 57.6±28 | -0.342, <0.0001 |
| Superior | 97.8±18 | 83.7±18 | 59.3±18 | 44.2±13 | -0.263, 0.0006 |
| Inferior | 100.1±10 | 86.7±15 | 74.6±17 | 65.3±13 | -0.251, 0.0006 |
| Nasal | 98.2±17 | 84.9±18 | 63.6±17 | 46.0±17 | -0.189, 0.0143 |
| Temporal | 107.7±49 | 83.5±20 | 74.8±25 | 67.8±19 | -0.106, 0.1787 |
| Ganglion cell complex layer | | | | | |
| Whole image | 99.5±17 | 83.6±14 | 64.0±9 | 58.5±11 | -0.312, 0.0002 |
| Fovea | 108.3±40 | 85.9±24 | 63.2±15 | 56.2±13 | -0.231, 0.0074 |
| Perifovea | 101.5±14 | 85.9±12 | 69.4±8 | 65.1±10 | -0.322, 0.0001 |
| Superior | 96.7±17 | 83.1±15 | 62.9±9 | 55.9±10 | -0.319, 0.0002 |
| Inferior | 103.3±23 | 86.4±16 | 64.5±10 | 60.0±14 | -0.294, 0.0006 |
| Nasal | 98.6±16 | 81.8±14 | 65.2±10 | 61.3±11 | -0.293, 0.0006 |
| Temporal | 99.3±13 | 84.5±12 | 66.3±9 | 60.4±14 | -0.316, 0.0002 |

Data were calculated as ratio of (ITON/fellow eye)×100%. ^aPearson’s correlation coefficient, calculated against number of days (post-injury). ITON: Indirect traumatic optic neuropathy.

peripherally towards the macula at the temporal over time. Gradual axonal loss and progressive macula GCC thinning in ITON has been reported in some case studies^[33-34], and in our cohort, we anticipated that further RGC axon degeneration progressed and reached the macula. Therefore, although we may not have observed significant GCC thinning or macular vessel attenuation at the fovea in early-stage data, analysis of long-term data demonstrates time-dependent significance in decrease of macular GCC thickness and vasculature density at the fovea.

Moreover, we investigated the association between the alteration in retinal thickness and vasculature and preserved vision

acuity in ITON patients. Some patients had better preserved eyesight at their visit while some had poor vision such as NLP. However, we found that the prognostic association between time-dependent retinal vasculature alteration and the patients’ post-injury eyesight was weak. For patients who had mild vision impairment (VA between 0.1 and 0.3), they usually had delayed hospital visit, *i.e.*, at least 30d after injury, and OCTA findings suggested that they had worse retinal thickness and vessel density. This observation added evidence to that post-injury retinal degeneration was time-dependent, however the immediate effect of injury or the onset of the disease was not often reflected on the patients’ vision loss.

Table 4 Comparison of retinal vessel densities between ITON and the unaffected fellow eye (preoperative) mean±SD, %

| Parameters | ITON eye | Unaffected eye | P | ITON/unaffected ^a |
|-----------------------------------|-------------|----------------|---------|------------------------------|
| Radial papillary capillary | | | | |
| Whole image | 44.42±6.53 | 49.69±2.17 | <0.0001 | 90.1±12 |
| Inside disc | 45.54±5.63 | 49.59±5.37 | <0.0001 | 93.6±12 |
| Peripapillary | 45.23±8.08 | 52.02±2.87 | <0.0001 | 87.7±14 |
| Superior | 45.26±8.52 | 52.26±2.70 | <0.0001 | 87.3±15 |
| Inferior | 45.16±7.97 | 51.74±3.40 | <0.0001 | 88.2±14 |
| Nasal | 42.74±7.26 | 47.60±4.66 | <0.0001 | 90.9±18 |
| Temporal | 48.94±7.95 | 54.75±3.42 | <0.0001 | 90.3±14 |
| Macular vessels | | | | |
| Whole image | 45.09±5.82 | 46.82±3.305 | 0.0176 | 96.5±12 |
| Fovea | 20.76±11.10 | 18.65±6.159 | 0.1278 | 116.7±59 |
| Perifovea | 46.78±5.94 | 49.96±3.013 | <0.0001 | 93.7±11 |
| Superior | 48.59±5.94 | 50.62±3.76 | 0.0090 | 95.4±13 |
| Inferior | 47.95±6.55 | 50.43±4.02 | 0.0049 | 98.4±12 |
| Nasal | 49.28±6.35 | 51.86±3.950 | 0.0029 | 96.3±12 |
| Temporal | 47.59±5.92 | 48.49±3.75 | 0.2314 | 95.4±13 |

^aRatio between ITON and good fellow eye calculated by (ITON data)/(fellow eye data)×100%. ITON: Indirect traumatic optic neuropathy.

Table 5 Time-dependent change in retinal vessel densities in ITON eyes after injury mean±SD, %

| Parameters | Time after injury | | | | R ^a , P |
|-----------------------------------|-------------------|----------|---------|---------|--------------------|
| | ≤7d | 7-30d | 31-90d | 91-365d | |
| Radial papillary capillary | | | | | |
| Whole image | 94.2±8 | 88.6±11 | 76.2±11 | 73.9±17 | -0.234, 0.0031 |
| Inside disc | 94.8±12 | 93.4±13 | 87.3±16 | 84.7±11 | -0.181, 0.0229 |
| Peripapillary | 93.8±11 | 84.8±13 | 70.9±12 | 67.9±23 | -0.255, 0.0013 |
| Superior | 94.1±10 | 84.4±13 | 69.0±13 | 66.5±22 | -0.236, 0.0029 |
| Inferior | 93.6±11 | 85.2±14 | 73.1±12 | 70.9±25 | -0.249, 0.0017 |
| Nasal | 97.9±19 | 89.6±19 | 76.7±14 | 70.7±12 | -0.139, 0.0393 |
| Temporal | 96.1±10 | 90.6±15 | 73.5±13 | 69.2±11 | -0.161, 0.0774 |
| Macular vessel | | | | | |
| Whole image | 99.4±11 | 97.6±11 | 86.5±11 | 84.0±13 | -0.176, 0.0213 |
| Fovea | 127.4±63 | 117.8±46 | 96.4±88 | 77.1±46 | -0.116, 0.1276 |
| Perifovea | 97.1±10 | 94.5±10 | 82.6±10 | 82.5±15 | -0.173, 0.0233 |
| Superior | 98.4±10 | 97.2±12 | 86.9±10 | 84.4±14 | -0.172, 0.0242 |
| Inferior | 98.1±13 | 96.2±12 | 85.4±11 | 83.2±13 | -0.151, 0.0481 |
| Nasal | 97.3±11 | 96.7±9 | 87.0±12 | 84.3±15 | -0.141, 0.0654 |
| Temporal | 100.7±12 | 99.6±12 | 89.2±11 | 86.8±12 | -0.153, 0.0555 |

Data were calculated as (ITON/fellow eye)×100%. ^aPearson's correlation coefficient, calculated against number of days (post-injury).

The major limitation in this observational study was the inconsistency of follow-up timeframe among patients, which was due to several reasons: 1) varied lag-time between injury and initial hospital visit due to different severity of injuries; 2) loss of follow-up after few months following optic canal decompression surgeries, whether they benefited vision recovery, especially for non-local patients who lived in rural regions. Due to the limited time of following-up after surgery (mean 83.32d), it is unclear whether surgical intervention is helpful for chronic recovery of microvasculature perfusion

over a long-term period, it would be interesting to include patients for longer observation.

In conclusion, OCTA is a useful ophthalmic examination tool for routine diagnostic and treatment indication, where it provides depth resolved images for evaluating retinal vascular changes in ITON eyes by assessing thickness of the RNFL and macular GCC. In present study, OCTA revealed that time-dependent retina thinning and vascular attenuation are physiological features of ITON due to insufficient retinal blood supply.

Table 6 Time-dependent correlation of retinal thickness and vessel density for patients with varied severity of preoperative vision

| Parameters | Preoperative visual acuity (^a R, P) | | | | | |
|--------------------------------|---|----------------|----------------|-----------------|------------------|----------------|
| | NLP (n=29) | LP (n=5) | HM (n=4) | FC (n=12) | 0.01-0.08 (n=16) | 0.1-0.3 (n=7) |
| Retinal thickness | | | | | | |
| Retinal nerve fiber layer | | | | | | |
| Peripapillary | -0.777, <0.0001 | -0.899, 0.0127 | -0.954, 0.0048 | -0.801, <0.0001 | -0.714, <0.0001 | -0.423, 0.1219 |
| Ganglion cell complex | | | | | | |
| Whole image | -0.788, <0.0001 | -0.883, 0.0444 | -0.926, 0.0333 | -0.830, <0.0001 | -0.623, 0.0001 | -0.905, 0.0007 |
| Fovea | -0.727, <0.0001 | -0.883, 0.0428 | -0.772, 0.1036 | -0.724, <0.0001 | -0.590, 0.0003 | -0.675, 0.0281 |
| Perifovea | -0.812, <0.0001 | -0.795, 0.1298 | -0.926, 0.0333 | -0.773, <0.0001 | -0.606, 0.0002 | -0.804, 0.0058 |
| Vessel density | | | | | | |
| Radial peripapillary capillary | | | | | | |
| Whole image | -0.610, <0.0001 | -0.239, 0.6159 | -0.674, 0.1143 | -0.715, <0.0001 | -0.727, <0.0001 | -0.211, 0.4596 |
| Inside disc | -0.498, 0.0001 | -0.312, 0.5016 | -0.056, 0.9238 | -0.561, 0.001 | -0.146, 0.3697 | 0.296, 0.2921 |
| Peripapillary | -0.654, <0.0001 | -0.220, 0.6413 | -0.767, 0.0571 | -0.770, <0.0001 | -0.739, <0.0001 | -0.328, 0.2501 |
| Macular vessels | | | | | | |
| Whole image | -0.406, 0.0013 | -0.719, 0.0275 | -0.719, 0.0353 | -0.558, 0.0011 | -0.537, 0.0004 | -0.234, 0.3501 |
| Fovea | -0.377, 0.0025 | -0.657, 0.0507 | -0.650, 0.0659 | -0.095, 0.6107 | -0.445, 0.004 | -0.223, 0.3746 |
| Perifovea | -0.433, 0.0005 | -0.719, 0.0275 | -0.676, 0.054 | -0.568, 0.0008 | -0.576, 0.0001 | -0.148, 0.5588 |

^aPearson's correlation coefficient, calculated against number of days (post-injury). NLP: No light perception; LP: Light precepted; HM: Hand movement; FC: Finger count.

ACKNOWLEDGEMENTS

Foundations: Supported by the High-level Hospital Construction Project (No.303010406); Natural Science Foundation of Guangdong Province, China (No.2019A1515010361).

Conflicts of Interest: Ma H, None; Gao Y, None; Li JM, None; Bao YK, None; Nie C, None; Yin P, None; Lyu X, None; Ding XY, None; Lu R, None.

REFERENCES

- Singman EL, Daphalapurkar N, White H, Nguyen TD, Panghat L, Chang J, McCulley T. Indirect traumatic optic neuropathy. *Mil Med Res* 2016;3:2.
- Lee V, Ford RL, Xing W, Bunce C, Foot B. Surveillance of traumatic optic neuropathy in the UK. *Eye (Lond)* 2010;24(2):240-250.
- Anderson RL, Panje WR, Gross CE. Optic nerve blindness following blunt forehead trauma. *Ophthalmology* 1982;89(5):445-455.
- Warner N, Eggenberger E. Traumatic optic neuropathy: a review of the current literature. *Curr Opin Ophthalmol* 2010;21(6):459-462.
- Sarkies N. Traumatic optic neuropathy. *Eye (Lond)* 2004;18(11):1122-1125.
- Gross CE, DeKock JR, Panje WR, Hershkowitz N, Newman J. Evidence for orbital deformation that may contribute to monocular blindness following minor frontal head trauma. *J Neurosurg* 1981;55(6):963-966.
- Lee AG. Traumatic optic neuropathy. *Ophthalmology* 2000;107(5):814.
- Tong J, Kedar S, Ghate D, Gu L. Indirect traumatic optic neuropathy induced by primary blast: a fluid-structure interaction study. *J Biomech Eng* 2019. Epub ahead of print.
- Steinsapir KD, Goldberg RA. Traumatic optic neuropathy: an evolving understanding. *Am J Ophthalmol* 2011;151(6):928-933.e2.
- Wu N, Yin ZQ, Wang Y. Traumatic optic neuropathy therapy: an update of clinical and experimental studies. *J Int Med Res* 2008;36(5):883-889.
- Crompton MR. Visual lesions in closed head injury. *Brain* 1970;93(4):785-792.
- Jang SY. Traumatic optic neuropathy. *Korean J Neurotrauma* 2018;14(1):1-5.
- Yu-Wai-Man P. Traumatic optic neuropathy-clinical features and management issues. *Taiwan J Ophthalmol* 2015;5(1):3-8.
- Spaide RF, Fujimoto JG, Waheed NK, Sadda SR, Staurengi G. Optical coherence tomography angiography. *Prog Retin Eye Res* 2018;64:1-55.
- Spaide RF, Klancnik JM Jr, Cooney MJ. Retinal vascular layers imaged by fluorescein angiography and optical coherence tomography angiography. *JAMA Ophthalmol* 2015;133(1):45-50.
- Jia Y, Tan O, Tokayer J, Potsaid B, Wang Y, Liu JJ, Kraus MF, Subhash H, Fujimoto JG, Hornegger J, Huang D. Split-spectrum amplitude-decorrelation angiography with optical coherence tomography. *Opt Express* 2012;20(4):4710-4725.
- Kashani AH, Chen CL, Gahm JK, Zheng F, Richter GM, Rosenfeld PJ, Shi Y, Wang RK. Optical coherence tomography angiography: a comprehensive review of current methods and clinical applications. *Prog Retin Eye Res* 2017;60:66-100.
- Choi W, Moulton EM, Waheed NK, Adhi M, Lee B, Lu CD, de Carlo TE, Jayaraman V, Rosenfeld PJ, Duker JS, Fujimoto JG. Ultrahigh-speed, swept-source optical coherence tomography angiography in nonexudative age-related macular degeneration with geographic atrophy. *Ophthalmology* 2015;122(12):2532-2544.
- Coscas GJ, Lupidi M, Coscas F, Cagini C, Souied EH. Optical coherence tomography angiography versus traditional multimodal

- imaging in assessing the activity of exudative age-related macular degeneration. *Retina* 2015;35(11):2219-2228.
- 20 Akagi T, Iida Y, Nakanishi H, Terada N, Morooka S, Yamada H, Hasegawa T, Yokota S, Yoshikawa M, Yoshimura N. Microvascular density in glaucomatous eyes with hemifield visual field defects: an optical coherence tomography angiography study. *Am J Ophthalmol* 2016;168:237-249.
- 21 Chen CL, Zhang A, Bojikian KD, Wen JC, Zhang Q, Xin C, Mudumbai RC, Johnstone MA, Chen PP, Wang RK. Peripapillary retinal nerve fiber layer vascular microcirculation in glaucoma using optical coherence tomography-based microangiography. *Invest Ophthalmol Vis Sci* 2016;57(9):OCT475-OCT485.
- 22 Al-Sheikh M, Akil H, Pfau M, Sadda SR. Swept-source OCT angiography imaging of the foveal avascular zone and macular capillary network density in diabetic retinopathy. *Invest Ophthalmol Vis Sci* 2016;57(8):3907-3913.
- 23 Couturier A, Mané V, Bonnin S, Erginay A, Massin P, Gaudric A, Tadayoni R. Capillary plexus anomalies in diabetic retinopathy on optical coherence tomography angiography. *Retina* 2015;35(11):2384-2391.
- 24 Zhang T, Xiao W, Ye H, Chen R, Mao Y, Yang H. Peripapillary and macular vessel density in dysthyroid optic neuropathy: an optical coherence tomography angiography study. *Invest Ophthalmol Vis Sci* 2019;60(6):1863-1869.
- 25 Augstburger E, Zéboulon P, Keilani C, Baudouin C, Labbé A. Retinal and choroidal microvasculature in nonarteritic anterior ischemic optic neuropathy: an optical coherence tomography angiography study. *Invest Ophthalmol Vis Sci* 2018;59(2):870-877.
- 26 Munemasa Y, Kitaoka Y. Autophagy in axonal degeneration in glaucomatous optic neuropathy. *Prog Retin Eye Res* 2015;47:1-18.
- 27 Bernardo-Colón A, Vest V, Cooper ML, Naguib SA, Calkins DJ, Rex TS. Progression and pathology of traumatic optic neuropathy from repeated primary blast exposure. *Front Neurosci* 2019;13:719.
- 28 Micieli JA, Newman NJ, Biousse V. The role of optical coherence tomography in the evaluation of compressive optic neuropathies. *Curr Opin Neurol* 2019;32(1):115-123.
- 29 Danesh-Meyer HV, Carroll SC, Foroozan R, Savino PJ, Fan J, Jiang Y, Vander Hoorn S. Relationship between retinal nerve fiber layer and visual field sensitivity as measured by optical coherence tomography in chiasmal compression. *Invest Ophthalmol Vis Sci* 2006;47(11):4827-4835.
- 30 Lee JY, Cho K, Park KA, Oh SY. Analysis of retinal layer thicknesses and their clinical correlation in patients with traumatic optic neuropathy. *PLoS One* 2016;11(6):e0157388.
- 31 Chan JW, Hills NK, Bakall B, Fernandez B. Indirect traumatic optic neuropathy in mild chronic traumatic brain injury. *Invest Ophthalmol Vis Sci* 2019;60(6):2005-2011.
- 32 Li J, Shi W, Li M, Wang Z, He H, Xian J, Lv B, Yan F. Time-dependent diffusion tensor changes of optic nerve in patients with indirect traumatic optic neuropathy. *Acta Radiol* 2014;55(7):855-863.
- 33 Medeiros FA, Moura FC, Vessani RM, Susanna R Jr. Axonal loss after traumatic optic neuropathy documented by optical coherence tomography. *Am J Ophthalmol* 2003;135(3):406-408.
- 34 Vessani RM, Cunha LP, Monteiro ML. Progressive macular thinning after indirect traumatic optic neuropathy documented by optical coherence tomography. *Br J Ophthalmol* 2007;91(5):697-698.