

# Recurrence after spontaneous separation of epiretinal membrane in a young woman: a case report

Qiao-Zhu Zeng<sup>1,2</sup>, Wen-Zhen Yu<sup>1,2</sup>

<sup>1</sup>Department of Ophthalmology, Eye Diseases and Optometry Institute, Peking University People's Hospital, Beijing 100044, China

<sup>2</sup>Beijing Key Laboratory of Diagnosis and Therapy of Retinal and Choroid Diseases, College of Optometry, Peking University Health Science Center, Beijing 100044, China

**Correspondence to:** Wen-Zhen Yu. Department of Ophthalmology, Peking University People's Hospital, No.11 Xizhimen South Street, Xicheng District, Beijing 10044, China. wenzhenyubjmu@163.com

Received: 2022-09-26 Accepted: 2023-01-29

**DOI:10.18240/ijo.2023.03.22**

**Citation:** Zeng QZ, Yu WZ. Recurrence after spontaneous separation of epiretinal membrane in a young woman: a case report. *Int J Ophthalmol* 2023;16(3):476-478

**Dear Editor,**

We report a case of recurrence after spontaneous separation of epiretinal membrane (ERM) in a young woman with suspected retinal vasculitis. ERM is defined as the fibrocellular membrane that proliferates on the inner surface of neurosensory retina at the macular area. Idiopathic ERM (iERM) usually occurs without a clearly identifiable cause in patients of more than 50 years of age and a great discrepancy in its prevalence from 1.02% to 28.9% among different ethnic groups were noted in previous epidemiologic studies<sup>[1-3]</sup>. Secondary ERM is associated with a series of ocular diseases, including retinal vascular diseases, retinal detachment, ocular inflammatory disease, ocular trauma, intraocular surgery, *etc.* Most iERM will remain relatively stable and no therapy is required. A large population-based study revealed that ERM may progress, regress, or stay stable in 28.6%, 25.7%, and 38.8% of eyes over 5y<sup>[3]</sup>.

ERM is rarely reported in young subjects, for whom the secondary ERM were more common<sup>[1]</sup>. Spontaneous resolution of ERM is an uncommon phenomenon, with a rate of 2.3% by Meyer *et al*<sup>[4]</sup> and 26.9% by Kim *et al*<sup>[5]</sup>. Moreover, reports of recurrence after spontaneous separation of ERM were lacked.

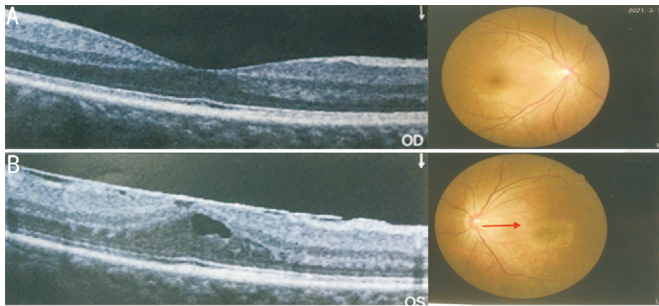
A 33-year-old woman complained of mild metamorphopsia in her left eye for 6mo in March, 2021, and the right eye was asymptomatic. She denied history of ocular trauma, inflammation, infection or surgery. The best corrected visual acuity (BCVA) was 1.0 and 0.8 in the right and left eye. Anterior segment findings and intraocular pressure were normal. Fundus examination revealed a dense ERM with retinal striae in the left eye. The report of spectral domain optical coherence tomography (SD-OCT, Optovue RTVue) confirmed ERM overlying the macula, and the central foveal thickness (CFT) was increased to 332  $\mu\text{m}$  in the left eye (Figure 1).

In May 2021, her vision had improved to 1.0 left eye and the metamorphopsia had completely resolved. But she felt more floaters in the left eye. Weiss ring was observed by binocular indirect ophthalmoscope. SD-OCT (Carl Zeiss Meditec, Cirrus) examinations confirmed the disappearance of the ERM and the intraretinal oedema had resolved, with reduction of CFT to 215  $\mu\text{m}$ . A more normal foveal anatomy was restored (Figure 2A).

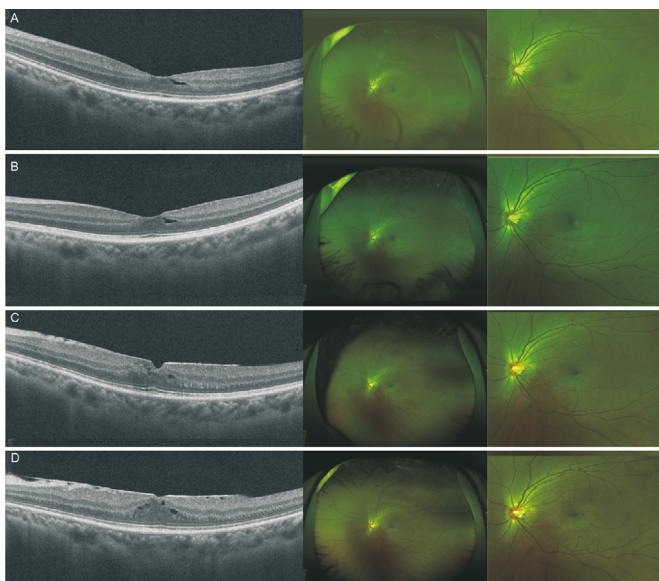
In fundus examination, the ERM had spontaneously separated from the retina. And it was revealed that the ERM was floating freely in the vitreous, presented as a thin and grayish-white flap attached to the retina. In addition, the foveal reflex was normal. In June 1<sup>st</sup>, she revisited our clinic without additional signs or symptoms, with OCT and fundus photography demonstrating no ERM (Figure 2B).

However, she came back to our clinic again, presenting with recurrent metamorphopsia in June 30<sup>th</sup>. The BCVA of her left eye decreased to 0.6. An OCT scan demonstrated no edema. A semi-transparent ERM with a size of about 3-disc diameters was confirmed (Figure 2C).

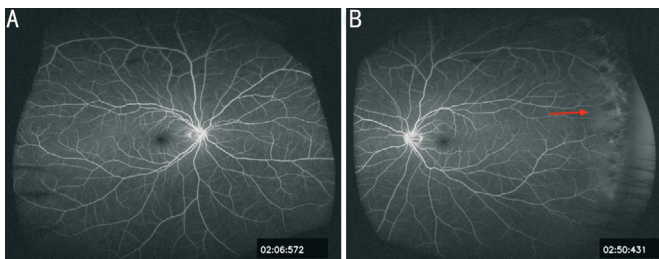
A conservative approach was chosen. In August 12<sup>th</sup>, she returned to our hospital. Her BCVA was 1.0 in the left eye, and OCT revealed there was hyporeflective intraretinal cystic spaces in the macula. The CFT was 327  $\mu\text{m}$  (Figure 2D). In January 2021, the patient still had no additional signs or symptoms of the ERM. We have summarized the changes of central retinal thickness before and after recurrence as in Table 1. Ultrawidefield fluorescein angiography at 02:06:572 (Figure 3A) and at 02:50:431 (Figure 3B) indicated temporally



**Figure 1** The vertical OCT scans and the corresponding color photographs of the right (A) and left eyes (B) on March 11<sup>th</sup>. The BCVA was 1.0 and 0.8 in the right and left eye. OCT: Optical coherence tomography; BCVA: Best corrected visual acuity.



**Figure 2** The vertical OCT scans and the corresponding color photographs of the left eye on May 11<sup>th</sup> (A), BCVA was 1.0; on June 1<sup>st</sup> (B), BCVA was 1.0; on June 30<sup>th</sup> (C), BCVA was 0.6; on August 12<sup>th</sup> (D), BCVA was 1.0. OCT: Optical coherence tomography; BCVA: Best corrected visual acuity.



**Figure 3** Fluorescein angiography at 02:06:572 (A) and at 02:50:431 (B) on August 12<sup>th</sup> demonstrated temporally located vascular lesion with early hyperfluorescence and late leakage.

located vascular lesion with early hyperfluorescence. Therefore, she received the blood tests. The anti-nuclear antibody test, anti-neutrophil cytoplasmic antibody test and traditional interferon-gamma release assay (T-SPOT.TB) test were negative. The patient was suspected of having hereditary vitreoretinopathy with possibility of previous leakage, which may be the cause of ERM. Considering the good vision, we

**Table 1** Changes of central retinal thickness before and after recurrence

Date	Status of the diseased eye	Central retinal thickness of the diseased eye ( $\mu\text{m}$ )
March, 2021	ERM	332
May, 2021	ERM resolution	215
June 1 <sup>st</sup> , 2021	No ERM	206
June 30 <sup>th</sup> , 2021	ERM recurrence	250
August 12 <sup>th</sup> , 2021	ERM	327

ERM: Epiretinal membrane.

decided to carry out follow-up observations. This study was approved by the Institutional Review Board Committee of Peking University People's Hospital (2021PHB032) and was conducted in accordance with the principles of the Declaration of Helsinki. The informed consent was obtained from the subjects.

ERMs have a variety of possible origins. Microbreaks of internal limiting membrane (ILM) during posterior vitreous detachment (PVD) may lead to migration and proliferation of retinal glial cell or retinal pigment epithelial cell onto anterior retinal surface<sup>[6-7]</sup>. Another hypothesis has been put forward that in the absence of PVD, cells in the cortical vitreous remnants on ILM could be activated into myofibroblasts, allowing for ILM formation<sup>[2]</sup>. Most ERMs contain various cell types, including glial cells, hyalocytes, macrophages, retinal pigment epithelial cells, fibroblasts and myofibroblasts<sup>[1]</sup>. Combination of vitreous collagen, several cellular origins and differentiations, and extracellular matrix material constitutes ERM.

Spontaneous separation of ERM is an uncommon phenomenon, with previously reported rates of 1%-3%<sup>[4,8-10]</sup>. In the 33-month study by Yang *et al*<sup>[11]</sup> with 1248 iERM cases, the prevalence of spontaneous separation in eyes with and without PVD was 1.5% and 13.4%. During 2-13mo of follow-up in the study by Meyer *et al*<sup>[4]</sup>, spontaneous separation rates were reported to be 0.47% and 2.3% in eyes with and without PVD among 210 patients under the age of 30 who had iERM. Interestingly in the case reported by Ozgonul and Besirli<sup>[12]</sup>, they demonstrated a self-peeling ERM associated with a retinal capillary hemangioma. There was similar temporally late leakage to ours in the left eye seen from fluorescein angiography. It was suggested that peripheral angiomatic lesions may be excluded in the follow-up period of our patient. In addition, some "idiopathic" ERM reported in young populations could actually be secondary, which may not be found due to limited examinations.

Two main mechanisms of spontaneous ERM separation have been proposed in the literature. With PVD, the ERM may spontaneously separate when its inner contractive forces are stronger than the adhesion to the retina. Another mechanism

is the tangential cell-mediated traction along the inner retinal layer unrelated to PVD induction<sup>[4]</sup>, which could be demonstrated in red arrows in Figure 1. Concentric tangential traction could be presented as all folds directing to the center of the fovea. Moreover, Yang *et al*<sup>[11]</sup> suggested that a combined process involving PVD and self-contraction may also contribute to the pathogenesis of ERM spontaneous resolution.

The pathogenesis of recurrent ERM after spontaneous resolution of ERM remained unclear. It is proposed that the retinal glial cells could migrate and proliferate on the inner retina, through the subtle defects of ILM developed in the process of spontaneous removal. Another possible cause is that membrane remnants of ERM left on the ILM may proliferate and develop to a recurrent ERM when ERM is not completely removed following surgery, which might be also applied to the formation of recurrent ERM after spontaneous separation. It was also proposed that after spontaneous separation, the retinal inner segment/outer segment line is deficient. And ERM is more commonly recurrent in this circumstance<sup>[4]</sup>. Moreover, multimodal imaging should be applied to explore the possible reason for ERM in young patients. It is important to carry out peripheral retinal examination in determining possible cause of ERM.

The majority of ERMs in young patients may remain stable and do not require therapy. The severity of patients' symptoms and cause of the disease decide whether to intervene surgically in patients with ERM. Conservative observation is suggested for ERM patients with mild visual disturbance due to possible spontaneous resolution. When there is recurrence after spontaneous self-separation, we should periodically evaluate the central vision in order to detect changes may occur over time. It is crucial to timely treat the primary diseases when we found the secondary reasons.

In summary, we report recurrence after self-peeling of an ERM in a young patient. The pathogenesis of recurrent ERM after spontaneous ERM is still poorly understood. A period of observation may be considered in patients with recurrent ERM after spontaneous separation. In addition, we are suggested to take thorough examinations, including multimodal imaging to eliminate secondary factors that could be the actual reason for ERM in young people, which is often neglected in clinic settings.

## ACKNOWLEDGEMENTS

**Foundation:** Supported by Beijing Natural Science Foundation (No.J190005).

**Conflicts of Interest:** Zeng QZ, None; Yu WZ, None.

## REFERENCES

- 1 Chua PY, Sandinha MT, Steel DH. Idiopathic epiretinal membrane: progression and timing of surgery. *Eye (Lond)* 2022;36(3):495-503.
- 2 Flaxel CJ, Adelman RA, Bailey ST, Fawzi A, Lim JI, Vemulakonda GA, Ying GS. Idiopathic epiretinal membrane and vitreomacular traction preferred practice pattern<sup>®</sup>. *Ophthalmology* 2020;127(2):P145-P183.
- 3 Zhu XB, Yang MC, Wang YX, *et al*. Prevalence and risk factors of epiretinal membranes in a Chinese population: the Kailuan eye study. *Invest Ophthalmol Vis Sci* 2020;61(11):37.
- 4 Meyer CH, Rodrigues EB, Mennel S, Schmidt JC, Kroll P. Spontaneous separation of epiretinal membrane in young subjects: personal observations and review of the literature. *Graefes Arch Clin Exp Ophthalmol* 2004;242(12):977-985.
- 5 Kim JH, Kim JW, Kim CG, Lee DW. Long-term natural history of the idiopathic epiretinal membrane in children and young adults. *Graefes Arch Clin Exp Ophthalmol* 2020;258(10):2141-2150.
- 6 Gonzalez-Cortes JH, Bilgic A, De Los Santos Polanco J, Treviño-Herrera AB, Sudhalkar A, Gonzalez-Cantu JE, Mohamed-Hamsho J. Spontaneous closure of an idiopathic macular hole after epiretinal membrane development. *Am J Ophthalmol Case Rep* 2022;29:101767.
- 7 Jones CH, Gui W, Schumann RG, *et al*. Hyalocytes in proliferative vitreo-retinal diseases. *Expert Rev Ophthalmol* 2022;17(4):263-280.
- 8 Nomoto H, Matsumoto C, Arimura E, Okuyama S, Takada S, Hashimoto S, Shimomura Y. Quantification of changes in Metamorphopsia and retinal contraction in eyes with spontaneous separation of idiopathic epiretinal membrane. *Eye (Lond)* 2013;27(8):924-930.
- 9 Kolomeyer AM, Schwartz DM. Spontaneous epiretinal membrane separation. *Oman J Ophthalmol* 2013;6(1):56-57.
- 10 Desatnik H, Treister G, Moisseiev J. Spontaneous separation of an idiopathic macular pucker in a young girl. *Am J Ophthalmol* 1999;127(6):729-731.
- 11 Yang HS, Hong JW, Kim YJ, Kim JG, Joe SG. Characteristics of spontaneous idiopathic epiretinal membrane separation in spectral domain optical coherence tomography. *Retina* 2014;34(10):2079-2087.
- 12 Ozgonul C, Besirli CG. Self-peeling epiretinal membrane. *Retin Cases Brief Rep* 2018;12(3):196-199.