

# Expression of Nogo-A on the retina in rat model with chronic ocular hypertension

Qing-Zhu Nie<sup>1</sup>, Zhi-Li Liu<sup>1</sup>, Qian Sha<sup>2</sup>, Dian-Wen Gao<sup>1</sup>

**Foundation item:** Scientific and Technological Research Funded Projects in Liaoning Province, China (No. 2009225021)

<sup>1</sup>Department of Ophthalmology, Shengjing Hospital Affiliated to China Medical University, Shenyang 110004, Liaoning Province, China

<sup>2</sup>Heilongjiang Eye Hospital, Harbin 150001, Heilongjiang Province, China

**Correspondence to:** Qing-Zhu Nie. Department of Ophthalmology, Shengjing Hospital Affiliated to China Medical University, Shenyang 110004, Liaoning Province, China. nieqz1966@yahoo.cn

Received: 2010-03-15 Accepted: 2010-04-26

## Abstract

• **AIM:** To study the expressive variation of Nogo-A on rat retina in the process of chronic ocular hypertension.

• **METHODS:** Thirty-six healthy adult male Wistars were randomly divided into control group (6 rats) and chronic hypertension group (30 rats). Chronic hypertension was created by cauterizing the superficial scleral veins. Immunohistochemistry technique was used to evaluate the expressive varieties of Nogo-A at different time points during the course of chronic ocular hypertension.

• **RESULTS:** The success of the model was indicated by over 40% of increase in the IOP as compared with normal rats. Compared with control group, as time passed chronic hypertension group gradually had detectable morphology changes in the retina. At the 21<sup>st</sup> day of chronic ocular hypertension, retinas became thinner and the quantity of retinal ganglion cell (RGC) decreased ( $P < 0.05$ ). Associated with the morphological changes, the expression of Nogo-A was strongly increased ( $P < 0.05$ ).

• **CONCLUSION:** Myelin associated protein Nogo-A plays a part in the process of chronic ocular hypertension.

• **KEYWORDS:** retina; chronic hypertension; Nogo-A; retinal ganglion cell

DOI: 10.3969/j.issn.1672-5123.2010.05.001

Nie QZ, Liu ZL, Sha Q, Gao DW. Expression of Nogo-A on the retina in rat model with chronic ocular hypertension. *Int J Ophthalmol (Guji Yanke Zazhi)* 2010;10(5):825-826

## INTRODUCTION

The pathological mechanism of glaucomatous optic neuropathy is progressive death of retinal ganglion cells, which leads to irreversible damage. Regeneration of damaged central nervous system, including optic nerve, is difficult to

achieve because of a number of reasons, such as inhibitors of axonal regeneration are present in myelin, lack of neurotrophic factors, and formation of the glia scar. It has been postulated that the regeneration of central nervous system is affected by myelin associated protein Nogo-A. Nogo-A, which is predominantly present in oligodendrocytes and myelin in the adult central nervous system (CNS), not only restricts neurite growth, plasticity, and axonal regeneration, but also limits the invasion and migration of cells and tumors in the CNS<sup>[1]</sup>. Therefore, our finding on the expressive variation of Nogo-A in rat retina indicates an important role of Nogo-A in the optic nerve injury in the process of chronic ocular hypertension and suggests a new approach to rehabilitate glaucomatous optic nerve.

## MATERIALS AND METHODS

**Materials** Thirty-six male Wistar rats, weighing between 250-300g were supplied by experiment animal department of China Medical University. The animals and experimental conditions were performed in accordance with laboratory animal regulations of State Science and Technology Commission. Animals were randomly divided into 2 groups, which were 6 in control group (12 eyes), and 30 in chronic hypertension group (60 eyes). Rabbit anti-rat Nogo-A (Wuhan Boster Biotechnology Co, Ltd), and SP kit (Fuzhou Maixin Biotechnology) were used.

**Methods** Rat model of chronic IOP elevation. Rats were anesthetized by intraperitoneal injection of 3.5 mL/kg of chloral hydrate (100g/L). Bulbar conjunctiva was cut and two superficial venous tributaries were burnt. Signs of successful burn were shown as disappeared episclera venous blood flow on the distal end of the burnt point, and distension and darkness of the vessels near comeoscleral limbus. Bulbar conjunctiva was then reset with Tobradex drops and pasted with eyedrop. IOP was measured with Tonopen XL before the operation, half an hour after the operation, and at the 3<sup>rd</sup> day, the 7<sup>th</sup> day, the 14<sup>th</sup> day, the 21<sup>st</sup> day and the 28<sup>th</sup> day after operation. IOP that is 40% beyond preoperative value (9-16 mmHg) indicates a success of the model.

After sampling fixation, dehydration and paraffin imbedding were performed according to the instruction of the kit. Positive cells were those with yellow or brownish-yellow granules deposited in cytoplasm or nuclei. We selected 5 discontinued high power fields from each section to assess the expression intensity with metaMorph/BX51 microgram analytical system to determine the integrated A of positive cells.

**Statistical Analysis** Quantitative data were expressed as the mean  $\pm$  SEM, and were analyzed with one-way analysis of variance

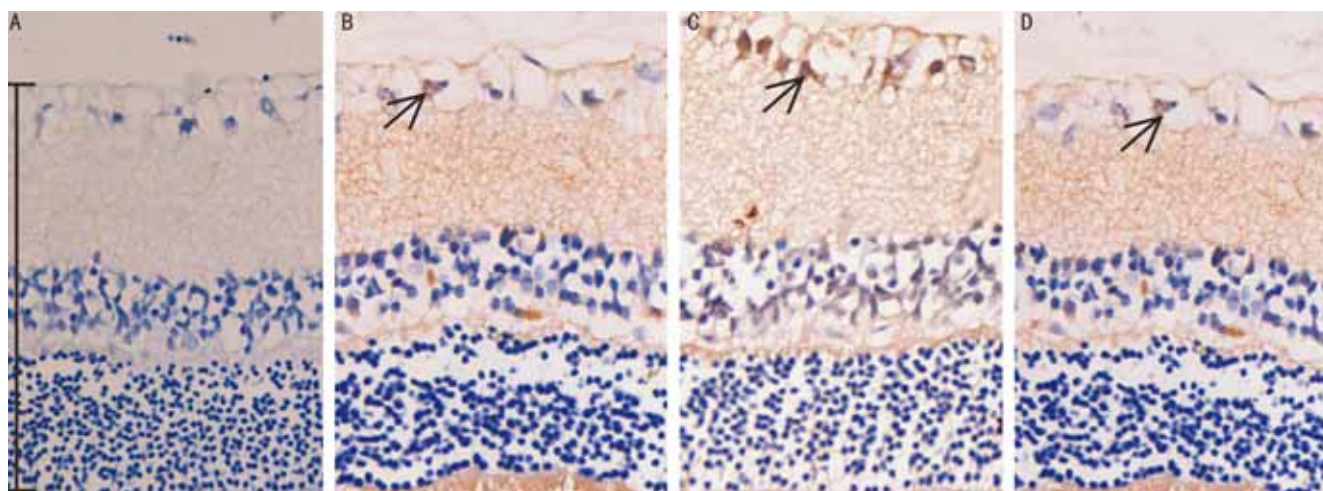


Figure 1 Expression of Nogo-A in retinas of rats with chronic ocular hypertension A: Control; B: 3 days; C: 7 days; D: 28 days.

(ANOVA) followed by Bonferroni test for multiple comparisons among experimental groups and control groups. Statistical analysis was performed using the SPSS 17.0 statistical software. The results were considered statistically different at  $P < 0.05$ .

### RESULTS

After 21 days of chronic ocular hypertension the retina became thinner ( $28.3 \pm 8.0$ ,  $17.0 \pm 6.5 \mu\text{m}$ ,  $P < 0.05$ ) and the number of RGC decreased as compared with control group. In the control group only trace amount of Nogo-A was detected in the layer of ganglion cells in the retina. In the retina from rat model with chronic ocular hypertension, the level of Nogo-A protein (IOD) were found to increase at 7 days ( $64.17 \pm 2.68$ ,  $24.93 \pm 1.31 \mu\text{m}$ ,  $P < 0.01$ ) after establishment of the model, and the increase remained significantly at 28 days ( $37.69 \pm 3.15$ ,  $24.93 \pm 1.31 \mu\text{m}$ ,  $P < 0.05$ ) after the model establishment compared with control group (Figure 1).

### DISCUSSION

Optic nerve damage of glaucoma is a chronic course. However, most animal models for glaucoma research are ischemia-reperfusion models and have disadvantage for observation of retina protection. Reports about morphological changes under chronic ocular hypertension are rare. Regenerative nerve fiber growth and structural plasticity are limited in the CNS of adult mammalian, including optic nerve, in part because of the presence of neurite growth inhibitory constituents<sup>[2]</sup>. An important step in elucidating the mechanisms of this inhibition was the discovery of Nogo-A, which is an oligodendrocyte-associated neurite growth inhibitor<sup>[3-5]</sup>. The nogo gene encodes three major protein products, Nogo-A, -B, and -C, by alternative splicing and alternative promoter usage<sup>[6,7]</sup>. Nogo-A was shown to be inhibitory for fibroblast spreading and neurite outgrowth and to induce growth cone collapse in rat dorsal root ganglion (DRG) and chick retinal ganglion cell (RGC) neurons. Our results suggest the change of expression of Nogo-A protein in the retina was associated with the elevated ocular pressure. The dramatically increased Nogo-A indicated that Nogo-A may play an important role in obstructing regeneration of optic nerve. Suppression of the Nogo-A might be a new treatment for glaucoma.

### REFERENCES

- 1 Belien ATJ, Paganetti PA, Schwab ME. Membrane-type 1 matrix metalloprotease (MT1-MMP) enables invasive migration of glioma cells in central nervous system white matter. *J Cell Biol* 1999;144:373-383
- 2 Behar O, Mizuno K, Neumann S, Woolf CJ. Putting the spinal cord together again. *Neuron* 2000;26:291-293
- 3 Chen MS, Huber AB, van der Haar ME, Frank M, Schnell L, Spillmann AA, Christ F, Schwab ME. Nogo-A is a myelin-associated neurite outgrowth inhibitor and an antigen for monoclonal antibody IN-1. *Nature* 2000;403:434-439
- 4 GrandPré T, Nakamura F, Vartanian T, Strittmatter SM. Identification of the Nogo inhibitor of axon regeneration as a reticulon protein. *Nature* 2000;403:439-444
- 5 Prinjha R, Moore SE, Vinson M, Blake S, Morrow R, Christie G, Michalovich D, Simmons DL, Walsh FS. Inhibitor of neurite outgrowth in humans. *Nature* 2000;403:383-384
- 6 Chen MS, Huber AB, van der Haar ME, Frank M, Schnell L, Spillmann AA, Christ F, Schwab ME. Nogo-A is a myelin-associated neurite outgrowth inhibitor and an antigen for monoclonal antibody IN-1. *Nature* 2000;403:434-439
- 7 Oertle T, Huber C, van der Putten H, Schwab ME. Genomic structure and functional characterisation of the promoters of human and mouse Nogo/Rtn-4. *J Mol Biol* 2003;325:299-323

### 大鼠慢性高眼压视网膜 Nogo-A 的表达

聂庆珠<sup>1</sup>, 刘致力<sup>1</sup>, 沙倩<sup>2</sup>, 高殿文<sup>1</sup>

基金项目: 中国辽宁省科技攻关资助项目 (No. 2009225021)

(作者单位: <sup>1</sup>110004 中国辽宁省沈阳市, 中国医科大学附属盛京医院眼科; <sup>2</sup>150001 中国黑龙江省哈尔滨市, 黑龙江省眼科医院) 作者简介: 聂庆珠, 男, 副教授, 硕士生导师, 研究方向: 青光眼与视神经病变。

通讯作者: 聂庆珠. nieqz1966@yahoo.cn

#### 摘要

**目的:** 研究慢性高眼压大鼠视网膜髓鞘相关抑制蛋白 Nogo-A 表达的变化。

**方法:** 成年雄性 Wistar 大鼠 36 只随机分为正常对照组 6 只和慢性高眼压组 30 只, 应用免疫组织化学方法观察慢性高眼压大鼠视网膜不同时点 Nogo-A 表达的变化。

**结果:** 与正常对照组相比, 慢性高眼压 21d 大鼠视网膜变薄, 节细胞数量减少 ( $P < 0.05$ ); Nogo-A 表达增多, 与形态学变化相一致 ( $P < 0.05$ )。

**结论:** 髓鞘相关抑制蛋白 Nogo-A 在慢性高眼压大鼠视网膜损伤过程中发挥了重要作用。

**关键词:** 视网膜; 慢性高眼压; Nogo-A; 视网膜神经节细胞