

Effects of oral antidiabetic drugs and insulin treatment on ocular surface

Burçin Köklü Çakır¹, Yasemin Aslan Katircioğlu², Nurten Ünlü², Hüseyin Üstün², Remzi Kasım², Sunay Duman²

¹Orkide Street 39/5 Bahçelievler, Balıkesir 10050, Turkey

²Ankara Eğitim Araştırma Hastanesi Göz Kliniği, Ankara 06600, Turkey

Correspondence to: Burçin Köklü Çakır. Orkide Street 39/5 Bahçelievler, Balıkesir 10050, Turkey. b_koklu@yahoo.com

Received: 2012-12-04 Accepted: 2013-08-19

口服降糖药和胰岛素对眼表治疗的影响

Burçin Köklü Çakır¹, Yasemin Aslan Katircioğlu², Nurten Ünlü², Hüseyin Üstün², Remzi Kasım², Sunay Duman²

(作者单位:¹土耳其,巴勒克埃西尔 10050, Bahçelievler 市 Orkide 大街 39/5 号; ² 土耳其,安卡拉 06600,安卡拉培训和研究医院眼科)

通讯作者: Burçin Köklü Çakır. b_koklu@yahoo.com

摘要

目的: 描述和对比口服降糖药 (OAD) 和胰岛素治疗 2 型糖尿病患者眼表的效果。

方法: 在安卡拉卫生部培训和研究医院就诊的 20 例 40 眼口服降糖药患者, 20 例 40 眼胰岛素治疗患者, 对照组的 10 例非糖尿病人作为研究对象。对所有患者进行常规眼科检查, Schirmer 试验, 泪膜破裂时间分析和结膜印迹细胞学分析。比较三组的泪液功能参数, 杯状细胞密度和鳞状上皮化生等级。记录视网膜病变及眼表疾病之间的关系。

结果: 口服降糖药患者泪膜破裂时间值明显低于其他组 ($P < 0.05$)。三组的杯状细胞密度和鳞状上皮化生等级相近。上皮细胞稍大, 呈现更多的多边形的眼的中位数级为 1 级, 并且嗜酸性染色胞浆和杯状细胞数量减少。视网膜病变与眼表疾病不相关。

结论: 口服降糖药患者的角膜前泪膜稳定性比其他组差。各组的印迹细胞学分析结果相似。

关键词: 眼表; 糖尿病; 印迹细胞学

引用: Çakır BK, Katircioğlu YA, Ünlü N, Üstün H, Kasım R, Duman S. 口服降糖药和胰岛素对眼表治疗的影响. 国际眼科杂志 2013;13(9):1747-1750

Abstract

• **AIM:** To describe and compare ocular surface changes in type 2 diabetes patients treated either oral antidiabetic

drugs (OAD) or insulin.

• **METHODS:** Forty eyes of twenty patients treated with OAD, 40 eyes of 20 patients treated with insulin and 10 non-diabetic controls seen at the Ministry of Health Ankara Educational and Research Hospital were studied. All subjects underwent routine ophthalmic examinations, Schirmer test, tear film break-up time analysis and conjunctival impression cytology analysis. Patients in three groups were compared for tear function parameters, goblet cell density and squamous metaplasia grade. The relation between status of retinopathy and ocular surface disorders were noted.

• **RESULTS:** The tear film break-up time values were significantly lower at patients treated with OAD ($P < 0.05$). Goblet cell density and squamous metaplasia grade were similar at all groups. The median grade was grade 1 in which epithelial cells are slightly larger, more polygonal, have eosinophilic staining cytoplasm and goblet cells are decreased in number. Status of retinopathy did not seem to relate with ocular surface disorders.

• **CONCLUSION:** Precorneal tear film stability is found to be worse in patients treated with OAD whereas impression cytology analysis is similar in all groups.

• **KEYWORDS:** ocular surface; diabetes mellitus; impression cytology

DOI:10.3980/j.issn.1672-5123.2013.09.02

Citation: Çakır BK, Katircioğlu YA, Ünlü N, Üstün H, Kasım R, Duman S. Effects of oral antidiabetic drugs and insulin treatment on ocular surface. *Guoji Yanke Zazhi (Int Eye Sci)* 2013;13(9):1747-1750

INTRODUCTION

Ocular complications of diabetes mellitus (DM) such as diabetic retinopathy, cataract, neovascular glaucoma, refractory deviations are already known. Dry eye syndrome and ocular surface disorders are also important problems. The cause of this condition could be the neuropathy itself, the metabolic dysfunction or an abnormal lacrimal secretion^[1-3]. Recent studies focused on the tear film of diabetic patients compared with healthy individuals^[1-6].

In this study, we investigate the amount of tear production, the stability of the tear film and the condition of the

conjunctival surface in diabetic patients treated with OAD and insulin. We examine the differences of each medical treatment with reference to non-diabetic control group.

SUBJECTS AND METHODS

Subjects We studied 40 eyes of 20 diabetic patients (12 female, 8 male) treated with OAD (group 1), 40 eyes of 20 diabetic patients (14 female, 6 male) treated with insulin (group 2) and 20 eyes of 10 non-diabetic individuals (6 female, 4 male) (group 3) at the Ministry of Health Ankara Educational and Research Hospital. The study was approved by the ethics committee of Ankara Training and Research Hospital Ministry of Health.

All subjects underwent routine ophthalmic examination. In this examination particular attention was paid to lid margins, tarsal and bulbar conjunctiva and cornea. Patients who had a history of contact lens wear, topical medication, ocular surgery and abnormalities in the cornea, conjunctiva or eyelid were excluded from this study. A written informed consent was obtained from each patient.

Methods We performed tear film break-up time (BUT), Schirmer test and conjunctival impression cytology on all patients. We also evaluated age, sex, duration of diabetes and presence of diabetic retinopathy.

Diabetic patients were divided into two subgroups as either having non-proliferative diabetic retinopathy (14 patients) or non-diabetic retinopathy (26 patients). Schirmer test, tear film break-up time and impression cytology grade were compared among these groups.

Tear film break-up time was performed for evaluating precorneal tear film stability. A moistened fluorescein strip was applied to the tarsal conjunctiva. After several blinks, the tear film was examined using a broad beam of the slit lamp with a blue filter. The time lapse between the last blink and the appearance of the first randomly distributed dry spot was measured three times and the mean value of the measurements was calculated.

Schirmer test without topical anesthesia was performed. The standardized thin filter paper strips were placed in the lateral canthus away from the cornea and left in place for 5 minutes with the eyes closed. The amount of wetting in millimeters was measured.

Impression cytology of the conjunctiva was performed according to the technique described by Nelson *et al*^[7]. Eyes were topically anesthetized with 0.5% proparacaine hydrochloride. Small discs of cellulose acetate filter paper with a pore size of 0.025mm were placed on the superior conjunctiva adjacent to the corneal limbus. The specimens were placed in a fixative solution and stained according to Papanicolaus Gill's technique. The specimens were examined with light-microscopy in a blinded fashion by a pathologist. This examination employed the Nelson's method. The epithelial

cells of conjunctiva and the existence of goblet cells were evaluated. The degree of squamous metaplasia and goblet cell density were graded from 0 to 3 according to Nelson's grading scheme;

Grade 0: The epithelial cells are small and round with eosinophilic cytoplasm. The nuclei are large, basophilic with a nucleocytoplasmic ratio (N/C of 1:2). The goblet cells are abundant, plump and oval.

Grade 1: The epithelial cells are slightly larger, more polygonal, have eosinophilic staining cytoplasm (N/C of 1:3) and goblet cells are slightly decreased in number; however, they still maintain their plump, oval shape with an intensely PAS-positive cytoplasm.

Grade 2: The epithelial cells are larger and polygonal. (N/C of 1:4-1:5). The goblet cells are markedly decreased in number and are smaller less intensely PAS-positive with poorly defined cellular borders.

Grade 3: The epithelial cells are larger than those in grade II and polygonal with basophilic staining cytoplasm. The nuclei are small pyknotic or in many cells completely absent. The NCR is greater than 1:6, goblet cells are completely absent.

Statistical Analysis Parameters were analyzed at Statistical Package for Social Science (SPSS) software. Data were expressed as mean \pm standard deviation or median. Kruskal-Wallis test was used to compare Schirmer test, BUT, and impression cytology grades among groups. Correlation between Schirmer test, BUT, and impression cytology grades among groups was investigated with calculation of Spearman's Rho correlation. Mann-Whitney U test was used for analyzing duration of DM in groups 1 and 2. *P* values of less than 0.05 were considered statistically significant.

RESULTS

There were no significant difference in age and gender among all groups. The mean age was 53.3 years with a range from 40 to 67 in group 1, 52.25 years with a range from 40 to 68 years in group 2, 51.57 years with a range from 48 to 56 years in group 3. Duration of DM time and diabetic retinopathy status were also similar in both groups. Thirty eyes (75%) in group 1, 22 eyes (55%) in group 2 had no diabetic retinopathy. Median duration of DM was 7 years in group 1 and 6 years in group 2 (Table 1).

Slit-lamp biomicroscopy of the eye-lid margins and conjunctiva did not reveal any coexistent blepharitis, meibomian gland disorder or conjunctivitis.

The median BUT was 7 seconds (2-15 seconds) in group 1, 10 seconds (2-16 seconds) in group 2 and 10.50 seconds (4-15 seconds) in group 3 (Table 2). The difference was statistically significant (*P*<0.05). Patients treated with OAD had lower tear film BUT values than patients treated with insulin and healthy individuals. The median Schirmer test values were 14mm (1-20mm) in group 1, 16mm (7-21mm)

Table 1 Demographic characteristics of the study subjects

Parameters	Group 1	Group 2	Group 3
Number of subjects	20	20	10
Male	8	6	4
Female	12	14	6
Mean age (a)	53.3 (range, 40– 67)	52.25 (range, 40– 68)	51.57 (range 48– 56)
Median duration of DM (a)	7	6	
No DR	15	11	
NPDR	5	9	

No DR; No diabetic retinopathy; NPDR; Nonproliferative diabetic retinopathy.

in group 2 and 16.50mm (4–20mm) in group 3 (Table 2). Patients treated with OAD had relatively lower Schirmer test values than other groups but the difference was not statistically significant. There was a positive correlation between Schirmer test values and tear film break-up time values among groups. Squamous metaplasia and goblet cell density was graded as described above. The median grade was 1 in all groups. At grade 1, epithelial cells are slightly larger, more polygonal, have eosinophilic staining cytoplasm and goblet cells are decreased in number (Figure 1). Different treatments of DM did not seem to affect the grade of squamous metaplasia and goblet cell density ($P > 0.05$). At subgroup analysis, significant difference was not found in all parameters related with the status of diabetic retinopathy.

DISCUSSION

Several clinical studies have examined ocular surface disorders at diabetic patients reporting a relation between status of metabolic control, peripheral neuropathy, diabetic retinopathy and ocular surface changes^[1–6, 8–10]. In the present study, we assessed tear film BUT, total tear secretion test, and conjunctival impression cytology in diabetic patients treated with either OAD or insulin and compared them with each other and non diabetic control group. A study was performed on rats by M3dulo *et al*^[11] to evaluate whether insulin treatment inhibits ocular surface changes. Five weeks after streptozotocin injection, changes in morphology and increased numbers of lipofuscin – like inclusions were observed in lacrimal glands of diabetic but not insulin – treated rats. Impression cytology from control, diabetic, and diabetic insulin–treated rats ($n = 5–10$ /group) was performed. Data did not differ significantly among the three groups. At the fifth week, tear secretion measured by the Schirmer test was (2.5 ± 1.1)mm in diabetic rats, (5.3 ± 0.3)mm in diabetic insulin–treated rats, and (8.0 ± 0.6)mm in controls ($P = 0.03$). Our study also showed no difference at impression cytology, and slightly high Schirmer test outcomes with insulin treatment. Zagonet *al*^[12] studied corneal reepithelialization in diabetic rats. Intensive therapy with insulin prevented the delay in wound healing of ocular surface epithelium observed in poorly controlled diabetic animals. Insulin therapy, maintaining blood

Table 2 Results of tear film BUT and Schirmer test

Parameters	Group 1	Group 2	Group 3
Tear film BUT (s)	7 (2–15)	10 (2–18)	10.5 (4–15)
Schirmer test (mm)	14 (1–20)	16 (7–21)	16.5 (3–20)

Values are median (minimum–maximum); Tear film BUT; break-up time.

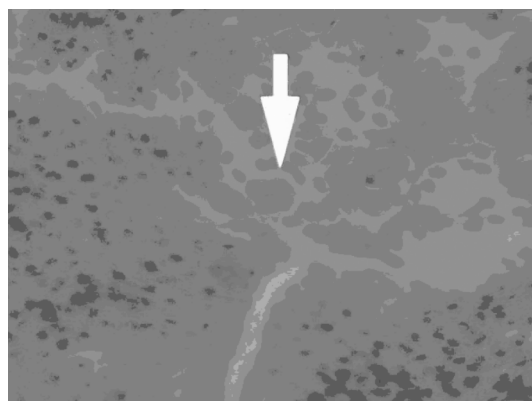


Figure 1 Epithelial cells at grade 1.

glucose concentrations close to the normal range, may also prevent ocular surface disorders in diabetic patients. The outer lipid layer of tear film, which is produced primarily by the meibomian glands, improves the stability of the tear film and increases tear break up time. In our study, tear film BUT was found to be significantly lower in patients treated with OAD. Inoue *et al*^[2] also found that tear film break-up time was lower and the tear lipid layer was less uniform in diabetic patients. Regulation of meibomian gland secretion is not known clearly but neural (parasympathetic system) and hormonal (androgen sex steroids) mechanisms seem to be important. Poor regulation of blood glucose with oral medical treatment may influence the innervation of the meibomian gland adversely. The middle aqueous layer of tear film contains various proteins. Herber *et al*^[4] studied tear protein patterns of diabetic patients. They reported that composition of tear proteins are different from healthy subjects. Yu *et al*^[6] reported lower concentrations of lactoferrin and tear-specific prealbumin at patients with proliferative diabetic retinopathy when compared with patients with non-proliferative diabetic

retinopathy. Diabetic retinopathy status is not seem to relate with precorneal tear film stability, total tear film secretion and conjunctival cytologic changes according to our study. Dogru at al. also found that status of retinopathy did not affect ocular surface disorders^[1]. But Yoon *et al*^[5] found statistical difference at total tear secretion test between patients having no diabetic retinopathy and non - proliferative diabetic retinopathy. They suggested that the decrease in total tear secretion may be the first change of tear film when diabetic retinopathy progresses. Figueroa-Ortiz *et al*^[13] also revealed that 83.3% of conjunctival cytologies of diabetic patients with nonproliferative diabetic retinopathy exhibit a squamous metaplasia grade of 0 or 1; in contrast, 69.24% of patients with proliferative diabetic retinopathy exhibit a grade of 2, 3 or 4.

Goblet cell secretion is stimulated by activation of sensory nerves in the cornea and conjunctiva. Impression cytology reveals conjunctival squamous metaplasia and goblet cell density values. At diabetes patients, treated either OAD or insulin, goblet cells were slightly decreased and minimal changes occurred at conjunctival epithelial cells.

In conclusion, Schirmer test values, conjunctival squamous metaplasia and goblet cell density were similar in all groups but tear film BUT were significantly lower with OAD treatment. Therefore, different treatment modalities of DM may affect precorneal tear film stability but not affect total tear secretion and conjunctival cytologic analysis.

REFERENCES

1 Dogru M, Katakami C, Inoue M. Tear function and ocular surface changes in noninsulin - dependent diabetes mellitus. *Ophthalmology* 2001;108(3):586-592

2 Inoue K, Kato S, Ohara C, Numaga J, Amano S, Oshika T. Ocular and systemic factors relevant to diabetic keratoepitheliopathy. *Cornea* 2001;20(8):798-801

3 Sánchez Thorin J. The cornea in diabetes mellitus. *Int Ophthalmol Clin* 1998;38(2):19-36

4 Herber S, Grus FH, Sabuncuo P, Augustin AJ. Two - dimensional analysis of tear protein patterns of diabetic patients. *Electrophoresis* 2001;22(9):1838-1844

5 Yoon KC, Im SK, Seo MS. Changes of tear film and ocular surface in diabetes mellitus. *Korean J Ophthalmol* 2004;18(2):168-174

6 Yu L, Chen X, Qin G, Xie H, Lv P. Tear film function in type 2 diabetic patients with retinopathy. *Ophthalmologica* 2008;222(4):284-291

7 Arici MK, Arici DS, Topalkara A, Güler C. Adverse effects of topical antiglaucoma drugs on the ocular surface. *Clin Experiment Ophthalmol* 2000;28(2):113-117

8 Nepp J, Abela C, Polzer I, Derbolav A, Wedrich A. Is there a correlation between the severity of diabetic retinopathy and keratoconjunctivitis sicca? *Cornea* 2000;19(4):487-491

9 Ozdemir M, Büyükbese MA, Cetinkaya A, Ozdemir G. Risk factors for ocular surface disorders in patients with diabetes mellitus. *Diabetes Res Clin Pract* 2003;59(3):195-199

10 Goebbels M. Tear secretion and tear film function in insulin dependent diabetics. *Br J Ophthalmol* 2000;84(1):19-21

11 Módulo CM, Jorge AG, Dias AC, Braz AM, Bertazzoli - Filho R, Jordão AA Jr, Sérgio Marchini J, Rocha EM. Influence of insulin treatment on the lacrimal gland and ocular surface of diabetic rats. *Endocrine* 2009;36(1):161-168

12 Zagon IS, Sassani JW, McLaughlin PJ. Insulin treatment ameliorates impaired corneal reepithelialization in diabetic rats. *Diabetes* 2006;55(4):1141-1147

13 Figueroa-Ortiz LC, Jiménez Rodríguez E, García-Ben A, García-Campos J. Study of tear function and the conjunctival surface in diabetic patients. *Arch Soc Esp Ophthalmol* 2011;86(4):107-112