

抗青光眼术后白内障行超声乳化术的临床观察

李莉, 杨珂, 玉光珏

基金项目: 广西科技厅科技攻关项目 (No. 桂科攻 1355005-5-4)
作者单位: (530021) 中国广西壮族自治区南宁市, 广西壮族自治区人民医院眼科
作者简介: 李莉, 女, 硕士, 主任医师, 硕士研究生导师, 研究方向: 白内障、青光眼。
通讯作者: 李莉. lily21cn@189.com
收稿日期: 2013-05-15 修回日期: 2013-08-19

Clinical observation of phacoemulsification in patients with previous trabeculectomy

Li Li, Ke Yang, Guang-Jue Yu

Foundation item: Department of Science and Technology Research Project of Guangxi Zhuang Autonomous Region (No. 1355005-5-4) Department of Ophthalmology, People's Hospital of Guangxi Zhuang Autonomous Region, Nanning 530021, Guangxi Zhuang Autonomous Region, China

Correspondence to: Li Li. Department of Ophthalmology, People's Hospital of Guangxi Zhuang Autonomous Region, Nanning 530021, Guangxi Zhuang Autonomous Region, China. lily21cn@189.com
Received: 2013-05-15 Accepted: 2013-08-19

Abstract

• **AIM:** To observe the clinical effect of transparent corneal incision phacoemulsification in cataract patients who had undergone different kinds of glaucoma filtration surgeries.

• **METHODS:** Totally 43 cases (50 eyes), in which 23 patients with primary angle-closure glaucoma (group A, 26 eyes) and 20 patients with primary open angle glaucoma (group B, 24 eyes), all had undergone glaucoma filtration surgery for more than 6 months. Visual acuity, intraocular pressure, slit lamp, gonioscope, corneal endothelial cell counts, etc., were done before surgery. And transparent corneal incision phacoemulsification combined with artificial lens implantation operation were performed, postoperative follow-up of 3 to 12 months, visual acuity, intraocular pressure, corneal endothelial cell counts and vision field, etc. were observed and recorded.

• **RESULTS:** The visual acuity of 50 eyes (100%) increased with different degree postoperatively, 41 eyes (82%) with postoperative visual acuity ≥ 0.3 ; average preoperative intraocular pressure: group A 18.08 ± 5.08 mmHg (1 mmHg = 0.133 kPa), group B 14.48 ± 3.52 mmHg; Postoperative follow-up average intraocular pressure: group A 13.65 ± 3.51 mmHg, group B 14.28 ± 3.41 mmHg, intraocular pressure changed significantly pre and post-operation in group A ($P < 0.05$), there was no significant difference between pre and post-operation in group B ($P >$

0.05); Postoperative intraocular pressure of 1 eye in group A and 3 eyes in group B rose within three days post-operation, the intraocular pressure fluctuated between 21-33 mmHg, with drug therapy and drug withdrawal when intraocular pressure epistrophy; Intraocular pressure was stable in the follow-up process. Corneal endothelial cell density: pre-operation group A was 2293.57 ± 352.24 (cells/mm²), group B 2658.14 ± 458.69 (cells/mm²), post-operation group A 2175.95 ± 379.16 (cells/mm²), group B 2442.97 ± 477.30 (cells/mm²), cell loss rate: 5.13% in group A, and 8.10% in group B. Postoperative visual acuity was related to vision field damage in patients, the more visual field damage, the longer the duration.

• **CONCLUSION:** Visual function restore is stable in transparent corneal incision phacoemulsification in cataract patients who underwent glaucoma filtration surgeries; the intraocular pressure can be controlled effectively, and can further reduce the intraocular pressure of angle-closure glaucoma. Preoperative comprehensive evaluation of the affected eye and appropriate technique selection are benefit to the improvement of operation effect and the reduction of complications.

• **KEYWORDS:** phacoemulsification; cataract; glaucoma surgery

Citation: Li L, Yang K, Yu GJ. Clinical observation of phacoemulsification in patients with previous trabeculectomy. *Guoji Yanke Zazhi (Int Eye Sci)* 2013;13(9):1769-1771

摘要

目的: 观察不同类型青光眼滤过手术后白内障患者行透明角膜切口白内障超声乳化术的临床效果。

方法: 患者 43 例 50 眼, 其中原发性闭角型青光眼患者 (A 组) 23 例 26 眼, 原发性开角型青光眼患者 (B 组) 20 例 24 眼, 均为青光眼滤过术后 6mo 以上的白内障患者; 术前行视力、眼压、裂隙灯、前房角镜及角膜内皮细胞计数等检查。予行透明角膜切口白内障超声乳化联合人工晶状体植入手术, 术后随访 3 ~ 12mo, 观察记录视力、眼压、角膜内皮细胞计数及视野等。

结果: 患者 50 眼 (100%) 术后视力均有不同程度提高, 41 眼 (82%) 术后视力 ≥ 0.3 ; 术前平均眼压, A 组 18.08 ± 5.08 mmHg (1 mmHg = 0.133 kPa), B 组 14.48 ± 3.52 mmHg; 术后随访平均眼压, A 组 13.65 ± 3.51 mmHg, B 组 14.28 ± 3.41 mmHg, A 组手术前后眼压变化明显 ($P < 0.05$); B 组手术前后眼压变化均无统计学差异 ($P < 0.05$); A 组 1 眼和 B 组 3 眼术后 3d 内眼压升高, 眼压波动在 21 ~ 33 mmHg, 经药物治疗恢复正常并停药; 随访过程中眼压稳定。角膜内皮细胞密度: 术前 A 组 2293.57 ± 352.24 cells/mm², B 组

2658.14±458.69cells/mm²,术后A组2175.95±379.16 cells/mm²,B组2442.97±477.30cells/mm²;细胞丢失率:A组5.13%,B组8.10%;术后视力恢复时间与患者视野损害程度有关,视野损害严重者视力恢复时间长。

结论:透明角膜切口白内障超声乳化术治疗青光眼滤过手术后白内障视功能恢复稳定,眼压能有效控制,并能进一步降低闭角型青光眼的眼压。术前对患眼全面评价及适当的手术技巧有助于手术效果的提高且减少并发症的发生。

关键词:超声乳化;白内障;抗青光眼手术
DOI:10.3980/j.issn.1672-5123.2013.09.08

引用:李莉,杨珂,玉光珏.抗青光眼术后白内障行超声乳化术的临床观察.国际眼科杂志2013;13(9):1769-1771

0 引言

白内障及青光眼均为常见致盲眼病。抗青光眼术后白内障患者在临床上比较常见,由于其病情较为复杂,除了存在青光眼的视神经损害,常合并角膜内皮损伤、浅前房、瞳孔变形僵直、虹膜粘连、晶状体核硬及悬韧带的损伤等^[1,2],给白内障手术增加了很大困难,对白内障术后视功能的评估也增加复杂而不确定的因素。为客观评价抗青光眼术后白内障手术的临床疗效,改善手术治疗效果,我们通过对照研究不同类型青光眼术后的白内障患者施行透明角膜切口超声乳化白内障吸除联合人工晶状体植入手术后的临床效果,报告如下。

1 对象和方法

1.1 对象 选择2009-02/2012-12在广西人民医院眼科行透明角膜切口超声乳化白内障吸除联合人工晶状体植入治疗抗青光眼术后白内障的连续病例43例50眼,其中原发性闭角型青光眼患者(A组)23例26眼,原发性开角型青光眼患者(B组)20例24眼,均为青光眼滤过术后1~20a的白内障患者;女33例38眼,男10例12眼;术前视力为眼前/手动~0.25,年龄53~81(平均73.03)岁;所有患者晶状体混浊程度不同,但均为超声乳化白内障吸除术的适应证。

1.2 方法

1.2.1 手术方法 所有手术为同一操作熟练的手术者完成,爱尔卡因表面麻醉后作长为2.2mm的隧道式透明角膜切口和辅助切口,前房注入黏弹剂,连续环形撕囊,使用爱尔康公司的Alcon Infiniti超声乳化仪行原位乳化劈核术,由自动灌注、抽吸系统清除晶状体皮质,囊袋内植入单片疏水性丙烯酸折叠型人工晶状体。术中对浅前房及有虹膜粘连的患者先以黏弹剂形成前房,并分离粘连之虹膜,再行进一步的操作。植入人工晶状体前以黏弹剂注入囊袋内同时全周分离前房角;对于瞳孔固定,直径小于4mm者,以眼内剪剪开3:00,6:00,8:00之瞳孔缘一定程度扩大瞳孔。随后充分吸除黏弹剂,完成手术时注意检查眼压,避免前房压力过高。

1.2.2 术后处理 手术结束时结膜囊涂以妥布霉素地塞米松眼膏,无须结膜下注药。术后第1d开始用氯替泼诺+左氧氟沙星滴眼液,每2h1次,1wk后减为qid,睡前用妥布霉素地塞米松眼膏。视炎症情况可持续1~2mo,眼压高的患者加用噻吗酰胺滴眼液bid,至眼压稳定。

表1 两组患者手术前后眼压变化 ($\bar{x}\pm s$,mmHg)

分组	术前眼压	术后眼压	t	P
A组	18.08±4.08	13.65±3.51	3.6810	0.0007
B组	14.48±3.52	14.25±3.41	0.1290	0.8988

表2 手术前后角膜内皮细胞损伤情况

分组	角膜内皮细胞密度($\bar{x}\pm s$,cells/mm ²)		细胞丢失率(%)
	术前	术后	
A组	2293.57±352.24	2175.95±379.16	5.13
B组	2658.14±458.69	2442.97±477.30	8.10

1.2.3 随访 随访时间3mo~3a,平均12±9mo,随访期间主要观察术后视力、眼压、视野及术后并发症,并以最后一次随访资料作为统计分析的数据。部分患者进行超声生物显微镜检查以观察手术前后前房变化。

统计学分析:应用SPSS 10.0软件统计分析,计量资料采用 $\bar{x}\pm s$ 表示,组间比较采用两均数t检验。 $P<0.05$ 为差异有统计学意义。

2 结果

2.1 术后视力 患者50眼(100%)术后视力均有不同程度提高,41眼(82%)术后随访视力 ≥ 0.3 ;术后视力恢复与青光眼性视神经损害有关,视野损害显示晚期青光眼者视力恢复缓慢,A组1例患者术后第1d视力0.2,视野检查为管状视野,1mo后视力恢复到1.0,随后的随访中视力、视野稳定。

2.2 眼压变化 两组患者手术前后眼压变化见表1。A组1眼和B组3眼术后3d内眼压升高,眼压波动在21~33mmHg,经药物治疗恢复正常并停药;随访过程中眼压稳定。

2.3 角膜内皮细胞损伤情况 手术前后角膜内皮细胞密度和细胞丢失率见表2。

2.4 前房深度及前房角变化 通过UBM对部分患者的检查,术前A组前房较B组浅,术后两组前房深度相似,A组手术后前房角变化明显,见图1~3。

3 讨论

透明角膜切口超声乳化白内障吸除术治疗抗青光眼术后白内障可避开原手术区域,保护原有滤过泡功能^[3-5];同时因手术为闭合式,能有效减少组织损伤、加深前房深度及开放前房角^[6,7]。我们通过对不同类型青光眼术后的白内障患者在行超声乳化白内障吸除术后的眼压变化,结果显示,原发性闭角型青光眼组术后眼压较术前有显著性降低($P<0.05$)。提示在原发性闭角型青光眼的过程中,晶状体是重要的解剖因素。眼压下降的机制可能与晶状体摘除后眼前段内容减少、前房加深、房角开放有关^[8-10];另外,超声乳化白内障吸除术为闭合式手术,结合手术中以黏弹剂分离前房角,亦可使前房角再度开放或粘连减少^[11,12]。这可以为今后对抗青光眼术后白内障患者的手术时机提供参考,对于眼压控制不满意的患者行白内障手术可进一步降低其眼压。此外,我们通过对比两组手术前后角膜内皮细胞的丢失情况,丢失率分别为A组5.13%,B组8.10%,内皮损伤没有因手术的复杂性增加^[13-15],可能与手术过程采用适当的技巧及保护措施有关。术中采用适当的手术技巧,如前房维持、前房角分离等将有助于手术效果的提高,且减少并发症的发生。

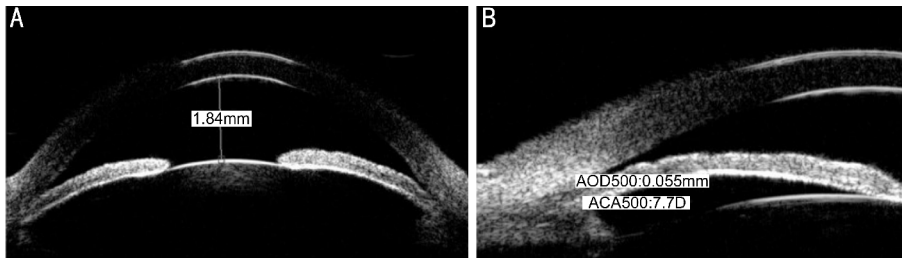


图1 术前A组前房深度和前房角情况 A:前房深度;B:前房角。

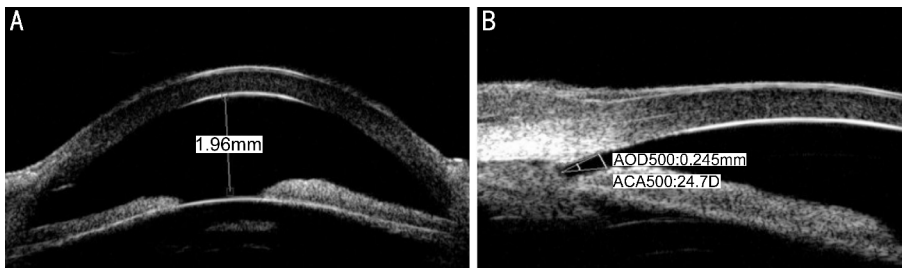


图2 术前B组前房深度和前房角情况 A:前房深度;B:前房角。

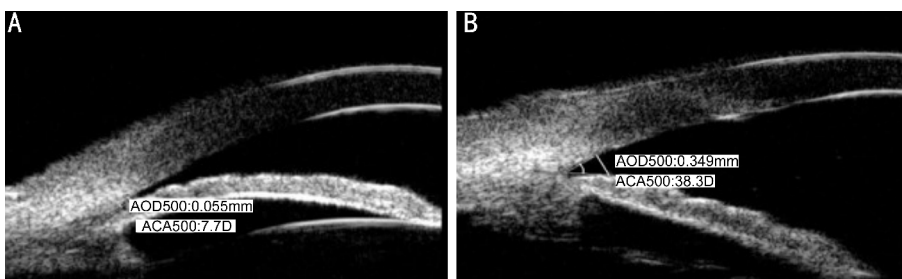

图3 手术前后A组前房角变化 A:术前;B:术后。

对于手术后前房的变化及与眼压的关系,我们正在进行进一步的研究。因此,我们认为透明角膜切口白内障超声乳化术治疗青光眼滤过手术后白内障视功能恢复稳定,眼压能有效控制,并能进一步降低闭角型青光眼的眼压。术前对患眼全面评价及适当的手术技巧有助于手术效果的提高,且减少并发症的发生。

参考文献

- 1 Kahraman G, Amon M, Franz C, et al. Intraindividual comparison of surgical trauma after bimanual microincision and conventional small-incision coaxial phacoemulsification. *J Cataract Refract Surg* 2007;33(4):618-622
- 2 Hayashi K, Yoshida M, Manabe S, et al. Cataract surgery in eyes with low corneal endothelial cell density. *J Cataract Refract Surg* 2011;37(8):1419-1425
- 3 刘奕志,葛坚,程冰.抗青光眼滤过术后超声乳化白内障吸除术的临床观察. *中华眼科杂志* 2000;36(6):435-437
- 4 张卫忠,李丽,管永清,等.青光眼前术后超声乳化白内障吸除术. *中华眼科杂志* 2001;37(1):66-67
- 5 李绍珍. *眼科手术学*.北京:人民卫生出版社 2000;373-435
- 6 Inal A, Bayraktar S, Inal B, et al. Intraocular pressure control after clear phacoemulsification in eyes with previous trabeculectomy: a controlled study. *Acta Ophthalmol Scand* 2005;83(5):554-560
- 7 Kim M, Park KH, Kim TW, et al. Anterior chamber configuration changes after cataract surgery in eyes with glaucoma. *Korean J*

Ophthalmol 2012;26(2):97-103

- 8 Dada T, Mohan S, Sihota R, et al. Comparison of ultrasound biomicroscopic parameters after laser iridotomy in eyes with primary angle closure and primary angle closure glaucoma. *Eye (Lond)* 2007;21(7):956-961
- 9 Zhuo YH, Wang M, Li Y, et al. Phacoemulsification treatment of subjects with acute primary angle closure and chronic primary angle-closure glaucoma. *J Glaucoma* 2009;18(9):646-651
- 10 Mathalone N, Hyams M, Neiman S, et al. Long-term intraocular pressure control after clear corneal phacoemulsification in glaucoma patients. *J Cataract Refract Surg* 2005;31(3):479-483
- 11 Zhao Y, Li X, Tao A, et al. Intraocular pressure and calculated diastolic ocular perfusion pressure during three simulated steps of phacoemulsification *in vivo*. *Invest Ophthalmol Vis Sci* 2009;50(6):2927-2931
- 12 Khng C, Packer M, Fine IH, et al. Intraocular pressure during phacoemulsification. *J Cataract Refract Surg* 2006;32(2):301-308
- 13 姚克,王玮,吴炜,等.同轴1.8mm微切口超声乳化白内障手术临床效果评价. *中华眼科杂志* 2011;47(10):903-907
- 14 Millá E, Vergés C, Ciprés M. Corneal endothelium evaluation after phacoemulsification with continuous anterior chamber infusion. *Cornea* 2005;24(3):278-282
- 15 Claesson M, Armitage WJ, Stenevi U. Corneal oedema after cataract surgery: predisposing factors and corneal graft outcome. *Acta Ophthalmol* 2009;87(2):154-159