

Effect of stenting and mucosal flap preservation on outcome of endoscopic dacryocystorhinostomy

Evelyn Tai Li Min^{1,2}, Jessica Mani Penny Tevaraj^{1,2}, Wan Hazabbah Wan Hitam^{1,2}, Ramiza Ramza^{2,3}, Baharudin Abdullah^{2,3}, Adil Hussein^{1,2}

Foundation item: Incentive Grant from Universiti Sains Malaysia

¹Department of Ophthalmology, School of Medical Sciences, Health Campus Universiti Sains Malaysia, Kubang Kerian, Kelantan 16150, Malaysia

²Hospital Universiti Sains Malaysia, Kubang Kerian, Kelantan 16150, Malaysia

³Department of Otolaryngology, School of Medical Sciences, Health Campus Universiti Sains Malaysia, Kubang Kerian, Kelantan 16150, Malaysia

Correspondence to: Evelyn Tai Li Min. Department of Ophthalmology, School of Medical Sciences, Health Campus, Universiti Sains Malaysia, Kubang Kerian, Kelantan 16150, Malaysia. daileid@yahoo.com

Received: 2013-09-14 Accepted: 204-01-20

支架植入和黏膜瓣保留对鼻内镜下泪囊鼻腔吻合术结果的影响

Evelyn Tai Li Min^{1,2}, Jessica Mani Penny Tevaraj^{1,2}, Wan Hazabbah Wan Hitam^{1,2}, Ramiza Ramza^{2,3}, Baharudin Abdullah^{2,3}, Adil Hussein^{1,2}

基金项目:马来西亚理科大学资助项目

(作者单位:¹马来西亚,吉兰丹 16150,古邦阁亮区,马来西亚理科大学保健学院,医学科学学院眼科系;²马来西亚,吉兰丹 16150,古邦阁亮区,马来西亚理科大学校医院;³马来西亚,吉兰丹 16150,古邦阁亮区,马来西亚理科大学保健学院,耳鼻喉系)

通讯作者:Evelyn Tai Li Min. daileid@yahoo.com

摘要

目的:研究支架植入术和黏膜瓣保留对鼻内镜下泪囊鼻腔吻合术结果的影响。

方法:回顾性分析 2007~2011 年间在马来西亚理科大学校医院所有行鼻内镜下泪囊鼻腔吻合术病例。25 例鼻泪管阻塞患者参与此研究。术后 1,6,12mo,通过泪溢症状缓解、泪道冲洗通畅、鼻内窥镜下造瘘口通畅三个标准来评估手术结果。术后 1a 内三个标准都通过时手术才算成功。采用多元逻辑回归分析研究支架植入和黏膜瓣保留与手术成功率之间的关系。

结果:25 例患者中 13 例采用支架植入术,此方法同样适用于黏膜瓣保留。术后 1a 内鼻内镜下泪囊鼻腔吻合术的成功率是 64%。支架植入与否与术后成功率之间的无关联($P=0.694$),然而黏膜瓣保留能有效提高手术成功率(调整后 $OR=7.926$; 95% CI : 1.172~53.620, $P=0.034$)。术后主要并发症为局部粘连,50% 的病例有此症状表现。

支架植入或黏膜瓣保留与并发症之间无关联。

结论:在鼻泪管阻塞治疗中,鼻内镜下泪囊鼻腔吻合术成功率与黏膜瓣保留有着重大的关系,而与支架植入无关。支架植入和黏膜瓣保留与并发症发生率无关。

关键词:泪囊鼻腔吻合术;内视镜检查法;鼻泪管阻塞;黏膜瓣;支架植入术

引用:Evelyn-Tai LM, Jessica MPT, Wan-Hazabbah WH, Ramiza R, Baharudin A, Adil H. 支架植入和黏膜瓣保留对鼻内镜下泪囊鼻腔吻合术结果的影响. 国际眼科杂志 2014;14(3):381-385

Abstract

• **AIM:** To determine the effect of stenting and flap preservation on the outcome of endoscopic dacryocystorhinostomy.

• **METHODS:** Retrospective study of all endoscopic dacryocystorhinostomy cases performed between 2007 - 2011 at Hospital Universiti Sains Malaysia. A total of 25 cases with nasolacrimal duct obstruction underwent this procedure. Outcome of endoscopic dacryocystorhinostomy was evaluated based on relief of epiphora and anatomical patency by lacrimal syringing and nasal endoscopy upon follow-up at 1, 6 and 12 months post-op. The outcome was considered to be successful only if all three criteria were fulfilled at one year follow-up post-op. Multiple logistic regression was used to determine the association of stenting and flap creation with a successful outcome.

• **RESULTS:** Stents were inserted in 13 cases out of 25, and likewise for flaps. The success rate of endoscopic dacryocystorhinostomy at one year post-op was 64%. There was no significant association of stenting with outcome ($P=0.694$), whereas mucosal flap creation was significantly associated with a better outcome (adjusted $OR=7.926$; 95% CI : 1.172-53.620, $P=0.034$). The main post-operative complication was adhesions, which occurred in 50% of cases. There was no significant association between stenting or flap preservation with complications.

• **CONCLUSION:** Preservation of a mucosal flap is significantly associated with a successful outcome of endoscopic dacryocystorhinostomy in nasolacrimal duct obstruction, while stenting is not. Neither stenting nor mucosal flap creation is significantly associated with complications.

• **KEYWORDS:** dacryocystorhinostomy; endoscopy; lacrimal duct obstruction; surgical flaps; stent

DOI:10.3980/j.issn.1672-5123.2014.03.01

Citation: Evelyn-Tai LM, Jessica MPT, Wan-Hazabbah WH, Ramiza R, Baharudin A, Adil H. Effect of stenting and mucosal flap preservation on outcome of endoscopic dacryocystorhinostomy. *Guoji Yanke Zazhi (Int Eye Sci)* 2014;14(3):381-385

INTRODUCTION

Although the endoscope was invented for more than two centuries, it is only in the last few decades that endoscopic dacryocystorhinostomy (EDCR) has become increasingly popular as an alternative to external dacryocystorhinostomy^[1-5].

Since its introduction by Caldwell^[6] in 1893, various modifications of the technique of EDCR have been performed in the endeavour to achieve reproducible rates of successful outcome^[7,8]. One issue being debated over the years concerns the practice of silicone intubation in EDCR^[9,10]. Although in earlier years, stenting was believed to confer a more favourable prognosis on the outcome of EDCR, the last decade has been characterised by studies that advocate EDCR without stenting, contending that there is no added benefit to be gained by routine silicone intubation^[11-14].

A similar development has arisen in the case of mucosal flap creation, where proponents of this technique suggest that it plays a role in preventing failure of EDCR *via* inhibition of ostium closure^[15-17]. However, dissidents assert that there is no significant difference in the outcome of EDCR even without flap preservation^[18-21].

Over the years, as the popularity of different methods waxed and waned, various ways of performing EDCR have been used in our center. Faced with the predicament of choosing the best technique to employ among our patients, we have reviewed all EDCR cases performed in our centre over the last 5 years. Our aim was to determine the effect of stenting and flap preservation on the outcome of endoscopic dacryocystorhinostomy. Our results are presented below.

SUBJECTS AND METHODS

Subjects Retrospective review of medical records of all EDCR cases for nasolacrimal duct obstruction (NLDO) performed in Hospital Universiti Sains Malaysia between 2007 and 2011. Preoperatively, all patients were thoroughly evaluated by both an ophthalmologist and an otolaryngologist. Presenting symptoms were documented, and patency upon lacrimal probing and syringing assessed. All cases underwent preoperative nasal endoscopy.

Methods Intra-operatively, the procedure was performed under general anaesthesia in the operating theatre by a combined team of ophthalmologists and otolaryngologists. The patient was placed supine, with the head turned slightly to the right side. Decongestant packing (gauze) was placed intranasally, followed by intubation of the canaliculi. A 0 or 30 degree nasal endoscope was used to visualise the area of lacrimal bone. Local anaesthesia was infiltrated at the area anterior to the axilla of the middle turbinate and anterior middle turbinate. Subsequently, the nasal mucous membrane

(10mm by 10mm anterior to the maxillary line) was incised and removed to allow for the creation of a window on the lacrimal sac and upper nasolacrimal duct. A 3 millimetre powered diamond burr was used to remove a portion of the lacrimal and maxilla bone at this stage. The lacrimal probe was inserted *via* one of the canaliculi and used to tent the medial wall of the lacrimal sac in the nasal cavity. Visualisation of the tenting was used to guide the incision in the lacrimal sac and nasolacrimal duct, and then the system was flushed to check patency. The main modifications to this standard technique were preservation of nasal and lacrimal sac mucosal flaps, and insertion of a stent at the end of the procedure, according to the surgeon's preference. Postoperatively, patients were placed on topical antibiotics and steroids, as well as nasal steroid spray and oral antihistamines. Daily syringing with normal saline was also performed for the first few days after EDCR.

Outcome of EDCR was evaluated based on relief of epiphora and anatomical patency by lacrimal syringing and nasal endoscopy upon follow up at 1, 6 and 12 months post EDCR. The outcome was considered to be successful only if all these three criteria were fulfilled at one year follow-up post EDCR.

Statistical Analysis Data was compiled and analysed *via* SPSS v20. Multiple logistic regression was used to determine the association of stenting and flap creation with a successful outcome. A *P*-value of <0.05 was considered statistically significant.

RESULTS

A total of 25 cases of EDCR were performed. The age of patients ranged from 5 to 72 years of age, with the median age being 47 years old. Approximately 70% were female. Seven patients had bilateral nasolacrimal duct obstruction. Table 1 shows the clinical features of the sample group.

In all cases, the patients presented either with isolated eye symptoms (in 72%), or both eye and nasal symptoms. All patients had epiphora, with or without lid swelling, while the nasal complaints, which were only present in 7 patients, were of rhinorrhoea (4 patients) or nasal congestion (3 patients). Forty percent of the sample had no significant past history, while the remainder had a history of recurrent dacryocystitis, septorhinoplasty or functional endoscopic sinus surgery.

Preoperative nasal endoscopy detected abnormalities in 72% (18 cases), the major abnormality (in 17 out of 18 cases) being a deviated nasal septum, which was associated with inferior turbinate hypertrophy in 7 cases. Among those with septal deviation, 14 had unilateral nasolacrimal duct obstruction, which occurred on the same side as that of the septal deviation in all cases except one.

Stents were inserted in approximately 50% of cases, and likewise for flaps (Tables 2,3). The stent was dislodged in only one case, and the duration of retaining the stent varied from less than 2 months until up to a year. There was no significant association of stenting with outcome of EDCR, unlike in the case of mucosal flaps, where the latter was significantly associated with a better outcome. After controlling

Table 1 Clinical features of the sample group *n*=25(%)

Variable	Cases
Laterality of NLDO	
Unilateral right NLDO	11 (44.0)
Unilateral left NLDO	7 (28.0)
Bilateral NLDO	7 (28.0)
Presenting symptoms	
Eye symptoms only	18 (72.0)
Both eye and nasal symptoms	7 (28.0)
Presenting eye symptoms	
Epiphora	14 (56.0)
Epiphora, discharge and lid swelling	11 (44.0)
Endoscopic findings	
No abnormality detected	7(28.0)
Deviated nasal septum only	10 (40.0)
Deviated nasal septum with inferior turbinate hypertrophy	7(28.0)
Inferior turbinate hypertrophy only	1 (4.0)
Significant history	
None	10 (40.0)
Dacryocystitis	7(28.0)
Septorhinoplasty	4(16.0)
Functional endoscopic sinus surgery	4 (16.0)

NLDO: Nasolacrimal duct obstruction.

Table 2 Outcome and complications categorized by presence of stent

Variable	Cases stented <i>n</i> =13(%)	Cases not stented <i>n</i> =12(%)
Outcome		
Successful	8 (61.5)	8 (66.7)
Failed	5 (38.5)	4 (33.3)
Complications		
None	4 (30.8)	5 (41.7)
Adhesions	6 (46.1)	7 (58.3)
Sump syndrome	1 (7.7)	0
Granuloma	2 (15.4)	0

Table 3 Outcome and complications categorized by presence of flap

Variable	Cases with flap <i>n</i> =13(%)	Cases without flap <i>n</i> =12(%)
Outcome		
Successful	11 (84.6)	5 (41.7)
Failed	2 (15.4)	7 (58.3)
Complications		
None	5 (38.5)	4 (33.3)
Adhesions	7 (53.8)	6 (50.0)
Sump syndrome	1 (7.7)	0
Granuloma	0	2 (16.7)

for the presence of a stent, we found that retention of a flap was still significantly associated with a successful outcome (OR=7.926; 95% CI: 1.172–53.620, Table 4).

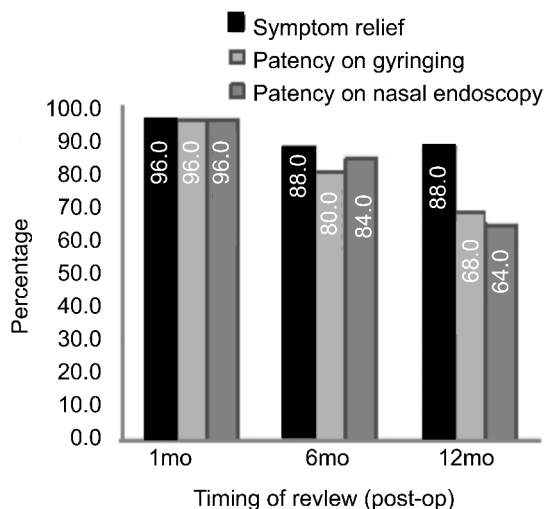
Intra-operatively, no complications occurred, while post-operatively, the main complications were adhesions, which occurred in about half of the cases performed. Fortunately, most of these adhesions were easily removed *via* nasal endoscopy upon follow-up, and thus did not significantly

Table 4 Association of stent/flap with outcome

Variable	Adjusted odds ratio [OR] (95% CI)	<i>P</i> (<0.05 is significant)
Stent	0.690 (0.109, 4.375)	0.694
Flap	7.926 (1.172, 53.620)	0.034

Table 5 Association of stent/lap with complications

Variable	Adjustedodds ratio [OR] (95% CI)	<i>P</i> (<0.05 is significant)
Stent	1.625 (0.312, 8.457)	0.564
Flap	0.783 (0.15, 4.088)	0.771

**Figure 1 Outcome at 1, 6 and 12 months post-EDCR.**

impact the outcome of EDCR. One patient had transient epistaxis post-op, which resolved quickly after application of icepacks, and was not included in our list of post-operative complications. The only other complications documented were Sump syndrome and granuloma formation, both of which occurred in patients who had stents inserted. However, after controlling for the presence of a stent or a flap, we found no significant association between either stenting or flap preservation with complications (Table 5).

In 48% of all EDCR cases, relief of symptoms occurred within 1 week post EDCR. However, upon follow-up at 1 month, 6 and 12 months post-op, we noted a fall in the initial success rate of 96.0%, which plateaued at a final overall success rate of 64.0% at one year post-EDCR (Figure 1). Of the remaining failed cases, 77.8% underwent revision surgery later on.

DISCUSSION

The overall success rate of primary EDCR in our study was 64%, which compares rather unfavourably with those documented in other studies, which have ranged from about 75% to 90%, and even achieved success rates of approximately 96% in certain studies^[3-5,22]. However, there were slight variations between the methods of surgery performed in different studies, which may have a bearing on the outcome of EDCR. Another reason for our low reported rates of success is that being a tertiary education centre for the

whole of Malaysia, our surgeries were performed by a motley collection of surgeons—in-training. Some of whom may have been just taking their baby steps in this field.

Despite the initial unpromising outcome of EDCR, the improvement in the success rate over the years is not unexpected, as our practitioners gain familiarity with the relevant surgical anatomy and techniques available^[23]. The rate of complications parallels the learning curve afflicting any surgeon prior to mastery of a new technique, especially the fine skill of endoscopic surgery^[24,25]. Although at this point in time, our rates of success still compare unfavourably with those reported in most other studies in this field, we hope that with continued exposure to the endoscopic procedures, our practitioners will gradually acquire the necessary expertise in this rapidly developing field.

Our pre-operative endoscopy finding of nasal septal deviation, when present, generally occurring on the same side as that of the nasolacrimal duct obstruction, is comparable to that of a recent study which found that unilateral nasolacrimal duct obstruction appears to occur on the side in which the nasal septum is deviated^[26]. The relevance of noting nasal septal deviation preoperatively is that it has been found to be the most common nasal anomaly causing operative difficulty in EDCR^[27]. Preoperative knowledge of the potential difficulties to be encountered in a planned surgery can assist the surgeon in planning the appropriate approach. In our series, in which only primary EDCR was performed, septoplasty was occasionally required during the revision surgeries for cases of failed EDCR.

Complications of EDCR noted in other studies include synechiae, excessive granulation tissue formation, punctual granuloma, sump syndrome and epistaxis^[28-30]. Although a high proportion (13 out of 25) of our cases developed adhesions, these did not affect the patency of the opening, and were easily removed during routine post-operative follow-up, except in three patients who experienced failure of EDCR due to adhesions between the lateral nasal wall and the middle turbinate. The one patient in our series who developed a granuloma also experienced failure caused by granulation tissue blocking the stent. Onerci *et al*^[31] noted that the most common causes of EDCR failure include granulation tissue formation around the tubes and synechiae between the lateral wall and middle turbinate.

Regarding silicone intubation, a recent review summed up the current state of affairs by noting that the evidence base either in favour of or against the practice of routine intubation remains lacking. On one hand, pro-stenting studies have claimed that the best EDCR results are achieved by stenting^[10,11], while on the other, some studies have noted that performing primary EDCR without stenting can achieve similar success rates as external DCR, and that there is no difference in the surgical outcome between stented and non-stented cases^[12,32-34]. Considering the advantages of shorter operative time and reduced stent-related costs and complications, Unlu *et al*^[12] has recommended EDCR without

intubation as the gold standard of treatment for chronic epiphora due to nasolacrimal duct obstruction. In cases of EDCR for canalicular obstruction, however, stenting is still advocated^[31,35]. In our study, which involved patients with post-saccal stenosis of the lacrimal drainage system, we tend to concur with the results of a recent meta-analysis of primary dacryocystorhinostomy, in which no benefit was found for silicone tube intubation^[36].

In the matter of lacrimal sac flaps, there are diverse studies describing different techniques of flap creation^[37-41]. One of the limitations of our study is that because of a small sample size and the diversity of techniques employed in our centre. We were unable to compare the relative statistical advantages of each of those methods. Suffice to say that we found a small but significant association between preservation of a mucosal flap and a successful outcome of EDCR ($P=0.035$). This finding is comparable with that of Yuen *et al*^[38], who noted a statistically significant difference ($P=0.031$) between the outcome of patients who had creation of a flap and those who had their entire medial lacrimal sac wall removed. Although various studies have suggested that flap creation may prevent ostium closure^[18] and decrease formation of granulation tissue^[19], we do not deny that similar rates of success as those obtained in EDCR with flap preservation^[15,40] can also be achieved in EDCR without mucosal flap preservation^[19-21]. We would make haste to add, though, that this is because there are naturally many other factors which may influence the outcome of EDCR, including the operator's endoscopic expertise and experience in the procedure of EDCR.

To conclude, we would advocate making a flap if the technical expertise is available. But if stenting were indicated, we would also consider it an acceptable alternative. We hasten to add that although preservation of a mucosal flap was noted to be significantly associated with a successful EDCR outcome in our series. Beginner surgeons should take into account the technical difficulties and the steep learning curve involved, and should attempt to master the basic skills required before undertaking the added challenge of flap-preserving techniques. We would like to recommend that this study be followed by a prospective, randomized, large-scale study involving a standardized flap creation technique in the interventional group.

REFERENCES

- 1 Morgenstern L. The 200th anniversary of the first endoscope; Philipp Bozzini (1773-1809). *Surg Innov* 2005;12(2):105-106
- 2 Seppa J, Smirnov G, Kaarmiranta K, Tuomilehto H. Surgery for lower nasolacrimal duct obstructions in adults. *Duodecim* 2012;128(2):205-211
- 3 Hartikainen J, Antila J, Varpula M, Puukka P, Seppa H, Grenman R. Prospective randomized comparison of endonasal endoscopic dacryocystorhinostomy and external dacryocystorhinostomy. *Laryngoscope* 1998;108(12):1861-1866
- 4 Dolman PJ. Comparison of external dacryocystorhinostomy with nonlaser endonasal dacryocystorhinostomy. *Ophthalmology* 2003; 110(1):78-84
- 5 Walker RA, Al-Ghoul A, Conlon MR. Comparison of nonlaser nonendoscopic endonasal dacryocystorhinostomy with external

- dacryocystorhinostomy. *Can J Ophthalmol* 2011;46(2):191–195
- 6 Caldwell GW. Two new operations for obstruction of the nasal duct with preservation of the canaliculi, and with an incidental description of a new lacrimal probe. *Am J Ophthalmol* 1893;10:189–193
- 7 Massaro BM, Gonnering RS, Harris GJ. Endonasal laser dacryocystorhinostomy. A new approach to nasolacrimal duct obstruction. *Arch Ophthalmol* 1990;108(8):1172–1176
- 8 West JM. A Window resection of the nasal duct in cases of stenosis. *Trans Am Ophthalmol Soc* 1910;12(Pt 2):654–658
- 9 Onerci M. Dacryocystorhinostomy. Diagnosis and treatment of nasolacrimal canal obstructions. *Rhinology* 2002;40(2):49–65
- 10 de Souza C, Nissar J. Experience with endoscopic dacryocystorhinostomy using four methods. *Otolaryngol Head Neck Surg* 2010;142(3):389–393
- 11 Mantynen J, Yoshitsugu M, Rautiainen M. Results of dacryocystorhinostomy in 96 patients. *Acta Otolaryngol Suppl* 1997;529:187–189
- 12 Unlu HH, Gunhan K, Baser EF, Songu M. Long-term results in endoscopic dacryocystorhinostomy: is intubation really required? *Otolaryngol Head Neck Surg* 2009;140(4):589–595
- 13 Pittore B, Tan N, Salis G, Brennan PA, Puxeddu R. Endoscopic transnasal dacryocystorhinostomy without stenting: results in 64 consecutive procedures. *Acta Otorhinolaryngol Ital* 2010;30(6):294–298
- 14 Madge SN, Selva D. Intubation in routine dacryocystorhinostomy: why we do what we do. *Clin Experiment Ophthalmol* 2009;37(6):620–623
- 15 Tsirbas A, Wormald PJ. Endonasal dacryocystorhinostomy with mucosal flaps. *Am J Ophthalmol* 2003;135(1):76–83
- 16 Kodama S, Hirano T, Suzuki M. Endoscopic dacryocystorhinostomy with mucosal flap. *Nihon Jibiinkoka Gakkai kaiho* 2011;114(10):820–823
- 17 Cukurova I, Caner Mercan G, Cetinkaya E, Gumussoy M, Soken H. Endoscopic dacryocystorhinostomy: outcomes using mucosal flap preserving technique. *Eur Arch Otorhinolaryngol* 2013;270(5):1661–1666
- 18 Codere F, Denton P, Corona J. Endonasal dacryocystorhinostomy: a modified technique with preservation of the nasal and lacrimal mucosa. *Ophthalm Plast Reconstr Surg* 2010;26(3):161–164
- 19 Kansu L, Aydin E, Avci S, Kal A, Gedik S. Comparison of surgical outcomes of endonasal dacryocystorhinostomy with or without mucosal flaps. *Auris Nasus Larynx* 2009;36(5):555–559
- 20 Deviprasad D, Mahesh SG, Pujary K, Pillai S, Mallick SA, Jain V. Endonasal endoscopic dacryocystorhinostomy: our experience. *Indian J Otolaryngol Head Neck Surg* 2009;61(3):223–226
- 21 Ramakrishnan VR, Hink EM, Durairaj VD, Kingdom TT. Outcomes after endoscopic dacryocystorhinostomy without mucosal flap preservation. *Am J Rhinol* 2007;21(6):753–757
- 22 Wormald PJ. Powered endoscopic dacryocystorhinostomy. *Laryngoscope* 2002;112(1):69–72
- 23 McDonogh M, Meiring JH. Endoscopic transnasal dacryocystorhinostomy. *J Laryngol Otol* 1989;103(6):585–587
- 24 Uribe JI, Ralph WM Jr., Glaser AY, Fried MP. Learning curves, acquisition, and retention of skills trained with the endoscopic sinus surgery simulator. *Am J Rhinol* 2004;18(2):87–92
- 25 Sgambatti Celis L, Gil Melcon M, Franco Calvo F, dela Fuente Canibano R, del Rey Tomas – Biosca F, Batuecas Caletrio A. Complications of endoscopic sinus surgery in a residency training program. *Acta Otorrinolaringol Esp* 2010;61(5):345–350
- 26 Taban M, Jarullazada I, Mancini R, Hwang C, Goldberg RA. Facial asymmetry and nasal septal deviation in acquired nasolacrimal duct obstruction. *Orbit* 2011;30(5):226–229
- 27 Knijnik D. Analyzing endoscopic dacryocystorhinostomy: difficulties and solutions. *Arq Bras Oftalmol* 2007;70(3):391–394
- 28 Rahman SH, Tarafder KH, Ahmed MS, Saha KL, Tariq A. Endoscopic dacryocystorhinostomy. *Mymensingh Med J* 2011;20(1):28–32
- 29 Zilelioglu G, Tekeli O, Ugurba SH, Akiner M, Akturk T, Anadolu Y. Results of endoscopic endonasal non-laser dacryocystorhinostomy. *Doc Ophthalmol* 2002;105(1):57–62
- 30 Ben Simon GJ, Joseph J, Lee S, Schwarcz RM, McCann JD, Goldberg RA. External versus endoscopic dacryocystorhinostomy for acquired nasolacrimal duct obstruction in a tertiary referral center. *Ophthalmology* 2005;112(8):1463–1468
- 31 Onerci M, Orhan M, Ogtretmenoglu O, Irkec M. Long-term results and reasons for failure of intranasal endoscopic dacryocystorhinostomy. *Acta Otolaryngol* 2000;120(2):319–322
- 32 Gupta AK, Bansal S. Primary endoscopic dacryocystorhinostomy in children—analysis of 18 patients. *Int J Pediatr Otorhinolaryngol* 2006;70(7):1213–1217
- 33 Al-Qahtani AS. Primary endoscopic dacryocystorhinostomy with or without silicone tubing: a prospective randomized study. *Am J Rhinol Allergy* 2012;26(4):332–334
- 34 Smirnov G, Tuomilehto H, Terasvirta M, Nuutinen J, Seppa J. Silicone tubing after endoscopic dacryocystorhinostomy: is it necessary? *Am J Rhinol* 2006;20(6):600–602
- 35 Baek BJ, Hwang GR, Jung DH, Kim IS, Sin JM, Lee HM. Surgical results of endoscopic dacryocystorhinostomy and lacrimal trephination in distal or common canalicular obstruction. *Clin Exp Otorhinolaryngol* 2012;5(2):101–106
- 36 Feng YF, Cai JQ, Zhang JY, Han XH. A meta-analysis of primary dacryocystorhinostomy with and without silicone intubation. *Can J Ophthalmol* 2011;46(6):521–527
- 37 Tsirbas A, Wormald PJ. Mechanical endonasal dacryocystorhinostomy with mucosal flaps. *Otolaryngol Clin North Am* 2006;39(5):1019–1036
- 38 Yuen KS, Lam LY, Tse MW, Chan DD, Wong BW, Chan WM. Modified endoscopic dacryocystorhinostomy with posterior lacrimal sac flap for nasolacrimal duct obstruction. *Hong Kong Med J* 2004;10(6):394–400
- 39 Trimarchi M, Giordano Resti A, Bellini C, Forti M, Bussi M. Anastomosis of nasal mucosal and lacrimal sac flaps in endoscopic dacryocystorhinostomy. *Eur Arch Otorhinolaryngol* 2009;266(11):1747–1752
- 40 Sonkhya N, Mishra P. Endoscopic transnasal dacryocystorhinostomy with nasal mucosal and posterior lacrimal sac flap. *J Laryngol Otol* 2009;123(3):320–326
- 41 Jin HR, Yeon JY, Choi MY. Endoscopic dacryocystorhinostomy: creation of a large marsupialized lacrimal sac. *J Korean Med Sci* 2006;21(4):719–723