

A small incision technique facilitates pterygium removal

Shu Zhang¹, Tao Wang², Guo-Fan Cao¹, Jin Liu³

¹In-patient Department, the Affiliated Eye Hospital of Nanjing Medical University, Nanjing 210029, Jiangsu Province, China

²Department of ENT and Eye, Community Health Service Center of Tang Shan Neighborhood Office, Jiangning District, Nanjing 211131, Jiangsu Province, China

³Department of Ophthalmology, the Second Affiliated Hospital of Nanjing Medical University, Nanjing 210011, Jiangsu Province, China

Correspondence to: Shu Zhang. In-patient Department No. 2, the Affiliated Eye Hospital of Nanjing Medical University, No. 138 Han Zhong Road, Nanjing 210029, Jiangsu Province, China. zhangs60@aliyun.com

Received: 2015-01-09 Accepted: 2015-05-25

小切口改良翼状胬肉手术的优势

张舒¹, 王涛², 曹国凡¹, 刘锦³

(作者单位:¹210029 中国江苏省南京市, 南京医科大学附属眼科医院; ²211131 中国江苏省南京市, 江宁区汤山街道社区卫生服务中心眼耳鼻喉科; ³210011 中国江苏省南京市, 南京医科大学第二附属医院眼科)

作者简介: 张舒, 本科, 主任医师, 副教授, 研究方向: 白内障。

通讯作者: 张舒. zhangs60@aliyun.com

摘要

目的: 研究小切口改良翼状胬肉手术较传统手术方式的优势。

方法: 将 40 例原发翼状胬肉病例按手术方式分为 2 组 (每组 20 例): 第一组为小切口组, 手术先在翼状胬肉体部切一小口, 经其分离结膜与结膜下的变性筋膜组织; 而第二组则先用刀片将翼状胬肉头部从角膜分离, 然后再分离结膜与结膜下的变性筋膜组织。第一组分离翼状胬肉头部时采用类似角膜瓣成型的方法, 用镊子钝性分离而不是用刀片。分别观察两组的手术时间、疼痛程度和创面愈合, 进行比较。

结果: 第一组平均手术时间较第二组缩短了 7.72min (48.9%, $P < 0.001$)。手术后 1, 2d 第一组的疼痛程度和创面愈合均好于第二组 ($P < 0.001$)。另外, 第一组的手术可由一名医生完成, 而第二组则由两名医生完成。

结论: 小切口翼状胬肉手术较传统手术方式更容易操作, 效果更好。

关键词: 翼状胬肉; 小切口; 手术切除

引用: 张舒, 王涛, 曹国凡, 刘锦. 小切口改良翼状胬肉手术的优势. 国际眼科杂志 2015; 15(9): 1507-1511

Abstract

• **AIM:** To verify the advantages of an improved protocol for pterygium surgery (small incision removal) over a conventional protocol of this surgery.

• **METHODS:** Totally 40 primary pterygium cases were divided into two groups ($n = 20$ each) according to the protocols: small incision removal versus conventional removal. In our small incision removal, group 1, the pterygium body was cut open with a small incision firstly, through which the conjunctiva was separated from the underlying degenerated Tenon's layer; while in the conventional protocol, group 2, the whole head of pterygium was taken down before the separation. Then the head of pterygium was torn down in our protocol using a forceps instead of cutting it down with a blade, which was facilitated by a special corneal epithelial flap formation method. Surgery time, pain score and corneal wound healing were measured to provide objective comparison of outcome between the two protocols.

• **RESULTS:** In the group using small incision removal, the average surgery time was 7.72min (or 48.9%) shorter than that of the control group using conventional protocol ($P < 0.001$). The pain score was lower and the corneal wound was healed better in day 1 and 2 after the surgery in the small incision group ($P < 0.001$). In addition, the surgery can be done by one surgeon using the small incision protocol, while the surgery using the conventional protocol requires two persons.

• **CONCLUSION:** The small incision pterygium removal protocol was easier to perform and resulted in a better outcome than the conventional protocol.

• **KEYWORDS:** pterygium; small incision; surgical removal

DOI:10.3980/j.issn.1672-5123.2015.9.04

Citation: Zhang S, Wang T, Cao GF, Liu J. A small incision technique facilitates pterygium removal. *Guoji Yanke Zazhi (Int Eye Sci)* 2015; 15(9): 1507-1511

INTRODUCTION

Pterygium is a fibrovascular growth arising from conjunctiva. The growth may extend onto cornea and affect vision. This ocular disease has documented long in history and is extremely common worldwide^[1,2]. Conservative topical treatments with lubricants or steroids are recommended in cases that are quiet and limited invading ($< 1-2\text{mm}$) into the cornea^[3]. For advanced symptomatic pterygium, surgical removal of the growth is the only choice. Pterygium surgery has been performed for more than 3000y, and many changes have been scattered in this long period. These changes include extended pterygium removal, conjunctival transplantation, the use of amniotic membrane to cover the wound of the sclera, the use of various adjuvant therapies during surgery (such as β -radiation, argon laser therapy, topical thiotepa, mitomycin C)^[3-9]. Most of those changes

have aimed to reduce recurrence and complications, not to reduce surgery difficulty. Revision of surgical protocol to improve the easiness of this surgery is rare. This may be due to the fact that the surgery is considered as low grade and usually to be performed by junior surgeons. However, difficulties exist in the surgery, which sometime can be frustrating. For a typical example, the dissection of tissue between conjunctiva and its underlying degenerated Tenon's layer is often time consuming because both structures are sliding on a moving eye after the pterygium head was freed from the cornea. We established an improved protocol named, according to the first step of the surgery, as small incision pterygium removal. In this study, we proved the advantages of this protocol by comparing both the easiness of surgical performance and the outcome of the surgery with a conventional protocol.

SUBJECTS AND METHODS

Subjects This study consisted of 40 subjects collected between 2010–2013, in each of them a primary pterygium was removed from one eye. They were assigned according to a random list so that 20 were received small incision pterygium removal while the other 20 were undergone conventional pterygium removal. The sample size of 20 was proved to be adequate by power analysis using G power software in a priori test against the primary outcome of the study: the reduction in surgery time; to reach the power of 95%, 5 samples was enough in each group when α is 0.05, and standard deviation of surgery time is around 3min.

This study was also adhered to the tenets of the Declaration of Helsinki and approved by the Human Research Ethics Committee of the Second Affiliated Hospital of Nanjing Medical University. Fully informed surgical consent was obtained before the surgery and the experimental component of the surgery was explained to the patients.

Patients were followed up at 1, 2 and 3d, and at approximately 1, 3, 6 and 12mo after the surgery^[10].

Methods

Operation procedure A combination of topical and subconjunctival anesthesia was used as previously described^[11,12]. Firstly, a drop of topical anesthetic (Oxybuprocaine Hydrochloride Eye Drops, Santen Pharmaceutical Co., Ltd., Osaka, Japan) was applied to induce anesthesia of the cornea and conjunctiva. An eye speculum was inserted, and the pterygium was filled with 2% lidocaine/1:100000 epinephrine mixture for subconjunctival anesthesia, which also served to separate the pterygium from the underlying sclera.

In group 1 (small incision pterygium removal), a small incision of 3mm in length was cut with a pair of scissor at the pterygium neck to open the top layer of conjunctiva parallel along limbus direction (Figure 1A), and then the degenerated Tenon's layer of pterygium body was separated from the conjunctiva using the scissors (Figure 1B). After that, a cut was made just in front of the edge of pterygium head to isolate the head from the cornea epithelium (Figure

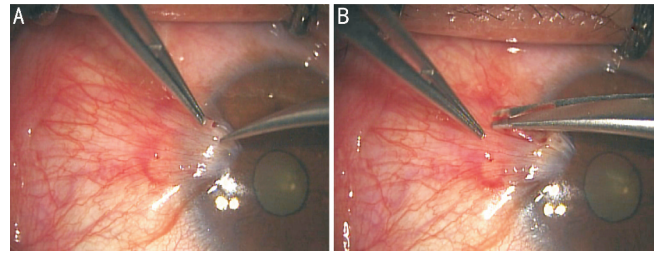


Figure 1 Images for small incision pterygium removal surgery A: A small cut was made with a scissors at the neck of the pterygium; B: the degenerated Tenon's layer of pterygium body was separated from the conjunctiva using the scissors.

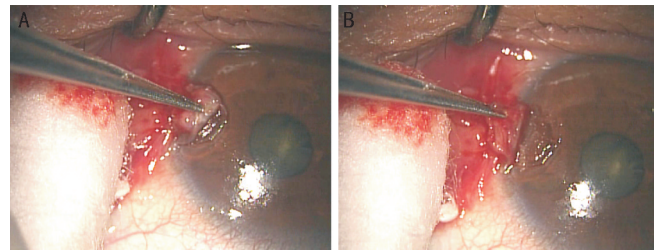


Figure 2 Methods to depart the head of pterygium A: A cut was made just in front of the edge of pterygium head and catching it; B: the head of pterygium was torn from the cornea epithelium and flipped over towards the rectus.

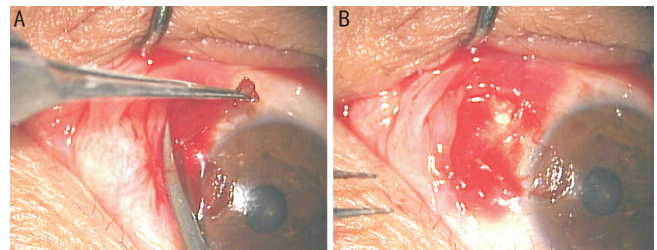


Figure 3 Surgical images for removing the head and the subconjunctival tissue of pterygium A: The head of pterygium was hold up and the subconjunctival tissue of pterygium body (the degenerated Tenon's layer) was cut to the edge rectus; B: the limbus and sclera underneath the wound after the pterygium was removed.

2A). Further, the head of pterygium was torn and flipped over towards the rectus(Figure 2B).

In group 2 with conventional protocol, the first step was to dissect the pterygium's head from the cornea by using a blade, a bit by a bit from the head of pterygium toward the limbus. Then the pterygium was separated from underneath layer of sclera. Therefore, in this protocol, the separation between the conjunctiva and the Tenon's layer was done after the pterygium was free from the sclera. Because the pterygium was not restrained at this stage, both structures (the conjunctiva and the Tenon's layer) are pending and slippery on a moving eye, a pair of scissors and two forceps must be used to catch and separate the conjunctiva from the Tenon's layer simultaneously. This must be done by two surgeons (at least 3 hands).

Following procedures were the same in both groups. Briefly, the head of pterygium and its subconjunctival tissue of its body (the degenerated Tenon's layer) were cut to the edge rectus (Figure 3A, 3B). The limbus and sclera underneath the

wound were cleared by a blade. The upper and lower corners of conjunctiva wound were cut along the limbus (Figure 4A, 4B), the two corners of conjunctiva wound were dragged and secured with suture (8-0 vycril, Ethicon, Inc.) to cover the wound of the sclera near the limbus (Figures 5A, 6A); another 1-2 stitch of interrupted sutures were made to close the conjunctiva wound (Figures 5B, 6B) if necessary. This means that two mini rotated autologous conjunctiva grafts were made to cover the sclera bed that was exposed in the nasal area to limbus^[9,13-15]. The eyes in both groups were covered for 1d, and topical antibiotics (Tarivid, Santen Pharmaceutical Co., Ltd., Osaka, Japan) and steroids (0.1% Flumetholon, Santen Pharmaceutical Co., Ltd., Osaka, Japan) were administered 4 times a day for 2wk. The sutures were removed 1wk after the surgery, if there were still in existence.

Outcome evaluations The outcome evaluation included following items. The time length of the surgery as the index of surgery easiness. Degree of pain^[16] was evaluated by a subjective ranking method. The patients were asked to rank their pain in a 4-point scale (0 = none pain; 1 = little pain; 2 = moderate pain; 3 = several pain). A standard instruction was used in the ranking to avoid bias. This ranking was done during the surgery and repeated at the 1, 2 and 3d. Corneal wound healing, which was observed also at the 1, 2 and 3 postoperative day by fluorescent staining under micro-slit lamp (Haag - Streit 900, Gartenstadtstrasse, Switzerland). Recurrence was defined as the postoperative growth of fibrovascular tissue more than 1mm onto the cornea within 1y.

Statistical Analysis The average surgery times for groups' analyses were done using a Student's *t*-test. A two-way analysis of variance (ANOVA) in a general linear model was performed to evaluate whether or not there was a significant change between groups for the pain scores at the different time points.

RESULTS

In this report, 14 subjects were male and 26 were females. The subjects were at age of 36-74 (58 on average) with a nasal side pterygium without other ocular pathologies. The subjects in the 2 groups were matched in age, gender, pterygium size (Table 1).

The average surgery time for group 1 was 8.055 ± 2.58 min (mean \pm SD), as compared with 15.775 ± 2.98 min for group 2. The difference was 7.72min (or 48.9%) in favor of group 1. This reduction of surgery time was statistically significant (student's *t* test, $t = 10.125$, $df = 38$, $P < 0.001$).

Table 2 showed the ranked pain perception score by the subjects during and after the surgery. A two-way ANOVA showed significant group effect ($F_1 = 10.16$, $P < 0.01$) and time effect ($F_2 = 27.154$, $P < 0.001$). Post-hoc comparisons (Mann-Whitney Rank Sum Test) for factor of group showed significantly lower pain score in group 1 ($P < 0.05$) one day after the surgery. The difference was not significant between groups 3d after the surgery, which was obviously due to the

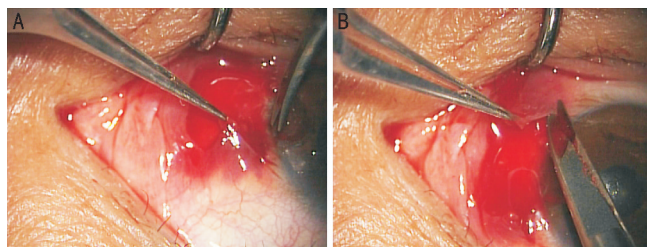


Figure 4 Construction of autologous conjunctiva graft The upper (A) and lower (B) corners of conjunctiva wound were cut along the limbus to establish the graft.

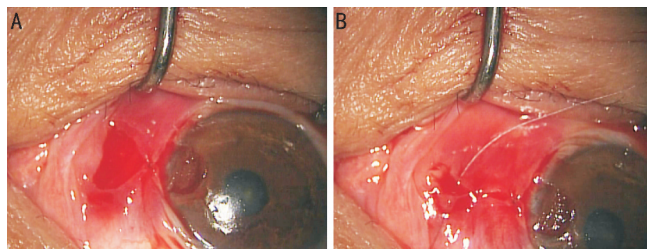


Figure 5 Images showing the suturing of the conjunctiva graft to cover the wound the sclera wound after pterygium removal

A: The upper and lower corners of the conjunctiva were cut open along the limbus for half of the length of the distance between the two corners (dashed lines in Figure 6) and then the two corners were pulled together by one suture; B: more sutures were added to sell the wound.

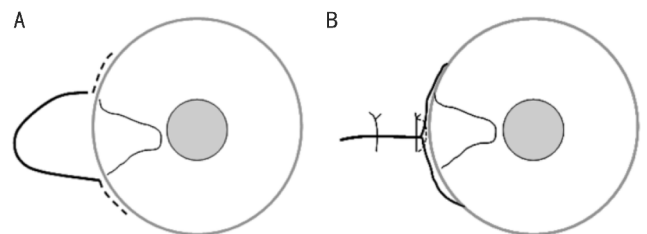


Figure 6 Schematic diagrams of Figure 5.

Parameters	Group 1	Group 2
No. of patients (eyes)	20	20
M: F	3:7	4:6
Mean age (a)	56.1 ± 9.5	60.1 ± 8.9
Size of pterygium (mm)		
2-3	5	4
4-5	13	15
>5	2	1

near total recovery of corneal epithelium at this time.

The healing of the cornea was indicated by negative result in fluorescent staining. In accordance with less wound and shorter surgery time, the post-surgery healing of cornea appeared to be quicker in group 1 as shown in Figure 7. This was manifested by the larger numbers of healed cornea in group 1 in the first two days after the surgery.

In this sample, recurrence was found only 1 patient who was in group 2. The recurrence was shown as a vascularized dellen more than 1mm onto the cornea within 12mo post-surgery. In this case, no further expansion was observed after 2wk of steroid eye drops.

Table 2 Pain scores as indicated by the number of eyes

Parameters	During operative				1d postoperatively				3d postoperatively			
	0	1	2	3	0	1	2	3	0	1	2	3
Group 1	15	4	1	0	4	15	1	0	18	2	0	0
Group 2	10	7	3	0	1	12	6	1	16	3	1	0
<i>P</i>	>0.05				<0.05				>0.05			

The *P* values are the results of post-hoc pairwise comparisons (Mann-Whitney Rank Sum Test) between groups.

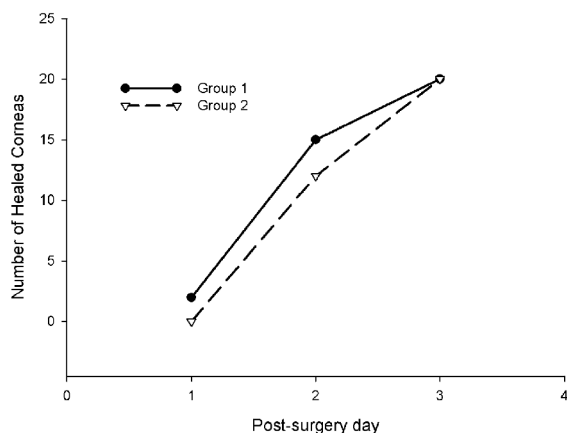


Figure 7 Between group comparison in the number of cornea that were healed as the function of post-surgery time. A quicker recovery was indicated by the larger numbers of healed cornea in group 1 at the first two days postoperatively.

In group 1, only one surgeon was need; while in group 2, two surgeons were needed to complete the procedure.

DISCUSSION

The surgery procedure for pterygium removal should be optimized to promise the provision of a smooth cosmetic conjunctiva after the removal, with no persistent symptoms and a low recurrence rate, as well as an easy performance of the surgery itself^[3]. There has been no single pterygium surgical technique that reaches such requirements^[1]. The history of pterygium surgery is longer than many other ophthalmic operations. The degree of difficulty and the value-at-risk of this surgery are fairly low and it usually can be done by junior surgeons. This is likely the reason for the fact that optimizing of the surgery protocol itself has been largely ignored.

By carefully inspecting each individual step of conventional pterygium surgery, we found that there was a big room for the improvement, especially during the separation between the conjunctiva and underlying degenerated Tenon's layer. The major difficulty in this step was due to the fact that the Tenon's layer had been free from the cornea and sclera and therefore lost tension. In group 1, we dissociated degenerated Tenon's layer from the tissues above it through the small hole made on the neck of pterygium head before it was departed from the cornea. In this way, the dissociation of the Tenon's layer was done when the conjunctiva on the pterygium was still flattened at its original location and tension was remained, making it easier to be segregated from the Tenon's layer. This modification provided a big advantage in shortening the surgery time. Moreover, the whole surgery could be done by

only one surgeon with our improved protocol; while in group 2, two surgeons (at least three hands) were needed at the stage of segregating the Tenon's layer from the conjunctiva.

The second major modification in our modified protocol was the local application of anesthetics, which can loosen corneal epithelium for easy dissection. This was inspired by the manual epithelial flap formation of laser epithelialkeratomileusis (LASEK) technique^[17-19], in which 20% ethanol was commonly utilized. The primary purpose of this procedure is to separate the epithelial layer from the top of the cornea. Chemical agents, such as 0.5% proparacaine, iodine, cocaine, are effectively in loosening corneal epithelium. After the application of the anesthetics drop, we could grasp the cutting edge of pterygium head, lift, pull, and split the corneal epithelium easily by using forceps^[20], and separate the head of pterygium from the cornea. This could be done successfully in most primary cases. If there is a difficulty, a few more drops of topical anesthetics may be helpful which could loosen the corneal epithelium further. We have found that by using this technique, not only the duration of the maneuver was reduced, but also a smoother appearance of corneal cutting with minimal damage to Bowman's membrane was obtained. This smooth corneal wound appeared to have contributed to the better corneal epithelial regeneration after the operation and prevented recurrence of pterygium as demonstrated by studies from others^[5,9,21]. In cases in which the pterygium tissue was adhered tightly to the corneal stroma near limbus, a blunt detachment was necessary using instruments such as forceps. For very difficult cases with strong stromal invasion, careful dissection with surgical knives may be necessary to prevent complications.

The postoperative course was associated with slight pain for 1 to 3d, which paralleled with the corneal wound (Table 2). Quicker surgical procedure and smooth corneal cutting appeared to result in less pain and accelerate the recovery in group 1. Grittiness and redness remained in most cases of both groups for 1 to 3wk. By the visit at 4wk, the patient usually reported no uncomfortable, and the eye was quiet and the final cosmetic appearance was evident.

Therecurrence rate was low in both groups in our study. Therefore, the potential advantage of our small-incision protocol in recurrence rate could not be statistically verified. There is a large variability in recurrence rates across studies^[1]. The reasons are unclear, but some influencing factors could be surgical techniques, demographic differences and mean age of patients or differences in the definition of recurrence^[22].

By studying facts above, we deduced that the potential reason

for the low recurrence rate in the two groups of our samples was likely due to the appropriate treatment to the limbus as supported by many other studies^[12, 23–28]. However, none of these methods can totally eliminate the recurrence^[1,29]. Here, we adapted the technique of rotating autologous conjunctiva graft as the final step of the surgery. This step was supported by fact that the limbus and its stem cells could promote wound repair and reduce pterygium recurrence^[9]. The conjunctiva above the pterygium body was healthy and contains no pathologic tissue. Besides, subconjunctival connective tissue (degenerated Tenon's layer) was likely to be the source of scar tissue and pterygium re-growth; and proliferation activity was present only in the pterygium head, not in its body^[15]. Therefore, clear removal of Tenon's layer was necessary and adequate in preventing recurrence. This concept was introduced and emphasized by Hirst^[1].

In conclusion, the key points of the new protocol include: a) the dissect between the conjunctiva and underlying degenerated Tenon's layer via the small incision before the head of pterygium taken down; b) the use of epithelial flap formation technique to loose the pterygium head from cornea. The surgery difficulties were significantly reduced in the new protocol as indicated mainly by the reduction of surgery time. Although several minutes shortening of surgery time is not what we pursue, this reduction is a clear index reflecting the improvement in surgery easiness. Therefore, the new protocol probably worth to be promoted. This small incision technique, we hope, will push one step forward in pterygium surgery. It must be beneficial for further evaluation of the protocol in a larger scale and longer term and in combination with other methods^[1].

REFERENCES

- Hirst LW. Prospective study of primary pterygium surgery using pterygium extended removal followed by extended conjunctival transplantation. *Ophthalmology* 2008;115(10):1663–1672
- Mahar PS, Manzar N. The study of etiological and demographic characteristics of pterygium recurrence: a consecutive case series study from Pakistan. *Int Ophthalmol* 2014;34(1):69–74
- Massaoutis P, Khemka S, Ayliffe W. Clinical outcome study of a modified surgical technique for pterygium excision. *Can J Ophthalmol* 2006;41(6):704–708
- Razeghinejad MR, Banifatemi M. Subconjunctival bevacizumab for primary pterygium excision; a randomized clinical trial. *J Ophthalmic Vis Res* 2014;9(1):22–30
- Gulkilik G, Kocabora S, Taskapili M, Ozsutcu M. A new technique for pterygium excision: air-assisted dissection. *Ophthalmologica* 2006;220(5):307–310
- Yeung SN, Rubenstein D, Price AJ, Elbaz U, Zhang AQ, Cote E, Slomovic AR. Sequential pterygium excision with conjunctival autograft in the management of primary double-headed pterygia. *Can J Ophthalmol* 2013;48(6):521–523
- Kim SH, Oh JH, Do JR, Chuck RS, Park CY. A comparison of anchored conjunctival rotation flap and conjunctival autograft techniques in pterygium surgery. *Cornea* 2013;32(12):1578–1581
- Hirst LW. Other considerations in pterygium surgery. *Ophthalmology* 2013;120(9):e60
- Kurna SA, Altun A, Aksu B, Kurna R, Sengor T. Comparing treatment options of pterygium: limbal sliding flap transplantation, primary closing, and amniotic membrane grafting. *Eur J Ophthalmol* 2013;23(4):480–487

- Hirst LW. Recurrence and complications after 1,000 surgeries using pterygium extended removal followed by extended conjunctival transplant. *Ophthalmology* 2012;119(11):2205–2210
- Naftali M, Jabaly –Habib H, Mukari A. Burn during a routine pterygium excision operation. *Eur J Ophthalmol* 2008;18(4):639–640
- Young AL, Ho M, Jhanji V, Cheng LL. Ten – year results of a randomized controlled trial comparing 0.02% mitomycin C and limbal conjunctival autograft in pterygium surgery. *Ophthalmology* 2013;120(12):2390–2395
- Muller S, Stahn J, Schmitz K, Behrens –Baumann W. Recurrence rates after pterygium excision with sliding conjunctival flap versus free conjunctival autograft. *Ophthalmologie* 2007;104(6):480–483
- Varssano D, Shalev H, Lazar M, Fischer N. Pterygium excision with conjunctival autograft: true survival rate statistics. *Cornea* 2013;32(9):1243–1250
- Ozer A, Yildirim N, Erol N, Yurdakul S. Long-term results of bare sclera, limbal – conjunctival autograft and amniotic membrane graft techniques in primary pterygium excisions. *Ophthalmologica* 2009;223(4):269–273
- Aslankurt M, Aslan L, Baskan AM, Aksoy A, Silay E, Yildiz H. Pain and cooperation in patients having dominant-side or nondominant-side phacoemulsification. *J Cataract Refract Surg* 2014;40(2):199–202
- McAlinden C, Moore JE. Comparison of higher order aberrations after LASIK and LASEK for myopia. *J Refract Surg* 2010;26(1):45–51
- Choi CY, Kim JY, Kim MJ, Tchah H. Transmission electron microscopy study of corneal epithelial flaps following removal using mechanical scraping, alcohol, and epikeratome techniques. *J Refract Surg* 2008;24(7):667–670
- Lee HK, Lee KS, Kim JK, Kim HC, Seo KR, Kim EK. Epithelial healing and clinical outcomes in excimer laser photorefractive surgery following three epithelial removal techniques: mechanical, alcohol, and excimer laser. *Am J Ophthalmol* 2005;139(1):56–63
- Wilson SE, Santhiago MR. Flaporrhesis: rapid and effective technique to limit epithelial ingrowth after LASIK enhancement. *J Cataract Refract Surg* 2012;38(1):2–4
- Chui J, Coroneo MT, Tat LT, Crouch R, Wakefield D, Di Girolamo N. Ophthalmic pterygium: a stem cell disorder with premalignant features. *Am J Pathol* 2011;178(2):817–827
- Kilic A, Gurler B. The efficiency of limbal conjunctival autografting in pterygium surgery. *Eur J Ophthalmol* 2006;16(3):365–370
- Zheng K, Cai J, Jhanji V, Chen H. Comparison of pterygium recurrence rates after limbal conjunctival autograft transplantation and other techniques: meta-analysis. *Cornea* 2012;31(12):1422–1427
- Han SB, Hyon JY, Hwang JM, Wee WR. Efficacy and safety of limbal – conjunctival autografting with limbal fixation sutures after pterygium excision. *Ophthalmologica* 2012;227(4):210–214
- Yu C, Liang W, Huang Y, Guan W. Comparison of clinical efficacy of three surgical methods in the treatment of pterygium. *Eye Sci* 2011;26(4):193–196
- Kheirkhah A, Hashemi H, Adelpour M, Nikdel M, Rajabi MB, Behrouz MJ. Randomized trial of pterygium surgery with mitomycin C application using conjunctival autograft versus conjunctival – limbal autograft. *Ophthalmology* 2012;119(2):227–232
- Oguz H. Amniotic membrane grafting versus conjunctival autografting in pterygium surgery. *Clin Experiment Ophthalmol* 2005;33(4):447–448
- Dupps WJ Jr, Jeng BH, Meisler DM. Narrow – strip conjunctival autograft for treatment of pterygium. *Ophthalmology* 2007;114(2):227–231
- Ari S, Caca I, Yildiz ZO, Sakalar YB, Dogan E. Comparison of mitomycin C and limbal – conjunctival autograft in the prevention of pterygia recurrence in Turkish patients: a one – year, randomized, assessor-masked, controlled trial. *Curr Ther Res Clin Exp* 2009;70(4):274–281