

Relationship of MMP-2 or TGF- β 2 levels in human vitreous with axial length

Ting-Ting Zhao, Meng-Zhu Wu, Jing Jin, Shu-Nong Xie, Ying Fan

Foundation item: Major State Basic Research Development Program of China (No. 2011CB707500).

Department of Ophthalmology, Shanghai General Hospital, Shanghai Jiao Tong University School of Medicine, Shanghai 200080, China

Correspondence to: Ying Fan. Department of Ophthalmology, Shanghai General Hospital, Shanghai Jiao Tong University School of Medicine, Shanghai 200080, China. mdfanying@sjtu.edu.cn

Received:2016-09-20 Accepted:2017-01-18

高度近视患者玻璃体中 MMP-2 和 TGF- β 2 水平与眼轴的相关性

赵婷婷, 吴梦竹, 靳婧, 谢书浓, 樊莹

基金项目: 国家重点基础研究发展计划(973 计划)(No. 2011CB707500)

(作者单位:200080 中国上海市上海交通大学附属第一人民医院眼科)

作者简介:赵婷婷,毕业于上海交通大学医学院,硕士研究生,住院医师,研究方向:玻璃体视网膜疾病。

通讯作者:樊莹,毕业于上海医学院,博士研究生,主任医师,教授,研究方向:玻璃体视网膜疾病. mdfanying@sjtu.edu.cn

摘要

目的:探究高度近视患者眼轴与玻璃体中 MMP-2 和 TGF- β 2 水平的相关性。

方法:研究患者玻璃体切除术中获取玻璃体样本 55 份。依据角膜表面曲率大小及眼轴长度,将研究对象分为两组:即高度近视组(25 例):SE>-6.00D, AL \geq 26.00mm 和对照组或非高度近视组(30 例):SE \leq -6.00D, AL<26.00mm。利用 ELISA 的方法测量研究对象玻璃体 MMP-2 和 TGF- β 2 浓度。

结果:高度近视组玻璃体 MMP-2 浓度(96.87 \pm 55.95ng/mL)显著高于对照组(77.24 \pm 41.81ng/mL, $P<0.05$),但与眼轴没有相关性($r=0.088$, $P=0.544$)。高度近视组(3729.08 \pm 1890.88pg/mL)与对照组(3926.00 \pm 1333.88pg/mL, $P<0.05$)TGF- β 2 浓度具有显著差异性,且 TGF- β 2 浓度与眼轴长度呈负相关($r=-0.344$, $P=0.014$)。

结论:人玻璃体中 MMP-2 和 TGF- β 2 两种分子浓度在高度近视进展中具有重要作用,TGF- β 2 浓度与眼轴长度具有相关性。

关键词:基质金属蛋白酶-2;转移生长因子- β 2;玻璃体;高度近视;眼轴长度

引用:赵婷婷,吴梦竹,靳婧,谢书浓,樊莹. 高度近视患者玻璃体中 MMP-2 和 TGF- β 2 水平与眼轴的相关性. 国际眼科杂志 2017;17(4):587-591

Abstract

• **AIM:** To investigate the relationship of matrix metalloproteinase-2 (MMP-2) and transforming growth factor-beta 2 (TGF- β 2) levels in human vitreous with axial length (AL) of patients with high myopia.

• **METHODS:** The concentrations of MMP-2 and TGF- β 2 levels were tested by Enzyme-Linked Immunosorbent Assay (ELISA). Fifty-five human vitreous samples of 55 patients were collected during vitrectomy surgery, and were divided into two groups according to their spherical equivalent (SE) and axial length (AL). High myopia group (25 cases): SE > -6.00D, AL \geq 26.00mm, and control group or non-high myopia group (30 cases): SE \leq -6.00D, AL < 26.00mm.

• **RESULTS:** The MMP-2 levels in vitreous of high myopia group (96.87 \pm 55.95ng/mL) was significantly higher than that of control group (77.24 \pm 41.81ng/mL, $P<0.05$), but not correlated with AL ($r=0.088$, $P=0.544$). While the TGF- β 2 vitreous concentration was negatively correlated with AL ($r=-0.344$, $P=0.014$), and there was significant difference of TGF- β 2 vitreous levels between high myopia group (3729.08 \pm 1890.88pg/mL) and control group (3926.00 \pm 1333.88pg/mL, $P<0.05$).

• **CONCLUSION:** MMP-2 and TGF- β 2 in human vitreous may play a critical role in human high myopia development, and the TGF- β 2 appears to be associated with axial length.

• **KEYWORDS:** matrix metalloproteinase-2; transforming growth factor-beta 2; vitreous body; high myopia; axial length

DOI:10.3980/j.issn.1672-5123.2017.4.01

Citation: Zhao TT, Wu MZ, Jin J, Xie SN, Fan Y. Relationship of MMP-2 or TGF- β 2 levels in human vitreous with axial length. *Guoji Yanke Zazhi(Int Eye Sci)* 2017;17(4):587-591

INTRODUCTION

Myopia is the most common visual disorder in the worldwide, especially in the Asia countries^[1-3]. High myopia is often defined as refractive error >-6.00D and axial length (AL) \geq 26.00mm, with complications including posterior staphyloma (PS)^[3-8], choroidal neovascularization (CNV)^[9-13], macular hole (MH)^[4,14-16], retinal detachment (RD)^[17-18], macular hole retinal detachment (MHRD) or macular retinoschisis (MRS)^[19-21] and so on. These may result from its pathology characteristics: sclera thinning, remodeling and axial elongation^[22-24].

In myopic eyes, sclera remodeling and axial elongation are

associated with changes of its extracellular matrix (ECM)^[25], and controlled by a number of little chemical molecules, in which, the major two are matrix metalloproteinase-2 (MMP-2) and transforming growth factor-beta 2 (TGF-β2). MMPs are a group of zinc-dependent proteinases that can degrade collagens, gelatins, ECM molecules, which composed by collagenases, stromelysins, gelatinases and membrane type-MMPs^[26-37]. Among above, Gelatinases, including MMP-2, also called Gelatinase A, can be found in various ocular tissues of human and animals^[29]. Although numbers of human and animal experiments have suggested that the expression of MMP-2 (mRNA or protein) increases during myopia developing and decreases when recovery^[25,27,38-39]. However, there are also studies suggested no association between myopia and MMP-2^[28,33,40], this comes out controversy.

TGF-β plays a critically important role in regulating extracellular matrix turnover^[41-45]. There are five isoforms, that are, TGF-β1, TGF-β2, TGF-β3, TGF-β4 and TGF-β5 in total, among them, the first three have been demonstrated expression in few tissues in mammal animals, include sclera, retina and choroid, in addition, TGF-β2 is the main subtype and a normal composition in human vitreous^[46-49].

Nevertheless, the previous researches primarily instructed the two molecules: MMP-2 and TGF-β2 (mRNA or protein) in aqueous humor, sclera, retina, choroid etc. of human or animals, maybe, just investigating the changes of MMP-2 and TGF-β2 levels in patients with high myopia. The purpose of our study was to explore the relationship between MMP-2 and TGF-β2 levels in human vitreous and axial length of high myopic patients, furthermore, to explicit the action of MMP-2 on myopia.

SUBJECTS AND METHODS

Patients and Samples This study was an observational and case-control study. Fifty-five samples of 55 individuals received vitrectomy for retinal detachment or macular hole, which were all collected from Mar. 2015 to Nov. 2015. There were 24 males and 31 females in total with ages ranging from 18 to 80y, their average age is 58.53y. Informed consent was obtained from all individual participants included in the study, the study followed the principle of the Declaration of Helsinki (2008) and was approved by the Ethics Committee of Shanghai General Hospital of Shanghai Jiao Tong University. Comprehensive ocular examinations were received, which including detailed ophthalmoscopic examinations, B-scan ultrasonography and optical coherence tomography (OCT), AL was measured with an IOL-Master (Optical Biometry, Master 500, Carl Zeiss Meditec AG, Germany). According to AL etc., the subjects were divided into two groups (high myopia group, 25 cases and control group or non-high myopia group, 30 case). The exclusion criteria were ocular traumas, choroidal neovascularization, proliferative vitreoretinopathy, endophthalmitis and any other history of ocular surgery. The samples were collected into

marked sterile tubes during vitrectomy prior to intraocular infusion and immediately stored at -80°C until analysis.

Measurement of MMP-2 and TGF-β2 All the vitreous samples were assayed with Enzyme-Linked Immunosorbent Assay (ELISA) Kit (ELISA Kits, R&D System, USA). According to the manufacturer's instructions, briefly, diluted human vitreous or rebuilt standard samples incubated for 2h at room temperature, repeated aspirating and washing with wash buffer for a total of three times, conjugate added and washed also, stopped with stop solution and measured by a microplate reader at a wavelength of 450 nm.

Statistical Analysis The results from two groups were analyzed with SPSS 17.0 statistical software. The original data of MMP-2/TGF-β2 levels and ages of two groups were normally distributed by the Kolmogorov-Smirnov test. The relationship between AL and MMP-2/TGF-β2 or ages and MMP-2/TGF-β2 was used Spearman correlation analysis. The MMP-2/TGF-β2 levels and ages were expressed as mean±standard deviation (SD) and analyzed with *t*-test. The χ^2 test was used to analyzed the comparison of sex distribution. A two-tailed *P* value of less than 0.05 was considered statistically significant.

RESULTS

The Characteristics of Sex, Ages and AL There was no significant difference of age ($F = 0.006$, $P = 0.94$) or gender ($\chi^2 = 1.528$, $P = 0.216$) between high myopia group and non-high myopia group, furthermore, no statistically significant correlation between the age and AL was found ($r = -0.249$, $P = 0.081$) (Table 1).

Levels of MMP-2 and AL The MMP-2 could be detected in all vitreous samples and MMP-2 ($P = 0.037$, $P < 0.05$) concentration of high myopia group was significantly higher than control group, nevertheless, there was no significant correlation between AL concentration and MMP-2 ($r = 0.088$, $P = 0.544$) in all subjects (Table 1, Figure 1).

Levels of TGF-β2 and AL The TGF-β2 could be detected in all vitreous samples, there was significant difference of TGF-β2 ($P = 0.030$, $P < 0.05$) between the two groups, in addition, there was significant correlation between AL concentration and TGF-β2 ($r = -0.344$, $P = 0.014$) (Table 1, Figure 2).

Relationship between Concentrations of MMP-2/TGF-β2 and Age/Gender No significant correlation was found between MMP-2 ($r = -0.106$, $P = 0.451$) or TGF-β2 ($r = 0.014$, $P = 0.923$) and age, either, there was no significant difference of MMP-2 ($F = 0.057$, $P = 0.812$) or TGF-β2 ($F = 2.007$, $P = 0.163$) between males and females.

DISCUSSION

In the present study, we found three important contributions to literature on myopia. First, to our best knowledge, this was the first research that clearly illuminate the significant correlation of AL between MMP-2 and TGF-β2 levels of the human vitreous respectively. Second, the relationship of MMP-2 and high myopia was emphasized once again. MMP-2 and TGF-β2 are

Table 1 Main characteristics of 55 patients from two groups

| Variables | Groups | | P |
|------------------------------|--------------------------|----------------------|--------------------|
| | High myopia group (n=25) | Control group (n=30) | |
| Age (a) | 57.72±12.26 | 60.21±14.23 | 0.940 ^a |
| Gender (M/F) | 12/13 | 12/18 | 0.216 ^b |
| Axial length (mm) | 28.69±1.93 | 23.57±1.08 | 0.020 ^a |
| MMP-2 concentration (ng/mL) | 96.87±55.95 | 77.24±41.81 | 0.037 ^a |
| TGF-β2 concentration (pg/mL) | 3729.08±1890.88 | 3926.00±1333.88 | 0.030 ^a |

MMP-2; Matrix metalloproteinase-2; TGF-β2; Transforming growth factor-beta 2; ^aIndependent *t*-test; ^bPearson χ^2 test.

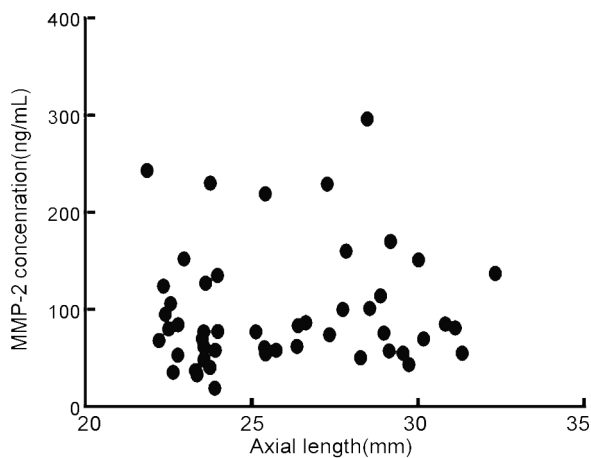


Figure 1 Correlation between axial length and MMP-2.

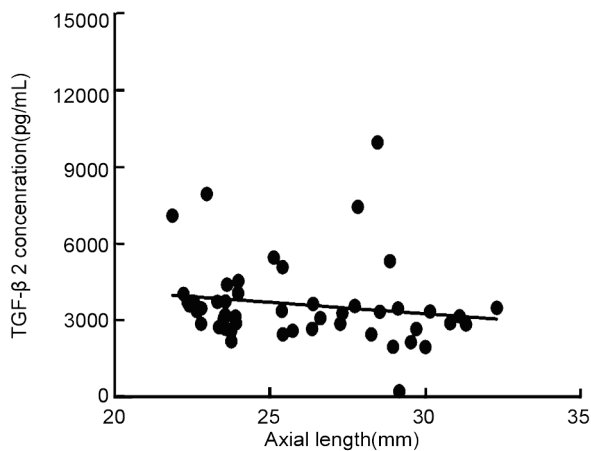


Figure 2 Correlation between axial length and TGF-β2.

important cytokines for high myopia, we could detected and measured these with ELISE and draw several conclusions. In the first place, MMP-2 concentration of human vitreous in high myopia was statistically significant higher than non-high myopia group, moreover, there was no significant correlation between MMP-2 concentration and AL for all subjects, this was one bone of contention comparing with previous reports. Researches of animal (tree shrew and chicken) model and human have constituted evidence of significant association between MMP-2 (mRNA and protein) and myopia scleral remodeling. Animal experiments have illustrated the MMP-2 mRNA level up- and down-regulation changes during form deprivation, different time course and recovery^[38-39,50]. In addition, previous studies have provided strong evidence that MMP-2 expression increased in human vitreous or aqueous humor with high myopia, significantly positive correlation lies

between MMP-2 concentration in human aqueous humor and axial length^[25,27]. In our study, results showed elevated MMP-2 level in human vitreous of high myopia and no further AL correlation. MMP-2 protein findings were consist with preceding researches (mRNA or protein) generally, we speculated that tissue and race specificities maybe the sources for discrepancy.

Several antecedent studies found that MMP-2 (single-nucleotide polymorphisms, SNP analysis) did not appear to be associated with myopia or refractive error with the dye terminator-based SNaPshot method including Han Chinese high myopia, Japanese high myopia and Caucasian ethnicity myopia^[28,33,40,51]. Another research discovered MMP-2 gene was involved in myopia of AMISH families but not in Ashkenazi families using the same genetic analysis means^[52]. The results suggested that tagging different promoter SNPs that carrying common sequence or not and environmental heterogeneity probably came out various associations with myopia.

In the next place, TGF-β2 level of high myopia group was significant lower than non-high myopia group, furthermore, there was a significantly negative correlation between TGF-β2 concentration and AL. TGF-β2 is the critical mediator of scleral remodeling during myopia development, it mainly lead to reducing synthesis and increasing resolution of scleral collagen. Researches of TGF-β2 concentration in human myopia subjects are controversial, significantly higher in human aqueous humor and positively correlated with axial length were found but no significant difference in human vitreous between high myopia and control group^[27,41], the difference may be generated by tissue diversity and measuring method. Previously, studies in animal models showed that retinal and choroid TGF-β2 mRNA level was not altered while reduced abidingly or fluctuant in the scleral at specific myopia scleral remodeling stages^[38,42-43,47-49]. It was probably that the early decrease of scleral TGF-β2 was an indication for retinoscleral signal guiding ocular myopia change^[49], these were not in conformity with our study, which could be attribute to tissue and race specificities, detection method may also accounted for part factors.

In conclusion, this study implied that the protein levels of MMP-2 and TGF-β2 changed in the human vitreous of patients with longer axial. The concentration of MMP-2 increased while TGF-β2 decreased in high myopia subjects,

in addition, it implied that longer axial patients had lower level TGF- β 2. MMP-2 and TGF- β 2 played critical roles in high myopia scleral remodeling. Our study will provide a strong evidence for the research concerned high myopia clinically.

REFERENCES

1 Sun J, Zhou J, Zhao P, Lian J, Zhu H, Zhou Y, Sun Y, Wang Y, Zhao L, Wei Y, Wang L, Cun B, Ge S, Fan X. High prevalence of myopia and high myopia in 5060 Chinese university students in Shanghai. *Invest Ophthalmol Vis Sci* 2012;53(12):7504-7509

2 Lv L, Zhang Z. Pattern of myopia progression in Chinese medical students: a two-year follow-up study. *Graefes Arch Clin Exp Ophthalmol* 2013;251(1):163-168

3 Frisina R, Baldi A, Cesana BM, Semeraro F, Parolini B. Morphological and clinical characteristics of myopic posterior staphyloma in Caucasians. *Graefes Arch Clin Exp Ophthalmol* 2016;254(11):2119-2129

4 Alkabes M, Padilla L, Salinas C, Nucci P, Vitale L, Pichi F, Bures-Jelstrup A, Mateo C. Assessment of OCT measurements as prognostic factors in myopic macular hole surgery without foveoschisis. *Graefes Arch Clin Exp Ophthalmol* 2013;251(11):2521-2527

5 Ellabban AA, Tsujikawa A, Matsumoto A, Yamashiro K, Oishi A, Ooto S, Nakata I, Akagi-Kurashige Y, Miyake M, Yoshimura N. Macular choroidal thickness measured by swept source optical coherence tomography in eyes with inferior posterior staphyloma. *Invest Ophthalmol Vis Sci* 2012;53(12):7735-7745

6 Henaine-Berra A, Zand-Hadas IM, Fromow-Guerra J, Garcia-Aguirre G. Prevalence of macular anatomic abnormalities in high myopia. *Ophthalmic Surg Lasers Imaging Retina* 2013;44(2):140-144

7 Vella Briffa B, D'Souza Y. Serous macular detachment associated with menstruation in the presence of a posterior staphyloma. *Can J Ophthalmol* 2013;48(3):e55-57

8 Rino F, Elena Z, Ivan M, Paolo B, Barbara P, Federica R. Lamellar macular hole in high myopic eyes with posterior staphyloma: morphological and functional characteristics. *Graefes Arch Clin Exp Ophthalmol* 2016;254(11):2141-2150

9 Pece A, Milani P, Monteleone C, Trombetta CJ, De Crecchio G, Fasolino G, Matranga D, Cillino S, Vadala M. A randomized trial of intravitreal bevacizumab vs. ranibizumab for myopic CNV. *Graefes Arch Clin Exp Ophthalmol* 2015;253(11):1867-1872

10 Traversi C, Nuti E, Marigliani D, Cevenini G, Balestrazzi A, Martone G, Caporossi T, Tosi GM. Forty-two-month outcome of intravitreal bevacizumab in myopic choroidal neovascularization. *Graefes Arch Clin Exp Ophthalmol* 2015;253(4):511-517

11 Milani P, Massacesi A, Setaccioli M, Moschini S, Mantovani E, Ciaccia S, Bergamini F. Sensitivity of fluorescein angiography alone or with SD-OCT for the diagnosis of myopic choroidal neovascularization. *Graefes Arch Clin Exp Ophthalmol* 2013;251(8):1891-1900

12 Lai TY, Cheung CM. Myopic choroidal neovascularization: Diagnosis and Treatment. *Retina* 2016;36(9):1614-1621

13 Liu B, Bao L, Zhang J. Optical Coherence Tomography Angiography Of Pathological Myopia Sourced and Idiopathic Choroidal Neovascularization With Follow-Up. *Medicine* 2016;95(14):e3264

14 Gomez-Resa M, Bures-Jelstrup A, Mateo C. Myopic traction maculopathy. *Dev Ophthalmol* 2014;54:204-212

15 Alkabes M, Pichi F, Nucci P, Massaro D, Dutra Medeiros M, Corcostegui B, Mateo C. Anatomical and visual outcomes in high myopic macular hole (HM-MH) without retinal detachment: a review. *Graefes Arch Clin Exp Ophthalmol* 2014;252(2):191-199

16 Alkabes M, Bures-Jelstrup A, Salinas C, Medeiros MD, Rios J, Corcostegui B, Mateo C. Macular buckling for previously untreated and recurrent retinal detachment due to high myopic macular hole: a 12-

month comparative study. *Graefes Arch Clin Exp Ophthalmol* 2014;252(4):571-581

17 Faghihi H, Hajizadeh F, Riazi-Esfahani M. Optical coherence tomographic findings in highly myopic eyes. *J Ophthalmic Vis Res* 2010;5(2):110-121

18 McBrien NA, Cornell LM, Gentle A. Structural and ultrastructural changes to the sclera in a mammalian model of high myopia. *Invest Ophthalmol Vis Sci* 2001;42(10):2179-2187

19 Lavers H, Zambarakji H. Management of macular hole retinal detachment and macular retinoschisis secondary to pathological myopia: a national survey of UK practice patterns. *Eye (Lond)* 2013;27(11):1324

20 Wu TY, Yang CH, Yang CM. Gas tamponade for myopic foveoschisis with foveal detachment. *Graefes Arch Clin Exp Ophthalmol* 2013;251(5):1319-1324

21 Sun CB, You YS, Liu Z, Zheng LY, Chen PQ, Yao K, Xue AQ. Myopic Macular Retinoschisis in Teenagers: Clinical Characteristics and Spectral Domain Optical Coherence Tomography Findings. *Sci Rep* 2016;6:27952

22 McBrien NA, Lawlor P, Gentle A. Scleral remodeling during the development of and recovery from axial myopia in the tree shrew. *Invest Ophthalmol Vis Sci* 2000;41(12):3713-3719

23 Rada JA, Shelton S, Norton TT. The sclera and myopia. *Exp Eye Res* 2006;82(2):185-200

24 Ohno-Matsui K. Complicated mechanism for axial elongation in eyes with pathologic myopia accompanying scleral thinning and deformity. *Graefes Arch Clin Exp Ophthalmol* 2013;251(9):2279

25 Jia Y, Hu DN, Zhu D, Zhang L, Gu P, Fan X, Zhou J. MMP-2, MMP-3, TIMP-1, TIMP-2, and TIMP-3 protein levels in human aqueous humor: relationship with axial length. *Invest Ophthalmol Vis Sci* 2014;55(6):3922-3928

26 Murphy G, Nagase H. Progress in matrix metalloproteinase research. *Mol Aspects Med* 2008;29(5):290-308

27 Zhuang H, Zhang R, Shu Q, Jiang R, Chang Q, Huang X, Jiang C, Xu G. Changes of TGF- β 2, MMP-2, and TIMP-2 levels in the vitreous of patients with high myopia. *Graefes Arch Clin Exp Ophthalmol* 2014;252(11):1763-1767

28 Schache M, Baird PN. Assessment of the association of matrix metalloproteinases with myopia, refractive error and ocular biometric measures in an Australian cohort. *PLoS ONE* 2012;7(10):e47181

29 Chu SC, Hu DN, Yang SF, Yang PY, Hsieh YS, Huang SM, Yu G, McCormick SA. Uveal melanocytes produce matrix metalloproteinases-2 and -9 *in vitro*. *Pigment Cell Res* 2004;17(6):636-642

30 Shelton L, Rada JS. Effects of cyclic mechanical stretch on extracellular matrix synthesis by human scleral fibroblasts. *Exp Eye Res* 2007;84(2):314-322

31 Weinreb RN, Lindsey JD. Metalloproteinase gene transcription in human ciliary muscle cells with latanoprost. *Invest Ophthalmol Vis Sci* 2002;43(3):716-722

32 Bandyopadhyay M, Rohrer B. Matrix metalloproteinase activity creates pro-angiogenic environment in primary human retinal pigment epithelial cells exposed to complement. *Invest Ophthalmol Vis Sci* 2012;53(4):1953-1961

33 Gong B, Liu X, Zhang D, Wang P, Huang L, Lin Y, Lu F, Ma S, Cheng J, Chen R, Li X, Lin H, Zeng G, Zhu X, Hu J, Yang Z, Shi Y. Evaluation of MMP2 as a candidate gene for high myopia. *Mol Vis* 2013;19:121-127

34 Pang IH, Hellberg PE, Fleenor DL, Jacobson N, Clark AF. Expression of matrix metalloproteinases and their inhibitors in human trabecular meshwork cells. *Invest Ophthalmol Vis Sci* 2003;44(8):3485-3493

35 Page-McCaw A, Ewald AJ, Werb Z. Matrix metalloproteinases and the regulation of tissue remodelling. *Nat Rev Mol Cell Biol* 2007;8(3):

- 221–233
- 36 Ronkko S, Rekonen P, Kaamiranta K, Puustjarvi T, Terasvirta M, Uusitalo H. Matrix metalloproteinases and their inhibitors in the chamber angle of normal eyes and patients with primary open-angle glaucoma and exfoliation glaucoma. *Graefes Arch Clin Exp Ophthalmol* 2007; 245(5): 697–704
- 37 Lan YQ, Zhang C, Xiao JH, Zhuo YH, Guo H, Peng W, Ge J. Suppression of IkappaBalpha increases the expression of matrix metalloproteinase-2 in human ciliary muscle cells. *Mol Vis* 2009; 15: 1977–1987
- 38 Schippert R, Brand C, Schaeffel F, Feldkaemper MP. Changes in scleral MMP-2, TIMP-2 and TGFbeta-2 mRNA expression after imposed myopic and hyperopic defocus in chickens. *Exp Eye Res* 2006; 82(4):710–719
- 39 Siegwart JT Jr, Norton TT. Selective regulation of MMP and TIMP mRNA levels in tree shrew sclera during minus lens compensation and recovery. *Invest Ophthalmol Vis Sci* 2005; 46(10):3484–3492
- 40 Leung KH, Yiu WC, Yap MK, Ng PW, Fung WY, Sham PC, Yip SP. Systematic investigation of the relationship between high myopia and polymorphisms of the MMP2, TIMP2, and TIMP3 genes by a DNA pooling approach. *Invest Ophthalmol Vis Sci* 2011; 52(6):3893–3900
- 41 Jia Y, Hu DN, Zhou J. Human aqueous humor levels of TGF-beta2: relationship with axial length. *Biomed Res Int* 2014; 2014:258591
- 42 McBrien NA. Regulation of scleral metabolism in myopia and the role of transforming growth factor-beta. *Exp Eye Res* 2013; 114:128–140
- 43 Chen BY, Wang CY, Chen WY, Ma JX. Altered TGF-beta2 and bFGF expression in scleral desmocytes from an experimentally-induced myopia guinea pig model. *Graefes Arch Clin Exp Ophthalmol* 2013; 251(4):1133–1144
- 44 Jobling AI, Gentle A, Metlapally R, McGowan BJ, McBrien NA. Regulation of scleral cell contraction by transforming growth factor-beta and stress: competing roles in myopic eye growth. *J Biol Chem* 2009; 284(4):2072–2079
- 45 Yokoyama K, Kimoto K, Itoh Y, Nakatsuka K, Matsuo N, Yoshioka H, Kubota T. The PI3K/Akt pathway mediates the expression of type I collagen induced by TGF-beta2 in human retinal pigment epithelial cells. *Graefes Arch Clin Exp Ophthalmol* 2012; 250(1):15–23
- 46 Liu JH. Circadian variations of transforming growth factor-beta2 and basic fibroblast growth factor in the rabbit aqueous humor. *Curr Eye Res* 2002; 24(1):75–80
- 47 Jobling AI, Wan R, Gentle A, Bui BV, McBrien NA. Retinal and choroidal TGF-beta in the tree shrew model of myopia: isoform expression, activation and effects on function. *Exp Eye Res* 2009; 88(3):458–466
- 48 Mathis U, Schaeffel F. Transforming growth factor-beta in the chicken fundal layers: an immunohistochemical study. *Exp Eye Res* 2010; 90(6):780–790
- 49 Jobling AI, Nguyen M, Gentle A, McBrien NA. Isoform-specific changes in scleral transforming growth factor-beta expression and the regulation of collagen synthesis during myopia progression. *J Biol Chem* 2004; 279(18):18121–18126
- 50 Siegwart JT, Jr., Norton TT. The time course of changes in mRNA levels in tree shrew sclera during induced myopia and recovery. *Invest Ophthalmol Vis Sci* 2002; 43(7):2067–2075
- 51 Nakanishi H, Hayashi H, Yamada R, Yamashiro K, Nakata I, Shimada N, Ohno-Matsui K, Mochizuki M, Ozaki M, Yoshitake S, Kuriyama S, Saito M, Lida T, Matsuo K, Matsuo F, Yoshimura U. Single-nucleotide polymorphisms in the promoter region of matrix metalloproteinase-1, -2, and -3 in Japanese with high myopia. *Invest Ophthalmol Vis Sci* 2010; 51(9):4432–4436
- 52 Wojciechowski R, Bailey-Wilson JE, Stambolian D. Association of matrix metalloproteinase gene polymorphisms with refractive error in Amish and Ashkenazi families. *Invest Ophthalmol Vis Sci* 2010; 51(10): 4989–4995