

Results of mitomycin – C – augmented viscocanalostomy for open–angle glaucoma

Sabur Huri¹, Baykara Mehmet²

¹Department of Ophthalmology, Agri Dogubeyazit State Hospital, RefikBaşkaya Cad, Dogubeyazit, Agri 04400, Turkey

²Department of Ophthalmology, Uludag Universitesi, Gorukle Kampusu Nilufer, Bursa 16059, Turkey

Correspondence to: Sabur Huri. Department of Ophthalmology, Agri Dogubeyazit State Hospital, RefikBaşkaya Cad, Dogubeyazit, Agri 04400, Turkey. dr_hurisabur@hotmail.com

Received: 2017-02-19 Accepted: 2017-06-20

丝裂霉素 C 联合粘小管成形术治疗开角型青光眼的疗效

Sabur Huri¹, Baykara Mehmet²

(作者单位:¹04400 土耳其,阿勒省,RefikBaşkaya Cad. 多乌巴亚泽特,阿勒省多乌巴亚泽特州立医院,眼科;²16059 土耳其,布尔萨,Gorukle Kampusu Nilufer, 乌卢山大学,眼科)

通讯作者:Sabur Huri. dr_hurisabur@hotmail.com

摘要

目的:评估丝裂霉素 C(MMC)联合粘小管成形术治疗开角型青光眼的效果。

方法:回顾性研究。收集 2007-12/2014-03 接受粘小管成形术患者 104 例 122 眼。记录术前术后眼内压(IOP),青光眼用药数量,视力,并发症,辅助治疗(激光前房角穿刺或青光眼用药)和成功率。IOP \leq 21 mmHg 无额外用药为完全成功,IOP \leq 21 mmHg 有或无青光眼用药为部分成功。

结果:术前平均 IOP 为 27.5 \pm 9.2 mmHg,术后平均 IOP 为 14.5 \pm 6.6 mmHg($P<0.001$)。术前平均视力为 0.42 \pm 0.4,术后为 0.32 \pm 0.4 ($P=0.726$)。部分成功 106 眼(86.9%),完全成功 62 眼(50.8%)。激光前房角穿刺术 43 眼(35.2%),青光眼药物使用率为 49.1%。术后平均随访 27.29 \pm 16.78 (1~79)mo。

结论:粘小管成形术并发症发生率低且术后视力稳定,是一种安全的选择,术后补充进行激光前房角穿刺术可以提高手术成功率。丝裂霉素 C 对于粘小管成形术的作用还需进行深入的比较研究。

关键词:青光眼;激光前房角穿刺术;丝裂霉素 C;手术;粘小管成形术

引用:Sabur H, Baykara M. 丝裂霉素 C 联合粘小管成形术治疗开角型青光眼的疗效. 国际眼科杂志 2017;17(9):1605-1609

Abstract

• **AIM:** To evaluate the results of mitomycin-C (MMC)-

augmented viscocanalostomy in patients with open-angle glaucoma.

• **METHODS:** This retrospective study included 104 patients who underwent viscocanalostomy surgery between December 2007 and March 2014. Pre- and postoperative intraocular pressure (IOP), number of glaucoma medications, visual acuity, complications, adjunctive procedure (laser goniopuncture and/or glaucoma medication), and success rate were recorded. Complete success was defined as IOP \leq 21 mmHg without additional medication, and qualified success was defined as IOP \leq 21 mmHg with or without glaucoma medication.

• **RESULTS:** Mean preoperative IOP was 27.5 \pm 9.2 mmHg and mean postoperative IOP was 14.5 \pm 6.6 mmHg at the last visit ($P<0.001$). Mean visual acuity before and after surgery were 0.42 \pm 0.4 and 0.32 \pm 0.4, respectively ($P=0.726$). Qualified success was achieved in 106 (86.9%) eyes and complete success was achieved in 62 (50.8%) eyes. Laser goniopuncture was performed in 43 (35.2%) eyes and glaucoma medication usage rate was 49.1%. The mean postoperative followup period was 27.29 \pm 16.78 (1-79)mo.

• **CONCLUSION:** Although viscocanalostomy is a safer option due to low complication rates and stable visual acuity, without laser goniopuncture (LGP), surgical success rate is still very low. Further comparative studies are necessary to evaluate the contribution of MMC to viscocanalostomy surgery.

• **KEYWORDS:** glaucoma; laser goniopuncture; mitomycin-C; surgery; viscocanalostomy

DOI:10.3980/j.issn.1672-5123.2017.9.01

Citation: Sabur H, Baykara M. Results of mitomycin – C – augmented viscocanalostomy for open–angle glaucoma. *Guoji Yanke Zazhi(Int Eye Sci)* 2017;17(9):1605-1609

INTRODUCTION

High intraocular pressure (IOP) is the only modifiable risk factor of glaucoma and the primary goal of glaucoma treatment is to determine the ideal target IOP at which optic nerve damage is halted. Eyes diagnosed with glaucoma can be cured *via* medical, laser, and surgical treatment methods^[1]. While the most effective surgery for decreasing IOP is trabeculectomy^[2], non – penetrating glaucoma surgeries (NPGS) are currently a trending topic, due to serious, sight-threatening complications that may be associated with trabeculectomy. Many studies have shown that NPGS decreases IOP safely and effectively^[3-6].

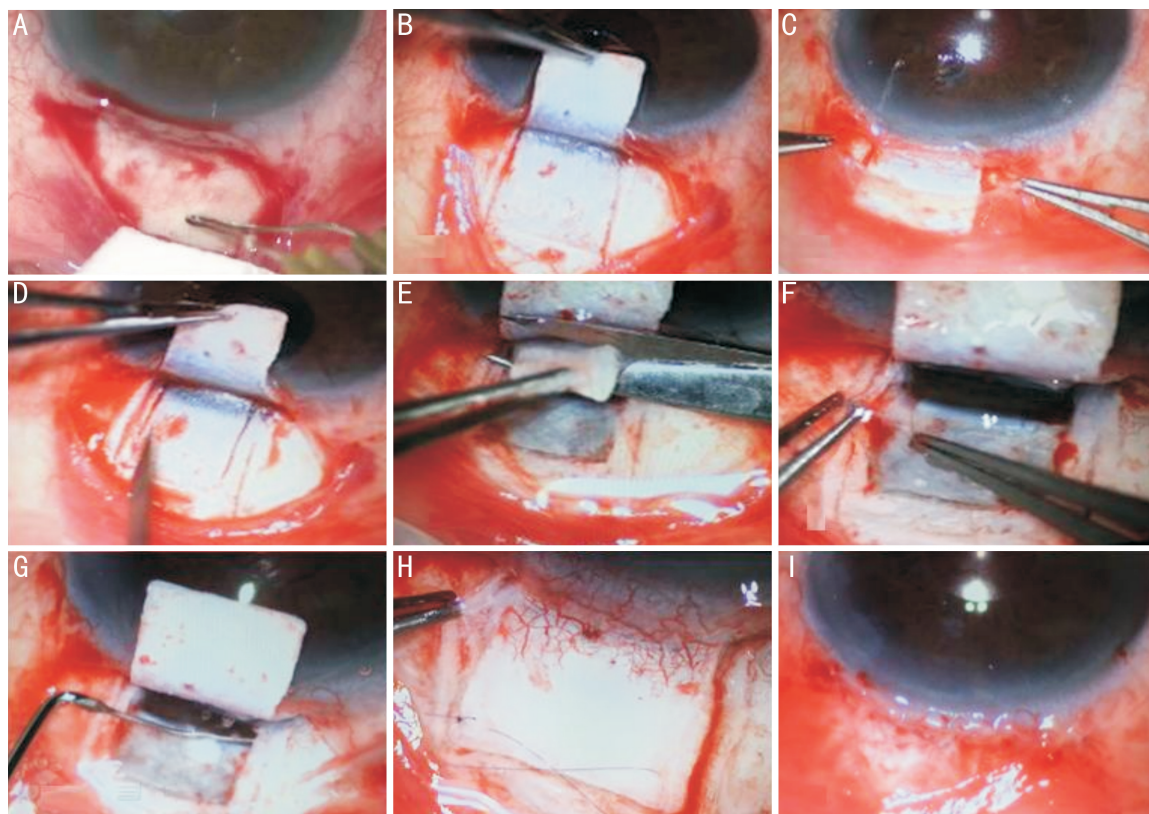


Figure 1 Surgical technique A: A fornix based conjunctival flap was made; B: 5 * 5 * 5 mm square, one third thickness scleral flap was dissected 0.5 mm into clear cornea; C: An MMC soaked gelform (0.04%) was placed above the sclera for 2min; D: A second scleral flap 4 * 4 * 4 mm, two third thickness, was dissected; E: The inner scleral flap was then excised; F: At the level of scleral spur, Schlemm's canal was deroofed; G: A 30 gauge cannula was used to inject sodium hyaluronate (14 mg/ml), both left and right; H: The superficial scleral flap was sutured loosely with 10.0 polyglactin sutures; I: Conjunctiva was closed with 10.0 polyglactin running sutures.

Viscocanalostomy is a non-penetrating glaucoma surgery that allows filtration through a thin trabeculo - Descemet's membrane (TDM) [7-8]. When the surgical method was first described, the use of antimetabolite was not preferred due to the high complication rates according to bleb formation [3]. However, it is known that fibrosis is the most important cause of surgical failure at late period. During viscocanalostomy surgery, using an antimetabolite can be more effective in decreasing IOP by increasing aqueous humor drainage from subconjunctival pathway [9-10].

The purpose of this study was to evaluate the results of mitomycin - C (MMC) augmented viscocanalostomy in the patients with open - angle glaucoma (OAG), resistant to maximum tolerated medical therapy.

SUBJECTS AND METHODS

The medical records of all open - angle glaucoma (OAG) patients who underwent viscocanalostomy surgery between December 2007 and March 2014 were evaluated retrospectively. The indication for surgery was eyes with uncontrolled IOP on maximum tolerated medication and characteristic glaucomatous visual field loss. The patients were identified from surgical logbooks and clinical databases at Department of Ophthalmology, Uludag University Faculty of Medicine. The study was approved by the local ethics committee, according to the tenets of the Declaration of Helsinki. The authors declare no financial or conflicting

interests. No research funding was received.

Pre- and postoperative IOP, number of glaucoma medication, visual acuity, complications, adjunctive procedure [laser goniopuncture (LGP) and/or glaucoma medication] and success rate were recorded. Eyes with history of trauma, eyes that had previously undergone glaucoma surgery and cases with insufficient data were excluded from the study.

Surgical Technique All surgeries were performed by one surgeon (Baykara M) and were performed under peribulbar anesthesia. Surgical technique is shown in Figure 1.

Postoperative Management All the patients were treated postoperatively with prednisolone acetate 1% four times a day for 1mo and topical antibiotics three times a day until the conjunctival polyglactin suture was absorbed. Postoperative examinations were performed on first day, first week and on first, third and sixth months after surgery and every 6mo thereafter included best corrected visual acuity (BCVA), assessed with the logMAR, Goldmann aplanation tonometry, slit lamp biomicroscopy and fundoscopy. Complete success was defined as IOP \leq 21 mmHg without additional medication and qualified success was defined as IOP \leq 21 mmHg with or without glaucoma medication.

Additional Treatments Postoperative laser goniopuncture (LGP) was preferred in cases of shallow filtering bleb and higher postoperative IOPs than targeted. The target of LGP is to decrease TDM resistance and to lower intraocular pressure

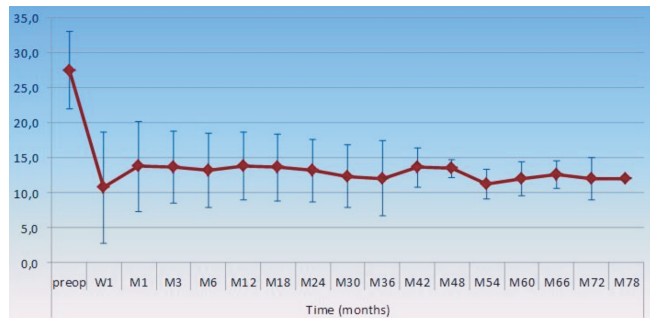


Figure 2 Mean intraocular pressure before and after MMC-viscocanalostomy Vertical bars represent ± 1 standard deviation.

Table 1 Patient demographics and preoperative data

Characteristics	mean \pm SD	P
Age (a)	60.7 \pm 16.2	
M/F	63/41	
Number of eyes	122	
Meanpreoperative IOP (mm Hg)	27.5 \pm 9.2	
Mean preoperative glaucoma medication	3.9 \pm 1.0	
Mean follow-up (mo)	27.3 \pm 16.8	
Mean deviation	-8.88 \pm 7.06 dB	
Meanpattern standard deviation	6.3 \pm 3.6 dB	
Meanvisual field index	61.2 \pm 34.6%	
POAG	85	
PXG	21	
INFG	12	
PDG	4	

IOP; Intraocular pressure; SD; Standard deviation; POAG; Primary open angle glaucoma; PXG; Pseudoexfoliation glaucoma; INFG; Inflammatory glaucoma; PDG; Pigment dispersion glaucoma.

(IOP). Neodymium-doped yttrium aluminum garnet (Nd:YAG) laser (conventional 1064 nm, free-running, Q-switched, Lpuls SYL 9000; Light Med, San Clemente, CA) was used for LGP in this study. The laser was applied under topical anesthesia, over the surgical area only (TDM), by author (Baykara M) with energy levels of 2–6 mJ, spot size of 8 μ m, and 8–10 shots. Success was defined as maintenance of intraocular pressure < 20 mmHg or 20% decrease from levels prior to LGP.

The IOPs > 21 mmHg despite the LGP and topical antiglaucoma treatment was defined as surgical failure. Patients with failed surgery underwent a second viscocanalostomy, trabeculectomy or cyclocryotherapy.

Statistical Analysis SPSS 22.0 was used to evaluate the results. Student's *t*-test was used to determine the significance of any differences in the continuous variables and for a long-term success rate, the Kaplan-Meier survival curve was used. All tests were two-tailed, and $P < 0.05$ were taken to be significant.

RESULTS

The patients' preoperative data and demographics are provided in Table 1.

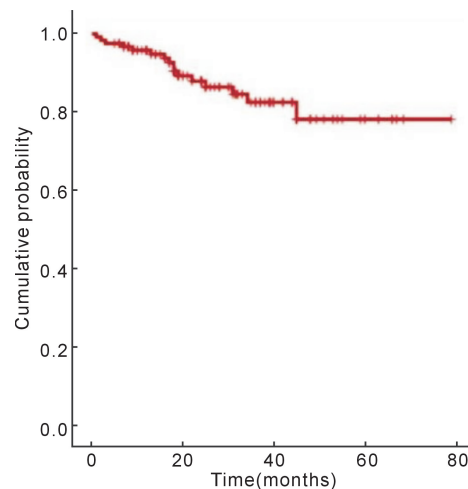


Figure 3 Kaplan - Meier survival analysis. Cumulative probability of qualified success Intraocular pressure ≤ 21 mmHg with or without glaucoma medication.

Table 2 Laser goniopuncture data

		Mean \pm SD	Median	Min-max	P
IOP (mmHg)	Before LGP	23.4 \pm 5.6	22	21-45	
	1wk	12.8 \pm 4.0	12	7-23	0.00
	1mo	13.2 \pm 4.3	13	7-25	0.00
	3mo	13.0 \pm 4.0	12	8-25	0.00
	Last visit	14.9 \pm 5.9	14	8-28	0.00

LGP; Laser goniopuncture; IOP; Intraocular pressure; SD; Standard deviation.

The mean follow-up time for all 122 eyes was 27.3mo. The mean preoperative intraocular pressure (IOP) was 27.5 \pm 9.2 mmHg and the mean postoperative first day IOP was 10.7 \pm 5.4 mmHg ($P < 0.001$). The significant reduction in IOP during the follow-up period lasted up to 78mo [$(P < 0.001$, Student *t*-test) (Figure 2)]. The decrease in IOP at the last follow-up examination was 42.1% from baseline.

Complete success rate (IOP ≤ 21 mmHg without medication) was 87.7% at 6mo, 73.7% at 12mo, and 50.8% at the last follow-up examination. Kaplan-Meier survival curve analysis showed that a cumulative probability of qualified success rate (IOP ≤ 21 mmHg with/without medication) was 95.1% at 6mo, 92.6% at 12mo, and 86.9% at 40mo and remained stable during further follow-ups (Figure 3). Qualified success was achieved in 88.2% (75/85) of primary open-angle glaucoma (POAG) eyes, 81% (17/21) of pseudoexfoliation glaucoma (PXG) eyes, 83.3% (10/12) of inflammatory glaucoma (INFG) eyes (Figure 3).

Mean best corrected visual acuity (BCVA) was 0.42 \pm 0.44 logMAR prior to surgery, and 0.32 \pm 0.38 logMAR at the last follow-up examination ($P = 0.764$, Student *t*-test).

Mean number of glaucoma medication was 3.9 \pm 1.0 (range: 0–6) prior to surgery and 1.5 \pm 1.6 (range: 0–5) at the last follow-up examination ($P < 0.001$). Number of glaucoma medication was 0.39 \pm 0.9 (range: 0–4) at 3mo and it increased through the time to 1.5 \pm 1.6 (range: 0–5) at the last follow-up examination. The last documented rate of glaucoma medication use was 49.1%.

Table 3 Postoperative complications

Complications	Number (%)
Iris incarceration	6 (4.9)
Choroidal detachment	5 (4.1)
Hyphema	4 (3.3)
Wound leakage	2 (1.6)
Decompressive retinopathy	2 (1.6)
Descemet's detachment	1 (0.8)

Laser goniopuncture was performed on a total of 43 eyes (35.2%) when IOP was > 21 mmHg. The mean time between MMC - viscocanalostomy and laser was 14.8 ± 11.3mo. The LGP data are shown in Table 2. Laser goniopuncture was considered to be unsuccessful in ten eyes, which then underwent a second surgery.

A total of 16 eyes were identified as surgical failure despite LGP procedure and medical treatment. The mean time to failure was 12.4 ± 9.5 (range: 1-40) mo. Ten of 16 eyes had POAG, four eyes had PXG, and two eyes had INFG. In this failed group, the mean preoperative IOP was 31.06 ± 10.5 mmHg, the mean preoperative number of glaucoma medication was 3.93 ± 0.5. Eleven eyes underwent trabeculectomy with adjunctive MMC, four eyes underwent second viscocanalostomy and one eye underwent cyclocryotherapy.

Postoperative complications are summarized in Table 3. One patient had Descemet's detachment which seriously threatened vision, but it is completely resolved by giving air to the anterior chamber. There were no significant complications such as blebitis, endophthalmitis.

DISCUSSION

This study of MMC-augmented viscocanalostomy includes the highest number of eyes and has the longest follow-up period of MMC-viscocanalostomy in Turkish literature. One hundred and twenty-two eyes of 104 patients were enrolled in the study, qualified success was achieved in 106 (86.9%) eyes and complete success in 62 (50.8%) eyes. The mean follow-up time of 27.3mo, and the mean decrease in IOP at the last follow up was 42%.

When the surgical method was first described, antimetabolites and loose flap sutures were not preferred, in order to avoid complications related to bleb formation^[3]. However, it is known that the major reason for surgical failure in non-penetrating glaucoma surgeries at late period was fibrosis. Therefore, when lower target IOPs are required, loose flap sutures and antimetabolites can be used to maintain long-term drainage^[9-11].

The number of studies in the literature on viscocanalostomy with adjunctive MMC is limited. At their 15mo follow-up, Lu^[9] reached a complete success rate of 69.6% and a qualified success rate of 91.3% by viscocanalostomy with adjunctive MMC in 25 Asian youngsters.

Yarangümel *et al*^[10] applied standard viscocanalostomy on 15 patients (group 1) and viscocanalostomy with adjunctive MMC on 15 patients (group 2). In the first group, IOP

decrease was found to be of 55% and complete success rate was 40%. In the second group, IOP decrease was 69% and complete success rate was 67% at the 12mo follow-up. Although the IOP decrease was greater with MMC, there were no significant differences in terms of success rate, pre- and postoperative number of glaucoma medication and even in complication rate.

The success rate in current study was somewhat lower compared to relevant literature mentioned above. This result was unexpected, as success rate is known to be higher in non-penetrating glaucoma surgeries augmented with MMC. The majority of failed eyes had blebs, but we did not think there was a relationship between bleb formation and successful filtration. In addition and in those cases, glaucoma resistance might be at the next pathways from scleral lake rather than juxtacanalicular trabecular meshwork.

It is difficult to compare the surgical success rates of studies, because there is variability of the anterior chamber among different racial groups. Viscocanalostomy which proved remarkably successful in a black population might be easier to perform in black than in white patients, as the sclera is usually thicker and the trabecular meshwork darker than in white patients^[3]. In older, white glaucoma patients, the anterior trabecular meshwork is very thin and trabecular pigmentation that can be used as a topographic landmark is often lacking^[12]. Our success rate might have been affected by the fact that our patient population consisted of white, older glaucoma patients.

Laser goniopuncture is a non-invasive, complementary adjunct to non-penetrating glaucoma surgery^[13]. In our study, laser goniopuncture (LGP) rate was 35.2% (n = 43 eyes), the mean time of application was 14.8mo and the mean IOP decrease was 33%. In our opinion, if we are going to do non-penetrating glaucoma surgeries (NPGS), we have to ready to do laser when fibrosis-related surgical failure has developed.

While the most common early postoperative complications were TDM microperforations and microhyphema, fibrosis related high IOP and iris incarceration were the most common late complications in the literature^[11,14-22]. This result is in line with our findings. The most common early complication was hyphema in 3.3% (four eyes) of cases, and the most common late postoperative complication was iris incarceration 4.9% (six eyes) of the cases. One patient had Descemet's detachment which seriously threatened the patient's vision, but it was completely resolved by providing air to the anterior chamber.

As a result, although viscocanalostomy is a safer option due to low complication rates and stable visual acuity, without laser goniopuncture (LGP), surgical success is still very low. Further comparative studies are necessary to evaluate the contribution of MMC to viscocanalostomy surgery.

REFERENCES

1 Weinreb RN, Khaw PT. Primary open-angle glaucoma. *Lancet* 2004; 363(9422):1711-1720

- 2 Schwartz AL, Anderson DR. Trabecular surge laser goniopuncture. *Arch Ophthalmol* 1974;92(2):134-138
- 3 Stegmann R, Pienaar A, Miller D. Viscocanalostomy for open-angle glaucoma in black African patients. *J Cataract Refract Surg* 1999;25(3):316-322
- 4 Wishart PK, Wishart MS, Porooshani H. Viscocanalostomy and deep sclerectomy for the surgical treatment of glaucoma: a longterm follow-up. *Acta Ophthalmol Scand* 2003;81(4):343-348
- 5 Grieshaber MC, Peckar C, Pienaar A, Koerber N, Stegmann R. Long-term results of up to 12 years of over 700 cases of viscocanalostomy for open-angle glaucoma. *Acta Ophthalmol* 2015;93(4):362-367
- 6 Guven Yilmaz S, Ateş H. Non-penetrating glaucoma surgery. *Glo-Kat* 2011;6:110-118
- 7 Johnson DH, Johnson M. How does nonpenetrating glaucoma surgery work? Aqueous outflow resistance and glaucoma surgery. *J Glaucoma* 2001;10(1):55-67
- 8 Gunenc U, Arikan G. Viscocanalostomy. *Glo-Kat* 2006;1:161-164
- 9 Lu DW. Intermediate term follow-up of intraocular pressure after mitomycin - C augmented viscocanalostomy in young patients with glaucoma. *Asian J Ophthalmol* 2001;3:3-5
- 10 Yarangümeli A, Köz OG, Alp MN, Elhan AH, Kural G. Viscocanalostomy with mitomycin - C: a preliminary study. *Eur J Ophthalmol* 2005;15(2):202-208
- 11 David VP, Kutty KG, Somasundaram N, Varghese AM. Five-year results of viscocanalostomy. *Eur J Ophthalmol* 2008;18(3):417-422
- 12 Dietlein TS. Morphological variability of the trabecular meshwork in glaucoma patients: implications for non-perforating glaucoma surgery. *Br J Ophthalmol* 2000;84(12):1354-1359
- 13 Tam DY, Barnebey HS, Ahmed II. Nd:YAG laser goniopuncture: indications and procedure. *J Glaucoma* 2013;22(8):620-625
- 14 Mermoud A, Karlen ME, Schnyder CC, Sickenberg M, Chiou AG, Hediguer SE, Sanchez E. Nd:YAG goniopuncture after deep sclerectomy with collagen implant. *Ophthalmic Surg Lasers* 1999;30(2):120-125
- 15 Karlen ME, Sanchez E, Schnyder CC, Sickenberg M, Mermoud A. Deep sclerectomy with collagen implant: medium-term results. *Br J Ophthalmol* 1999;83(1):6-11
- 16 Shaarawy T, Nyugen C, Schnyder C, Mermoud A. Five year results of viscocanalostomy. *Br J Ophthalmol* 2003;87(4):441-445
- 17 Ambresin A, Shaarawy T, Mermoud A. Deep sclerectomy with collagen implant in one eye compared with trabeculectomy in the other eye of the same patient. *J Glaucoma* 2002;11(3):214-220
- 18 Anand N, Atherley C. Deep sclerectomy augmented with mitomycin C. *Eye* 2005;19(4):442-450
- 19 Khairy HA, Green FD, Nassar MK, Azuara-Blanco A. Control of intraocular pressure after deep sclerectomy. *Eye* 2006;20(3):336-340
- 20 Detry - Morel M, Detry MB. Five-year experience with non penetrating deep sclerectomy. *Bull Soc Belge Ophthalmol* 2006;(299):83-94
- 21 Drolsum L. Long-term follow-up after deep sclerectomy in patients with pseudoexfoliative glaucoma. *Acta Ophthalmol Scand* 2006;84(4):502-506
- 22 Rekonen P, Kannisto T, Puustjarvi T, Terasvirta M, Uusitalo H. Deep sclerectomy for the treatment of exfoliation and primary open-angle glaucoma. *Acta Ophthalmol Scand* 2006;84(4):507-511