

# Conjunctival squamous cell carcinoma: outcome analysis of 55 cases in Abidjan

Rokia Coulibaly Berete<sup>1</sup>, Thierry Yves Constant Sowagnon<sup>2</sup>, Abokan Joel Konan<sup>1</sup>, Sylvanius Beossin Kou<sup>3</sup>, Sandrine Kouassi Kouakou<sup>1</sup>, Simon N'Dri Dede<sup>4</sup>, Adama Fanny<sup>1</sup>

<sup>1</sup>Department of Ophthalmology, the Teaching Hospital of Treichville, 01 BP V3 Abidjan 01, Ivory Coast

<sup>2</sup>Department of Ophthalmology, the Teaching Hospital of Yopougon, 21 BP 632 Abidjan 21, Ivory Coast

<sup>3</sup>Department of Pathology, Teaching Hospital of Treichville, 01 BP V3 Abidjan 01, Ivory Coast

<sup>4</sup>Department of Imaging, Teaching Hospital of Treichville, 01 BP V3 Abidjan 01, Ivory Coast

**Correspondence to:** Rokia Coulibaly Berete. Department of Ophthalmology, University Hospital of Treichville, Abidjan, Ivory Coast. [bereterokia@hotmail.fr](mailto:bereterokia@hotmail.fr)

Received: 2017-02-07 Accepted: 2017-10-11

## 科特迪瓦阿比让 55 例结膜鳞状细胞癌结果分析

Rokia Coulibaly Berete<sup>1</sup>, Thierry Yves Constant Sowagnon<sup>2</sup>, Abokan Joel Konan<sup>1</sup>, Sylvanius Beossin Kou<sup>3</sup>, Sandrine Kouassi Kouakou<sup>1</sup>, Simon N'Dri Dede<sup>4</sup>, Adama Fanny<sup>1</sup>

(作者单位: <sup>1</sup>科特迪瓦,阿比让,特雷什维尔教学医院,眼科; <sup>2</sup>科特迪瓦,阿比让,尤布贡教学医院,眼科; <sup>3</sup>科特迪瓦,阿比让,特雷什维尔教学医院,病理科; <sup>4</sup>科特迪瓦,阿比让,特雷什维尔教学医院,影像科)

通讯作者: Rokia Coulibaly Berete. [bereterokia@hotmail.fr](mailto:bereterokia@hotmail.fr)

### 摘要

**目的:** 研究 55 例结膜鳞状细胞癌的流行病学、临床特点,以及艾滋病毒对其发病情况的影响。

**方法:** 横断面研究,纳入就诊于阿比让特雷什维尔大学医院眼科的 54 例 55 例结膜鳞状细胞癌患者。收集的数据包括书面问卷、眼科检查、病理检查、HIV 血清学检查、治疗情况(手术及化疗)、随访情况和预后。

**结果:** 患者年龄为 7~75(平均 42.28)岁。女性占 53%。发病到就诊时间 6~60(平均 18)mo。患者平均随访 29mo。共有 53%(29 眼)无视功能。54 例患者中 42 例 HIV 阳性,28 例为 HIV1 感染,4 例为 HIV2 感染,10 例为混合感染。这 42 例患者中 28 例进行了淋巴细胞分类检查,结果显示 33% 的患者 CD4 细胞计数 <200/mL,19% 的患者 200~500/mL,12% 的患者 >500/mL。42 眼(76%)为侵袭性分化型鳞状细胞癌,13 眼(24%)为原位癌。40 例(73%)局部肿瘤进行了肿块切除,其中 6 例进行了术后局部辅助化疗。社会经济情况分析显示 39% 的患者经济情况较差。

**结论:** HIV 感染是结膜鳞状细胞癌发病的危险因素,尤其是在撒哈拉以南的非洲。这一疾病不良预后可能与患者

社会经济情况较差,我们治疗机构中医疗资源不足,抗肿瘤药物治疗经费较少有关,HIV 感染也对疾病有一定影响。

**关键词:** 上皮癌;鳞状细胞;获得性免疫缺陷病毒

**引用:** Berete CR, Sowagnon TYC, Konan AJ, Kou SB, Kouakou KS, Dede NS, Fanny A. 科特迪瓦阿比让 55 例结膜鳞状细胞癌结果分析. 国际眼科杂志 2017;17(12):2187-2192

### Abstract

• **AIM:** To determine epidemiological, clinical profile and access the impact of HIV in its occurrence in 55 eyes of conjunctival squamous cell carcinoma.

• **METHODS:** A cross sectional study, 55 eyes of 54 patients affected by conjunctival squamous cell carcinoma (CSCs) presented in the Ophthalmology Department of University Hospital of Treichville in Abidjan were included. Data were collected: interrogatories, ophthalmologic examination, histopathologic finding, HIV serology, therapeutic (surgery, chemotherapy), follow-up and prognosis. The statistical analysis was performed using Epi-info version 6.0 and a statistical comparison was performed using the Chi-square test with a significance threshold set at 5%.

• **RESULTS:** The age ranged 7-75y (median age 42.28). A female predominance was observed with a sex-ratio of 0.89. The average consultation period was 18mo, with extremes ranging from 6-60mo. Physically 53% of our eyes (29 eyes) presented a functional loss of the eye. And 42 out of the 54 patients were HIV positive with 28 cases of HIV1 infection, 4 cases of HIV2 infection and 10 cases of HIV1 and 2 co-infection. Lymphocyte typing was performed for 28 out of 42 patients with CD4 cell counts <200/mL in 33% of cases, between 200 and 500 in 19% of cases and 500/mL in 12% of cases. It was noted 42 cases (76%) of invasive differentiated squamous cell carcinoma, and 13 cases (24%) of squamous cell carcinoma *in situ*. Forty localized tumors underwent tumor resection (73%) associated with a postoperative adjuvant topical chemotherapy in 6 cases. Socioeconomic status showed 39% of patients were economic cally inactive. The average follow up period of our patients was 29mo.

• **CONCLUSION:** HIV infection is a risk factor for the occurrence of conjunctival squamous cell carcinoma

especially in sub-Saharan Africa where the fight against the infection although boosted in these recent years is far from achieving all objectives. The poor prognosis of conjunctival squamous cell carcinoma reflects the low socioeconomic status of patients, the inadequate medical care in our facilities, the prohibitive cost of anticancer drugs and the link between this disease and HIV/AIDS.

• **KEYWORDS:** carcinoma; squamous cell; acquired human immunodeficiency

DOI:10.3980/j.issn.1672-5123.2017.12.01

**Citation:** Berete CR, Sowagnon TYC, Konan AJ, Kouï SB, Kouakou KS, Dede NS, Fanny A. Conjunctival squamous cell carcinoma; outcome analysis of 55 cases in Abidjan. *Guoji Yanke Zazhi(Int Eye Sci)* 2017;17(12):2187-2192

## INTRODUCTION

Conjunctival squamous cell carcinomas are neoplasias of the ocular surface, rare, which present a recrudescence and a high mortality rate<sup>[1]</sup>. They are divided into 2 major entities: *in situ* carcinomas that reach the thickness of the conjunctiva with respect to the basement membrane and invasive carcinomas characterized by their capacity for extension in depth and metastases<sup>[2]</sup>. It is a common condition in adults but is an uncommon or under-diagnosed cancer. Their incidence is variously estimated 0.03 per 100 000 inhabitants/year in the USA, 0.13 per 100 000 inhabitants/year in Uganda and 1.9 per 100 000 inhabitants/year in Australia. They are more common in adults in countries near the equator due to high UV exposure, as well as in young people with HIV infection. Their incidence would be increasing in tropical Africa due to prolonged exposure to ultraviolet rays but also due to the recrudescence of human immunodeficiency virus (HIV) infection, especially in sub-Saharan Africa<sup>[3-5]</sup>. The aim of our study is to analyze the epidemiological and clinical parameters of conjunctival squamous cell carcinomas in order to assess the impact of HIV/AIDS in their occurrence.

## SUBJECTS AND METHODS

We carried out a descriptive cross-sectional study over a period of 9y, from January 2007 to December 2016 in the Ophthalmology Department of the University Hospital Treichville. The study involved 55 eyes from 54 patients all admitted and treated in our department. This study included all patients who consulted during the period and presented a conjunctival tumor with or without locoregional and cerebral invasion as well as a histopathology diagnosis of squamous cell carcinoma. The data collected included the elements of the anamnesis (age, gender, race, onset of symptom, personal and family history including HIV infection, consultation time, clinical signs, elements of ophthalmological examination, HIV serology, radiological examination, surgical management, medical management, histopathology, and evolution). The pathological diagnosis is obtained after analysis of incisional biopsy fragment or surgical excision specimen and/or

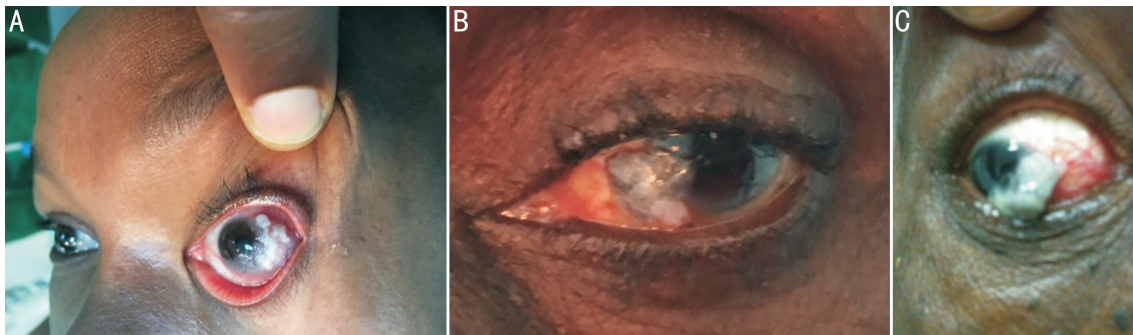
enucleation or even exenteration. All surgical gestures are performed under general anesthesia. The samples were fixed to formalin before being transferred to the pathology department. The HIV serological status was noted on admission when the patient knew his status. If need be, HIV-AIDS serology is performed after informed consent. When HIV positive status is confirmed in the patient, CD4 T-cell typing is proposed to the patient. Patients presenting lesions with regional or cerebral extension were referred to the cancer registry for neoadjuvant or adjuvant general chemotherapy in addition to surgery. Patients with localized tumor received a prescription for topical chemotherapy (mitomycin C, cyclophosphamide) in an attempt to reduce the size of the tumor or after surgery to control of local disease. All patients were operated under general anesthesia for either biopsy, biopsy resection, enucleation or exenteration. The statistical analysis was performed using Epi-info version 6.0 and a statistical comparison was performed using the Chi square test with a significance threshold set at 5%.

AJCC 8th Edition classification of conjunctival carcinoma (OSNN) was using<sup>[6]</sup>. The clinical classification based on tumor size ( $\leq 5$ mm versus  $>5$ mm), tumor invasiveness [*in situ*, substantia propria, adjacent structures (fornix, plica semilunaris, caruncle, palpebrum), orbit, bone, sinus and brain].

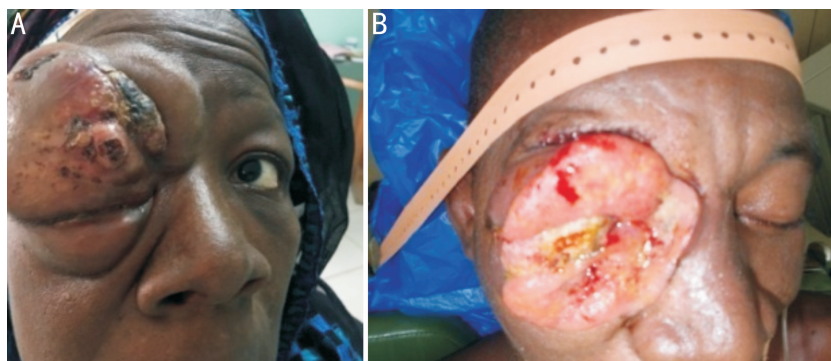## RESULTS

**Epidemiological Results** We found 55 cases for 9y. The frequency of conjunctival squamous cell carcinoma in the Ophthalmology Department of University Hospital of Treichville, could be estimated as 6 cases per year. The age ranged 7-75y (median age 42.28). Patients age range included: 7-24, 1; 25-45, 28; 46-65, 21; over 65y, 4. Twenty-nine patients were aged less than 45y (54%), however, only 7% were aged  $>65$ . The standard deviation (SD) 11.78 and 138.77 as variance. Female predominance was observed and a sex-ratio equal to 0.89. All patients were black and resided in Abidjan (sub-Saharan Africa).

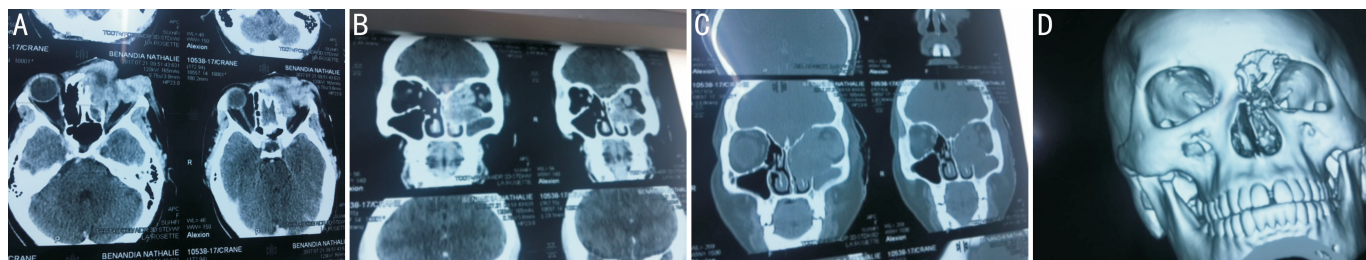
**Clinical Results** The average consultation period was 18mo with extremes ranging from 6-60mo. Three clinical appearance of CSCs were found: localized limbal conjunctival and/or corneal in 22 (40%) (Figure 1), localized orbital with exophthalmos in 18 (33%) (Figure 2), diffuse invasion (bulbe, eyelid, orbit, and/or sinus, brain) in 15 (27%) (Figure 3). In most cases, the right eye was involved in 66% of the cases, with one case of bilateral involvement in a 7-year-old girl. Physically, 53% of our eyes (29 eyes) presented a functional loss of the eye (absence of luminous perception). We realized a sectional cross study who has limits. It is difficult to establish a clear classification. All tumors were large sizes greater than 10mm. They were: localized on limbus, cornea, orbit in 40 cases (73%), extended diffuse invasion with metastasis (sinus, brain) in 15 cases (27%).



**Figure 1 Conjunctival–limbal–corneal tumor** A; Leucoplakia form; B; Leucoplakia form coated with a patch of keratin; C; Gelatinous–translucent form; Patients in A and B; localized carcinoma without VIH; Patient in C; with VIH.



**Figure 2 Orbital extension of conjunctival squamous cell carcinoma with exophthalmos** A; Cyst form; B; Ulcers form; Both with HIV.



**Figure 3 Contrast enhanced computed tomography (CT) images of orbit and brain in a patient with invasive squamous cell carcinoma on left eye** A; Axial view shows heterogeneously enhanced soft tissue masse lesion; B; Coronal view with bony destruction; C; Bony window shows intracranial extension on left temporal region; D; 3D–CT image shows destruction of left ethmoid bone causing intracranial extension.

**Table 1 Serologique status**

Parameters	Positive	Negative	Indefinite
Effective	42	11	1
Percentage	78%	20%	2%

**Table 2 VIH subtypes**

Parameters	VIH 1	VIH 2	VIH 1+2
Effective	28	4	10
Percentage	67%	9%	24%

VIH=acquired human immunodeficiency virus.

**Table 3 CD4 lymphocyte rate**

Parameters	<200	200–500	>500	Non precise	Total
Effective	14	8	5	15	42
Percentage	33%	19%	12%	36%	100%

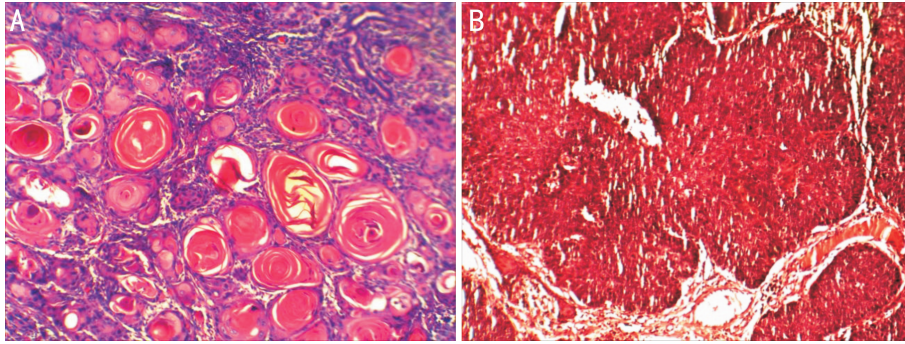
CD4 rate was found in 27 cases (64%).

**HIV Status** Forty–two out of the 54 patients had positive serological status with 28 cases of HIV1 infection, 4 cases of

HIV 2 infection and 10 cases of HIV 1 and 2 co–infection. VIH was not defined in one case. Lymphocytic typing was performed for 27 out of 42 patients that is 64% with CD4 cell counts 200/mL in 33% of cases, between 200 and 500/mL in 19% of cases and 500/mL in 12% of cases. The mean CD4 count was estimated to be 131/mL.

**Radiological Aspect** Radiologically, we noted 15 cases that is 27% of extra–ocular extension seen on the orbito–cerebral CT scan (Figure 3); heterogeneously enhanced tissue in intraconal orbit compartment, brain and sinus extension, bony destruction.

**Management** Our study noted 40 localized forms (73%) and 15 advanced forms (27%) whose underwent the medical care included a medical component and a surgical component. On surgical component, 17 biopsy, 32 tumor excision, 4 enucleations and 2 exenterating were performed. The medical treatment was only available for 15 patients (27%). This component consisted of the administration of adjuvant topical chemotherapy (mitomycin C, cyclophosphamide)



**Figure 4 Histology** A: Mature squamous cell carcinoma (HE, X100): variable size of lobules of squamous cells centered by keratinization; B: Immature squamous cell carcinoma (HE, X100): anastomosed lobules of squamous cells without keratinization; Squamous cells exhibit marked cell nucleus atypia.

**Table 4 Socio economic status**

Parameters	Economic cally inactive <sup>a</sup>	Retreat	Sales work and none classified work	Administrative and clerical work	Private employee	Total
Effective	21	8	16	5	4	54
Percentage	39%	15%	30%	9%	7%	100%

<sup>a</sup>Patients with low economic status.

in 6 localized tumor (after excision to control of local disease in 4 cases, in an attempt to reduce the size of 2 tumor before surgery) and systemic chemotherapy in 9 patients; neoadjuvant chemotherapy in 4 patients with cerebral tumor extension before surgery, adjuvant chemotherapy in 5 patients (2 patients with orbital localization without brain damage, 3 patients orbit and brain extension). Neoadjuvant chemotherapy of 4 patients with cerebral extension occurred as 2 patients: 50mg of cyclophosphamide tablet, 2 others with combination of irinotecan, cisplatin, doxorubicin.

**Follow Up** After 2y of follow-up, 3 of the 5 patients who benefited from adjuvant chemotherapy died that is 60%. We noted 3 recurrences, 1 localized form who underwent surgical excision and topic mitomycin, 1 localized expended on orbit, 1 orbit form expended metasis in brain, both underwent adjuvant chemotherapy. Fourteen patients are lost to follow-up (26%) whose 8 with extended forms (57%). The average follow-up time for our patients was 29mo.

**Pathological Findings** There were 42 cases of invasive differentiated squamous cell carcinoma (76%), compared with 13 cases of squamous cell carcinoma *in situ* (24%).

The tumors were assessed in both biopsies, excisional biopsy, enucleation or exenteration. Tumors fragment were fixed in formol stains, processed to paraffin and section satins was used to evaluate basement membrane integrity and the presence of mucin. This study is not prospective, we were unable to histological features regarding to local, extraorbital extension and lymph node metastasis. Lesions were categorised as intraepithelial squamous cell carcinoma (*in situ* carcinoma) and invasive carcinoma. We provided more pathological details mentioned in Figure 4 as follow.

**DISCUSSION**

Conjunctival squamous cell carcinoma is a condition occurring inelderly patients, subjects over 50y of age<sup>[7]</sup>. There was a

lower mean age in our study was 42.28y. It is rare tumor<sup>[8]</sup>, we noted 6 cases per year; however we can find different geographic frequency without real gender predominance (sex ratio in the literature is 1)<sup>[9]</sup>. In our study this sex ratio was 0.89 with 53% female. On the other hand, authors, as Caujolle *et al*<sup>[11]</sup> and Ogun *et al*<sup>[10]</sup>, have found a male predominance. This finding in sub-Saharan Africa could be explained by the tendency to feminize HIV infection with 6.4% vs 2.9% of seroprevalence in males<sup>[11]</sup>. Indeed, HIV infection as well as prolonged solar exposure and human papilloma virus (HPV) infection are unanimously recognized as risk factors<sup>[12]</sup> especially in tropical Africa. This female population represents the population group most exposed to abuse of all kinds (sexual, polygamy and agricultural activities etc) in Africa where they support men to this day. This observation of the predominance of the female gender in the occurrence of the CSCs in HIV-positive subjects was also made by Kaimbo Wa Kaimbo *et al*<sup>[13]</sup> in Congo and by Makupa *et al*<sup>[14]</sup> in Tanzania who found 70% and 62.2% respectively. HIV induces chronic suppression of the immune system and the anti-cancer immunity consequently, which increases oncogenic potential especially in dysplasia<sup>[15-16]</sup>. We found 78% of HIV positive patients with a statistically significant link as well in correlation with HIV infection as with CD4 level. Indeed, Wadell *et al*<sup>[4]</sup> And Newton *et al*<sup>[17]</sup> associate squamous cell carcinomas with HIV-AIDS. The HIV-AIDS virus is considered to be a risk factor for the occurrence of conjunctival squamous cell carcinomas<sup>[2,18]</sup>. The two phrases not coincide. The comparition is still difficult. It should be noted that HIV positive was identified in 42 of 54 patients (78%). Although CD4 lymphocytes could not be administrated to 28 of 42 patients whose represent 64% of 42 seropositives and 51% of all patients.

In our series, 33% of HIV infected patients had very low

level of CD4 T-lymphocytes and the highly advanced forms were found in this group of patients in a statistically significant way ( $P=0.001$ ). This link was also established by Makupa *et al*<sup>[14]</sup>. And Shields *et al*<sup>[19]</sup>. Immune depression seems to play a role in the evolution of the pathology. The malignant transformation of conjunctival dysplastic lesions caused by ultraviolet radiation is more common in HIV - infected patients. In addition, polygamy which is very common in our regions would lead to a more increased vulnerability to HIV/AIDS. As a result, the relative high prevalence of HIV infection despite efforts to combat HIV and the delay in management due to poverty of populations, ignorance, absence or remoteness of hospital centers, or denial of disease, would be responsible for the advanced forms of the disease with a high rate of mortality.

We found 42 cases of CSCs invasive (76%) versus 13 CSCs *in situ* (24%) (Figure3). These were similar in the histopathological lesions from our last and other two countries studies<sup>[4,7]</sup>. In our study, socio economic status showed that 39% of patients were economic cally inactive, 15% retreat, 30% with sales work and only 16% for administrative and private employee. A significant number had outdoor occupation, low socioeconomic status and inability to afford treatment was common among our patient<sup>[7,11]</sup>.

The management of CSCs involves surgical resection versus non - surgical therapy, including topical chemotherapy (mitomycin C, 5 - fluorouracil), topical and injection immunotherapy (interferon alpha - 2b), topical antiviral medication (cidofovir), photodynamic therapy (PDT)<sup>[6]</sup>. Chemotherapy could be used as adjuvant or neoadjuvant treatment of CSCs to reduce tumor size before surgery or complete treatment after surgery<sup>[20-21]</sup>. The cost of surgical versus medical treatments found equal efficacy of both treatment<sup>[22]</sup>. Surgical management were performed in all patients of our study for diagnosis and /or therapeutic (17 biopsy, 32 tumor excision, 4 enucleation, 2 exenteration). Cancer chemotherapy was available only in 15 patients: topic chemotherapy in only 6 patients and 9 systemic chemotherapy. It is the only therapeutic resource in the advanced forms in our country. Patients with invasive CSCs in Abidjan present late, the average consultation period was 18mo and have significant delay before having any treatment because of their low socio-economic status compare to the prohibitive cost of anticancer drugs. Others treatments with proven efficacy have been mentioned in the literatures: cryotherapy, fractionated strontium - 90 radiation would have great efficacy in population with high prevalence of HIV, while in our population 78% of patients were HIV positive, 1/3 (33%) with CD4 cells less than 200/mL<sup>[3,23]</sup>.

Innovation in this area of management is called immunotherapy, which is a therapeutic method based on the body's own defenses. Its mechanism involves stimulation of the patient's immune system by administration of antibodies directed against cancer cells but also against factors necessary

for the multiplication of malignant cells. This innovation according to studies would increase the survival rate to more than 30% or even double. Interferon alpha 2b (IFN $\alpha$ 2b) recognized as an excellent drug for immunotherapy. Some authors consider this medication as alternative of surgery or radiotherapy management. This therapy seems to archived complete control of tumor<sup>[24-25]</sup>. The worry remains its undesirable effects and the cost which will surely constitute a brake to its use in our heavily indebted poor countries unlike the industrialized nations. The prognosis of CSCs remains poor in our study. With 29mo of the average follow-up, we found 3 of 5 patients who underwent adjuvant chemotherapy died. Fourteen patients were lost to follow - up (26%). The 3 patients who died on adjuvant chemotherapy course had a very involves forms (Figure 2 and 3) with positive surgical margin. In additional they were VIH positive with CD4 rate below 200 cel/mL. McKelvie *et al*<sup>[20]</sup> found higher death rates with 26 patients evaluated over 6y, therefore, study noted low rate of lost to follow up.

In this study we can established relationship between CSCs occurrence (54 patients) and infection of VIH infection and specially (78% HIV positive). HIV remains the main risk factor for CSCs occurrence. In any case, we must not forget other factors not less important as UV exposure, infection with HPV virus<sup>[2-3,20]</sup>. The occurrence of extended forms (77.8%) is related to rate low rate of CD4 lymphocyte (52% was <500 cell/mL) on the one hand and the other hand, leading to faster tumor grow with the onset of metastasis and the low socioeconomic conditions leaning to a very long delay of consultation period, an inability to take care of quickly with mostly a health insurance absence. All patients whose died and more than half of patients loss of follow up were HIV positive with surely rate of CD4 lymphocyte below 500 cell/ml. The prevention of invasive CSCs involves sensibilization, screening of patients with suspicious of conjunctival tumors and above all, localized CSCs confirmed must be taken care optimally.

HIV infection is a risk factor for the occurrence of conjunctival squamous cell carcinoma, especially in sub-Saharan Africa, where the fight against infection, although boosted in these recent years, is far from achieving all objectives. This seroprevalence is very often associated with opportunistic infections which include carcinogenic processes such as conjunctival squamous cell carcinomas. The extended forms as relationship between the low rate of CD4 lymphocyte. Squamous cell carcinomas are neoplasia of the adult's eye surface relatively uncommon in sub - Saharan Africa. The proximity of the equator, with exposure of the population to UV rays, some viral infectious agents including human immunodeficiency virus (HIV) are the main risk factors. Even if *in situ* carcinoma remains the prerogative of subjects aged 50 - 60y, there is a recrudescence of invasive forms in the younger population infected with HIV with a late diagnosis. The particular gravity of squamous cell carcinomas

is related to depression of CD4 lymphocytes. HIV infection in Africa can be considered a risk factor for the occurrence of conjunctival squamous cell carcinoma.

#### REFERENCES

1 Caujolle JP, Maschi C, Chauvel P, Herault J, Gastaud P. Surgery and additionnel proton therapy for treatment of invasive and recurrent squamous cell carcinomas : technique and preliminary results. *J Fr Ophthalmol* 2009;32(10):707-714

2 Amoll FA, Heidari AB. Surgery of 447 patients with conjunctival neoplastic lesions in Farabi eye Hospital, Teheran, Iran. *Ophthalmic Epidemiol* 2006;13(4):275-279

3 Poso MY, Mwanza JC, Kayembe DL. Malignant tumors of the eye and adnexa in Congo-Kinshasa. *J Fr Ophthalmol* 2000;23(4):327-332

4 Wadell KM, Lewallen S, Lucas SB, Ateenyi-Agaba C, Herrington G, Herrington CS, Liomba G. Carcinoma of the conjunctive and HIV infection in Uganda and Malwi. *Br J Ophthalmol* 1996;80(6):503-508

5 Kiire CA, Dhillon B. The aetiology and associations of conjunctival intraepithelial neoplasia. *Br J Ophthalmol* 2006;90(1):109-113

6 Shields CL, Chien JL, Surakiatchanukul T, Sioufi K, Lally SE, Shields JA. Conjunctival tumors: review of clinical features, risks, biomarkers, and outcomes--The 2017 J. Donald M. Gass Lecture. *Asia Pac J Ophthalmol (Phila)* 2017;6(2):109-120

7 Berete CR, Desjardins L, Kouassi LJ, Coulibaly F, Kouakou KS, Gbe K, Fanny A. Relationship between human immunodeficiency virus (HIV-AIDS) and conjunctival squamous cell carcinoma: A clinical epidemiological study of 26 cases in the ophthalmology department of the university hospital of Treichville-Abidjan (Abidjan-Côte d'Ivoire). *J Fr Ophthalmol* 2016;39(5):467-473

8 Melgares-Ramos Mde L, Carnesoltas-Lázaro D, Silveira-Melgares YS, Domínguez-Odio A. [Subconjunctival chemotherapy in patients with acquired immunodeficiency syndrome. Experimental study of 3 clinical cases]. *Rev Med Inst Mex Seguro Soc* 2015;53(5):564-568

9 Acis D, Donnio A, Ayéboua L, Richer R, Guyomarch J, Wärter A, Merle H. [Conjunctival squamous cell carcinoma. Four cases reported in the French West Indies]. *J Fr Ophthalmol* 2008;31(5):533. e1-5

10 Ogun GO, Ogun AO, Bekilrele CO, Akang EE. Intraepithelial and invasive squamous neoplasms of the conjunctiva in Ibadan, Nigeria: a clinicopathological study of 46 cases. *Int Ophthalmol* 2009;29(5):401-409

11 Dagnan NS, Tiembré I, Bi Vroh JB, Diaby B, Zengbe-Acray P, Attoh - Touré H, Adjoua D, Ekra KD, Tagliante - Saracino J. [Seroprevalence of HIV infection in the context of a mobile counseling and voluntary testing strategy in rural areas of Côte d'Ivoire]. *Sante Publique* 2013;25(6):849-856

12 Ateenyi-Agaba C. Conjunctival squamous- cell carcinoma associated with HIV infection in Kampala, Uganda. *Lancet* 1995;345(8951):695-696

13 Kaimbo Wa Kaimbo D, Parys-Van Gingerdeuren R, Missoten L. Conjunctival squamous cell carcinoma and intraepithelial neoplasia in AIDS patients in Congo-Kinshasa. *Bull Soc Belge Ophthalmol* 1998;268:135-141

14 Makupa II, Swai B, Makupa WU, White VA, Lewallen S. Clinical factors associated with malignancy and HIV status in patients with ocular surface squamous neoplasia at Kilimanjaro Christian medical centre, Tanzania. *Br J Ophthalmol* 2012;96(4):482-484

15 Dalton-Griffin L, Kellam P. Infectious causes of cancer and their detection. *J Biol* 2009;8(7):67

16 Verma V, Shen D, Sieving PC, Chan CC. The role of infectious agents in the etiology of ocular adnexal neoplasia. *Surv Ophthalmol* 2008;53(4):312-331

17 Newton R, Ziegler J, Ateenyi-Agaba C, Bousarghin L, Casabonne D, Beral V, Mbidde E, Carpenter L, Reeves G, Parkin DM, Wabinga H, Mbulaiteye S, Jaffe H, Bourbouliou D, Boshoff C, Touzé A, Coursaget P; Uganda Kaposi's Sarcoma Study Group. The epidemiology of conjunctival squamous cell carcinoma in Uganda. *Br J Cancer* 2002;87(7):301-308

18 Biswas J, Sudharshan S. Anterior segment manifestations of human immunodeficiency virus/acquired immune deficiency syndrome. *Indian J Ophthalmol* 2008;56(5):363-375

19 Shields CL, Ramasubramanian A, Mellen PL, Shields JA. Conjunctival squamous cell carcinoma arising in immunosuppressed patients (organ transplant, human immunodeficiency virus infection). *Ophthalmology* 2011;118(11):2133-2137

20 McKelvie PA, Daniell M, McNab A, Loughnan M, Santamaria JD. Squamous cell carcinoma of the conjunctiva: a series of 26 cases. *Br J Ophthalmol* 2002;86(2):168-173

21 Nair AG, Kaliki S, Mishra DK, Reddy VA, Naik MN. Neoadjuvant chemotherapy for invasive squamous cell carcinoma of the conjunctiva: A case report. *Indian J Ophthalmol* 2015;63(12):927-929

22 Lecuona K, Stannard C, Hart G, Rice J, Cook C, Wetter J, Duffield M. The treatment of carcinoma in situ and squamous cell carcinoma of the conjunctiva with fractionated strontium-90 radiation in a population with a high prevalence of HIV. *Br J Ophthalmol* 2015;99(9):1158-1161

23 Nanji AA, Sayyad FE, Karp CL. Topical chemotherapy for ocular surface squamous neoplasia. *Curr Opin Ophthalmol* 2013;24(4):336-342

24 Shields CL, Kaliki S, Kim HI, Al-Dahmash S, Shah SU, Lally SE, Shields JA. Interferon for ocular surface squamous neoplasia in 81 cases outcomes based on the American Joint Committee on cancer classification. *Cornea* 2013;32(3):248-256

25 Nanji AA, Moon CS, Gah A, Sein J, Oellers P, Karp CL. Surgical versus medical treatment of ocular squamous neoplasia: a comparison of recurrences and complications. *Ophthalmology* 2014;121(5):991-1000