

Toric intraocular lens for correction of high corneal astigmatism in cataract patients

Irene Simo¹, Rafael Freiria¹, Laura Remón²

Foundation item: This study was supported by the Ministerio de Economía y Competitividad (Grant DPI 2015-71256-R), Spain.

¹Departament of Ophthalmology, Marina Salud Hospital, Denia 03700, Spain

²Departament of Applied Physics, University of Zaragoza, Zaragoza 50009, Spain

Correspondence to: Laura Remón. Departament of Applied Physics, C/Pedro Cerbuna 12, Zaragoza 50009, Spain. lauremar@unizar.es

Received: 2017-08-18 Accepted: 2017-12-13

Toric 人工晶状体在合并高度角膜散光白内障中的应用

Irene Simo¹, Rafael Freiria¹, Laura Remón²

基金项目: 西班牙经济部资助项目 (Grant DPI 2015-71256-R)

(作者单位: ¹03700 西班牙, 德尼亚, Marina Salud 医院, 眼科;

²50009 西班牙, 萨拉戈萨, 萨拉戈萨大学, 应用物理学系)

通讯作者: Laura Remón. lauremar@unizar.es

摘要

目的: 评估 Bi-Flex toric 人工晶状体在合并散光的白内障中的应用。

方法: 回顾性研究包括 16 例 22 眼合并 2.50D 以上散光的白内障患者。测量了术前与术后的裸眼视力、最佳矫正视力、客观及主观验光、角膜散光仪和角膜地形图测量的散光值。术后人工晶状体屈光轴位置使用向量进行分析。

结果: 术后, 主观验光散光值从 $4.05\text{D} \pm 1.53\text{D}$ 显著降低至 $1.35\text{D} \pm 0.86\text{D}$, ($P < 0.05$)。屈光轴位置指标 J_0 , 从术前的 $-0.81 \pm 2.02\text{D}$ 降至 $-0.12 \pm 0.62\text{D}$ ($P < 0.05$)。裸眼视力和最佳矫正视力术后 1mo 时均显著改善 ($P < 0.05$), 分别为 0.24 ± 0.19 和 0.06 ± 0.08 。人工晶状体屈光轴旋转程度平均为 2.95 ± 5.25 度, 86.36% 的患眼旋转程度小于 10 度。术前、术后角膜散光计测量值未见显著差异 (J_0 和 J_{45} 均有 $P > 0.05$)。

结论: 对于合并大于 2.50D 散光的白内障患者, Bi-Flex toric 人工晶状体植入是安全有效的治疗方法。

关键词: toric 人工晶状体; 散光; 稳定性; 向量分析

引用: Simo I, Freiria R, Remón L. Toric 人工晶状体在合并高度角膜散光白内障中的应用. 国际眼科杂志 2018; 18(2): 213-218

Abstract

• **AIM:** To evaluate the efficacy of Bi-Flex toric intraocular lens (T-IOL) (Medicontur, Medical Engineering, Ltd.,

Inc.) implantation to correct preexisting astigmatism in patients having cataract surgery.

• **METHODS:** This retrospective consecutive study included 22 eyes of 16 patients with more than 2.50 diopters (D) of corneal preexisting astigmatism having cataract. Preoperative and postoperative uncorrected visual acuity (UCVA), best corrected visual acuity (BCVA), objective and subjective refraction and keratometric and topographic cylinder were measured. Postoperative the toric IOL axis was evaluated using vector analysis.

• **RESULTS:** Postoperatively, subjective refractive cylinder was reduced significant ($P < 0.05$) from $4.05 \pm 1.53\text{D}$ to $1.35 \pm 0.86\text{D}$. The component J_0 reduced in magnitude from $-0.81 \pm 2.02\text{D}$ to $-0.12 \pm 0.62\text{D}$ ($P < 0.05$). Both, UCVA and BCVA improved significantly at 1mo after surgery ($P < 0.05$ in both cases). After the surgery, the UCVA and BCVA were 0.24 ± 0.19 and 0.06 ± 0.08 , respectively. The mean toric IOL axis rotation was 2.95 ± 5.25 degree, with rotation less than 10 degrees in 86.36% of eyes. No differences in mean keratometric values obtained before and after surgery were found ($P > 0.05$ for J_0 and J_{45}).

• **CONCLUSION:** Implantation of the Bi-Flex toric IOL is a safe and effective method to correct the preexisting regular astigmatism (greater than 2.50D).

• **KEYWORDS:** toric intraocular lens; astigmatism; rotation stability; vector analysis

DOI:10.3980/j.issn.1672-5123.2018.2.03

Citation: Simo I, Freiria R, Remón L. Toric intraocular lens for correction of high corneal astigmatism in cataract patients. *Guoji Yanke Zazhi (Int Eye Sci)* 2018; 18(2): 213-218

INTRODUCTION

Nowadays, it is possible to achieve complete spectacle independence after cataract surgery due to the improvements in surgical techniques (control of the corneal incisions), accuracy of preoperative measurements, and intraocular lens technology. Although monofocal intraocular lenses are still frequently employed for treating cataracts, multifocal intraocular lenses (MIOLs)^[1] and toric intraocular lens (T-IOLs)^[2-4] are an increasingly used modality.

Astigmatism is a refractive error that considerably affects to the visual function and it is associated with impaired quality of life^[5-6]. It has been reported that 28% of all cataract patients have clinically significant astigmatism, usually higher than

1.00D^[7-8]. Prior to the development of T-IOLs, peripheral corneal arcuate incisions, limbal relaxing incisions (LRIs)^[9], opposite clear corneal incision^[10], astigmatic keratotomy (AK), and excimer laser refractive procedures had performed to correct astigmatism during or after cataract surgery. LRIs and opposite clear corneal incision works well in patients with pre-existing astigmatism of less than 1.00D. However, these techniques present some limitations: unpredictable healing of the corneal incision with inconsistent results, difficulty on placing the incision at certain axes and uncontrolled corneal high-order aberrations^[11-12]. The implantation of T-IOLs has been proven to be effective, predictable, and safe method to treat refractive correction in a single surgical procedure^[2-4,11-12]. However, the success of a T-IOL for achieving the desired astigmatic correction depends on some factors: 1) it is important to take into account the vector sum of the preexisting corneal astigmatism and the surgically induced astigmatism (SIA) when determining the power and meridian of a T-IOL^[13]; 2) the impact of the effective lens position and the sphero-equivalent power of the IOL on the effective toricity (defined as the variation of the apical curvature of the IOL meridians) of the IOL at the corneal plane^[14]; 3) the correct intraoperative alignment of the IOL and the good postoperative rotational stability^[15-16]. Rotation is the principal complication of the T-IOL and it causes residual astigmatism that affects the optical performance. Astigmatism is a vectorial variable with an associate magnitude and axis. For this reason, to evaluate the efficacy of T-IOL implantation, astigmatic change should be calculated by vector analysis^[17]. The method also allows to compare the results of astigmatism surgery in individuals and groups of individuals and to evaluate the surgical results.

The purpose of this study was to evaluate the astigmatic changes using vector analysis as well as postoperative refractive and visual outcomes after implantation of the Bi-Flex aspheric toric IOL (Medicontur, Medical Engineering, Ltd., Inc. Geneva, Switzerland) in a series of cataract surgery patients with corneal astigmatism greater than 2.50D.

SUBJECTS AND METHODS

Study Design A retrospective consecutive study was conducted on 16 patients underwent T-IOL implantation.

Subjects The study was done on 22 eyes from 16 patients underwent T-IOL Bi-Flex implantation at Marina Salud Hospital, Denia, Spain, between September 2013 and June 2014. The study followed the tenets of Declaration of Helsinki and it was approved by the local ethics committee. All patients were informed and signed a consent form.

Patients with preoperative regular corneal astigmatism greater than 2.50D were included in this study. Exclusion criteria were irregular astigmatism, corneal disease [dystrophies, degenerations (keratoconus), infections, etc.], history of glaucoma or retinal detachment, previous corneal or intraocular surgery, macular degeneration, and history of ocular inflammation.

Preoperative Examination Preoperatively, all patients had a complete ophthalmic examination including monocular uncorrected (UCVA) and best corrected distance visual acuity (BCVA, Snellen Charts) were recorded. An objective refraction with auto kerato-refractometer (Alcon, TOPCON KR-8100P, Oakland, New Jersey), a subjective refraction, slitlamp evaluation, applanation tonometry, and ophthalmoscopy. A corneal topography was performed with TOPCON KR-8100P to ensure the regularity of the corneal astigmatism. Axial length and keratometric were measured with the Zeiss Humphrey IOL Master (Berlin, Germany). Intraocular lens cylinder and axis placement were calculated using the software provided by the manufacturer (Medicontur). This calculation program requires preoperative keratometric and biometry data, incision location, the surgeon's estimated surgically induced corneal astigmatism (SIA), and the IOL type to be implanted. The spherical power of the lens was calculated using the SRK/T formula to achieve emmetropia.

Intraocular Lens The Bi-Flex T is a monofocal toric aspheric IOL with an optic zone diameter of 6.00 mm and on overall length of 13.00 mm. The optic design provides aberration-free aspheric IOL and it has a sharp 360 degree edge to prevent posterior capsule opacification. The optical material of the IOL is foldable hydrophilic acrylic with hydrophobic surface and 25% water content with UV filter. The refractive index of the material at 23°C is 1.46. It has double-loop haptics without angulation. The toric component, located on the posterior surface of the optic, has two marks indicating the localization of the flat meridian optic. The toric lens is available in cylinder powers of +1.00D and +1.50D to +9.00D (+0.75D steps) at the IOL plane. All models are available in spherical powers of -10.00D to +35.00D [-10.00D to -1.00D (1.00D steps); 0 to +30.00D (0.50D steps); +31.00D to +35.00D (1.00D steps)].

Surgical Technique One experienced surgeon (Freiria R) performed all surgeries with a standard phacoemulsification and topical anesthesia. Just before surgery, a sterile ink pen was used to make two marks on the corneal limbus at 0-degree and 180-degree positions, with the patient sitting upright at the slit lamp, to avoid ocular torsion. Intraoperatively, a pendulum marker (Tormak) was used to mark the steep corneal meridian with the aid of preload reference points. A 5 mm continuous curvilinear capsulorhexis was created in all cases. The T-IOLs were folded and implanted in the capsular bag with an injector through a 2.2 mm incision placed at 135°.

During surgery, the T-IOL was rotated to align the cylinder axis with the marked steep corneal meridian. After T-IOL implantation, all the ophthalmic viscosurgical devices (OVD) material was removed from the anterior chamber. The appropriate IOL position was rechecked at the end of surgery.

Postoperative Examination Postoperative examinations were performed at 1d, 2wk and 1mo. At 1d, the intraocular

Table 1 Preoperative demographics and preoperative data

Parameters	Values
Age (y)	73.13±9.31(50–81)
Sex (n)	
F	12
M	10
Operated eye (n)	
Right	10
Left	8
Both	2
Axial length (mm)	23.28±0.98(20.87–24.75)
Anterior chamber depth (mm)	3.19±0.33(2.68–3.69)
White-to-white distance (mm)	11.83±0.43(11.30–12.40)
Preoperative refractive sphere (D)	-1.09±4.25(-6.00 to +3.00)
Preoperative refractive cylinder (D)	-4.05±1.53(-1.25 to -6.25)
Spherical IOL power (D)	20.60±2.83(+5.00 to +30.00)
Cylindrical IOL power(D)	+5.55±1.82(+3.75 to +9.00)

Table 2 Visual and refractive outcomes over time

Parameters	Preoperatively	1mo postoperatively	P
logMAR UCVA	0.90±0.45	0.24±0.19	<0.05
logMAR BCVA	0.58±0.37	0.06±0.08	<0.05
Objective sphere (D)	1.53±3.52	0.36±0.93	0.35
Objective refractive cylinder (D)	-4.60±2.13	-1.51±1.25	-
Subjective sphere (D)	-1.09±4.25	-0.33±0.67	0.11
Subjective cylinder (D)	-4.05±1.53	-1.35±0.86	-
Topographic astigmatism (D)	-3.44±1.73	-3.40±1.81	-
Keratometric astigmatism (D)	-4.16±1.85	-4.19±2.09	-

UCVA: Uncorrected visual acuity; BCVA: Best corrected visual acuity.

pressure and the integrity of the anterior segment were evaluated. At 2wk, the intraocular lens rotation was measured using the biomicroscope (slitlamp with rotating slit) under adequate dilatation with intracameral mydriasis. At 1mo, UCVA and BCVA distance visual acuity, refraction, keratometric, and intraocular lens axis were recorded. Clock-wise rotation was regarded as a negative rotation and counterclockwise as a positive rotation.

Data Analysis All data were collected in an Excel database. Preoperative and postoperative astigmatic values were converted to vectorial notation using the power vector method described by Thibos^[17]:

$$M = S + \frac{C}{2}$$

$$J_0 = -\frac{C}{2} \cos(2\alpha)$$

$$J_{45} = -\frac{C}{2} \sin(2\alpha)$$

Where α is the axis of cylinder, C is the cylinder power and S is the spherical power.

Statistical analysis was computed with SPSS software (version 19.0, SPSS, Inc.). For each parameter, the mean values and standard deviations were calculated. Differences were considered statistically significant when $P < 0.05$. Data were tested for normality of distribution Kolmogorov – Smirnov.

When parametric analysis was possible, the *t*-Student test for paired data was applied for all parameter comparisons between preoperative and postoperative data. The Wilcoxon rank-sum test was used to compare preoperative and postoperative values, if parametric analysis was not possible. For the statistical analysis of the VA outcomes, the decimal values of VA were converted into logMAR values.

RESULTS

Patient demographics and preoperative data are presented in Table 1. The mean age was 73.13±9.31 (SD) (range 50 to 81 years). The mean preoperative sphere and preoperative cylinder were -1.09D±4.25D (range -6.00 to +3.00D) and -4.05D±1.53D (range -1.25D to -6.25D), respectively. From the 22 eyes, 9 eyes (41.00%) have with-the-rule corneal astigmatism, 10 eyes (45.40%) have against-the-rule corneal astigmatism, and 3 eyes (13.60%) have oblique corneal astigmatism. The distribution of toric IOL was as follows: 6 eyes with a toric IOL with cylindrical power at IOL plane of +3.75D, 5 eyes with +4.50D, 5 eyes with +5.25D, 2 eyes with +6.00D, 1 eye with +6.75D and 3 eyes with +9.00D.

Visual and Refractive Outcomes Table 2 shows the mean preoperative and postoperative UCVA and BCVA. At 1mo postoperatively, the mean logMAR UCVA was 0.24±0.19.

Table 3 Power vector analyzed preoperatively and postoperatively at 1mo after the surgery and P value calculated with t-test

Parameters	Preoperative keratometric cylinder	Postoperative refractive cylinder	P
J ₀ (D)	-0.81±2.02	-0.12±0.62	<0.05
J ₄₅ (D)	-0.09±1.06	-0.03±0.47	0.82

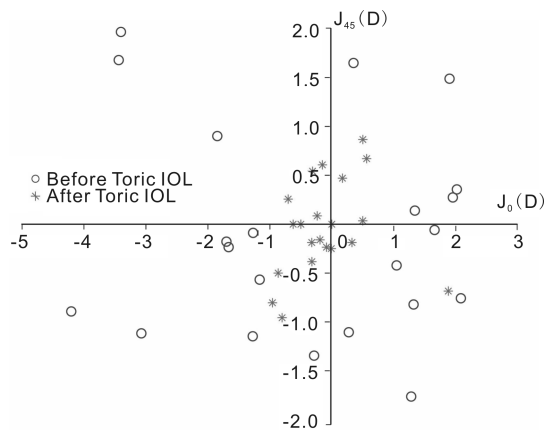


Figure 1 Representation of the astigmatic vector (J₀ and J₄₅) before and at 1mo after toric IOL implantation.

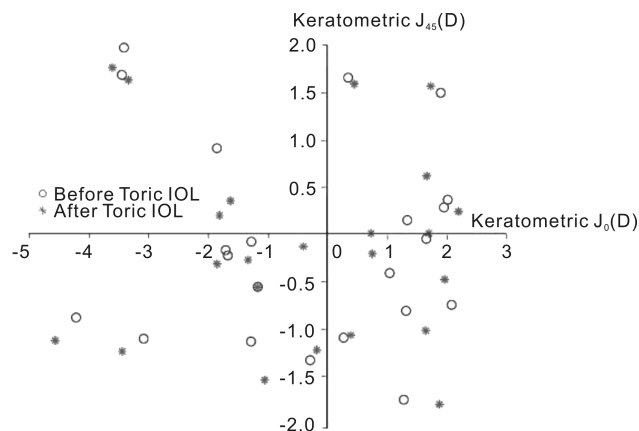


Figure 2 Representation of the keratometric astigmatic vector (J₀ and J₄₅) before and at 1mo after toric IOL implantation.

The BCVA improved to 0.06 ± 0.08 logMAR. The UCVA and BCVA improved significantly at 1mo after surgery ($P < 0.05$ in both cases). At 1mo, the refractive astigmatism was -2.25 D or less in 18 eyes (81.81%), between -2.25 D to -3.00 D in 3 eyes (13.63%) and -4.00 D in 1 eye (4.54%). Sphere did not change significantly after the surgery ($P = 0.11$ for the subjective sphere and $P = 0.35$ for the objective sphere) (Table 2).

Figure 1 shows the distribution of the preoperative keratometric astigmatism and postoperative refraction astigmatism in terms of power vector (components J₀ and J₄₅). It can be seen that there is a reduction in magnitude of astigmatism from preoperatively to at 1mo postoperatively [astigmatism clusters around the origin (0, 0) that represents an eye free of astigmatism]. Specifically, the component J₀ improved significantly at 1mo after surgery ($P < 0.05$). The component J₄₅ did not change significantly with the surgery ($P = 0.82$) because of the majority of the patients have no oblique astigmatism. The values and statistics are summarized in Table 3.

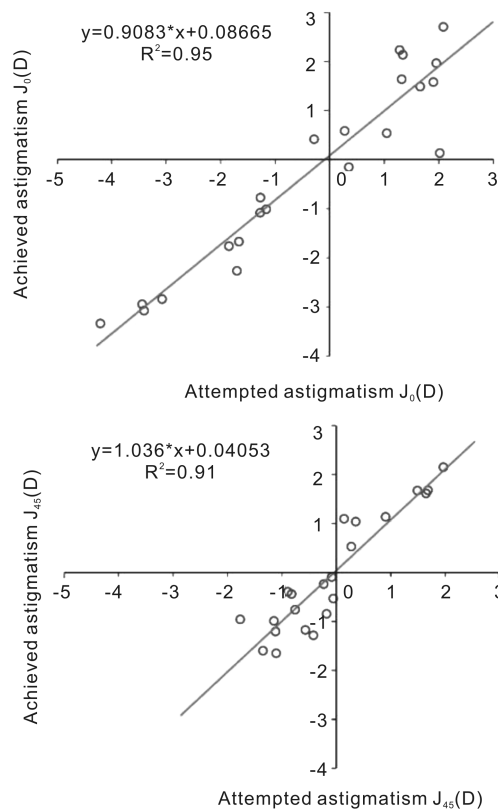


Figure 3 Achieved astigmatism versus attempted for the astigmatism components J₀ (above) and J₄₅ (below). Achieved astigmatism is calculated as the difference between the preoperative and postoperative astigmatism and the attempted astigmatism is the preoperative corneal astigmatism.

Corneal astigmatism was measured by biometry (IOL Master) and topographer (TOPCON KR-8100P) in 3mm diameter (Table 2). Figure 2 shows the distribution of the preoperative and postoperative keratometric astigmatism in terms of power vector (components J₀ and J₄₅). The spread of the points before and after T-IOL were similarly distributed. The mean change in keratometric astigmatism was 0.42 ± 0.50 for J₀ and 0.05 ± 0.14 for J₄₅. There were no statistically significant differences between the mean keratometric changes before and after surgery ($P = 0.52$ for J₀ and $P = 0.49$ for J₄₅).

Rotation Stability The mean rotation of the T-IOL was 4.72 ± 11.23 degrees (range -7 to 50 degrees) at 2wk after the surgery. One eye (4.5%) had a rotation of 50 degrees, two eyes (10%) had IOL rotation of 10 degrees, and the rest of the eye (86.36%) had a rotation less than 10 degrees. If excluded the T-IOL that rotates 50° , the mean rotation of the T-IOL was 2.45 ± 4.92 degrees (range -7 to 10 degrees). At 1mo, the rotation of the T-IOL was 2.95 ± 5.25 degrees. There were not statistically significant differences between the intraocular lens rotation at 2wk and 1mo after the rotation ($P = 0.15$).

Success of the Surgery Figure 3 shows the achieved versus attempted values for both components of the astigmatism; J_0 and J_{45} . The residual astigmatism (achieved) after the surgery is calculated as the difference between the preoperative and postoperative astigmatism. The attempted astigmatism is the preoperative corneal astigmatism. A linear regression between achieved and attempted was obtained, and both the correlation coefficient, R^2 , and the slope, b , were computed. For the component J_0 : $b = 0.90$ and $R^2 = 0.95$ and for J_{45} : $b = 1.036$ and $R^2 = 0.91$. A slope value of 1 would mean that postoperative astigmatism would be equal to 0.

Complications In 1 eye, a secondary procedure was necessary because IOL rotation was 50 degree at the 2wk after the surgery. This rotation was because of the lens haptic was broken. Any other serious intraoperative or postoperative complications occurred over time cause of the study.

DISCUSSION

Several studies have been demonstrated that the implantation of T-IOLs is an effective, safe and predictable method to treat corneal astigmatism in a single surgical procedure^[2-4]. However, patient's outcomes depend on accurate measurements of the corneal astigmatism, accurate marking of corneal meridian and angle alignment, and IOL rotational stability.

In this study, the efficacy of monofocal T-IOL Bi-Flex aspheric implantation to correct regular astigmatism during cataract surgery has been evaluated. The visual, refractive outcomes and astigmatic changes using the vector analysis as well as the rotational stability have been studied. To our knowledge, the present study is the first one in reporting the efficacy and rotational stability of this T-IOL using vector analysis in patients with cataract and corneal astigmatism greater than 2.50D. Previously, the efficacy of this lens has been evaluated without using vector analysis and in patients with preexisting corneal astigmatism between 1.50D and 4.00D^[2]. Recently, the same authors have published results with the same toric IOL model using vector analysis in patients with low corneal astigmatism (between 1.50D and 4.00D)^[18].

A significant improvement in UCVA and BCVA was achieved after the surgery (Table 2), which is consistent with other T-IOL models. In our study, 82.73% of patients achieved 20/40 or better UCVA. In a study by Bachernegg *et al*^[2], 100% of eyes achieved 20/40 or better after the identical IOL model. Mendicute *et al*^[3] report that 93% of the eyes achieving 20/40 or better after Acrysof T-IOL. Stewart *et al*^[19] evaluated T-flex toric IOL implantation in 14 eyes. Over 90% of eyes achieved an UDVA of 20/40 or better and the mean UDVA was 0.16 ± 0.16 LogMAR. In the present study, the postoperative examination UCVA and BCVA was performed one month after the surgery. In the study by Bachernegg *et al*^[2] postoperative examinations were performed at 1wk, 1 and 3mo. They found that there is no statically

significant change in the UCVA between the first and third postoperative month. Similar results were found by Alió *et al*^[4]. Krall *et al*^[20] found an improvement between 1wk and 3mo examination. They reported that might be explained by the increased inflammation in the early postoperative period resulting from the trauma of cataract surgery.

There is a reduction of refractive astigmatism after the surgery. Table 3 shows that the components of the astigmatism were reduced close to 0 after the surgery. The difference in magnitude between preoperative and postoperative J_0 was statistically significant ($P < 0.05$). The difference in magnitude between preoperative and postoperative J_{45} was not statistically significant ($P = 0.82$). This fact is shown in Figure 1. The mean preoperative refractive astigmatism was $4.05D \pm 1.53D$ and the postoperatively was $1.35D \pm 0.86D$ with a reduction of 67% after the T-IOL implantation. These results are consistent with results of previous studies. Bachernegg *et al*^[2,18] found that the mean refractive astigmatism decreased from $1.93D \pm 0.90D$ to $0.30D \pm 0.54D$ with the same T-IOL model. Other studies found that there is a reduction in astigmatism of 70% after T-IOL (preoperative corneal astigmatism $2.34 \pm 1.28D$)^[3]. After Rayner toric IOL implantation, the mean residual refractive cylinder has been shown to range from $-0.89D$ to $-0.95D$ ^[19]. The variability in the astigmatism reduction and visual outcomes between T-IOLs depends on the preoperative astigmatism values and the differences between IOL models. In the present study, mean preoperative refractive astigmatism was $-4.05D \pm 1.53D$ but in the study of Bachernegg *et al*^[2] the mean refractive astigmatism was $1.93 \pm 0.90D$.

In this study, the T-IOLs were folded and implanted in the capsular bag with an injector through a 2.2 mm incision placed at 135° . The location and size of the incision are important factor to take into account on the T-IOL implantation because IOL cylinder is based in keratometric values. In this work, all corneal incisions were performed in the same meridian and a small incision was performed. It is well known that small incisions induce less corneal astigmatism than larger ones. Figure 2 shows the keratometric changes before and after of the surgery. Keratometric astigmatism was distributed randomly before and after T-IOL implantation with no significant differences ($P > 0.05$).

Rotation is a major issue of T-IOLs and rotational stability is a crucial factor for good refractive results. Rotation occurs most frequently in the early postoperative period, before anterior and posterior capsule fuse together^[21]. There are several factors that can be caused rotation including incomplete viscoelastic clearance, early postoperative IOL fluctuations, capsulorhexis size and optic and haptic design and material of the IOL^[22]. There are several methods to determine the rotation of a T-IOL. The method used by Bayramlar *et al*^[23] employs the biomicroscope (slitlamp with rotating slit) under adequate dilatation with intracameral mydriasis. The mean rotation at 2wk was 2.45 ± 4.92 degrees and at 1mo after the

surgery was 2.95 ± 5.25 degrees. There were not statistically significant differences between the intraocular lens rotation at 2wk and 1mo after the rotation ($P = 0.15$). At 2wk, the rotation was 10 degrees or less in 19 eyes (86.36%), 10 degrees in 2 eyes (10%) and 50 degrees in 1 eye (4.5%). These results are in agreement with other studies. Bachernegg *et al*^[2], found a mean of IOL rotation of 2.12 ± 3.45 degrees (range -2 to $+5.00$ degrees) in 30 eyes with the IOL model used in our study. In the recent study published by Bachernegg *et al*^[18] they found an IOL rotation of 0.2 ± 2.41 degrees (range: -5 to $+4$ degrees) 1y after implantation. Hirschall *et al*^[24] found a IOL rotation less than 3 degrees and less than 6 degrees in 62% and 95% of all cases, respectively with the Tecnis Toric (AMO). Mendicute *et al*^[3] found a mean of IOL rotation of 3.53 ± 1.97 degrees (range 0 to 12 degrees) in 20 eyes with the Acrysof SN60T IOL (Alcon Laboratories). Alberdi *et al*^[25] found a mean of IOL rotation of 3.11 ± 3.57 degrees with the T-flex 573&623T. On the contrary, Hoffmann *et al*^[26] found postoperative rotation of 0.23 ± 0.19 degrees in 40 eyes with higher power toric IOLs and Chua *et al*^[27] found a mean of IOL rotation of 9.41 ± 7.80 degrees in 26 eyes with the AA4203-TF/TL.

In conclusion, the results of our study show that implantation of the Bi-Flex IOL is an effective, predictable and safe method to correct corneal astigmatism during routine cataract surgery. Figure 3 shows that both components of astigmatism (J_0 and J_{45}) were reduced and that the slope values are closer to 1 which means that the surgery with T-IOL implantation has been successful.

REFERENCES

- 1 Cetinkaya S, Dadaci Z, Oncel Acir N, Cetinkaya YF, Yener HI, Ozcimen M. Visual outcomes of multifocal intraocular lens implantation in patients with cataract and high hyperopia and patient selection. *Int J Ophthalmol* 2015;8(6):1258-1260
- 2 Bachernegg A, Rückl T, Riha W, Grabner G, Dextl AK. Rotational stability and visual outcome after implantation of a new intraocular lens for the correction of corneal astigmatism during cataract surgery. *J Cataract Refract Surg* 2013;39(9):1390-1398
- 3 Mendicute J, Irigoyen C, Aramberri J, Ondarra A, Montés-Mico R. Foldable toric intraocular lens for astigmatism correction in cataract patients. *J Cataract Refract Surg* 2008;34(4):601-607
- 4 Alió JL, Piñero DP, Tomás J, Aleson A. Vector analysis of astigmatic changes after cataract surgery with toric intraocular lens implantation. *J Cataract Refract Surg* 2011;37(6):1038-1049
- 5 Remón L, Monsorru JA, Furlan WD. Influence of different types of astigmatism on visual acuity. *J Optom* 2017;10(3):141-148
- 6 Read SA, Vicent SJ, Collins MJ. The visual and functional impacts of astigmatism and its clinical management. *Ophthalmic Physiol Opt* 2014;34(3):267-294
- 7 Mohammadi M, Naderan M, Pahlevani R, Jahanrad A. Prevalence of corneal astigmatism before cataract surgery. *Int Ophthalmol* 2016;36(6):807-817
- 8 De Bernardo M, Zeppa L, Cennamo M, Iaccarino S, Zeppa L, Rosa N. Prevalence of corneal astigmatism before cataract surgery in Caucasian patients. *Eur J Ophthalmol* 2014;24(4):494-500
- 9 Leon P, Pastore MR, Zanei A, Umari I, Messai M, Negro C, Tognetto

- D. Correction of low corneal astigmatism in cataract surgery. *Int J Ophthalmol* 2015;8(4):719-724
- 10 Yang J, Wang X, Zhang H, Pang Y, Wei RH. Clinical evaluation of surgery-induced astigmatism in cataract surgery using 2.2 mm or 1.8 mm clear corneal micro-incisions. *Int J Ophthalmol* 2017;10(1):68-71
- 11 Rigi M, Al-Mohtaseb Z, Weikert MP. Astigmatism correction in cataract surgery: toric intraocular lenses placement versus peripheral corneal relaxing incisions. *Int Ophthalmol Clin* 2016;56(3):39-47
- 12 Nanavaty MA, Bedi KK, Ali S, Holmes M, Rajak S. Toric intraocular lens versus peripheral corneal relaxing incisions for astigmatism between 0.75 and 2.50 Diopters during cataract surgery. *Am J Ophthalmol* 2017;180:165-177
- 13 Koch DD, Jenkins RB, Weikert MP, Yeu E, Wang L. Correcting astigmatism with toric intraocular lenses; effect of posterior corneal astigmatism. *J Cataract Refract Surg* 2013;39(12):1803-1809
- 14 Savini G, Hoffer KJ, Carbonelli M, Ducoli P, barboni P. Influence of axial length and corneal power on the astigmatic power of toric intraocular lenses. *J Cataract Refract Surg* 2013;39(12):1900-1903
- 15 Thulasi P, Khandelwal SS, Randleman JB. Intraocular lens alignment methods. *Curr Opin Ophthalmol* 2016;27(1):65-75
- 16 Webers VSC, Bauer NJC, Visser N, Berendschot TTJM, van den Biggelaar FJHM, Nuijts RMM. Image-guided system manual marking for toric intraocular lens alignment in cataract surgery. *J Cataract Refract Surg* 2017;43(6):781-788
- 17 Thibos LN, Wheeler W, Horner D. Power vectors: an application of Fourier analysis to the description and statistical analysis of refractive error. *Optom Vis Sci* 1997;74(6):367-375
- 18 Bachernegg A, Rückl T, Strohmaier C, Jell G, Grabner G, Dextl AK. Vector analysis, rotational stability, and visual outcome after implantation of a new aspheric toric IOL. *J Refract Surg* 2015;31(8):513-520
- 19 Stewart CM, McAlister JC. Comparison of grafted and non-grafted patients with corneal astigmatism undergoing cataract extraction with a toric intraocular lens implant. *Clin Experiment Ophthalmol* 2010;38(8):747-757
- 20 Krall EM, Arlt EM, Hohensinn M, Moussa S, Jell G, Alió JL, Plaza-Puche AB, Bascaran L, Mendicute J, Grabner G, Dextl AK. Vector analysis of astigmatism correction after toric intraocular lens implantation. *J Cataract Refract Surg* 2015;41(4):790-799
- 21 Wang GQ, Dang YL, Huang Q, Woo VC, So KF, Lai JS, Cheng GP, Chiu K. In vitro evaluation of the effects of intraocular lens material on lens epithelial cell proliferation, migration, and transformation. *Curr Eye Res* 2017;42(1):72-78
- 22 Hirschall N, Hoffmann PC, Draschl P, Maedel S, Findl O. Evaluation of factors influencing the remaining astigmatism after toric intraocular lens implantation. *J Refract Surg* 2014;30(6):394-400
- 23 Bayramlar H, Dag Y, Karadag R, Cakici O. An easy and practical method for toric intraocular lens implantation; marking corneal astigmatic axis at slit-lamp. *Int Ophthalmol* 2017;37(1):179-184
- 24 Hirschall N, Maedel S, Weber M, Findl O. Rotational stability of a single-piece toric acrylic intraocular lens; a pilot study. *Am J Ophthalmol* 2014;157(2):405-411
- 25 Alberdi T, Macías-Murelaga B, Bascaran L, Goñi N, de Arregui SS, Mendicute J. Rotational stability and visual quality in eyes with Rayner toric intraocular lens implantation. *J Refract Surg* 2012;28(10):696-701
- 26 Hoffmann PC, Auel S, Hütz WW. Results of higher power toric intraocular lens implantation. *J Refract Surg* 2011;37(8):1411-1418
- 27 Chua WH, Yuen LH, Chua J, Teh G, Hill WE. Matched comparison of rotational stability of 1-piece acrylic and plate-haptic silicone toric intraocular lenses in Asian eyes. *J Refract Surg* 2012;38(4):620-624