

# Intravitreal tissue plasminogen activator for treatment of vitreomacular adhesion

Saeed Karimi<sup>1</sup>, Masoud Soheilian<sup>2</sup>, Hodayoun Nikkhah<sup>1</sup>, Azadeh Haseli Mofrad<sup>3</sup>

<sup>1</sup> Ophthalmic Research Center, Torfeh Eye Hospital, Shahid Beheshti University of Medical Sciences, Tehran 1149847514, Iran

<sup>2</sup> Ophthalmic Research Center, Labbafinejad Eye Hospital, Shahid Beheshti University of Medical Sciences, Tehran 1149847514, Iran

<sup>3</sup> Torfeh Clinical Research Development Unit, Shahid Beheshti University of Medical Sciences, Tehran 1149847514, Iran

**Correspondence to:** Masoud Soheilian. Labbafinejad Eye Hospital, Pasdaran Ave. Boostan 9<sup>th</sup>, Tehran 1149847514, Iran. [masoud\\_soheilian@yahoo.com](mailto:masoud_soheilian@yahoo.com)

Received: 2017-04-08 Accepted: 2017-12-13

## 玻璃体腔组织纤溶酶原激活剂治疗玻璃体黄斑粘连

Saeed Karimi<sup>1</sup>, Masoud Soheilian<sup>2</sup>, Hodayoun Nikkhah<sup>1</sup>, Azadeh Haseli Mofrad<sup>3</sup>

(作者单位:<sup>1</sup>1149847514 伊朗,德黑兰,Shahid Beheshti 医科大学,Torfeh 眼科医院,眼科研究中心;<sup>2</sup>1149847514 伊朗,德黑兰,Shahid Beheshti 医科大学,Labbafinejad 眼科医院,眼科研究中心;<sup>3</sup>1149847514 伊朗,德黑兰,Shahid Beheshti 医科大学,Torfeh 临床研究发展部)

通讯作者:Masoud Soheilian. [masoud\\_soheilian@yahoo.com](mailto:masoud_soheilian@yahoo.com)

### 摘要

**目的:**评估仅玻璃体腔注射组织纤溶酶原激活剂(TPA)对玻璃体黄斑牵引以及玻璃体腔注射TPA和贝伐单抗对视网膜血管疾病的改善作用。

**方法:**前瞻性研究。对24例24眼患者进行干预性系统研究。其中5眼玻璃体黄斑牵引综合征(VMT),19眼视网膜血管疾病包括:糖尿病黄斑水肿(DME)眼,糖尿病性玻璃体出血(VH)眼,视网膜中央静脉阻塞(CRVO)和新生血管年龄相关性黄斑变性眼(AMD)。在注射前及注射1mo后分别进行视力,B超和OCT检查。3眼VMT接受玻璃体腔单次注射TPA50 μg,2眼接受100 μg注射。19例视网膜血管疾病患者接受玻璃体腔组织纤溶酶原激活剂(50 μg)和贝伐单抗(1.25 mg)联合治疗。

**结果:**纳入病例中男性10眼视网膜血管疾病和VMT患者平均年龄分别为56.8y和60.4y。纳入病例中男性10眼(41.7%),女性14眼(58.3%)。22眼(91.7%)晶状体眼,2眼(8.3%)人工晶状体眼。VMT和视网膜血管疾病的玻璃体后部脱离(PVD)分别为0(0/5)和57.8%(11/19)( $P=0.04$ )。在改善最佳矫正视力(BCVA)和降低黄斑中心凹厚度(CMT)方面,与无PVD眼相比,有PVD眼改善更多。

**结论:**在VMT患者中,单独玻璃体腔内注射TPA不能成功诱导玻璃体后部完全脱离。玻璃体腔联合注射TPA和

贝伐单抗可引起视网膜血管疾病患者玻璃体后部脱离,提高最佳矫正视力以及降低黄斑中心凹厚度。

**关键词:**贝伐单抗;玻璃体后部脱离;组织纤溶酶原激活剂

**引用:**Karimi S, Soheilian M, Nikkhah H, Haseli Mofrad A. 玻璃体腔组织纤溶酶原激活剂治疗玻璃体黄斑粘连. 国际眼科杂志 2018;18(2):219-225

### Abstract

• **AIM:** To evaluate the role of a single intravitreal injection of tissue plasminogen activator (TPA) alone for treatment of vitreomacular traction and the effect of combined intravitreal TPA and bevacizumab on retinal vascular diseases.

• **METHODS:** In this prospective, interventional case series a total of 24 eyes from 24 patients were studied. There were 5 eyes with symptomatic vitreomacular traction syndrome (VMT) and 19 eyes with retinal vascular diseases including diabetic macular edema (DME), diabetic vitreous hemorrhage (VH), central retinal vein occlusion (CRVO) and neovascular age related macular degeneration (AMD). Measurement of visual acuity, B-scan and OCT were performed at the baseline and 1mo after injections. Three eyes with VMT received a single intravitreal injection of 50 μg and two eyes received 100 μg TPA. And 19 eyes with retinal vascular diseases received combined intravitreal TPA (50 μg) and bevacizumab (1.25 mg).

• **RESULTS:** The mean ages for retinal vascular diseases and VMT patients were 56.8y and 60.4y, respectively. Ten patients (41.7%) were male and 14 patients (58.3%) were female. And 22 eyes (91.7%) were phakic and 2 eyes (8.3%) were pseudophakic. The incidence of posterior vitreous detachment (PVD) was 0 (0 of 5) and 57.8% (11 of 19) for VMT and retinal vascular diseases, respectively ( $P=0.04$ ). Improvement of best corrected visual acuity (BCVA) and decrement of central macular thickness (CMT) were significantly greater in PVD positive eyes compared with PVD negative eyes.

• **CONCLUSION:** Intravitreal injection of TPA was not successful to induce complete PVD in VMT patients. Combined intravitreal injection of TPA and bevacizumab can induce PVD and improve BCVA and decrease central macular thickness in eyes with retinal vascular diseases.

• **KEYWORDS:** bevacizumab; posterior vitreous detachment; tissue plasminogen activator  
DOI:10.3980/j.issn.1672-5123.2018.2.04

**Citation:** Karimi S, Soheilian M, Nikkhah H, Haseli Mofrad A. Intravitreal tissue plasminogen activator for treatment of vitreomacular adhesion. *Guoji Yanke Zazhi (Int Eye Sci)* 2018;18(2):219-225

## INTRODUCTION

The posterior vitreous cortex is variably adhered to the retina. Collagen fibrils are firmly attached at the macula and are connected to its internal limiting membrane by means of biochemical glue composed of laminin and fibrinectin<sup>[1-4]</sup>. With aging, the gel-like vitreous progressively liquefies and vitreoretinal adhesions weaken, leading to posterior vitreous detachment<sup>[5-7]</sup>.

Vitreomacular adhesion (VMA) occurs when there is incomplete separation of posterior vitreous at the macula. The adhesion may cause vitreomacular traction (VMT) syndrome and becomes symptomatic when anteroposterior or tangential forces increase.

Enzymatic vitreolysis is a potential nonsurgical, biologic method for treating vitreomacular interface disorder. Microplasmin (ocriplasmin), a recombinant protein that contains only the catalytic domain of human plasmin, has shown the ability to induce vitreolysis in patients with vitreomacular adhesion<sup>[8]</sup>, but this drug is expensive and is not available in Iran. Eight categories of adverse events were also identified for this drug. Acute reduction in visual acuity secondary to either worsening of macular pathology or development of subretinal fluid, electroretinogram changes, dyschromatopsia, retinal tears and detachments, lens subluxation or phacodonesis, impaired pupillary reflex and retinal vessels alterations were reported in both premarketing and postmarketing experiences<sup>[9]</sup>.

Recombinant tissue plasminogen activator (RTPA), a sterile and noninfectious agent, can induce posterior vitreous detachment (PVD) and is widely available for clinical use<sup>[10-12]</sup>. Hikichi *et al*<sup>[13]</sup> were the first who used intravitreal TPA to induce PVD.

It has been suggested that vitreomacular adhesion may play a role in the progression of diabetic retinopathy, central retinal vein occlusion (CRVO), and age related macular degeneration<sup>[14-17]</sup>. Some studies suggested that PVD induction might be beneficial in treating macular edema of diabetic retinopathy and central retinal vein occlusion<sup>[13, 18-19]</sup>. However, intravitreal injection of anti-VEGF agents such as bevacizumab (Avastin) has been widely investigated for treatment of diabetic macular edema<sup>[20-23]</sup>.

Based on these findings, we speculated that PVD induction by intravitreal TPA injection might be a possible way to resolve vitreomacular traction and combined intravitreal TPA and bevacizumab may be effective in treating macular edema secondary to diabetic retinopathy, central retinal vein occlusion and wet type age-related macular degeneration (AMD).

The purpose of this pilot study was to evaluate the role of a single intravitreal injection of 50 or 100 µg TPA in VMT

treatment and to assess the effect of combined intravitreal TPA and bevacizumab on retinal vascular diseases including diabetic macular edema, vitreous hemorrhage secondary to proliferative diabetic retinopathy, CRVO related macular edema and wet type AMD.

## SUBJECTS AND METHODS

In this prospective, interventional case series a total of 24 eyes from 24 patients were studied. The study was approved by the Institutional Review Board and Ethics Committee of Shahid Beheshti University of Medical Sciences and followed the tenetsof the Declaration of Helsinki.

There were 5 eyes with symptomatic vitreomacular traction syndrome (VMT) and 19 eyes with retinal vascular diseases including 12 eyes with clinically significant diabetic macular edema based on early treatment diabetic retinopathy study criteria<sup>[24]</sup> without proliferative diabetic retinopathy, five eyes with dense vitreous hemorrhage secondary to proliferative diabetic retinopathy, one eye with macular edema due to fresh (1wk) central retinal vein occlusion CRVO and one eye with choroidal neovascularization, intra and sub retinal fluid and sub retinal hemorrhage secondary to age-related macular degeneration.

Patients with VMT were eligible for the study if they were at least 18 years of age and had vitreomacular adhesion, defined as vitreous adhesion to the macula within a 6-mm central retinal field surrounded by elevation of the posterior vitreous cortex and distortion of foveal anatomy as seen on optical coherence tomography (Spectralis OCT, Heidelberg Engineering). There was no previous history of treatment in VMT patients. Patients with retinal vascular disease were eligible for the study if they were at least 18y of age and had the indication for intravitreal injection of bevacizumab and there was no PVD in ophthalmoscopy, OCT or B-scan and no history of prior retinal laser photocoagulation. Patients were excluded if there was PVD, (assessed by B-scan ocular ultrasonography, OCT of the macular area and optic disk, and slit-lamp biomicroscopy examination), aphakia, high myopia (more than -8 diopters), uncontrolled glaucoma, lenticular or zonular instability, history of retinal detachment in either eye or prior vitrectomy. Positive history of any types of intraocular surgeries or intravitreal injection or laser photocoagulation of the macula or peripheral retina in the previous 3mo was other exclusion criteria.

A complete ophthalmic examination was performed for all patients including measurement of best corrected visual acuity and intraocular pressure, manifest refraction, slit-lamp examination, ophthalmoscopy with pupillary dilation, B-scan ultrasonography to evaluate the status of the posterior vitreous cortex, OCT (except in patients with vitreous hemorrhage) to document the status of vitreomacular adhesion.

An optometrist was responsible for visual acuity testing. Best corrected visual acuity was measured using Snellen E chart and converted to the logMAR.

OCT measurements were obtained with the use of SD-OCT; the same protocol was repeated at follow-up visits.

B-scan ocular sonography was performed by a trained optometrist using the Nidek B-scan ultrasonography apparatus (Echoscan, US-400; Nidek Co Ltd, Gamagori, Japan) over the closed eyelids. B-scans were repeated using lower gain if necessary.

All examinations were performed at the baseline and 1 mo after injections. The patients were also examined at the day 1 and 7, mainly for detection of possible adverse effects.

Three eyes with VMT received a single intravitreal injection of 50 µg/0.05 mL TPA (Actilyse; BoehringerIngelheim, Ingelheim, Germany). Two eyes with VMT received a single intravitreal injection of 100 µg/0.1 mL TPA.

Combined intravitreal injections of 50 µg/0.05 mL TPA and 1.25 mg/0.05 mL bevacizumab (Hoffmann-La Roche, Ltd, Basel, Switzerland by Genentech, Inc, San Francisco, CA) were performed in 12 eyes with CSME, 5 eyes with diabetic vitreous hemorrhage, one eye with fresh CRVO and one eye with CNV.

Injections were performed in a sterile manner using topical anesthesia and insertion of a lid speculum with a 30-gauge needle through the superotemporal quadrant. Combined injections were performed through two separate superotemporal and superonasal sites.

The primary outcome measure was the incidence of complete PVD. Secondary outcome measures included change in best corrected logMAR visual acuity, change in central macular thickness and resolution of vitreomacular traction. Adverse effects like increase in intraocular pressure, cataract progression, intraocular inflammation, retinal breaks and detachment and any other side effects were considered.

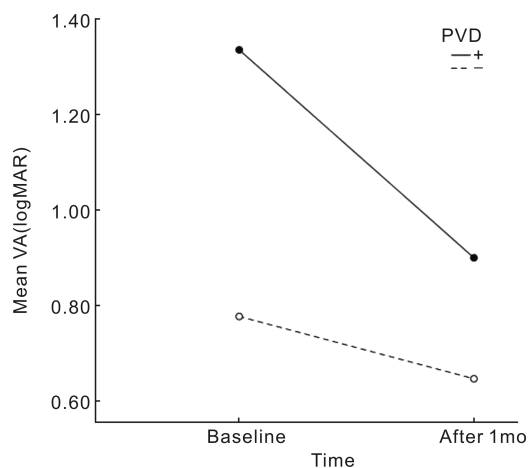
Statistical analysis was performed using SPSS software (Statistical Package for Social Sciences Version 21.0; Armonk, NY; IBM Corp.). Qualitative variables were expressed as percentages, and quantitative data were expressed as mean values with standard deviation and/or confidence interval. To evaluate changes from base line we used Wilcoxon. Then we shaped case series format table.  $P < 0.05$  considered statistically significant.

## RESULTS

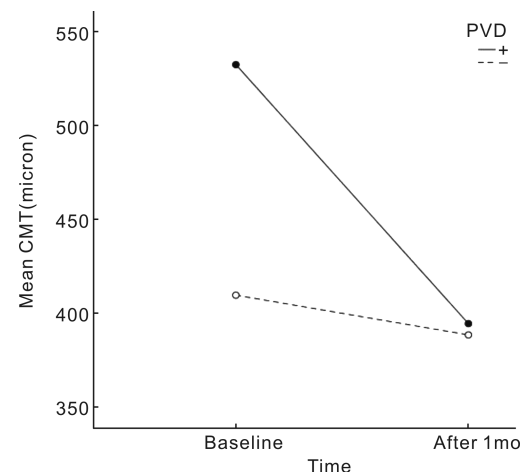
Between May 2014 and January 2015, 24 eyes from 24 patients were enrolled in the study. Five eyes (20.8%) with VMT received intravitreal TPA alone and 19 eyes (79.2%) with retinal vascular diseases including 12 eyes with CSME, 5 eyes with diabetic vitreous hemorrhage (VH), one eye with fresh CRVO and one eye with CNV received combined intravitreal TPA and bevacizumab. Complete data for all patients are presented in Table 1.

Mean ages for retinal vascular diseases and VMT patients were 56.8y and 60.4y, respectively. Ten patients (41.7%) were male and 14 patients (58.3%) were female. And 22 eyes (91.7%) were phakic and 2 eyes (8.3%) were pseudophakic.

The incidence of PVD over the 1mo follow-up period was 57.8% (11 of 19) and 0(0 of 5) for retinal vascular diseases



**Figure 1** The mean visual acuity (VA) changes by PVD status.



**Figure 2** The mean central macular thickness (CMT) changes by PVD status.

and VMT groups, respectively. The incidence of PVD in VMT patients was significantly lower than retinal vascular patients ( $P=0.041$ ). No significant difference was present between the incidence of PVD in phakic and pseudophakic eyes ( $P>0.999$ ) (Table 2).

Nearly all PVDs occurred in the first two weeks after injections. Considering all patients, compared to the baseline, mean visual acuity improved significantly 1mo after injections (mean BCVA improved from 1.03 logMAR to 0.76 logMAR,  $P=0.004$ ). Mean patients CMT before injections was 461 µm and 1mo after injections mean CMT decreased to 390 µm ( $P=0.005$ ). The improvement of BCVA and decrement in CMT were greater in PVD positive eyes compared with PVD negative eyes (Figure1-3).

This difference was statistically significant for CMT changes ( $P=0.007$ ) and was borderline for VA changes ( $P=0.051$ ) (Table 3).

In VMT group no PVD was induced with either 50 or 100 µg TPA. However in these PVD negative patients BCVA improved and CMT decreased at 1mo follow-up. There was no significant difference among 50 and 100 µg TPA groups in terms of BCVA and CMT changes. Complications such as cataract progression, significant inflammation, retinal break or detachment, significant rise of IOP, vitreous hemorrhage and

**Table 1 All patients information including age, sex diagnosis, laterality of the eye, dose of TPA, PVD induction by the procedure and the changes of BCVA and CMT after intravitreal injection of the drugs**

ID	Diagnostic	Age	Sex	Eye	Dose (μg) Of TPA	PVD	BCVA (LogMAR)		CMT (μm)		Lens	Drug
							Base	at 1mo	Base	at 1mo		
1	CRVO	59	Male	OD	50	+	1.00	0.70	595	459	Phakic	IVB+TPA
2	VMT	66	Male	OS	50	-	0.30	0.30	327	287	Phakic	TPA
3	VMT	50	Female	OD	50	-	0.40	0.30	375	345	Phakic	TPA
4	VMT	60	Female	OS	50	-	0.40	0.30	392	275	Phakic	TPA
5	VMT	66	Male	OS	100	-	0.30	0.20	287	278	Phakic	TPA
6	VMT	60	Female	OS	100	-	0.30	0.20	275	278	Phakic	TPA
7	AMD+CNV	63	Male	OD	50	+	1.70	1.50	803	603	Phakic	IVB+TPA
8	PDR+VH	61	Female	OD	50	+	2.60	1.20	un	353	Phakic	IVB+TPA
9	PDR+VH	42	Male	OS	50	+	2.60	1.00	un	485	Phakic	IVB+TPA
10	PDR+VH	53	Male	OS	50	-	1.30	1.10	un	un	Phakic	IVB+TPA
11	PDR+VH	63	Male	OS	50	-	2.10	1.50	un	un	Phakic	IVB+TPA
12	PDR+VH	61	Male	OS	50	+	1.70	1.50	un	un	Phakic	IVB+TPA
13	CSME	45	Female	OD	50	-	1.20	1.20	622	690	Phakic	IVB+TPA
14	CSME	45	Female	OS	50	-	0.60	0.50	310	305	Phakic	IVB+TPA
15	CSME	50	Female	OD	50	+	1.20	1.00	691	595	Phakic	IVB+TPA
16	CSME	68	Female	OS	50	+	1.00	1.00	320	160	Phakic	IVB+TPA
17	CSME	65	Female	OS	50	-	1.00	0.70	713	513	Phakic	IVB+TPA
18	CSME	55	Male	OS	50	+	0.60	0.40	406	292	Phakic	IVB+TPA
19	CSME	67	Male	OS	50	+	0.80	0.30	600	348	Phakic	IVB+TPA
20	CSME	49	Female	OS	50	-	1.10	1.00	355	363	Pseudo Phakic	IVB+TPA
21	CSME	58	Female	OD	50	-	0.40	0.20	306	304	Phakic	IVB+TPA
22	CSME	52	Female	OD	50	+	1.00	1.00	393	373	Pseudo Phakic	IVB+TPA
23	CSME	57	Female	OS	50	+	0.50	0.30	452	325	Phakic	IVB+TPA
24	CSME	67	Female	OS	50	-	1.00	1.10	543	634	Phakic	IVB+TPA
Mean		58					1.03	0.76	461	394		
SD		8					0.7	0.47	164	142		
<i>P</i>								<0.001		<0.001		

*P*-Values based on Wilcoxon signed-rank test; BCVA: Best corrected visual acuity; CMT: Central macular thickness, PVD: Posterior vitreous detachment; CRVO: Central retinal vein occlusion; VMT: Vitreomacular traction; AMD: Age-related macular degeneration; CNV: Choroidal neovascularization; PDR: Proliferative diabetic retinopathy; VH: Vitreous hemorrhage; CSME: Clinically significant macular edema; IVB: Intravitreal bevacizumab; TPA: Tissue plasminogen activator.

**Table 2 Number of PVD and no-PVD patients according to the type of diseases, injected drugs and the lens status**

Variable	Variable subtype	PVD		<i>P</i>
		+	-	
Diagnosis	VMT	0(0.0%)	5(100.0%)	0.041
	Others	11(57.9%)	8(42.1%)	
	CSME	6(50.0%)	6(50.0%)	
	PDR+VH	3(60.0%)	2(40.0%)	
	AMD+CNV	1(100.0%)	0(0.0%)	
	CRVO	1(100.0%)	0(0.0%)	
Drug	IVB+TPA	11(57.9%)	8(42.1%)	<0.001
	TPA	0(0.0%)	5(100.0%)	
Lens	Phakic	10(45.5%)	12(54.5%)	>0.999
	Pseudo Phakic	1(50.0%)	1(50.0%)	

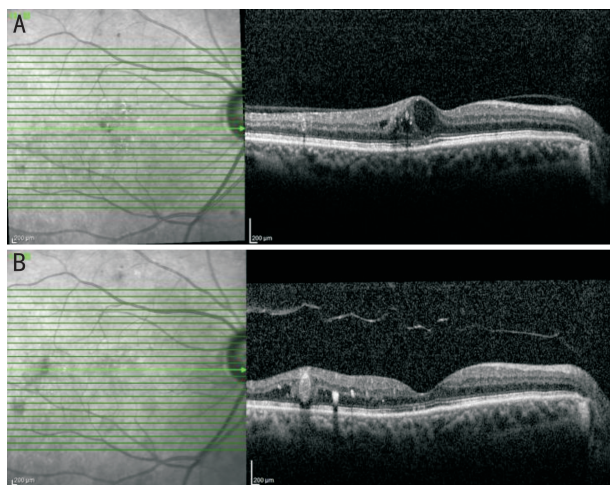
*P*-Values based on Fisher's exact test; PVD: Posterior vitreous detachment; CRVO: Central retinal vein occlusion; VMT: Vitreomacular traction; AMD: Age-related macular degeneration; CNV: Choroidal neovascularization; PDR: Proliferative diabetic retinopathy; VH: Vitreous hemorrhage; CSME: Clinically significant macular edema; IVB: Intravitreal bevacizumab; TPA: Tissue plasminogen activator.



**Table 3 Visual acuity and CMT changes in PVD induced and non-PVD induced eyes**

	Total		PVD				Diff	95% CI		P
	Mean ±SD	(Min, Max)	+		-			lower	Upper	
			Mean±SD	(range)	Mean±SD	(range)				
BCVA Change (logMAR)	-0.2±0.41	(-1.6,0.1)	-0.44±0.54	(-1.6,0)	-0.13±0.18	(-0.6, 0.1)	0.31	-0.03	0.64	0.051
CMT Change (µm)	-70.4±94.7	(-252,91)	-138.1±69.4	(-252,-20)	-21.2±80.2	(-200, 91)	117	42	191	0.007

Based on Mann-Whitney test; BCVA: Best corrected visual acuity; CMT: Central macular thickness; PVD: Posterior vitreous detachment.



**Figure 3 Horizontal OCT scans** A: Vitreomacular adhesion and center-involving diabetic macular edema before injection; B: One month after intravitreal injection of tissue plasminogen activator (TPA) and bevacizumab, posterior vitreous was detached and diabetic macular edema improved.

endophthalmitis were not encountered. At the end of study, each patient received the standard treatment (if needed) such as repeated intravitreal bevacizumab, laser photocoagulation or vitrectomy according to the underlying disease.

**DISCUSSION**

This study showed that intravitreal injection of TPA alone was not able to induce complete PVD in patients with vitreomacular traction syndrome but improved BCVA and decreased central macular thickness in these patients. According to OCT images, it seems that one month after intravitreal injection of TPA, vitreous traction over the macula decreased but did not completely resolved.

Vitreomacular traction can lead to macular distortion and macular hole formation. Symptoms typically include metamorphopsia, blurred vision and central visual - field defects. Angiography may demonstrate leakage of dye from retinal vessels in macular region as well as from the optic nerve<sup>[25]</sup>.

Vitreolysis involving an enzyme that has activity against the molecular substrates responsible for vitreomacular adhesion is a potential biologic treatment for this disorder. Some researches utilized pharmacologic agents such as plasmin, hyaluronidase, chondroitinase, collagenase, and dispaseintravitreally, seeking their effects on vitreomacular interface<sup>[26]</sup>, but most of them were abandoned because of insufficient clinical efficacy, complications, or both<sup>[10,26]</sup>.

Plasmin and a truncated form of plasmin, ocriplasmin, have

been shown to be effective in vitreolysis surveys in animals and humans<sup>[12,27]</sup>. Stalmans and co-workers used ocriplasmin intravitreally in 464 eyes with vitreomacular adhesion (VMA). 188 eyes considered as control group and received placebo. VMA resolved in 26.5% of ocriplasmin-injected eyes and in 10.1% of placebo-injected eyes ( $P < 0.001$ ). Total posterior vitreous detachment was more prevalent in eyes treated with ocriplasmin compared to placebo injected eyes (13.4% vs 3.7%,  $P < 0.001$ ), but ocriplasmin is expensive and is not available in all centers<sup>[27]</sup>.

Recombinant TPA, a sterile and noninfectious agent, is widely available for clinical use<sup>[10]</sup>. Plasmin, which is activated by TPA, has proteolytic activity against fibronectin and laminin, two major components of the vitreoretinal interface and is thought to induce cleavage between the posterior vitreous cortex and the retina<sup>[12]</sup>. TPA has been used for treatment purposes in the anterior and posterior chambers of the eye for more than a decade<sup>[12]</sup>.

The safe dose for intravitreal injection of TPA has been reported to be between 25 and 100 µg in the human eye (28). However, in one study intravitreal injection of a low dose (25 µg) of TPA caused an increase in macular thickness in the temporal side in 5 eyes, as shown by clinical examination<sup>[19]</sup>. The authors speculated that some remnants of vitreoretinal adhesions after the induction of PVD resulted in progression of macular edema in those patients. Therefore, 50 and 100 µg of TPA was selected in this study to ensure efficacy and patient safety.

In the present study, the incidence of complete PVD over the 1mo follow-up period after intravitreal injection of TPA and bevacizumab in eyes with retinal vascular diseases was 57.8%, which was significantly greater than that of the VMT group (0%,  $P = 0.04$ ). This significant difference may be related to low concentration of plasminogen in the vitreous of VMT eyes. The breakdown of blood retinal barrier in eyes with retinal vascular diseases may permit plasminogen to enter the vitreous cavity from blood circulation. Additionally, the presence of blood (vitreous hemorrhage, subretinal and intraretinal hemorrhage) could increase the concentration of plasminogen in vitreous cavity. Consequently, it seems that TPA is more effective in eyes with broken blood retinal barrier. Nonetheless, 2 eyes of VMT group had broad vitreomacular adhesion (more than 1500 µm). Most clinicians believe that enzymatic vitreolysis is more effective in focal vitreomacular adhesion (less than 1500 µm), so we should include patients with focal VMT in future studies. Moreover, the significant difference in the incidence of PVD

between VMT eyes and other patients may be related to few number of VMT eyes. With increasing the number of TPA injected VMT cases, the incidence of PVD may increase. Furthermore, VMT patients received just one intravitreal injection, but others received combined TPA and bevacizumab through two separate sites. Therefore, the higher incidence of PVD induction in combined group (TPA+bevacizumab) may be related to the higher volume of injected drugs and more injection sites.

The vitreous plays a key role in the pathology and natural course of PDR. In diabetic eyes, the presence of a complete posterior vitreous detachment (PVD) has been observed to be associated with lower risk for developing PDR (29, 30). Posterior vitreous detachment (PVD) has been shown to occur in 63% of patients without macular edema and in 31% of those with macular edema<sup>[31]</sup>. Hikichi *et al*<sup>[13]</sup> found that separation of the vitreous from the macula led to spontaneous improvement in macular edema. Abrishami *et al*<sup>[19]</sup> reported that intravitreal injection of TPA induced PVD in 69% of diabetic eyes but BCVA and CMT did not change significantly. Glacet-Bernard *et al*<sup>[28]</sup> showed that PVD was induced in 4 of 15 eyes with central retinal vein occlusion by intravitreal injection of TPA. Murakami *et al*<sup>[17]</sup> reported induction of PVD in 16 of 21 eyes in macular edema with central retinal vein occlusion. In the present study, the incidence of PVD in combined group (TPA+bevacizumab) was 57.8% (11 of 19 eyes), which is consistent with the results of Abrishami study, but in our study combined treatment caused improvement of BCVA and decreased central macular thickness. In the present study, the improvement of VA and CMT were more significant in PVD group, but this difference between PVD and no-PVD groups might be related to baseline differences.

Intravitreal TPA, bevacizumab and SF6 has been used in previous studies in order to treat CNV with extensive submacular hemorrhage<sup>[32]</sup>, however to the best of our knowledge, this study was the first to evaluate the effects of single dose intravitreal TPA injection on PVD induction to treat VMT syndrome and combined intravitreal TPA + bevacizumab to treat diabetic macular edema, diabetic vitreous hemorrhage and macular edema secondary to CRVO and CNV.

This study is limited by the short-term follow-up period, single injection, limited number of participants and lack of control group. Since the case numbers for VMT group is too small and there is no control group for either VMT or retinal vascular disease group, the results of this study cannot be generalized. The BCVA improvement could result from simple IVI bevacizumab in retinal vascular diseases. Another problem is the heterogeneity of etiologies in the retinal vascular disease group. Further studies in the form of randomized clinical trial with more participants, multiple injections and long follow-up time will result in more accurate findings.

In conclusion, intravitreal injection of 50 or 100 µg TPA was

not effective to induce complete PVD in patients with vitreomacular traction syndrome. Intravitreal injection of combined TPA and bevacizumab was effective to induce PVD in eyes with retinal vascular diseases. Intravitreal injection of TPA alone or in combination with Bevacizumab led to improvement of BCVA and decrement of central macular thickness in our patients.

## REFERENCES

- 1 Benz MS, Packo KH, Gonzalez V, Pakola S, Bezner D, Haller JA, Schwartz SD. A placebo-controlled trial of microplasmin intravitreal injection to facilitate posterior vitreous detachment before vitrectomy. *Ophthalmology* 2010;117(4):791-797
- 2 Ponsioen TI, Hooymans JM, Los LI. Remodeling of the human vitreous and vitreoretinal interface—a dynamic process. *Prog Retin Eye Res* 2010;29(6):580-595
- 3 Bishop PN. Structural macromolecules and supramolecular organization of the vitreous gel. *Prog Retin Eye Res* 2000;19(3):323-344
- 4 Le Goff MM, Bishop PN. Adult vitreous structure and postnatal changes. *Eye(Lond)* 2008;22(10):1214-1222
- 5 Foos RY, Wheeler NC. Vitreoretinal juncture: synchysis senilis and posterior vitreous detachment. *Ophthalmology* 1982;89(12):1502-1512
- 6 Sebag J. Age-related differences in the human vitreoretinal interface. *Arch Ophthalmol* 1991;109(7):966-971
- 7 Sebag J. Anomalous posterior vitreous detachment: a unifying concept in vitreoretinal disease. *Graefes Arch Clin Exp Ophthalmol* 2004;42(8):690-698
- 8 Stalmans P, Delaey C, de Smet MD, van Dijkman E, Pakola S. Intravitreal injection of microplasmin for treatment of vitreomacular adhesion; results of a prospective, randomized, sham-controlled phase II trial (the MIVI-IIT trial). *Retina* 2010;30(7):1122-1127
- 9 Kim JE. Safety and complications of ocriplasmin: ocriplasmin, ocriplasmin; oh, how safe art thou? *JAMA Ophthalmol* 2014;132(4):379-380
- 10 Sebag J. Pharmacologic Vitreolysis—Premise and promise of the first decade. *Retina* 2009;29(7):871-874
- 11 Vestraeten TC, Chapman C, Hartzler M, Winkler BS, Trese MT, Williams GA. Pharmacologic induction of posterior vitreous detachment in the rabbit. *Arch Ophthalmol* 1993;111(6):846-854
- 12 De Smet MD, Valmaggia C, Zarranz-Ventura J, Willekens B. Microplasmin: ex vivo characterization of its activity in porcine vitreous. *Invest Ophthalmol Vis Sci* 2009;50(2):814-819
- 13 Hikichi T, Fujio N, Akiba J, Azuma Y, Takahashi M, Yoshida A. Association between the short-term natural history of diabetic macular edema and the vitreomacular relationship in type II diabetes mellitus. *Ophthalmology* 1997;104(3):473-478
- 14 Johnson MW. Posterior vitreous detachment: evolution and complications of its early stages. *Am J Ophthalmol* 2010;149(3):371-382
- 15 Krebs I, Brannath W, Glittenberg C, Zeiler F, Sebag J, Binder S. Posterior Vitreomacular adhesion: a potential risk factor for exudative age-related macular degeneration? *Am J Ophthalmol* 2007;144(5):741-746
- 16 Mojana F, Cheng L, Bartsch DU. The role of abnormal vitreomacular adhesion in age-related macular degeneration: spectral optical coherence tomography and surgical results. *Am J Ophthalmol* 2008;146(2):218-227. e1
- 17 Murakami T, Takagi H, Ohashi H, Kita M, Nishiwaki H, Miyamoto K, Watanabe D, Sakamoto A, Yamaike N, Yoshimura N. Role of posterior vitreous detachment induced by intravitreal tissue plasminogen activator in macular edema with central retinal vein occlusion. *Retina* 2007;27(8):1031-1037

- 18 Hesse L, Nebeling B, Schroeder B, Heler G, Kroll P. Induction of posterior vitreous detachment in rabbits by intravitreal injection of tissue plasminogen activator following cryopexy. *Exp Eye Res* 2000;70(1):31-39
- 19 Abrishami, M, Moosavi MN, Shoeibi N, Hosseinpour SS. Intravitreal tissue plasminogen activator to treat refractory diabetic macular edema by induction of posterior vitreous detachment. *Retina* 2011;31(10):2065-2070
- 20 Faghihi H, Roohipour R, Mohammadi SF, Hojat-Jalali K, Mirshahi A, Lashay A, Piri N, Faghihi SH. Intravitreal bevacizumab versus combined bevacizumab - triamcinolone versus macular laser photocoagulation in diabetic macular edema. *Eur J Ophthalmol* 2008;18(6):941-948
- 21 Lam DS, Lai TY, Lee VY, Chan CK, Liu DT, Mohamed S, Li CL. Efficacy of 1.25 mg versus 2.5 mg intravitreal bevacizumab for diabetic macular edema: six-month results of a randomized controlled trial. *Retina* 2009;29(3):292-299
- 22 Scott IU, Edwards AR, Beck RW, Bressler NM, Chan CK, Elman MJ, Friedman SM, Greven CM, Maturi RK, Pieramici DJ, Shami M, Singerman LJ, Stockdale CR. A phase II randomized clinical trial of intravitreal bevacizumab for diabetic macular edema. *Ophthalmology* 2007;114(10):1860-1867
- 23 Soheilian M, Ramezani A, Obudi A, Bijanzadeh B, Salehipour M, Yaseri M, Ahmadi H, Dehghan MH, Azarmina M, Moradian S, Peyman GA. Randomized trial of intravitreal bevacizumab alone or combined with triamcinolone versus macular photocoagulation in diabetic macular edema. *Ophthalmology* 2009;116(6):1142-1150
- 24 Strauber SF. Photocoagulation for diabetic macular edema. Early treatment diabetic retinopathy study report number 1. Early treatment diabetic retinopathy study research group. *Arch Ophthalmol* 1985;103(12):1796-806
- 25 George M. Bohigian MD. Stereoscopic atlas of macular diseases: diagnosis and treatment. *JAMA* 1997;277(17):1411-1412
- 26 Rheaume MA, Vavvas D. Pharmacologic vitreolysis. *Semin Ophthalmol* 2010;25(5-6):295-302
- 27 Stalmans P, Benz MS, Gandorfer A, Kampik A, Girach A, Pakola S, Haller JA. Enzymatic vitreolysis with ocriplasmin for vitreomacular traction and macular hole. *N Engl J Med* 2012;367(7):606-615
- 28 Glacet-Bernard A, Kuhn D, Vine AK, Oubraham H, Coscas G, Soubrane G. Treatment of recent onset central retinal vein occlusion with intravitreal tissue plasminogen activator: a pilot study. *Br J Ophthalmol* 2000;84(6):609-613
- 29 Takahashi M, Trempe CL, Maguire K, McMeel JW. Vitreoretinal relationship in diabetic retinopathy. A biomicroscopic evaluation. *Arch Ophthalmol* 1981;99(2):241-245
- 30 Ono R, Kakehashi A, Yamagami H, Sugi N, Kinoshita N, Saito T, Tamemoto H, Kuroki M, Lshikawa SE, Kawakami M. Prospective assessment of proliferative diabetic retinopathy with observations of posterior vitreous detachment. *Int Ophthalmol* 2005;26(1-2):15-19
- 31 Gandorfer A. Pharmacologic vitreolysis. *Dev Ophthalmol* 2007;39:149-156
- 32 Mayer WJ, Hakim I, Haritoglou C, Gandorfer A, Ulbig M, Kampik A, Wolf A. Efficacy and safety of recombinant tissue plasminogen activator and gas versus bevacizumab and gas for subretinal hemorrhage. *Acta Ophthalmol* 2013;91(3):274-278