

# Implantable collamer lens for the correction of post-keratoplasty myopia and astigmatism

Nasser A Alsabaani<sup>1</sup>, Abdullah Abubaker<sup>2</sup>, Salem Almalki<sup>3</sup>

<sup>1</sup>Department of Ophthalmology, College of Medicine, King Khalid University, Abha 61421, Saudi Arabia

<sup>2</sup>Department of Ophthalmology, King Khalid Hospital, Najran 55461, Saudi Arabia

<sup>3</sup>King Khalid Eye Specialist Hospital, Riyadh 11462, Saudi Arabia

**Correspondence to:** Nasser A Alsabaani. Department of Ophthalmology, College of Medicine, King Khalid University, PO Box 641, Abha 61421, Saudi Arabia. dr.alsabaani@kku.edu.sa

Received: 2017-04-02 Accepted: 2018-03-07

## 后房型人工晶状体植入用于角膜移植术后近视和散光的矫正

Nasser A Alsabaani<sup>1</sup>, Abdullah Abubaker<sup>2</sup>, Salem Almalki<sup>3</sup>  
(作者单位:<sup>1</sup>61421 沙特阿拉伯,艾卜哈,哈利德国王大学医学院,眼科;<sup>2</sup>55461 沙特阿拉伯,奈季兰,哈利德国王医院,眼科;<sup>3</sup>11462沙特阿拉伯,利雅得,哈利德国王眼科医院)  
通讯作者:Nasser A Alsabaani. dr.alsabaani@kku.edu.sa

### 摘要

**目的:**评估角膜移植术(KP)后植入后房型人工晶状体(ICL)的安全性、屈光效果和视力。

**方法:**单中心回顾性研究。包括32例35眼接受后房型人工晶状体植入以矫正角膜移植术后近视和散光。患者在无法配戴眼镜、隐形眼镜或准分子激光术治疗不当的情况下接受后房型人工晶状体植入术。观察患者裸眼远视力(UDVA)、最佳矫正远视力(CDVA)、屈光度及并发症。对术前术后随访资料进行分析(16.7±13mo)( $P<0.05$ )。

**结果:**术前,患者等效球镜和柱镜分别为-4.00~-20.00 D和-2.00~-9.00 D。平均等效球镜由术前-11.41±3.62 D显著下降至术后-1.95±1.78 D( $P<0.0001$ )。平均UDVA由术前20/400显著增加至术后20/25( $P<0.0001$ )。与术前相比,术后CDVA平均提高1.5行,其中37%提高2行或更多。1眼(2.8%)CDVA降低≥1行。术中或术后无并发症。

**结论:**后房型人工晶状体植入对于无法配戴眼镜、隐形眼镜或准分子激光术治疗不当的患者是一种安全有效的治疗手段。

**关键词:**后房型人工晶状体植入;近视;散光;角膜移植术后

**引用:**Alsabaani NA, Abubaker A, Almalki S. 后房型人工晶状体植入用于角膜移植术后近视和散光的矫正. 国际眼科杂志 2018;18(6):975-978

### Abstract

• **AIM:** To evaluate the safety, refractive outcomes and vision after phakic posterior chamber implantable collamer lens (ICL) after keratoplasty (KP).

• **METHODS:** This retrospective single center study evaluated 32 (35 eyes) patients who received an ICL for myopia and/or astigmatism after keratoplasty. Patients underwent ICL surgery if they were unable to wear glasses or contact lenses and excimer laser surgery was contraindicated. Data were collected on uncorrected distance visual acuity (UDVA), corrected distance visual acuity (CDVA), refraction and complications. Data were analyzed for the preoperative and last postoperative visits (16.7±13mo) ( $P<0.05$ ).

• **RESULTS:** Preoperatively, spherical equivalent (SE) ranged from -4.00 to -20.00 D and cylinder from -2.00 to -9.00 D. The mean SE decreased statistically significantly from -11.41±3.62 D preoperatively to -1.95±1.78 D postoperatively ( $P<0.0001$ ). Mean UDVA increased statistically significantly from 20/400 preoperatively to 20/25 postoperatively ( $P<0.0001$ ). There was a mean improvement in postoperative CDVA of 1.5 lines compared to preoperatively, 37% of eyes had an increase of 2 or more lines. One eye (2.8%) lost ≥1 line of CDVA. There were no intraoperative or postoperative complications.

• **CONCLUSION:** Posterior chamber phakic intraocular lens implantation is a safe and effective treatment for post-keratoplasty myopia and astigmatism in patients who are unable to wear spectacles or contact lenses and where corneal refractive surgery is contraindicated.

• **KEYWORDS:** implantable collamer lens; myopia; astigmatism; post-keratoplasty

DOI:10.3980/j.issn.1672-5123.2018.6.01

**Citation:** Alsabaani NA, Abubaker A, Almalki S. Implantable collamer lens for the correction of post-keratoplasty myopia and astigmatism. *Guoji Yanke Zazhi(Int Eye Sci)* 2018;18(6):975-978

### INTRODUCTION

Postoperative refractive error and anisometropia can limit visual performance after keratoplasty<sup>[1]</sup>. Moderate to high postoperative refractive error have been reported after keratoplasty<sup>[2-3]</sup>. Postoperative refractive error may preclude adequate optical or excimer laser correction due to anisometropia, high astigmatism, dry eye or abnormal corneal topography<sup>[3]</sup>. Hence, alternate secondary surgical procedures are often required for postoperative functional vision.

Various procedures have been used to treat post-keratoplasty refractive error including intraocular lens implantation (IOL), piggyback IOL implantation, limbal relaxing incisions and phakic IOL (pIOL) implantation<sup>[4-6]</sup>.

The implantable collamer lens (ICL) is a posterior chamber phakic IOL that is safe and efficacious for the treatment of moderate to high myopia and astigmatism<sup>[7-8]</sup>. However, there is a relative paucity of publications on the treatment of post-keratoplasty refractive error with ICL surgery<sup>[6,9-10]</sup>. Recent publications are limited to case reports, case series or outcomes of 15 eyes<sup>[11]</sup>. In the current study, we present the safety, visual and refractive outcomes of a relatively large cohort of patients who underwent ICL surgery for correction of post-keratoplasty refractive error.

## SUBJECTS AND METHODS

This study evaluated the eyes of patients with residual refractive error after keratoplasty that underwent implantation of a myopic or toric ICL at the King Khalid Eye Specialist Hospital (KKESH), Riyadh, Saudi Arabia. All surgeries were performed between January 2008 and June 2012. An institutional review board approved this study and this study adhered to the tenets of the Declaration of Helsinki.

Post-keratoplasty patients were included if they were unable to wear spectacles or contact lenses, the excimer laser surgery was contraindicated<sup>[11]</sup>, and eyes had a stable refraction for at least 3mo after suture removal. Exclusion criteria were as follows, anterior chamber depth (ACD) less than 2.8 mm, cataract, a history of glaucoma or ocular inflammation, retinal detachment, neuro-ophthalmic disease, macular degeneration and retinal disease.

Before ICL implantation, all patients underwent a complete ophthalmologic examination, including measurement of uncorrected distance visual acuity (UDVA), corrected distance visual acuity (CDVA), manifest and cycloplegic refractions, keratometry, corneal tomography, pachymetry, slit lamp biomicroscopy, Goldmann applanation tonometry, specular microscopy and a dilated fundus examination. Postoperative examinations were performed at 1d, 2wk and 3, 6mo, 12mo and yearly thereafter.

**Surgical Procedure** All patients received 2 peripheral iridotomies with a neodymium: YAG laser 1wk prior to ICL surgery. To control for potential cyclotorsion in the supine position, the horizontal axis was marked with the patient sitting at the slit lamp just prior to ICL surgery. The patient was taken to the operating room and the eye was prepared in a sterile fashion and draped to isolate the lids and lashes. A topical anesthetic, dilating and cycloplegic drops were instilled in the operative eye. A lid speculum was inserted followed by instillation of an additional drop of anesthetic. A Mendez ring was used for intraoperative measurement of rotation from the horizontal axis. A viscoelastic device was placed into the anterior chamber and an ICL was inserted through a 3-mm clear corneal incision using an injector cartridge. The ICL was rotated with a manipulator to ensure proper placement in the posterior chamber. Subsequently, the

remaining viscoelastic material was completely washed out of the anterior chamber with balanced salt solution and a miotic agent was instilled. All surgeries were uneventful and there were no intraoperative complications. Postoperatively, the patients were prescribed topical steroid and an antibiotic (0.5% levofloxacin, Cravit<sup>TM</sup>, Santen, Osaka, Japan) to be instilled 4 times daily for 2wk. The topical steroid was slowly tapered after 2wk.

**Implantable collamer lens (ICL) size and power calculation** All eyes were targeted for emmetropia. The ICL diameter was based on the horizontal white-to-white (WTW) diameter using a caliper and anterior chamber depth (ACD) measured with the Pentacam tomographer (Oculus GmbH, Wetzlar, Germany). The modified vertex formula was used for calculating the ICL power with software provided by the manufacturer.

**Outcome Measures and Statistics** Data are presented for the preoperative and last postoperative visit. Data were collected on refraction, UDVA, CDVA, and complications. Data analysis was performed using SPSS for Windows version 20.0 (IBM Corp., New York, NY, USA). Visual acuity was converted to logMAR values for statistical analysis and the means and standard deviations were back-calculated to Snellen acuity. The efficacy index was calculated as:

Equation 1 mean postoperative UDVA/mean preoperative CDVA

The safety index was calculated as:

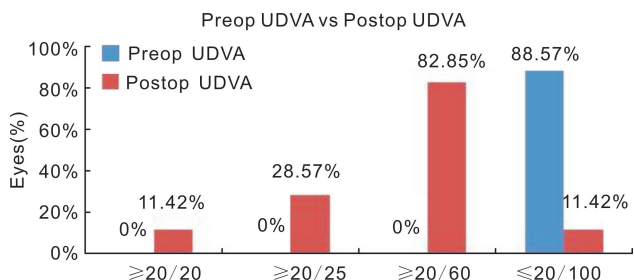
Equation 2 mean postoperative CDVA/mean preoperative CDVA

The paired *t*-test was used evaluating the difference between preoperative and postoperative visits. A *P* value less than 0.05 was considered statistically significant.

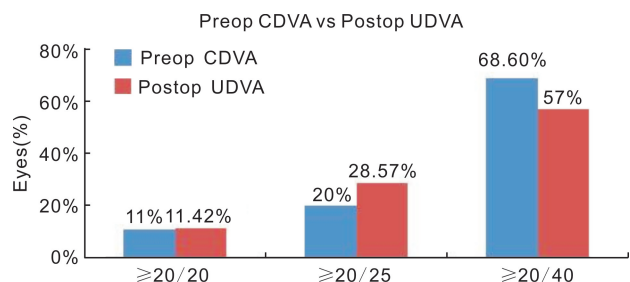
## RESULTS

**Patient Population** The study cohort was comprised of 35 eyes of 32 patients with a mean patient age of 31.12±7.86 (range from: 22 to 49) y. Twenty-five (78%) of the 32 patients were male. Preoperatively, the mean anterior chamber depth was 3.83±0.458 (range from: 3.02 to 5.10) mm. The mean preoperative corneal thickness was 516.63±60.44 (range from: 323 to 605) μm. The mean preoperative endothelial cell count was 1867.52±696 (range from: 507 to 2900) cells/mm<sup>2</sup>. The mean time between keratoplasty and ICL implantation was 4.12±1.63y. The mean follow up was 16.7±4 (range from: 3 to 39) mo. The mean preoperative sphere was -8.60±3.51 (range from: -2.00 to -18.75) D. The mean cylinder decreased statistically significantly from -4.84±2.01 (range from: -2.00 to -9.00) D preoperatively to -3.63±2.01 (range from: 0.00 to -8.00) D postoperatively (*P*=0.023).

The mean spherical equivalent decreased statistically significantly from -11.41±3.62 (range from: -4.00 to -20.00) D preoperatively to -1.95±1.78 (range from: 1.00 to -7.00) D postoperatively (*P*<0.0001). At baseline, no eyes (0) were within ±1.00 D MRSE compared with 28.57% at the last postoperative visit.



**Figure 1 Preoperative (Preop) uncorrected distance visual acuity (UDVA) versus last postoperative (Postop) visit UDVA for 35 eyes that underwent implantable collamer lens surgery for myopia and/or astigmatism.**



**Figure 2 Preoperative (Preop) corrected distance visual acuity (CDVA) versus last postoperative visit uncorrected distance visual acuity (UDVA) for 35 eyes that underwent implantable collamer lens surgery for post-keratoplasty myopia and/or astigmatism.**

There was a statistically significant increase in mean UDVA from 20/400 preoperatively to 20/25 at the last postoperative visit ( $P < 0.0001$ ) (Figure 1).

At the last postoperative visit, mean UDVA improved by 8.5 lines. The UDVA improved to 20/25 or better in 28.57% of patients and 57.14% of eyes were 20/40 or better. The UDVA was 20/100 or worse in 11.42%. No eyes lost UDVA.

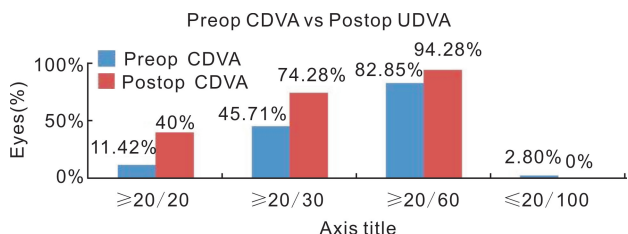
Figure 2 presents the preoperative CDVA versus postoperative UDVA.

Preoperatively 11% of eyes had 20/20 or better acuity CDVA compared to 11.42% of eyes with this level of UDVA postoperatively (Figure 2).

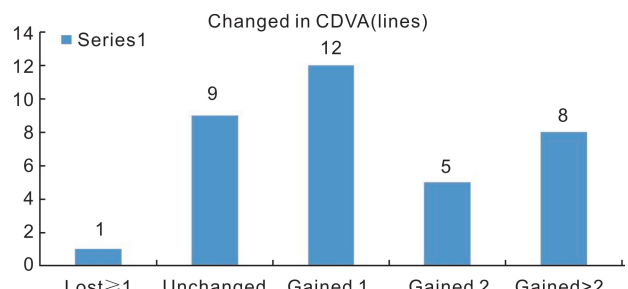
Postoperative UDVA was better than or equal to preoperative CDVA in 51.42% of eyes. The proportion of eyes that presented with preoperative CDVA < 20/20 yet had postoperative UDVA ≥ 20/20 was 5.71%. The efficacy index was 1.18 (According to Equation 1).

The mean improvement in postoperative CDVA was 1.5 lines compared to preoperatively. Postoperative CDVA was higher than or equal to preoperative CDVA in 80% eyes. There was a statistically significant increase of 28.57% in the proportion of eyes with CDVA greater than or equal to 20/20 from preoperatively to postoperatively ( $P < 0.0001$ ). No eyes had vision worse than 20/100 postoperatively (Figure 3).

At the last postoperative visit there was an increase in CDVA of 2 or more lines in 37.14% of eyes and one eye (2.8%) lost 3 lines of CDVA due to posterior subcapsular cataract (Figure 4). The safety index was 0.46 (According to Equation 2).



**Figure 3 Preoperative (Preop) corrected distance visual acuity (CDVA) versus last postoperative (Postop) visit CDVA for 35 eyes that underwent implantable collamer lens surgery for myopia and/or astigmatism.**



**Figure 4 Change in the corrected distance visual acuity for 35 eyes that underwent implantable collamer lens surgery for myopia and/or astigmatism.**

### DISCUSSION

The outcomes of this study of pIOL implantation for post-keratoplasty myopia or astigmatism indicated statistically significant increases in vision and reduced refractive error postoperatively. For example, there was a statistically significant increase in UDVA from 20/400 preoperatively to 20/25 postoperatively ( $P < 0.0001$ ). There was a statistically significant reduction in spherical equivalent of -9.46 D ( $P < 0.0001$ ).

To our knowledge, this is one of the largest series of patients in a publication of the ICL for post-keratoplasty refractive error. Our study evaluated patients who had exhausted all other optical or surgical options for treatment of the post-keratoplasty refractive error. For example, anisometropia, dry eye, irregular topography or inadequate residual stromal bed precluded spectacle wear, contact lens wear and excimer laser refractive surgery. The outcomes of the current study indicate that ICL implantation in this subset of patients results in good refractive outcomes with 37.14% of eyes gaining 2 or more lines of CDVA and minimal loss (2.8% of eyes) of CDVA. The refractive outcomes of this study are consistent with previous studies of pIOL for post-keratoplasty refractive error. The statistical decrease in spherical equivalent of -9.46 D is slightly greater than a study with smaller sample size (15 eyes) that reported a decrease of -8.85 D<sup>[6]</sup>. A study of 7 eyes reported a change in spherical equivalent of -7.76 D after ICL implantation for post-keratoplasty anisometropia<sup>[11]</sup>. The differences in enrollment criteria, range of post-keratoplasty refractive error and sample size between studies may account for the difference in outcomes reported in our study and previous studies.

The visual outcomes in the current study are well within the range reported for previous studies of ICL implantation for post-keratoplasty ametropia. For example, 7 eyes had a mean gain in UDVA of  $7.6 \pm 1.9$  lines  $12.8 \pm 8.8$  mo after ICL implantation for post-keratoplasty ametropia<sup>[11]</sup>. Our outcomes are similar with a mean increase in UDVA of 8.5 lines. UDVA was 20/40 or better in 7 eyes (46.6%) in a study<sup>[6]</sup> of 15 eyes after ICL implantation for post-keratoplasty ametropia which is somewhat lower than our outcome of 57.14%.

Loss of CDVA was minimal in our study with 1 eye (2.8%) losing 1 (or more) lines of CDVA at the last postoperative visit due to the development of posterior subcapsular cataract. This outcome concurs with a similar study that reported no loss of CDVA in 15 eyes<sup>[6]</sup>.

In summary, ICL implantation is efficacious for patients with post-keratoplasty myopia and astigmatism who are not candidates for optical treatments and in whom other surgical options are contraindicated. ICL implantation resulted in minimal loss of CDVA.

Myopia and astigmatism are common after keratoplasty and the patients may not be candidates for optical or excimer laser correction. Hence, alternate intraocular procedure may be required for correcting the post-keratoplasty refractive error.

Inappropriate candidates with post-keratoplasty ametropia, phakic intraocular lens implantation is a reasonable alternative to decrease refractive error and increase vision postoperatively.

#### REFERENCES

1 Langenbucher A, Naumann GO, Seitz B. Spontaneous long-term changes of corneal power and astigmatism after suture removal after

penetrating keratoplasty using a regression model. *Am J Ophthalmol* 2005;140(1):29-34

2 Genvert GI, Cohen EJ, Arentsen JJ, Laibson PR. Fitting gas-permeable contact lenses after penetrating keratoplasty. *Am J Ophthalmol* 1985;99(5):511-514

3 Moshirfar M, Feilmeier MR, Kang PC. Implantation of verisyse phakic intraocular lens to correct myopic refractive error after penetrating keratoplasty in pseudophakic eyes. *Cornea* 2006;25(1):107-111

4 Fenzl RE, Gills JP 3rd, Gills JP. Piggyback intraocular lens implantation. *Curr Opin Ophthalmol* 2000;11(1):73-76

5 Gayton JL, Sanders V, Van der Karr M, Raanan MG. Piggybacking intraocular implants to correct pseudophakic refractive error. *Ophthalmology* 1999;106(1):56-59

6 Alfonso JF, Lisa C, Abdelhamid A, Montés-Micó R, Poo-López A, Ferrer-Blasco T. Posterior chamber phakic intraocular lenses after penetrating keratoplasty. *J Cataract Refract Surg* 2009;35(7):1166-1173

7 Bamashmus MA, Al-Arabi AH, Alawad MA. Visual outcomes and patient satisfaction after implantable collamer lens and toric implantable collamer lens correction for moderate to high myopia and myopic astigmatism. *Saudi Med J* 2013;34(9):913-919

8 Sanders DR, Schneider D, Martin R, Brown D, Dulaney D, Vukich J, Slade S, Schallhorn S. Toric implantable collamer lens for moderate to high myopic astigmatism. *Ophthalmology* 2007;114(1):54-61

9 Akcay L, Kaplan AT, Kandemir B, Gunaydin NT, Dogan OK. Toric intraocular collamer lens for high myopic astigmatism after penetrating keratoplasty. *J Cataract Refract Surg* 2009;35(12):2161-2163

10 Mehta JS, Yuen LH, Mengher LS, Papathanassiou M, Allan BD. Correcting post-keratoplasty anisometropia with the implantable collamerphakic intraocular lens. *Clin Experiment Ophthalmol* 2010;38(8):764-767

11 Iovieno A, Guglielmetti S, Capuano V, Allan BD, Maurino V. Correction of postkeratoplasty ametropia in keratoconus patients using a toric implantable collamer lens. *Eur J Ophthalmol* 2013;23(3):361-367