

Diffusion tensor imaging of visual pathways in patients with acute and chronic optic neuritis

Ahmet Onur Keskin¹, Fethi Idiman², Ozkan Alatas³, Emel Ada³, Egemen Idiman³, Ali Osman Saatci⁴

¹Department of Neurology, Yunus Emre State Hospital, Eskisehir 26190, Turkey

²Department of Neurology, Dokuz Eylul University, Izmir 35040, Turkey

³Department of Radiology, Dokuz Eylul University, Izmir 35040, Turkey

⁴Department of Ophthalmology, Dokuz Eylul University, Izmir 35040, Turkey

Correspondence to: Ahmet Onur Keskin. Department of Neurology, Izmir 35040, Turkey. aonurkeskin@gmail.com

Received: 2017-01-17 Accepted: 2018-05-28

急性和慢性视神经炎患者视觉通路的弥散张量成像分析

Ahmet Onur Keskin¹, Fethi Idiman², Ozkan Alatas³, Emel Ada³, Egemen Idiman³, Ali Osman Saatci⁴

(作者单位:¹26190 土耳其,埃斯基谢希尔, Yunus Emre 州立医院神经疾病科;²35040 土耳其,伊兹密尔, Dokuz Eylul 大学神经疾病科;³35040 土耳其,伊兹密尔, Dokuz Eylul 大学放射科;⁴35040 土耳其,伊兹密尔, Dokuz Eylul 大学眼科)

通讯作者: Ahmet Onur Keskin. aonurkeskin@gmail.com

摘要

目的:急性和慢性视神经炎患者视觉通路的弥散张量成像评估以及视力障碍、视网膜神经纤维层厚度与扩散指数变化的相关性研究。

方法:在 26 例患者和 13 例健康对照组中进行扩散张量成像术。患者中 17 眼患有急性视神经炎, 20 眼患有慢性视神经炎和 15 例未受感染眼。所有受试者中, 采用神经眼科检查、光学相干断层扫描、视觉诱发电位、眶颞 MRI 等方法对视觉传入系统进行评估。

结果:急性和慢性视神经炎患者视神经中各向异性低于对照组 ($P=0.28$)。急性和慢性视神经炎患者视神经平均扩散率高于患者未受感染眼及对照组 ($P<0.01$)。患者与对照组视网膜神经纤维层厚度、P100 振幅、潜伏期及视力差异均有统计学意义 (均 $P<0.01$)。相较于对照组, 患者组中视交叉平均扩散率较高 ($P=0.011$)。各组间视束各向异性和平均扩散率测量差异均有统计学意义 (分别为 $P=0.032$ 和 $P=0.013$)。在相关性分析中, 急性视神经炎 P100 潜伏期与视神经各向异性相关 ($r=-0.439, P=0.021$)。平均扩散率与视网膜神经纤维层厚度、视力和 P100 潜伏期相关 ($r=-0.464, -0.334, -0.389; P<0.05$)。各向异性与平均扩散率和视力有关, 差异均有统计学意义 ($r=-0.393, 0.364; P<0.05$), 而慢性视神经炎的平均扩散系数与 P100 振幅和 RNLf 厚度相关

($r=-0.412, -0.374; P<0.05$)。视力下降与平均扩散率增加和各向异性下降有关 ($P<0.05$)。

结论:弥散张量成像能够显示眼眶 MRI 看似正常的组织中的异常。研究结果表明, 弥散张量成像的测量与视觉缺陷和组织损伤相关。

关键词:弥散张量成像; 视神经炎; 光学相干层析成像; 多发性硬化症

引用: Keskin AO, Idiman F, Alatas O, Ada E, Idiman E, Saatci AO. 急性和慢性视神经炎患者视觉通路的弥散张量成像分析. 国际眼科杂志 2018;18(9):1559-1566

Abstract

• **AIM:** To investigate diffusion tensor imaging (DTI) evaluations of visual pathways in patients with acute and chronic optic neuritis (ON), and investigate the correlations between visual disability, retinal nerve fiber layer thickness (RNFLT) and diffusion index changes.

• **METHODS:** We performed DTI in 26 patients and 13 healthy controls. Patients had acute ON in 17 eyes, chronic ON in 20 eyes and 15 unaffected eyes. In all participants, the visual afferent system was evaluated with neuro-ophthalmological examinations, optical coherence tomography (OCT), visual evoked potential (VEP), orbital and cranial MRI.

• **RESULTS:** Fractional anisotropy (FA) in the optic nerves was lower in patients with acute ON and chronic ON than controls ($P=0.28$). Mean diffusivity (MD) in the optic nerves was higher in patients with acute and chronic ON than the unaffected eyes of patients and controls ($P<0.01$). Retinal nerve fiber layer thickness, P100 amplitude and latency and visual acuity (VA) were significantly different between patient and control groups ($P<0.01$). Optic chiasm MD values were higher in the patient group compared to the control group ($P=0.011$). FA and MD measured in the optic tracts significantly were different between groups ($P=0.032, P=0.013$, respectively). In the correlation analysis, fractional anisotropy in the optic nerves was correlated with P100 latency in acute ON ($P=0.021$). Mean diffusivity was correlated with RNFLT, visual acuity and P100 latency ($P<0.05$). Fractional anisotropy was correlated with mean diffusivity and visual acuity, and, mean diffusivity was correlated with P100 amplitude and RNLF thickness in chronic ON ($P<0.05$). Reduction in visual acuity was correlated with increase in mean diffusivity and decrease in fractional anisotropy ($P<0.05$).

• **CONCLUSION:** DTI can demonstrate abnormalities in a tissue that appears normal in orbital MRI. Our results suggested that DTI derived measurements correlate with visual disability and tissue injury and therefore they are important from a clinical point of view and also in understanding the pathological processes.

• **KEYWORDS:** diffusion tensor imaging; optic neuritis; optical coherence tomography; multiple sclerosis

DOI:10.3980/j.issn.1672-5123.2018.9.02

Citation: Keskin AO, Idiman F, Alatas O, Ada E, Idiman E, Saatci AO. Diffusion tensor imaging of visual pathways in patients with acute and chronic optic neuritis. *Guoji Yanke Zazhi (Int Eye Sci)* 2018;18(9):1559-1566

INTRODUCTION

Multiple sclerosis (MS) is the most common immune-mediated inflammatory demyelinating disease of the central nervous system. Optic neuritis (ON) is an inflammation of one or both optic nerves resulting usually in temporary visual loss, mainly in young adults. It is highly associated with multiple sclerosis. Assessment of the afferent visual pathway by using clinical, imaging and electrophysiological methods can provide insights into the differential diagnosis and pathophysiology of MS. Abnormalities commonly found on examination in the North American Optic Neuritis Treatment Trial (ONTT) were reduced visual acuity (89.5%), visual field defects (97.5%), impairment of contrast sensitivity (98.2%) and color vision defects (93.8%)^[1]. Visual evoked potentials (VEPs) show conduction block or delay that reflects demyelination and reduced amplitudes that reflect the axonal loss. In MS and ON, the VEP P100 latency is characteristically delayed, usually with preserved waveform amplitude. However, in early and severe ON, the P100 amplitude may be reduced or even P100 may be absent^[2].

Optical coherence tomography (OCT) uses the echo time delay of low coherence light to delineate layers of retina where there is a change in refractive index. Each layer of the retina has a different reflectivity, and can thus be distinguished and measured. The first observation with OCT in MS was made by Parisi *et al*^[3] who found a reduction in RNFL thickness in eyes with a prior history of ON that is often an indicator of axonal loss and is associated with bad prognosis^[3].

Diffusion tensor imaging (DTI) is a noninvasive imaging technique capable of characterizing the diffusion properties of water molecules *in vivo* and detecting microstructural tissue changes not visible on conventional MR imaging. In white matter composed of packed nerve fibers, the diffusion mechanism is facilitated along the fiber tracts, and is slower in the direction perpendicular to the main axis of the tract^[4]. Such diffusion is said to be anisotropic and is dependent on the structural integrity of white matter tracts (Figure 1).

Fractional anisotropy (FA) is a measure of the preponderance of diffusion direction and mean diffusivity (MD) is a measure of average molecular motion^[4-5]. If there is a disruption in

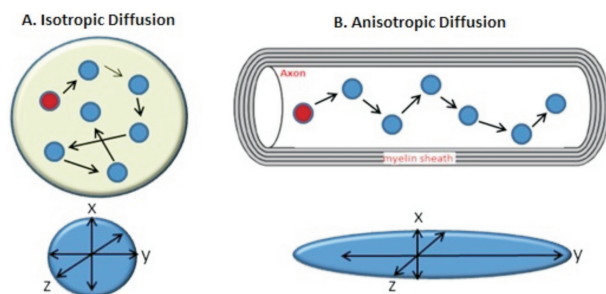


Figure 1 Isotropic and anisotropic diffusion A) Molecular diffusion, or brownian motion, refers to the notion that any type of molecule in a fluid is randomly displaced as the molecule is agitated by thermal energy. Water molecules are in constant motion. When motion is unconstrained, diffusion is isotropic, which means that motion occurs equally and randomly in all directions; B) When molecular motion is constrained, as in white-matter tracts, diffusion is anisotropic, meaning that motion is oriented more in one direction than another (e.g. along the y axis rather than along the x and z axis).

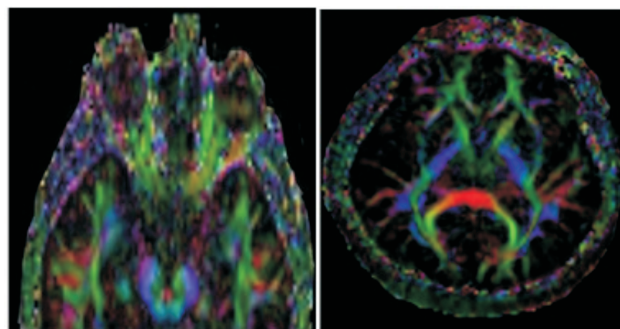


Figure 2 Diffusion tensor imaging of the brain in 23-year-old healthy woman A minimum of six non-collinear diffusion encoding directions are required to measure the full diffusion tensor. For diffusion tensors with high anisotropy, the major eigenvector direction is generally assumed to be parallel to the direction of white matter tract, which is often represented using an RGB (red-green-blue) color map to indicate the eigenvector orientations. On these images, the fibers are given different colors by their direction of diffusion; fibers running left-right are red, antero-posterior are green and supero-inferior are blue.

white matter tracts like demyelination or a change in axonal membrane permeability, a change in anisotropy would be expected by a decrease in FA and an increase in MD in diffusion tensor imaging^[5-7]. Studies in MS have shown increased apparent diffusion coefficient (ADC) and MD with decreased FA in chronic T1-hypointense lesions^[8]. As the optic nerve is almost a pure white matter tract, it should lend itself to study with DTI (Figure 2).

However, high spatial resolution is necessary in the slice direction to reduce the cerebrospinal fluid (CSF) contribution to the signal and to increase fiber coherence within voxels. Diffusion tensor imaging studies of affected optic nerves in patients with a remote history of ON reveal reduced FA and elevated diffusivities as well as correlations with concurrent measurements of acuity, VEPs, and RNFL thickness^[9]. DTI changes were also reported in glaucoma and macular degeneration^[10]. Malania *et al*^[10] reported that RNFL and the

white matter of the visual pathways are significantly altered in macular degeneration patients. Garaci *et al*^[11] investigated both the optic nerve and the optic radiation and reported that these structures had significantly higher MD and significantly lower FA in patients with glaucoma compared to controls. Moreover, MD and FA in the optic nerves were correlated with glaucoma severity^[11].

Multiple sclerosis can be detected by routine MRI with a high detection rate. However, central nervous system lesions due to other disorders may appear similar to MS lesions on MRI. This is particularly true for ischemic lesions, which make conventional MRI less reliable for the diagnosis of MS in patients over the age of 50. Advanced MRI techniques and evoked potentials may be useful in differential diagnosis of MS and can demonstrate occult tissue injury. Clinical involvement of the optic nerve is common in MS. The lesion of optic neuritis can be identified with MRI provided that fat saturation methods are used^[12]. However, early or occult lesions in MS cannot be detected by routine MRI, and this may explain the inconsistency between the severity of the lesions found by MRI and the degree of clinical disability of patients with MS. Although optic neuritis is detected clinically and electrophysiologically in optic nerves, optic nerve involvement in orbital MRI may not be demonstrated. Clinically silent lesions are also frequently found in the posterior afferent visual pathway in MS. Diffusion tensor imaging may be a more sensitive imaging tool for the diagnosis of early or occult lesions in MS, compared with MRI. Diffusion tensor imaging (DTI) has been used to detect occult injury of the corpus callosum in early MS^[8]. In the present study, we investigate whether DTI can demonstrate abnormalities due to axonal loss in the visual pathway that appear normal in orbital MRI, and whether these abnormalities are correlated with loss of function measured in several different evaluation techniques or not.

SUBJECTS AND METHODS

In the present study, we included 26 patients and 13 control (26 eyes) subjects. All patients were examined at the Dokuz Eylul University neuro-ophthalmology outpatient clinic. All participants were between the ages 17 and 55y and had no other ophthalmological disorder or any ischemic risk factors for stroke. All acute ON patients were examined up to 21d after the onset of ON symptoms. Chronic ON patients were examined at least 6mo later than the ON attack. Exclusion criteria for optic neuritis were: 1) Sudden onset, painless visual loss and progressive worsening; 2) Having systemic vasculitis and/or positive vasculitis serology; 3) Positive cerebrospinal fluid PCR serology. Ten patients were diagnosed as clinically isolated syndrome (CIS), 22 patients were diagnosed relapsing remitting multiple sclerosis (RRMS) according to 2010 McDonald criteria, and others had severe and progressive form of disease. None of the control group had any ophthalmological or neurological disorder. The study was approved by the Dokuz Eylul University Ethics Committee. Detailed information was provided to all subjects and controls regarding objectives and the study protocol. All participants

gave written informed consent. We fully adhered to the tenets of the Declaration of Helsinki during the study. Based on clinical features the patients had acute ON episodes in 17 eyes, chronic ON in 20 eyes and 15 unaffected eyes. Also, the visual afferent system was evaluated with neuro-ophthalmological examinations, OCT, VEP, orbital and cranial MRI in all participants. Moreover, we investigated the correlation between the results of different applied methods, and assessed their sensitivities.

Neuro-ophthalmological Evaluations Visual acuity (VA) was evaluated by Snellen chart and best corrected visual acuity was recorded. Visual acuity values were converted into a LogMAR values. If VA was normal in evaluation with Snellen chart, we continued our evaluation with Sloan letters low contrast charts which are more sensitive in diagnosing ON. Abnormality was found in all of the affected eyes with low contrast charts. The cases with 10/10 visual acuity were grouped as normal, 8-9/10 as mild visual loss, 5-7/10 as moderate and 4/10 and lower as severe visual loss. Fundus was evaluated separately for each eye with direct ophthalmoscopy. Color vision was evaluated with Ishihara color vision test.

Visual Evoked Potentials Conventional VEP recordings were used to measure the cortical response to 128 monocular stimulation with 200 msec sweep time. P100 latencies and amplitudes were evaluated.

Retinal Imaging Optic coherence tomography images were acquired with Stratus OCT model version 6.0.2 (Carl Zeiss Meditec). The fast RNFL thickness protocol was applied. All subjects were scanned, and pupils were dilated when small pupil size impaired the imaging. All subjects had ametropia < 10 D. The scans were performed at the retina unit of the Dokuz Eylul University ophthalmology clinic. The Stratus OCT device and software were used to acquire three 3.4 mm diameter circular scans centered on the optic disc for each eye. The mean was used to express RNFL thickness as a single average value for the whole 360° scan. RNFL thickness was measured. The RNFLT of the acute ON patients was calculated by both including and excluding the RNFLT of the anterior ON patients.

Magnetic Resonance Imaging Cranial MR examinations with 1.5 T MR imaging equipment (1.5 T Philips Achieva) were performed in patients included in the study and control groups. The MRI scans of the patients were evaluated twice, pre-contrast and post-contrast.

Sequences Used in MR Imaging T1 weighted TSE sequence: 5 mm section thickness, axial oriented to whole brain, TR:550 ms, TE: 15 ms, Matrix: 256×256, FOV: 240 mm, Proton density (PD) and T2 weighted dual echo SE sequence: 5 mm section thickness, axial oriented to whole brain, TR: 4000 ms, TE: 20 ms. Matrix 320×512, FOV: 230 mm, Rectangular FOV: 85, FLAIR sequence: 3 mm section thickness, sagittal oriented to whole brain, TR: 6000 ms, TE: 120 ms. Average: 1, Matrix: 256×256, FOV: 230,

Table 1 Disease and demographic data

Patient group	Age	Sex(% ; F/M)	MS attacks	EDSS score	OCB type II positivity (%)	Mean±SD
Patients with acute optic neuritis	34±8.67	86.7/13.3	2.64±1.93	2.35± 1.29	64.7	
Patients with chronic ON	32±8.82	76.5/24.5	3.52±2.58	2.63 ±1.57	61.1	

OCB; Oligoclonal band; ON: Optic neuritis; EDSS; Expanded disability status scale.

Table 2 Comparisons of visual acuities, VEP measures, optic nerve DTI and OCT measures between different groups

Evaluation technique	Acute ON (n=17)	Chronic ON (n=20)	Patient unaffected side (n=15)	Control (n=13)	P	Mean±SD
Visual acuity Snellen' chart (LogMAR)	0.50±0.58	0.17±0.24	0.01±0.02	0	<0.05	
RNFL thickness(μm)	90.50±30.38	78.90±17.59	92.62±5.73	100.16±8.2	<0.01	
VEP P100 latency (ms)	148.53±19.41	144.85±17.07	115.18±6.48	108.61±3.91	<0.01	
VEP P100 amplitude(μv)	4.36±2.67	4.66±2.06	7.84±2.47	9.19±3.26	<0.01	
Ishihara test	12.7±9.8	19.01±4.1	20.8±0.4	21.0	<0.01	
Optic nerve FA ×10 ⁻³ mm ² /s	0.50±0.098	0.48±0.080	0.59±0.011	0.60±0.076	0.28	
Optic nerve MD×10 ⁻³ mm ² /s	121.45±23.82	120.97±18.60	108.46±16.31	92.55±11.68	<0.01	

RNFL: Retinal nerve layer fiber; FA: Fractional anisotropy; MD: Mean diffusivity; VEP: Visual evoked potential.

Rectangular FOV: 85, T1 sequence with MT; 3 mm section thickness, axial oriented to whole brain, TR: 517 ms, TE 11 ms, Averages: 2, Matrix: 208×256, FOV: 240 mm, 20 image, Rectangular FOV:85.

T2 gradient echo sequence: 5 mm section thickness, axial oriented to whole brain; TR: 794 ms, TE:26 ms, FA: 20, Average: 1, Matrix: 166×256, FOV: 230 mm, 20 images

Diffusion Tensor Imaging Diffusion tensor imaging was performed in all patients for MD and FA measurements in addition to MR sequences in all patients and in the control group. Subjects were asked to close their eyes and to avoid any deliberate eye movements during image acquisition. A single shot spin-echo echoplanar imaging diffusion sequence was employed with fat-suppression, and reduced field of view technique with twice refocused diffusion weighting. Conventional and diffusion tensor images were evaluated by two separate observers, and fractional anisotropy (FA) and mean diffusion (MD) maps were obtained using Nordic ICE v2.3.10 (Nordic Imaging Lab AS, Bergen, Norway) program. Optic nerves were scanned individually using an optimized six direction fat saturated CSF-suppressed spin-echo EPI DTI sequence. ROI measurements in a mean of 0.1 cm² were performed in intraorbital optic nerves, optic chiasms and optic tracts. Imaging parameters were obtained in the axial plan with the parameters as follows: TR = 3260 ms; TE = 1000 ms; TI = 2100 ms; b-value = 1000 s/mm²; NEX = 1.2; FOV = 220×220 mm²; matrix size = 168 × 168.

Statistical Analysis Sub-group comparisons were performed using the Mann-Whitney U test, and the alpha significance level was interpreted using the Bonferroni correction. To compare the mean values of more than two independent groups that demonstrate regular distribution, the ANOVA test was used if the variances were distributed homogenously. The post-hoc Tukey test was used to evaluate the differences between the groups. Spearman Correlation was used for correlation analysis. The t-test was used to evaluate groups of two with a normal distribution. The equality of variances was

evaluated using the Levene test, and the appropriate P-value was determined.

RESULTS

Disease and Demographic Disease data and demographic data are shown in Table 1. The mean age of the control group was 30±5.44y, 73.8% of them were female. Their age and gender distribution was similar to the patient group. In our study, the disability of the optic neuritis patients was not high, and OCB was type II positivity in a significant portion (Table 1).

Neuro – ophthalmological Findings The lowest visual acuity (VA) was in the group with acute optic neuritis. In the group with chronic optic neuritis, VA was significantly lower than the unaffected and normal control groups just like in acute ON cases (P<0.05). Colored vision was low in the patient group, most significantly in the acute ON patients (Table 2). Papilledema was detected in 11.2% of the patients with acute ON, optical atrophy was detected in 30% of the patients with chronic ON, and temporal paleness in 40%. The cases with 10/10 visual acuity were grouped as normal, 8-9/10 was grouped as mild visual loss, 5-7/10 as moderate, and 4/10 and lower as severe visual loss. In the group with acute ON, full visual acuity was present in 23%, mild visual loss in 6%, and severe visual loss in 47% of the cases. In 35% of the eyes with chronic optic neuritis the visual acuity was measured full, 35% had mild, 10% had moderate, and 20% had severe visual loss.

Visual Evoked Potentials In the VEP evaluation significant prolonged latency and decreased amplitudes were detected in eyes with acute and chronic ON that was marked in the group with acute ON. Measurements of clinically unaffected eyes also showed a mildly prolonged latency and decreased amplitudes when compared to the controls. The P100 amplitude and latency measurements and visual acuity were significantly different between groups (P <0.01) (Table 2).

Optic Coherence Tomography Peripapillary retinal nerve fiber layer thickness (RNFLT) was significantly different

Table 3 Comparisons of optic tract DTI and optic chiasm DTI between different groups

Part of visual pathway	Patient with ON (<i>n</i> =37)	Control (<i>n</i> =13)	<i>P</i>
Optic chiasm FA $\times 10^{-3}$ mm ² /s	0.366±0.98	0.42±11.56	0.140
Optic chiasm MD $\times 10^{-3}$ mm ² /s	154.91±42.61	115.44±24.48	0.011
Optic tract FA $\times 10^{-3}$ mm ² /s	0.335±0.85	0.402±0.54	0.032
Optic tract MD $\times 10^{-3}$ mm ² /s	159.57±35.43	121.23±14.85	0.013

ON: Optic neuritis; FA: Fractional anisotropy; DTI: Diffusion tensor imaging.

Table 4 Comparisons based on the visual acuity

Evaluation techniques	Normal (<i>n</i> =47)	Mildly affected (<i>n</i> =9)	Moderately affected (<i>n</i> =9)	Severely affected (<i>n</i> =13)	Mean±SD
					<i>P</i>
Optic nerve FA $\times 10^{-3}$ mm ² /s	0.59±0.85	0.51±0.97	0.46±0.52	0.43±0.10	<0.01
Optic nerve MD $\times 10^{-3}$ mm ² /s	99.31±12.27	115.19±13.15	124.25±16.00	133.25±24.71	<0.01
VEP P100 latency (ms)	112.52±11.77	136.33±11.98	140.88±17.51	160.58±9.68	<0.01
VEP P100 amplitude (μ v)	7.90±3.27	4.87±2.83	6.32±3.19	3.40±1.97	<0.01
RNFL thickness (μ m)	96.78±15.01	81.88±19.61	85.44±21.82	78.08 ± 20.82	<0.01

RNFL: Retinal nerve layer fiber; VEP: Visual evoked potential.

between groups ($P < 0.01$). The most significant decrease of RNFL levels was detected in the chronic optic neuritis group (Table 2). Two patients with acute ON had anterior ON. The RNFL thicknesses of these two patients were measured as 167 μ m and 122 μ m, respectively. If the data of these two patients were not included in the calculation, the mean RNFL thickness averages of the remaining acute ON eyes were 82.7 μ m.

The MRI Findings of the Brain and Orbit In 82.4% of the acute ON patients and 88.9% of the chronic ON patients, ovoid T2 hyperintense lesions perpendicular to the supratentorial ventricle were observed in the brain MRI. In 58.8% of the acute ON patients and 66.7% of the chronic ON patients, infratentorial T2 hyperintense lesions were detected, and lesions were observed in the corpus callosum in 41.2% of the patients with acute ON and 66.5% of the chronic ON patients.

The orbital MRI of the acute ON patients in the affected optic nerves revealed T2W - hyperintense lesions in 43.4%, contrast enhancement in 22.3%, edema in 16.7%. The orbital MRI of the chronic optic neuritis patients revealed hyperintense lesions in the optic nerve in 20%, atrophy in 20%, and 60% was evaluated as normal.

Diffusion Tensor Imaging Findings The mean FA values measured at the trunks of the optic nerves were lower in the acute and chronic optic neuritis groups, and the MD values were higher than the control group (Table 2).

Although there was a decrease in the FA values measured at the optic chiasm in the patient group when compared to the control group, this decrease did not reach statistical significance ($P = 0.140$). The mean MD values were higher in the patient group when compared to the control group ($P = 0.11$) (Table 3).

While the mean FA values measured at the optic tracts were lower in the patient group than the control group ($P = 0.032$), the mean MD values were higher ($P = 0.013$) (Table 3).

The comparison of Various Evaluation Data of Optic Neuritis Cases

Comparisons based on the visual acuity The cases with 10/10 visual acuity were grouped as normal, 9/10 was grouped as mild visual loss, 5-8/10 as moderate and 4/10 and lower as severe visual loss. When cases were grouped as severely, moderately, mildly affected and full vision according to the loss of vision, statistically significant differences in MD, FA, RNFL, P100 latency and amplitudes were identified ($P < 0.01$) (Table 4). Two patients with acute ON had anterior ON. These two patient's visual acuities were moderately affected.

Comparisons done on the basis of orbital MRI abnormalities When Table 5 is reviewed, it can be seen that the ON cases with orbital MRI abnormalities were compared with the data acquired from other evaluations. We identified that a statistically significant decrease of FA ($P = 0.04$), increase of MD ($P < 0.01$), prolonged P100 latency ($P < 0.01$) and low amplitudes ($P = 0.01$) and a decrease of the RNFL thickness ($P = 0.02$) were present in the eyes with orbital MRI abnormalities when compared to those without (Table 5).

Correlation Analyzes In correlation analyses, the measurements of the affected optic nerves of patients with acute ON, the FA values were correlated with P100 latency ($r = -0.439$) ($P = 0.021$). The MD values were correlated with the P100 amplitudes ($r = -0.389$) ($P = 0.016$), RNFL ($r = -0.464$) ($P = 0.017$) thickness measurements, and visual acuity ($r = -0.334$) ($P = 0.046$). RNFL thickness measurements were also correlated with the visual acuity ($r = -0.485$) ($P = 0.049$). Measurements of the affected optic nerves of patients with chronic ON, FA values were correlated with MD ($r = -0.393$) ($P = 0.02$) and visual acuity ($r = 0.364$) ($P = 0.012$), MD values were correlated with P100 amplitudes ($r = -0.412$, $P = 0.016$) and RNFL thickness ($r = -0.374$) ($P = 0.047$).

In the measurements performed on the unaffected eyes of ON

Table 5 Comparisons done on the basis of orbital MRI abnormalities

Mean±SD

Patient group	Orbita MRI	Optic nerve FA ×10 ³ mm ² /s	Optic nerve MD ×10 ³ mm ² /s	VEP P100 latency(ms)	VEP P100 amplitude (μv)	RNFL thickness (μm)	Visual acuity
Acute optic neuritis (n=17)	Normal MRI (n=7)	0.49±0.06	114.53±26.06	144.72±18.08	4.25±1.77	93.57±13.59	0.57±0.40
	Abnormal MRI (n=10)	0.47±0.10	129.65±21.79	153.200±11.02	4.24±3.23	87.00±36.79	0.49±0.43
Chronic optic neuritis (n=20)	Normal MRI (n=8)	0.50±0.7633	117.31±18.49	141.42±13.51	5.01±2.01	84.42±13.62	0.77±0.24
	Abnormal MRI (n=12)	0.47±0.12	121.47±14.75	146.25±20.22	4.15±2.12	70.62±20.45	0.76±0.35
Control (n=13)	Normal MRI (n=13)	0.60±0.076	92.94±10.80	110.62±3.66	9.19±3.26	100.16± 8.23	1.00
	Patient unaffected side (n=15)	0.59±0.11	108.46±10.05	115.13±6.59	7.78±2.67	92.80±5.89	0.98±0.05

FA;Fractimal anisotropy.

patients, the FA values were correlated with P100 latency ($r = -0.321$) ($P = 0.012$) and amplitudes ($r = 0.306$) ($P = 0.029$) and also with the visual acuity ($r = 0.388$) ($P = 0.039$). The MD and FA values were correlated with measurements performed at the chiasm and optic tracts in the patient and healthy control groups, but no correlation was identified with the disease duration ($P > 0.05$).

Abnormalities in evaluation techniques Abnormality was found in all of the affected eyes with low contrast letter charts. Clinical assessments were taken as the gold standard. Abnormalities were identified at a rate of 97% in the VEP evaluations of eyes clinically diagnosed with ON. This rate was 46% in the unaffected eyes of the patient group. The OCT abnormality was 82% in the eyes with ON and 13% in the unaffected eyes of the patient group.

Contrast enhancement and atrophy were the abnormalities in orbital MRI. Abnormalities were identified at a rate of 48.4% in the orbital MRI of eyes clinically diagnosed with ON. No pathology was detected in the orbital MRI of the unaffected eyes of the patient group.

The DTI abnormality was determined by difference from the mean value ±2 SD. The DTI abnormalities were detected in 62% of the eyes with ON (FA decrease and/or MD increase). The FA decrease was detected in 13% and MD increase was detected in 26% in the unaffected eyes of the patient group. Healthy control group did not demonstrate an abnormal value.

DISCUSSION

The visual pathways, more significantly the optic nerves, are commonly affected in ON and MS. In patients, who have had ON attacks, the DTI indexes have shown changes in the optic nerves of the affected eyes and the optic tracts. When the data we acquired in this study was compared with the ONTT 1991 data, the visual acuities of the acute ON group were consistent with the values determined in that study. In a follow-up study performed with ON patients, the visual acuity was 20/20 in 74%, and better than 20/40 in 90% in the clinical

evaluation of the cases after 10y^[13]. This data shows that the chronic ON patients we examined in our study were much more severely affected than the patients reported in literature. The RNFL thickness measured by OCT is a good marker of axonal degeneration. A correlation between the decrease of RNFL thickening and brain volume loss has been shown and has been associated with neurodegeneration^[14]. The most significant RNFL thickness decrease was identified in the group with chronic ON in the presented study that demonstrate axonal degeneration was also correlated with MD. The findings are consistent with the results of other studies in literature^[6,15].

The purpose of this study is to examine visual pathway with different research methods, investigate the correlations of DTI with other study methods to provide information about axonal integrity, as they have gained a lot of attention in recent years and investigate normal appearing optic nerves with DTI to investigate occult axonal degeneration. Any pathology that leads to changes in axonal membrane permeability causes changes in diffusion tensor indexes^[16]. Previous studies have shown that diffusion abnormalities of optic nerves in ON and the brain tissue of MS patients can be identified with DTI, which appear normal in MRI^[17-18].

It has also been shown that the changes in the optic tracts of patients, who have had optic neuritis attacks, may be associated with transsynaptic degeneration^[19-20].

In the present study, we measured significantly higher MD values in the chiasms of the patient group than the normal group. It is hard to visualize the optic chiasm clearly in this area because of the oblique fibers with DTI and studies are required to visualize the optic chiasm clearly^[21]. There are very few studies in the literature that evaluate the optic tracts using DTI. In a recent study, diffusion abnormalities have also been shown in measurements done in the optic tracts of ON patients^[6]. In a study conducted by Reich *et al*^[17] in 2009, increased MD, decreased FA, and radial and axial diffusion increase were identified in the optic tracts of the

patient group and a significant correlation was found between the RNFL thickness and FA.

Eyes were grouped as severe, moderate, mild involvement and full vision in the present study according to the degree of visual loss and statistically significant differences between the MD, FA, RNFL thickness, P100 latency, and amplitudes were identified. A correlation was identified between the decrease of visual acuity, and the diffusion changes identified in DTI and the decrease of RNFL thickness. Interestingly, RNFL and VEP damage in the moderately vision affected eyes were statistically milder compared to the less affected VA. This was thought to be due to the increased RNFL thickness related to anterior optic neuritis in two eyes of the moderately vision affected group. In addition, the majority of the mildly vision affected group consisted of chronic ON patients (7/9), milder damage for P100 amplitude may be due to ongoing axonal degeneration in chronic ON. The results of our study show that the measurements done using DTI are in correlation with visual disability.

In the present study, the rate of abnormalities identified in VEPs of the eyes that were clinically defined as ON is 97%. Sensitivity of VEP in detecting abnormalities was also higher than the sensitivity of OCT and DTI. In our study the consistency of DTI findings with orbital MRI data has suggested that DTI is more sensitive than orbita MRI that has a relatively low sensitivity but a high specificity. Orbita MRI scan together with DTI examination may also reveal the involvement of optic nerve that appears normal in MRI and to estimate the extent of axonal degeneration.

The present study has shown that the increase in visual disability in optic neuritis patients in acute and chronic phases is correlated with the decrease in FA and the increase in MD. Visual dysfunction identified in clinical neuro – ophthalmological tests and the DTI findings are consistent. This feature points to the clinical safety of the examination and its usability in clinical practice. The correlation of RNFL thickness with DTI measurements in chronic optic neuritis has been explained with axonal degeneration, suggesting that DTI is a reliable method for demonstrating axonal degeneration.

The present study reveals that diffusion and axonal permeability abnormalities occurs not only in optic nerves but also in optic chiasm and optic tracts and even in normally appearing optic nerves in MRI. DTI abnormalities in the areas that appear normally in conventional MRI have also been revealed in previously conducted studies^[18,22–24]. This finding suggests that neurodegeneration is present at the early stages of the disease and provides additional evidence that MS pathology may be observed in normal appearing white matter. Suggesting that transsynaptic degeneration may also contribute to the damage of visual pathways. Eight CIS cases were examined in our study. Acute optic neuritis was identified in five of the CIS cases. Most of our acute ON cases are diagnosed MS. In some of these cases, subclinical chronic optic neuritis may be present, and the presence of

demyelination and axonal degeneration together may be perceived to be more natural. However, if these examinations are performed in more CIS cases with optic neuritis and similar results are obtained, this will definitely be supportive of the view that neurodegeneration is present from the onset of multiple sclerosis. If we also take into consideration that the changes in DTI indices were shown to be correlated with the prognosis of the disease, the importance of this finding may be more comprehensible^[25–27]. This shows that DTI can provide valuable information about disease prognosis, the efficiency of treatment and even early diagnosis.

Recent studies have revealed that radial diffusion is correlated with disease progression and axonal degeneration^[9,15]. The correlation between evaluation techniques associated with axonal degeneration, such as RNFL thickness, can be better revealed by performing radial diffusion measurement. Van der Walt *et al*^[27] revealed a correlation with multifocal VEP amplitude and DTI abnormalities. We conclude that the correlations between VEP amplitude, RNFL thickness, DTI indices and disease progression can be assessed better by performing these evaluation techniques.

DTI can provide important information about the progression of MS, similar to OCT. It can be used to monitor treatment and as the DTI technique advances it can be used especially in MS cases for early diagnosis. We believe that diffusion tensor imaging studies composed from different designs by advancements in technology can provide much more information about the pathogenesis of optic neuritis and MS, and their diagnosis, treatment and prognosis.

REFERENCES

- 1 The clinical profile of optic neuritis. Experience of the Optic Neuritis Treatment Trial. Optic Neuritis Study Group. *Arch Ophthalmol* 1991;109(12):1673–1678
- 2 Youl BD, Turano G, Miller DH, Towell AD, MacManus DG, Moore SG, Jones SJ, Barrett G, Kendall BE, Moseley IF. The pathophysiology of acute optic neuritis. An association of gadolinium leakage with clinical and electrophysiological deficits. *Brain* 1991;114(Pt 6):2437–2450
- 3 Parisi V, Manni G, Spadaro M, Colacino G, Restuccia R, Marchi S, Bucci MG, Pierelli F. Correlation between morphological and functional retinal impairment in multiple sclerosis patients. *Invest Ophthalmol Vis Sci* 1999;40(11):2520–2527
- 4 Fox RJ. Picturing multiple sclerosis: conventional and diffusion tensor imaging. *Semin Neurol* 2008;28(4):453–466
- 5 Miller TR, Mohan S, Choudhri AF, Gandhi D, Jindal G. Advances in multiple sclerosis and its variants: conventional and newer imaging techniques *Radiol. Clin North Am* 2014;52(2):321–336
- 6 Dasenbrock HH, Smith SA, Ozturk A, Farrell SK, Calabresi PA, Reich DS. Diffusion tensor imaging of the optic tracts in multiple sclerosis: association with retinal thinning and visual disability. *J Neuroimaging* 2011;21(2):e41–e9
- 7 Kolappan M, Henderson AP, Jenkins TM, Wheeler–Kingshott CA, Plant GT, Thompson AJ, Miller DH. Assessing structure and function of the afferent visual pathway in multiple sclerosis and associated optic neuritis. *J Neurol* 2009;256(3):305–319
- 8 Filippi M, Iannucci G, Cercignani M, Assunta Rocca M, Pratesi A, Comi G. A quantitative study of water diffusion in multiple sclerosis

- lesions and normal-appearing white matter using echo-planar imaging. *Arch Neurol* 2000;57(7):1017-1021
- 9 Naismith RT, Xu J, Tutlam NT, Lancia S, Trinkaus K, Song SK, Cross AH. Diffusion tensor imaging in acute optic neuropathies: predictor of clinical outcomes. *Arch Neurol* 2012;69(1):65-71
- 10 Malania M, Konrad J, Jäggle H, Werner JS, Greenlee MW. Compromised integrity of central visual pathways in patients with macular degeneration. *Invest Ophthalmol Vis Sci* 2017;58(7):2939-2947
- 11 Garaci FG, Bolacchi F, Cerulli A, Melis M, Spanò A, Cedrone C, Floris R, Simonetti G, Nucci C. Optic nerve and optic radiation neurodegeneration in patients with glaucoma: in vivo analysis with 3-T diffusion-tensor MR imaging. *Radiology* 2009;252(2):496-501
- 12 Gass A, Moseley IF, Barker GJ, Jones S, MacManus D, McDonald WI, Miller DH. Lesion discrimination in optic neuritis using high-resolution fat-suppressed fast spin-echo MRI. *Neuroradiology* 1996;38(4):317-21
- 13 Beck RW, Gal RL, Bhatti MT, *et al*; Optic Neuritis Study Group. Visual function more than 10 years after optic neuritis: experience of the optic neuritis treatment trial. *Am J Ophthalmol* 2004;137(1):77-83
- 14 Galetta KM, Calabresi PA, Frohman EM, Balcer LJ. Optical coherence tomography (OCT): imaging the visual pathway as a model for neurodegeneration. *Neurotherapeutics* 2011;8(1):117-132
- 15 Kolbe SC, van der Walt A, Butzkueven H, Klistorner A, Egan GF, Kilpatrick TJ. Serial diffusion tensor imaging of the optic radiations after acute optic neuritis. *J Ophthalmol* 2016;2016:2764538
- 16 Lerner A, Mogensen MA, Kim PE, Shiroishi MS, Hwang DH, Law M. Clinical applications of diffusion tensor imaging. *World Neurosurg* 2014;82(1-2):96-109
- 17 Reich DS, Smith SA, Gordon-Lipkin EM, Ozturk A, Caffo BS, Balcer LJ, Calabresi PA. Damage to the optic radiation in multiple sclerosis is associated with retinal injury and visual disability. *Arch Neurol* 2009;66(8):998-1006
- 18 Horsfield MA, Larsson HB, Jones DK, Gass A. Diffusion magnetic resonance imaging in multiple sclerosis. *J Neurol Neurosurg Psychiatry* 1998; 64(Suppl I): S80-S84
- 19 Kolbe S, Bajraszewski C, Chapman C, Nguyen T, Mitchell P, Paine M, Butzkueven H, Johnston L, Kilpatrick T, Egan G. Diffusion tensor imaging of the optic radiations after optic neuritis. *Hum Brain Mapp* 2012;33(9):2047-2061
- 20 Balk LJ, Steenwijk MD, Tewarie P, Daams M, Killestein J, Wattjes MP, Vrenken H, Barkhof F, Polman CH, Uitdehaag BM, Petzold A. Bidirectional trans-synaptic axonal degeneration in the visual pathway in multiple sclerosis. *J Neurol Neurosurg Psychiatry* 2015;86(4):419-424
- 21 Zhang Y, Wan SH, Wu GJ, Zhang XL. Magnetic resonance diffusion tensor imaging and diffusion tensor tractography of human visual pathway. *Int J Ophthalmol* 2012;5(4):452-458
- 22 Giorgio A, Palace J, Johansen-Berg H, Smith SM, Ropele S, Fuchs S, Wallner-Blazek M, Enzinger C, Fazekas F. Relationships of brain white matter microstructure with clinical and MR measures in relapsing-remitting multiple sclerosis. *J Magn Reson Imaging* 2010;31(2):309-316
- 23 Filippi M, Cercignani M, Inglese M, Horsfield MA, Comi G. Diffusion tensor magnetic resonance imaging in multiple sclerosis. *Neurology* 2001; 56(3):304-11
- 24 Moll NM, Rietsch AM, Thomas S, Ransohoff AJ, Lee JC, Fox R, Chang A, Ransohoff RM, Fisher E. Multiple sclerosis normal-appearing white matter: Pathology-imaging correlations. *Ann Neurol* 2011;70(5):764-773
- 25 Tian W, Zhu T, Zhong J, Liu X, Rao P, Segal BM, Ekholm S. Progressive decline in fractional anisotropy on serial DTI examinations of the corpus callosum: a putative marker of disease activity and progression in SPMS. *Neuroradiology* 2012;54(4):287-297
- 26 Naismith RT, Xu J, Tutlam NT, Scully PT, Trinkaus K, Snyder AZ, Song SK, Cross AH. Increased diffusivity in acute multiple sclerosis lesions predicts risk of black hole. *Neurology* 2010;74(21):1694-1701
- 27 Van der Walt A, Kolbe SC, Wang YE, Klistorner A, Shuey N, Ahmadi G, Paine M, Marriott M, Mitchell P, Egan GF, Butzkueven H, Kilpatrick TJ. Optic nerve diffusion tensor imaging after acute optic neuritis predicts axonal and visual outcomes. *PLoS ONE* 2013;8(12):e83825