

Clinical outcomes after femtosecond laser assisted cataract surgery with implantation of the tecnis symfony intraocular lens

Ji-Lin Tan^{1*}, Yan Qin^{1*}, Shi-Man Yuan¹, Hao Du¹, Xia-Lu Liu¹, Jian Ye²

引用: 谭吉林, 秦艳, 袁诗曼, 等. 飞秒激光辅助白内障联合 TECNIS Symfony 人工晶状体植入术后视觉质量的评价. 国际眼科杂志 2019;19(2):188-193

Foundation item: Clinical studies of femtosecond laser - assisted cataract surgery combined multifocal intraocular lenses in correcting presbyopia (No.AF152D10)

¹Chongqing Aier Mega Eye hospital, Chongqing 400060, China

²Department of Ophthalmology, Daping Hospital of Army Medical University, Chongqing 400016, China

Co-first authors: Ji-Lin Tan and Yan Qin

Correspondence to: Jian Ye. Department of Ophthalmology, Daping Hospital of Army Medical University, Chongqing 400016, China. Yejian1979@163.com

Received: 2018-01-03 Accepted: 2018-10-29

飞秒激光辅助白内障联合 TECNIS Symfony 人工晶状体植入术后视觉质量的评价

谭吉林¹, 秦艳¹, 袁诗曼¹, 杜浩¹, 刘夏露¹, 叶剑²

基金项目: 飞秒激光辅助的 Phaco 手术联合多焦点人工晶体植入治疗老视的效果分析 (No.AF152D10)

(作者单位: ¹400060 中国重庆市重庆爱尔麦格眼科医院; ²400016 中国重庆市陆军军医大学第三附属医院大坪医院)

*: 谭吉林和秦艳对本文贡献一致。

作者简介: 谭吉林, 毕业于重庆医科大学, 本科, 主任医师, 研究方向: 白内障; 秦艳, 毕业于陆军军医大学, 硕士, 主治医师, 研究方向: 白内障。

通讯作者: 叶剑, 毕业于陆军军医大学, 博士, 主任医师, 教授, 研究方向: 白内障. yejian1979@163.com

摘要

目的: 通过观察飞秒激光辅助的白内障手术联合 TECNIS Symfony 连续视程人工晶状体植入术后远中近全程视力、对比敏感度, 主观满意度, 综合评价 TECNIS Symfony 人工晶状体植入术后患者的视觉质量。

方法: 收集我院目前已实施 40 例 55 眼飞秒激光辅助白内障联合 TECNIS Symfony 连续视程人工晶状体植入术资料, 检测术后 3mo 裸眼远视力 (5 m)、中视力 (67 cm) 及近视力 (40 cm), 绘制离焦曲线, 根据多焦晶体满意度调查表并计算脱镜率。

结果: 所有患者术中术后无严重并发症发生。术后 3mo,

所有患者人工晶状体位置居中, 无明显偏位或倾斜。术后 3mo, 5 m、67 cm、40 cm 平均裸眼 LogMAR 视力分别为: -0.04 ± 0.08 , -0.17 ± 0.22 , 0.37 ± 0.17 。总体脱镜率 95%。不同空间频率的对比敏感度较普通单焦非球面人工晶状体无明显下降。无中等或严重光学干扰现象发生。远中近各功能区满意度评分分别为 9.0, 9.0, 7.0 分。

结论: 飞秒激光辅助的白内障手术联合 TECNIS Symfony 连续视程人工晶状体植入术后可获得满意的远中裸眼视力和基本满足日常生活的近视力, 术后光学干扰少, 脱镜率高, 患者满意度高。

关键词: 白内障; TECNIS Symfony; 连续视程人工晶状体; 飞秒激光辅助的白内障手术; 光学干扰

Abstract

• **AIM:** To evaluate the clinical outcomes in terms of vision across distances (near, intermediate and far), contrast sensitivity and subjective patient satisfaction after femtosecond laser - assisted cataract surgery (FLACS) with implantation of an extended range of vision (ERV) intraocular lens (IOL).

• **METHODS:** Forty patients (55 eyes) underwent bilateral or monocular FLACS with implantation of the ERV IOL Tecnis Symfony (Johnson & Johnson Vision) were enrolled. Uncorrected distance (UDVA), intermediate (UIVA) and near visual acuities (UNVA) were evaluated at 3mo after surgery, as well the defocus curve, contrast sensitivity, patient satisfaction and spectacle independence.

• **RESULTS:** No severe complications occurred. All eyes showed a central position of the IOL in the capsular bag without tilting at 3mo after surgery. 3mo postoperative mean logMAR visual acuity at 5 m, 67 cm and 40 cm were -0.04 ± 0.08 , -0.17 ± 0.22 , 0.37 ± 0.17 , respectively. All patients obtained satisfactory UDVA and UIVA, as well as functional UNVA, meeting the needs of daily life. Spectacle independence rate was 94.55%. Contrast sensitivity results did not differ from those obtained with monofocal aspheric lenses. Likewise, no moderate and severe photic phenomena were reported. Mean patient satisfaction scores with distance, intermediate and near vision were 9.0, 9.0, and 7.0, respectively.

• **CONCLUSION:** FLACS with implantation of the ERV IOL TECNIS Symfony provides a successful visual restoration

at far, intermediate distance and a functional-range near vision acuity, with minimal level of disturbing photic phenomena, and high rates of spectacle independence and patient satisfaction.

• **KEYWORDS:** cataract; extended range of vision IOL; FLACS; Tecnis Symphony; multifocal IOL; glare; presbyopia

DOI:10.3980/j.issn.1672-5123.2019.2.02

Citation: Qin Y, Tan JL, Yuan SM, Du H, Liu XL, Ye J. Clinical outcomes after femtosecond laser assisted cataract surgery with implantation of the tecnis symphony intraocular lens. *Guoji Yanke Zazhi(Int Eye Sci)* 2019;19(2):188-193

INTRODUCTION

Presbyopia affects the quality of life in elderly people^[1]. The compensation of this condition has become a major research focus in recent years. Due to increasing visual demands among elderly patients and the continuous development of cataract surgery technologies, the surgical correction of presbyopia has advanced significantly, the combination of cataract surgery with multifocal intraocular lens (MIOL) implantation being one of the most recommendable options^[2]. An increasing number of MIOLs have been developed and used in clinical practice^[2]. According to the 2014 statistical report from 1,502 members of the American Society of Cataract and Refractive Surgery (ASCRS), the use of presbyopia-correcting IOLs was still lower than 8%, primarily due to worries of patients and physicians about the potential induction of poor postoperative vision, decreased contrast sensitivity, and disturbing photic phenomena, such as glare and halos^[3].

In June 2014, the intraocular lens (IOL) Tecnis Symphony (Johnson & Johnson Vision, Santa Ana, California, USA) was introduced. This IOL has the peculiarity of being the first extended range of vision (ERV) IOL, with a specific design based on the combination of the compensation of spherical and chromatic corneal aberration^[4-6]. This optical design provides a continuous range of vision allowing a postoperative functional near, intermediate and distance vision and therefore high levels of spectacle independence^[7-9]. One advantage of this ERV IOL over MIOLs is that it provides a continuous range of high-quality vision, with good levels of contrast sensitivity and minimal induction of disturbing photic phenomena that are commonly reported with MIOLs^[8-9]. Studies published to date have demonstrated that Tecnis Symphony IOL can provide 0.0 logMAR or better visual acuity at a distance far than 67 cm, while 0.3 logMAR or better visual acuity at a distance far than 40 cm^[7-9]. Furthermore, Hamid and Sokwala^[10] found that the ERV Tecnis Symphony IOL provided better contrast sensitivity than MIOLs, with higher levels of postoperative patient satisfaction.

This study aimed at evaluating the clinical outcomes in terms

of visual acuity (near, intermediate and far), contrast sensitivity and subjective patient satisfaction after femtosecond laser-assisted cataract surgery (FLACS) with implantation of the Tecnis Symphony IOL.

SUBJECTS AND METHODS

Patients A total of 40 patients (55 eyes) were enrolled in this study. All of them underwent FLACS with implantation of the ERV IOL Tecnis Symphony IOL since July 2016. Inclusion criteria were definite diagnosis of age-related cataract and/or presbyopia, correctable ametropia with or without cataract, demand for spectacle independence, and reasonable expectations regarding the postoperative outcome. Exclusion criteria included astigmatism of more than 1.5 D, keratoconus or other keratopathies affecting visual acuity, fundus lesions, pupil diameter is more than 6 mm or less than 2 mm under natural light, professional drivers and those who often drive at night, history of previous eye surgery, patients suffering anxiety or paranoia, and patients with systemic disease (baseline data of all patients in Table 1).

Examination Protocol All patients underwent a preoperative examination including measurement of uncorrected distance visual acuity (UDVA), best corrected distance visual acuity (BCDVA), uncorrected near visual acuity (UNVA), split-lamp examination, non-contact measurement of intraocular pressure (IOP), optical biometry (IOL-Master 500, Carl Zeiss Meditec, Jena, Germany), corneal and anterior segment analysis (Pentacam, Oculus Optikgeräte GmbH, Wetzlar, Germany), and fundus evaluation. The power of IOL was selected according to the calculations provided by the optical biometer using the following formulas; Hoffer Q formula is adopted for the ones with eye axial length (AL) below 22.0 mm, Haigis formula is adopted for the ones with AL between 22.0 mm and 25.0 mm, Holladay formula is adopted for the ones with AL between 25.0 mm and 26.0 mm, and SRK-T formula is adopted for the ones with AL over 26.0 mm. Furthermore, the needs of the patient were also considered when selecting the IOL power, with a planned residual refraction of -0.50 D for eyes with AL of more than 26.0 mm and often using near vision, and -0.30 D for the rest of the patients.

Postoperatively, patients were examined at 1d, 1wk, 1mo and 3mo after surgery, with measurement of uncorrected and corrected visual acuity at all visits. At 3mo, the patient examination also included measurement of contrast sensitivity (Glare Tester CGT-1000, Takagi, Seiko) and defocus curve. Likewise, patients completed a satisfaction questionnaire (Figure 1).

Surgical Protocol All surgical procedures were performed by the same experienced surgeon. Surgery was initiated with the creation of a continuous annular capsulorrhexis with a 5.2 mm diameter using the femtosecond laser platform LenSx (Alcon, Fort Worth, Texas, USA), followed by nucleus chopping and the creation of a 2.2 mm transparent corneal

Table 1 Baseline data of all patients

Mean age (y)	Gender (M/F, %)	Preoperative mean UCVA	Preoperative mean axial length (mm)	Preoperative mean astigmatism (D)	IOL mean power (D)	IOL mean reserved powder (D)
70.82	45.0/55.0	0.25	24.10	0.69	19.09	-0.21

Name:	Gender:	Age:
-------	---------	------

Questionnaire on visual performance after implantation of presbyopia-correcting IOL (3 months postoperative)

- Do you need to wear eyeglasses or contact lenses after the operation?
 A. Often B. Sometimes C. Negative (please skip to Question 5)
- Do you need to wear eyeglasses or contact lenses to see objects at far distance (seeing the sight, or a movie, watching TV) after the operation?
 A. Negative B. Rarely C. Sometimes D. Usually E. Often
- Do you need to wear eyeglasses or contact lenses to see objects at intermediate distance (using a computer) after the operation?
 A. Negative B. Rarely C. Sometimes D. Usually E. Often
- Do you need to wear eyeglasses or contact lenses to see objects at near distance (using a cell phone, reading newspaper) after the operation?
 A. Negative B. Rarely C. Sometimes D. Usually E. Often
- If rated on a scale of 1 to 10 from least satisfied to most satisfied, how will you rate your postoperative visual satisfaction?
- How much difficulty do you have with any of the following? Please circle the point that best describe your situation. A point of 0 indicates there is no difficulty.

Glare (due to strong light or car headlights)	0	1	2	3	4	5
Night vision	0	1	2	3	4	5
Color distinguishing (e.g., unable to distinguish a specific color)	0	1	2	3	4	5
Depth sensing (e.g., going down stairs, pouring water, and arranging articles in a line)	0	1	2	3	4	5
Halos (streetlight is surrounded by a light ring)	0	1	2	3	4	5
- How much difficulty do you have to perform the following activities without correcting glasses? Please circle the point that best describe your situation. A point of 0 indicates there is no difficulty.

Daily activities	N/A	0	1	2	3	4	5
Watching a movie or TV	●	0	1	2	3	4	5
Working	●	0	1	2	3	4	5
Reading newspaper	●	0	1	2	3	4	5
Using a computer	●	0	1	2	3	4	5
Cooking	●	0	1	2	3	4	5
Shopping	●	0	1	2	3	4	5
Using a cell phone	●	0	1	2	3	4	5

Figure 1 Questionnaire on patient satisfaction administered to all patients at 3mo after surgery.

incision at 12 o'clock and an auxiliary incision at 9 o'clock. In those eyes with corneal astigmatism of more than 0.75 D, corneal relaxing incisions were performed with the femtosecond laser, with position, arc and depth selected according to the web based calculation of the femtosecond laser astigmatism correction (Alcon, Fort Worth, Texas, USA). Afterwards, ordinary phacoemulsification was initiated using the Infinity system (Alcon, Fort Worth, Texas, USA), followed by injection of viscoelastic substance into the lateral incision. Phacoemulsification was continued and followed by suction of cortex, injection of viscoelastic substance, implantation and centration of the IOL. Removal of viscoelastic substance was the last step of the surgical procedure. Prophylactic medication was prescribed to be applied during the initial postoperative period: Tobramycin/Dexamethasone eye drops (4 drops daily) for 4wk, being gradually reduced each week, and Bromfenac Sodium Hydrate ophthalmic solution (2 drops daily) for 4wk.

Statistical Analysis SPSS 19.0 statistical software was used for data analysis. The results of all variables were expressed as mean ± standard deviation (SD). Paired student *t* test was used for the evaluation of changes in visual acuity and refraction between preoperative and postoperative visits, with *P* < 0.05 indicating that differences reached statistical significance.

RESULTS

The sample included a total of 22 males (27 eyes) and 18 females (28 eyes), with a mean age of 70.8 years. Mean preoperative corneal astigmatism was 0.69 D, with mean preoperative axial length (AL) was 24.10 mm and uncorrected distance visual acuity (UDVA) was 0.25. Mean IOL power was 19.1 D. All patients completed the surgical procedure successfully, without experiencing any serious complication during the operation.

Visual and Refractive Outcomes A statistically significant improvement in both UDVA and refractive astigmatism was

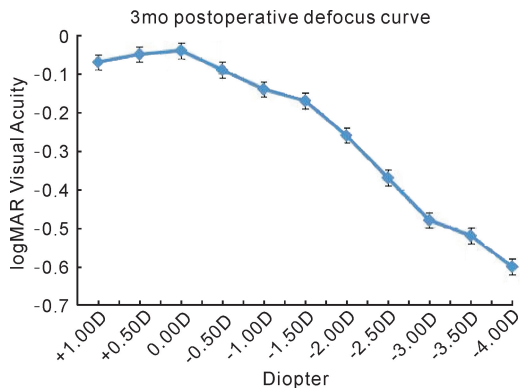


Figure 2 Postoperative monocular defocus curve at 3mo after surgery.

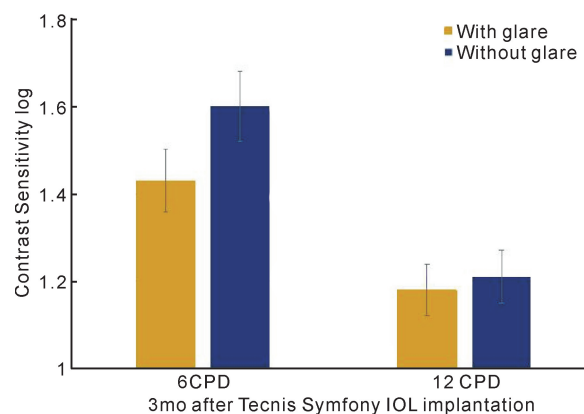


Figure 3 Mean contrast sensitivity at 3mo after surgery for the spatial frequencies of 6 and 12 cycles/degree measured with and without glare.

Table 2 Questionnaire on spectacle independence and subjective satisfaction of all patients regarding various functions 3mo postoperation

Function	Watching TV	Using a computer	Reading or cell phone
Use of eyeglasses (eyes, %)	0 (0.00%)	0 (0.00%)	3 (5.45%)
Satisfaction score	9	9	7

Patient satisfaction was rated on a scale of 0–10 points; 0– “totally unsatisfied” and 10 – “very satisfied” Satisfaction score is the median calculated.

observed after surgery ($P < 0.001$). Residual refraction was measured by comprehensive optometry 3mo after surgery with a result that residual spherical ranged from -0.01 to -0.49 D (with an average -0.21 ± 0.11 D) and mean residual astigmatism ranged from -0.12 to -1.35 D (with an average 0.46 ± 0.40 D). The defocus curve observed at 3mo after surgery showed a satisfactory visual acuity for all patients, with a continuous range of good performance from distance to vergence levels of $1.50 - 2.00$ D (equivalent to objects at 66 cm– 50 cm) (Figure 2).

Contrast Sensitivity Outcomes Figure 2 displays mean contrast sensitivity values at 3mo after surgery for the spatial frequencies of 6 and 12 cycles/degree (cpd), measured with and without glare. As shown, contrast sensitivity value were separately 1.43 and 1.6 with and without glare under 6 cpd, while the value there were separately 1.18 and 1.21 under 12 cpd. The result shows a significant reduction of contrast sensitivity when measured with a glare source ($P < 0.001$).

Patient Satisfaction Outcomes Only 3 patients (5.45%) had to wear glasses for reading or using cell phone, whose spectacle lens power were $+2.0$ D, $+2.5$ D and $+2.0$ D respectively, with an overall spectacle independence rate of 94.55%. None of the patients reported the need of glasses for watching television or using the computer (Table 1). Likewise, no disturbing photic phenomena including glare, halos and chromatic distortion were reported by most of patients at 3mo after surgery, with only 2 patients (3.64%) complained of halos, and only 1 patient (2.50%) complained

Table 3 Photic phenomena observed in all patients 3mo postoperatively

Parameter	Glare	Halos	Chromatic aberration
Visual interference (eyes, %)	1 (2.50%)	2 (3.64%)	0 (0.00%)

of glare during night driving, but the patient’s overall quality of life was not affected. The patient satisfaction score for visual performance achieved at far, intermediate and near distance was 9, 9 and 7 respectively (0 – “totally unsatisfied” and 10 – “very satisfied”) (Table 2).

Complications On the first postoperative day, mild corneal edema was observed in one eye (1.82%) that disappeared within the next 3d with treatment. Furthermore, high IOP was observed in two eyes (3.64%) on day 1, with a return to normal values at 3d after anterior chamber lavage. Obvious corneal edema, uncontrolled IOP, endophthalmitis, obvious posterior capsule opacification, or pupil deformation was not observed in any patient at 1wk, 1mo, or 3mo after surgery. Mydriasis test was performed for all patients at 3mo postoperatively, showing that all IOLs were well centered in the capsule, with no IOL displacement or tilting, or signs of capsular contraction syndrome.

DISCUSSION

Conventional diffractive MIOLs use the principle of diffraction to generate two or more focal points, and therefore provide some level of pseudophakic accommodation. In eyes implanted with this type of IOL, light coming from an object at far or near distance is focused on the retina^[11]. This allows the patient to have a good near, intermediate and distance visual performance, with high levels of spectacle independence^[2-3]. However, MIOLs also have some limitations. The most common is the induction of some level of photic phenomena, such as glare and halos^[12]. Indeed, the presence of this type of phenomena is the main cause of dissatisfaction after cataract surgery with MIOL implantation^[13] as well as the main cause leading to the explantation of this type of lens^[14]. The Tecnis Symphony IOL which is a new option is an ERV IOL aimed at

providing a continuous range of vision and reducing the induction of photic phenomena. The optical design of this ERV IOL is based on the combination of the compensation for the corneal spherical and chromatic aberration with a diffractive technology, allowing a good refractive correction, optimized visual quality and an increase of the range of vergences, for which a not significantly degraded image is obtained^[4-6,8]. The patented echelette diffraction grating design of its posterior surface is a new light diffraction mode for IOLs, providing constructive interference of light in different zones to enhance depth of focus by optimizing the diffraction gradient width, height and profile. In the current series, we have evaluated the clinical outcomes in terms of vision across distances (near, intermediate and far), contrast sensitivity and subjective patient satisfaction with this IOL after its implantation using a FLACS procedure.

Our results show good levels of UDVA (-0.04 ± 0.08 logMAR, 5 m) and UIVA (-0.17 ± 0.22 logMAR, 67 cm) as well as relatively good UNVA (0.37 ± 0.17 logMAR, 40 cm), confirming the ability of the ERV IOL to provide an efficacious visual restoration after cataract surgery. This is consistent with the results of all previous studies evaluating outcomes of this ERV IOL, using a conventional phacoemulsification procedure^[7-10]. These visual results obtained in our sample were associated to a relatively high levels of spectacle independence, as in previous series^[7-10]. Specifically, in the CONCERTO international multicenter study^[8], the ERV IOL Tecnis Symphony showed excellent visual outcomes at all distances, with UDVA, UIVA and UNVA of logMAR were -0.03 , -0.11 and -0.18 respectively, with some level of additional improvement in the near vision performance, when the IOL was implanted bilaterally using a micro-monovision approach. The prospective multicenter study of Kaymak *et al.*^[7] concluded that 3mo after implantation of the ERV IOL Tecnis Symphony UDVA of logMAR was -0.05 ± 0.11 and UIVA were -0.09 ± 0.02 , respectively, indicating that the same ERV IOL provided better far and intermediate vision than near vision, but the near vision is still in a functional range, which can meet the demands of daily living activities, which is in line with our research results.

One factor contributing to the good visual outcome obtained in our series and in previous studies is the high level of tolerance of the ERV IOL to mild to moderate residual astigmatism. It has been demonstrated that a residual astigmatism of 0.75 D after Tecnis Symphony IOL implantation has no significant impact on monocular and binocular UDVA^[17]. Likewise, Carones^[18] found that patients with pre-existing corneal astigmatism of 1.5 D can achieve good UNVA after implantation of this ERV IOL^[18]. Besides this, the use of femtosecond-laser technology for the cataract procedure is another factor that may have contributed to the excellent results. It should be considered that a capsulotomy created with a femtosecond laser is associated with less IOL tilt and

therefore better IOL optical performance^[19].

The incidence of photic phenomena in our series was low, with only 2 patients (3.64%) reporting halos inducing some level of visual discomfort, and one patient (2.50%) complaining of glare during night driving. No moderate or severe photic phenomena were reported by the patients. This rate of photic phenomena is comparable to that found in the multicenter CONCERTO study evaluating the same ERV IOL^[8] and is markedly lower than those reported by other authors evaluating a great variety of multifocal IOLs^[15-16]. Besides the low incidence of photic phenomena, the level of visual quality achieved with the ERV IOL in our sample was high, with levels of contrast sensitivity comparable to those obtained with a monofocal IOL, as in the work of Pedrotti *et al.*^[9]. In conclusion, our preliminary results at 3mo after implantation of the ERV IOL Tecnis Symphony show that satisfactory far and intermediate vision as well as a functional near vision (40-45 cm) meeting the demands of daily activities can be achieved with this ERV IOL. The level of spectacle independence is high, with most of the patients not requiring spectacles for any activity. Likewise, this IOL provides a visual restoration at different distances with minimal incidence of photic phenomena and with no significant decrease in postoperative contrast sensitivity. The combination of FLACS with the implantation of the Tecnis Symphony IOL may be beneficial to ensure an optimized intracapsular centration and long-term stability of the IOL. FLACS with implantation of the ERV IOL TECNIS Symphony provides a successful visual restoration at far, intermediate distance and a functional-range near vision acuity which can meet the demands of daily living activities, with minimal level of disturbing photic phenomena, and high rates of spectacle independence and patient satisfaction.

REFERENCES

- 1 Heemraz BS, Lee CN, Hysi PG, Jones CA, Hammond CJ, Mahroo OA. Changes in quality of life shortly after routine cataract surgery. *Canadian Journal of Ophthalmology* 2016;51(4):282-287
- 2 Alio JL, Plaza-Puche AB, Fernández-Buenaga R, Pikkell J, Maldonado M. Multifocal intraocular lenses: an overview. *Surv Ophthalmol* 2017;62(5):611-634
- 3 Braga-Mele R, Chang D, Dewey S, Foster G, Henderson BA, Hill W, Hoffman R, Little B, Mamalis N, Oetting T, Serafino D, Talley-Rostov A, Vasavada A, Yoo S. Multifocal intraocular lenses: relative indications and contraindications for implantation. *J Cataract Refract Surg* 2014;40(2):313-322
- 4 Gatinel D, Loicq J. Clinically relevant optical properties of bifocal, trifocal, and extended depth of focus intraocular lenses. *J Refract Surg* 2016;32(4):273-280
- 5 Domínguez-Vicent A, Esteve-Taboada JJ, del Águila-Carrasco AJ, Ferrer-Blasco T, Montés-Micó R. In vitro optical quality comparison between the Mini WELL Ready progressive multifocal and the TECNIS Symphony. *Graefes Arch Clin Exp Ophthalmol* 2016;254(7):1387-1397
- 6 Esteve-Taboada JJ, Domínguez-Vicent A, del Águila-Carrasco AJ, Ferrer-Blasco T, Montés-Micó R. Effect of large apertures on the optical quality of three multifocal lenses. *J Refract Surg* 2015;31(10):666-676

- 7 Kaymak H, Höhn F, Breyer D, Hagen P, Klabe K, Gerl R, Mueller M, Auffarth G, Gerl M, Kretz F. Functional results 3 months after implantation of an “extended range of vision” intraocular lens. *Klin Monbl Augenheilkd* 2016;233(8):923–927
- 8 Cochener B. Clinical outcomes of a new extended range of vision intraocular lens; International Multicenter Concerto Study. *J Cataract Refract Surg* 2016;42(9):1268–1275
- 9 Pedrotti E, Bruni E, Bonacci E, Badalamenti R, Mastropasqua R, Marchini G. Comparative analysis of the clinical outcomes with a monofocal and an extended range of vision intraocular lens. *J Refract Surg* 2016;32(7):436–442
- 10 Hamid A, Sokwala A. A more natural way of seeing: visual performance of three presbyopia correcting intraocular lenses. *Open Journal of Ophthalmology* 2016;6(3):176–183
- 11 Auffarth GU, Rabsilber TM, Kohnen T, Holzer MP. Design und optische prinzipien von multifokallinsen. *Der Ophthalmologe* 2008;105(6):522–526
- 12 Vega F, Alba–Bueno F, Millán MS, Varón C, Gil MA, Buil JA. Halo and through – focus performance of four diffractive multifocal intraocular lenses. *Invest Ophthalmol Vis Sci* 2015;56(6):3967–3975
- 13 De Vries NE, Webers CA, Touwslager WR, Bauer NJ, de Brabander J, Berendschot TT, Nuijts RM. Dissatisfaction after implantation of multifocal intraocular lenses. *J Cataract Refract Surg* 2011;37(5):859–865
- 14 Kamiya K, Hayashi K, Shimizu K, Negishi K, Sato M, Bissen–Miyajima H, Survey Working Group of the Japanese Society of Cataract and Refractive Surgery. Multifocal intraocular lens explantation; a case series of 50 eyes. *Am J Ophthalmol* 2015;159(1):202
- 15 Mendicute J, Kapp A, Lévy P, Krommes G, Arias – Puente A, Tomalla M, Barraquer E, Rozot P, Bouchut P. Evaluation of visual outcomes and patient satisfaction after implantation of a diffractive trifocal intraocular lens. *J Cataract Refract Surg* 2016;42(2):203–210
- 16 Law EM, Aggarwal RK, Kasaby H. Clinical outcomes with a new trifocal intraocular lens. *Eur J Ophthalmol* 2014;24(4):501–508
- 17 Cochener B. Tecnis symfony intraocular lens with a “sweet spot” for tolerance to postoperative residual refractive errors. *Open Journal of Ophthalmology* 2017;7(1):14–20
- 18 Carones F. Residual astigmatism threshold and patient satisfaction with bifocal, trifocal and extended range of vision intraocular lenses (IOLs). *Open Journal of Ophthalmology* 2017;7(1):1–7
- 19 Szigeti A, Kránitz K, Takacs AI, Miháltz K, Knorz MC, Nagy ZZ. Comparison of Long–term visual outcome and IOL position with a single–optic accommodating IOL after 5.5 – or 6.0 – mm femtosecond laser capsulotomy. *J Refract Surg* 2012;28(9):609–613