

# Visual outcomes of a new implantable Phakic contact lens in patients with stable keratoconus

Farideh Doroodgar<sup>1</sup>, Feizollah Niazi<sup>2</sup>, Sana Niazi<sup>2</sup>, Azad Sanginabadi<sup>3</sup>, Cyrus Alinia<sup>4</sup>

引用: Doroodgar F, Niazi F, Niazi S, Sanginabadi A, Alinia C. 稳定型圆锥角膜患者植入新型 Phakic 角膜接触镜的视觉效果分析. 国际眼科杂志 2019;19(7):1089-1094

<sup>1</sup>Negah Specialty Ophthalmic Research Center, Shahid Beheshti University of Medical Science, Tehran 1544914599, Iran

<sup>2</sup>Shahid Beheshti University of Medical Sciences and Health Services, Chamran Highway, Daneshjoo Street, Tehran 1544914599, Iran

<sup>3</sup>Iran University of Medical Sciences and Health Services, Tehran 1544914599, Iran

<sup>4</sup>Department of Public Health, School of Public Health, Urmia University of Medical Sciences, Urmia, West Azerbaijan 1544914599, Iran

**Correspondence to:** Azad Sanginabadi. Iran University of Medical Sciences and Health Services, Tehran 1544914599, Iran. [Sanginabadiasad@yahoo.com](mailto:Sanginabadiasad@yahoo.com)

Received: 2018-09-28 Accepted: 2019-03-08

## 稳定型圆锥角膜患者植入新型 Phakic 角膜接触镜的视觉效果分析

Farideh Doroodgar<sup>1</sup>, Feizollah Niazi<sup>2</sup>, Sana Niazi<sup>2</sup>, Azad Sanginabadi<sup>3</sup>, Cyrus Alinia<sup>4</sup>

(作者单位:<sup>1</sup>1544914599 伊朗德黑兰 Shahid Beheshti 医科大学, Negah 眼科研究中心;<sup>2</sup>1544914599 伊朗德黑兰, Shahid Beheshti 医学科学与卫生服务大学;<sup>3</sup>1544914599 伊朗德黑兰, 伊朗医学与健康服务大学;<sup>4</sup>1544914599 伊朗西阿塞拜疆, Urmia 医科大学公共卫生系)

通讯作者: Azad Sanginabadi. [Sanginabadiasad@yahoo.com](mailto:Sanginabadiasad@yahoo.com)

### 摘要

**目的:** 评估可植入式 Phakic 角膜接触镜治疗稳定型圆锥角膜患者的疗效、安全性、稳定性和可预测性。

**方法:** 共 14 例患者采用植入式 Phakic 角膜接触镜 (IPCL) 矫正屈光不正, 测量了未矫正视力、最佳矫正视力、离焦曲线、对比敏感度、屈光度及可能的副作用。评估结果超过 6mo。

**结果:** 平均等效球镜度 (SE) 和散光在术后 6mo 末次检查时由术前  $-6.94 \pm 2.79$  DS 和  $-4.24 \pm 1.42$  DC 分别变为术后  $-0.23 \pm 0.43$  DS 和  $-1.05 \pm 0.49$  DC。术前平均 Snellen 视力为  $0.18 \pm 0.10$ 。6mo 内未矫正视力和最佳矫正视力平均值分别为  $0.13 \pm 0.10$  和  $0.05 \pm 0.15$ 。平均安全指数为 1.11。所有眼视力均无降低, 其中 22 眼视力提高超过 1 行。20 眼 (71.4%) 屈光度在 0.50 D 以内, 27 眼 (96.42%) 在  $\pm 1.00$  D 以内。术后 1wk 至 6mo, 屈光度变化为  $-0.23 \pm 0.43$  (范围:  $-1.00$  至  $+0.75$ )。6mo 内角膜内

皮细胞 (ECL) 丢失率小于 5%。术后 6mo 眼压 (IOP) 为  $11.32 \pm 2.28$  mmHg。

**结论:** Toric 植入式 Phakic 角膜接触镜在矫正与稳定圆锥角膜相关的近视和近视散光方面具有有效性、安全性和可预测性。

**关键词:** 圆锥角膜; 植入式 Phakic 角膜接触镜; 视力

### Abstract

• **AIM:** To assess the efficacy, safety, stability and predictability of an implantable Phakic contact lens in patients with stable keratoconus.

• **METHODS:** The uncorrected and the best corrected visual acuity, defocus curve, contrast sensitivity, refraction and possible side effects were measured in 14 patients after utilizing implantable Phakic contact lens (IPCL) to correct refractive errors. The result was assessed for more than 6mo.

• **RESULTS:** The mean preoperative spherical equivalent (SE) and astigmatism got changed from  $-6.94 \pm 2.79$  DS and  $-4.24 \pm 1.42$  DC to  $-0.23 \pm 0.43$  DS and  $-1.05 \pm 0.49$  DC, respectively at the last examination after 6mo. Before the preoperative the mean Snellen visual acuity was  $0.18 \pm 0.10$  LogMAR. The mean uncorrected and the best corrected visual acuity got changed to  $0.13 \pm 0.10$  LogMAR and  $0.05 \pm 0.15$  LogMAR, respectively in 6mo. The mean safety indices were 1.11. There was no loss of visual acuity in any of the eyes and 22 eyes (78.5%) gained one or more lines. Twenty eyes (71.4%) were within 0.50 D and 27 (96.42%) were within  $\pm 1.00$  D of the desired spherical equivalent refraction. There was a change in manifest refraction of  $-0.23 \pm 0.43$  (range from  $-1.00$  to  $+0.75$ ) from the first week of surgery to 6mo. Contrast sensitivity got improvement value at 3 per degree ( $P < 0.005$ ) after Toric IPCL implantation. The total 6mo corneal endothelial cell loss (ECL) was less than 5%. Intraocular pressure (IOP) was  $11.32 \pm 2.28$  mmHg after 6mo.

• **CONCLUSION:** The clinical consequences of the present study exhibit the efficacy, safety, and predictability of Toric implantable Phakic contact lens in the correction of myopia and myopic astigmatism related with stable keratoconus.

• **KEYWORDS:** keratoconus; implantable Phakic contact lens; visual acuity

DOI:10.3980/j.issn.1672-5123.2019.7.01

**Citation:** Doroodgar F, Niazi F, Niazi S, Sanginabadi A, Alinia C. Visual outcomes of a new implantable Phakic contact lens in patients with stable keratoconus. *Guoji Yanke Zazhi (Int Eye Sci)* 2019;19(7):1089-1094

**INTRODUCTION**

Keratoconus is a non-inflammatory, progressive ectatic disorder related to irregular astigmatism and decrease corneal thickness<sup>[1]</sup>. Treatment of keratoconus relies upon the condition of the cornea ectasia and the degree of irregular astigmatism. In view of the biomechanical adjustments of the corneal collagen compound, it has been recommended to utilize collagen cross-linking (CXL) to end the progression of keratoconus, when progress is approved<sup>[2]</sup>. Soft contact lenses or glasses can be utilized in mild type and when the astigmatism increments and corneal distortion occurs, rigid gas permeable (RGP) lenses, intra-stromal ring sections or keratoplasty may be utilized to enhance the visual acuity<sup>[2-4]</sup>. The results of other treatment strategies like laser *in situ* keratomileusis (LASIK) appear to be capricious, as they may outcome in the further diminishing of the cornea and remainder refractive error<sup>[5-6]</sup>. Numerous studies<sup>[7-10]</sup> have utilized the Phakic intraocular lenses (pIOLs) containing posterior chamber pIOLs to rectify refractive errors related to keratoconus, proposing a promising option. At present, it is one of the prosperous pIOLs, the implantable Phakic contact lens (Toric IPCL, Care Group India). The IPCL is similar to the soft contact lens, single piece posterior chamber Phakic IOL, which can be inserted into eye through 2.8 mm incision. Sulcus placed posterior chamber Phakic intraocular lens (IOL) which is made from reinforced hybrid acrylic material. Another type of lens that has a longer history is the implantable collamer lens (ICL) (STAAR Surgical Inc.). However, the potential reactions of this method remain to be explored. This examination expected to evaluate the efficacy, safety, stability and predictability of the Toric implantable Phakic contact lens in patients with stable keratoconus amid a 6mo follow up. As far as we know, this is the first study to examine the behavior of this posterior Phakic IOL model.

**SUBJECTS AND METHODS**

This prospective study was conducted the clinical outcomes of the implantable Phakic contact lens to correct refractive error were researched in 28 keratoconic eyes of 14 consecutive patients (Table 1).

Patients who were over 23 years old were viewed as qualified to experience implantation of the Toric IPCL, intolerant to spectacles and contact lenses, had a steady refraction for at least one year and were happy with their vision when wearing glasses. Patients had no other general pathology and ocular and no more than stage III keratoconus pursuant to the Amsler-Krumeich classification<sup>[11]</sup>.

**Inclusion Criteria** Accompanied corrected distance visual acuity (CDVA) of +0.4 Logarithm of the minimum angle of resolution (LogMAR) of 5/10 decimal or better, clear cornea, intraocular pressure (IOP) <20 mmHg, normal ACD of at least 3 mm to the endothelium, a pupil diameter of less than 6.25 mm, width of angle greater than 30° and a pre-surgery endothelial cell count in association with age. Contact lens utilization was ceased for at least more than 3wk for RGP and one week for soft contact lens prior to any intervention.

**Table 1 Preoperative and postoperative demographic and clinical data of patients underwent Toric IPCL**

Parameters	Outcomes
Refractive surgery, <i>n</i> (eyes)	14 (28)
Mean age ±SD	31.04±4.3
Range	23-36
Gender, <i>n</i> (%)	
M	18 (64%)
F	10 (35.7%)
Preoperative visual acuity(range)	
UCDVA	0.97±0.14 (0.7-1.2)
CDVA	0.18±0.10 (0.0-0.3)
Preoperative refractive error (spherical equivalent)	
Range (Mean±SD)	-3.50 - -16 (-6.94±2.79)
Postoperative visual acuity	
UCDVA	0.14±0.11
CDVA	0.05±0.16
Specular microscopy	
Preoperative	2398.04±112.15
Postoperative	2337.36±112.39

UCDVA; Uncorrect distance visual acuity; CDVA; Correct distance visual acuity.

**Exclusion Criteria** contained introduction of autoimmune diseases and other ophthalmic issues, with the exception of keratoconus, for example, corneal opacification or scar, cataract, uveitis, diabetic retinopathy, glaucoma, central endothelial cell count of less than 2000 cells/mm<sup>2</sup> by specular microscopy (SP-8800; Konan, Nishinomiya, Japan), focal corneal thickness of under 450 mm [estimated by optical pachymetry (Pentacam-HR, Oculus Optikgerate, Wetzlar, Germany)] and ACD less than 3 mm from the endothelium to the anterior capsule measured by Orbscan IIZ (Orbscan, Bausch and Lomb, Rochester, New York, USA).

**Implantable IPCL Insertion Procedure** In this examination, the current V2 IPCL configuration was implanted. When started with topical anesthesia, dilating specialists were directed. For the Toric IPCL implantation, the surgeon (FD) denoted the zero horizontal axis amid slitlamp examination while the patient was lying upright to avoid cyclotorsion. IPCL, unlike the ICL, does not require a specific set. IPCL cartridge needs a 2.8 mm incision, marked to ensure proper orientation in the eye as it unfolds, observe the IPCL for proper orientation in the cartridge, open the cartridge and injector fill the Cartridge with saline and HPMC, open the IPCL Container, gently hold the IPCL with McPherson Forceps near haptics, check the orientation of IPCL, Place the IPCL in the Cartridge, put the Cartridge in injector.

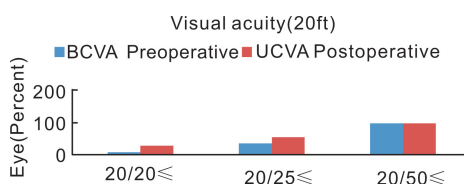
In a temporal approach, after injection of vasculosis, a small incision of the cornea was made at 2.8 mm, and the IPCL was injected through the incision into the anterior chamber and got slowly opened.

After injection of the Toric IPCL into the anterior chamber, the

**Table 2 Manifest refraction, the Toric implantable Phakic contact lens**

Preoperative				Postoperative after 1y			
Cylinder	n/N (%)	Sphere	n/N (%)	Cylinder	n/N (%)	Sphere	n/N (%)
≤ -1.50	0/28 (0)	≤ -3.00	8/28 (28)	≤ -1.50	24/28 (86)	≤ -3.00	28/28 (100)
≤ -3.50	11/28 (39)	≤ -5.00	16/28 (57)	≤ -3.50	28/28 (100)	≤ -5.00	28/28 (100)
≤ -5.00	21/28 (75)	≤ -10.00	27/28 (96)	≤ -5.00	28/28 (100)	≤ -10.00	28/28 (100)
≤ -7.00	27/28 (96)	≤ -12.00	28/28 (100)	≤ -7.00	28/28 (100)	≤ -12.00	28/28 (100)
≤ -8.00	28/28 (100)	≤ -18.00	28/28 (100)	≤ -8.00	28/28 (100)	≤ -18.00	28/28 (100)
Mean±SD	-4.24±1.45	Mean±SD	-4.89 ±2.55	Mean±SD	-1.05 (0.5)	Mean±SD	0.37±0.46

n; Number of subjects; N; Total subjects.



**Figure 1 A comparison of preoperative best corrected visual acuity and postoperative uncorrected distance visual acuity 6m after Toric IPCL.**

proper motion was accomplished with gentle posterior pressure and calm rotation of one or more clock hour. This move was rehased for each of the four footplates, situating them under the iris plane. In the event that any change of the Toric IPCL was fundamental, it was expert with a gentle movement contacting the IPCL at the intersection of the optic and haptic. Aspiration and irrigation of the viscoelastic materials were accomplished. An intraocular miotic (acetylcholine) was utilized to diminish the pupil size. The arrangement of the Toric IPCL was assessed by slitlamp examination at all visits postoperatively.

**Study Outcomes and Patients Follow-up** Postoperative examinations were directed at a consistent follow-up program (baseline and in 1, 2, 4 and 6mo). The primary results parameters for this examination were cycloplegic refractions and manifest, uncorrected distance visual acuity (UCDVA) and CDVA. We assessed the accompanying: anterior and posterior segments assessment with dilated fundus evaluation, pre- and postoperative inconveniences, endothelial cell count estimated on the central piece of the cornea by specular microscopy (SP - 8800, IOP with Goldman applanation tonometry and non-contact tonometer Topcon CT-1P. Vault height was estimated objectively with ultrasound bio-microscope (UBM, Sonomed, New York, USA) and subjectively (slit-lamp examination).

Contrast sensitivity test got accomplished under mesopic (3 cd/m<sup>2</sup>) and photopic (85 cd/m<sup>2</sup>) conditions utilizing the CVS1000 contrast sensitivity test (VectorVision, Greenville, SC). The tests were accomplished with the best glasses correction before the surgery and without correction after the surgery, utilizing a light level of 3 cd/m<sup>2</sup> after 10min of dark adaptation at a distance of 3 m. Testing was accomplished at 1, 3, 5, 6, 12 and 18 cycles for every degree (c/d). The defocus curve additionally gotten to assess the scope of utilitarian vision.

**Statistical Analysis** To statistically analyze the results, we utilized the SPSS programming (SPSS Statistics for Windows, V.23.0, 2013; IBM). The non-parametric Wilcoxon marked rank test was connected to decide the significant differences between the target outcomes before and after the implantation of Toric IPCL, for example, contrast sensitivity and the LogMAR visual acuity, defocus curve. Given that these variables had ordinary dispersion, we reported the mean and SD to them. Ordinary factors were accounted for as mean and SD, and we sat the middle if circulations were skewed. We considered 5% level to discover the statistically significant differences in our analysis.

**RESULTS**

**Patient Population** Table 1 illustrates patient’s demographics in summary. The mean spherical error was -4.89±3.96 D (range: -1.50 to -12.00 D), and the astigmatism was -4.24±1.42 D (range: -1.75 to -8.00 D). Toric IPCL was accomplished at the clinical investigational site from October 2017 to May 2018 in this group. Patients were followed up seven times after surgery at 1, 2, 4 and 6mo. All patients had a preoperative UCDVA worse than 20/40 with 95% having uncorrected acuity limited to counting of fingers. In 6mo, post-surgically UCDVA was better than or equal to pre-surgically CDVA in 85% (24/28) of eyes, and UCDVA was incremented by ≥ byrement, a 22 eyes (Table 2).

The preoperative CDVA and postoperative UCVA 6mo after Toric IPCL operation is compared in Figure 1. Six months after postoperative, 71.42% of eyes were within ± 0.50 D, and 96.42% were within ± 1.0 D of endeavored correction. At the end of the follow-up, the mean vault height was 603±54.33 (range: 510-701) μm, and the IOP was 11.32±2.28 mmHg.

**Safety LogMAR** CDVA was 0.06±0.11, 0.04±0.15, 0.05±0.15 and 0.05±0.15 in 1, 2, 4 and 6mo after surgery with the IPCL, respectively. We found a significant difference between preoperative CDVA IPCL and all other follow-up (P<0.05, Wilcoxon signed-rank test). The safety index (mean postoperative CDVA/mean preoperative CDVA) was 1.09, 1.15, 1.11 and 1.11 at 1, 2, 3 and 6mo after operation with the IPCL, respectively.

**Treatment Effectiveness** Uncorrected distance visual acuity 6mo after postoperative for the entire subjects was ≥20/20 in 46.42% of eyes and ≥ 20/40 in 100% of eyes. The uncorrected visual outcomes in this ‘all eyes’ group must be

interpreted in the context; only 50% of these eyes had CDVA of  $\geq 20/20$  at the baseline. 6mo after postoperative, UCDVA was equal to or better than preoperative CDVA in 78.57% (22/28) of eyes.

**Predictability of Manifest Refraction (attempted vs achieved)** The following outcomes are relied upon to give a more exact appraisal of refraction exactness than the postoperative mean refractive spherical equivalent (MRSE) results. Six months after postoperative, 71.42% of eyes were inside  $\pm 0.50$  D, and 96.42% were inside  $\pm 1.0$  D of endeavored correction. The differences in SE, cylinder and sphere were statistically significant between preoperative and 1mo postoperatively. These differences remained stable for 6mo and 2, 4 and 6mo after operation (Figure 2).

Even though emmetropia was the targeted postoperative refraction in all patients, small hyperopic and myopic deviations were found after IPCL implantation.

**Defocus Curve** Figure 3 demonstrates the LogMAR visual acuity under defocus curve of +2, +1, 0, -1, -2, and -3 D in postoperative and preoperative periods in a non-cycloplegic situation. The contrasts between the estimations of binocular distance corrected defocus bend in the examination showed significant differences in LogMAR visual acuity at the defocus bend levels of +1, 0 and -1 D, yet no significant differences were seen at the defocus bend levels of +2, -2, and -3 D.

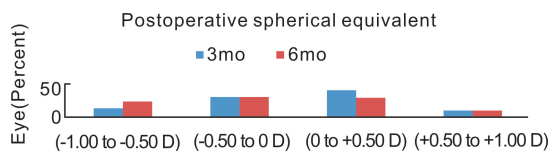
**Contrast Sensitivity** Figure 4 demonstrates the mesopic contrast sensitivity outcomes, which exhibit no loss of contrast at any spatial frequency and a measurably noteworthy change conversely an incentive at 3 and 1.5 for each degree. Furthermore, photopic contrast sensitivity exhibited a critical change, interestingly, an incentive at 3 for each degree incomparable mesopic conditions.

**Vaulting the IPCL** Figure 5 shows the adjustment in vault between successive estimations in various times. Objective and subjective vaults were steady after IPCL implantation in 2mo.

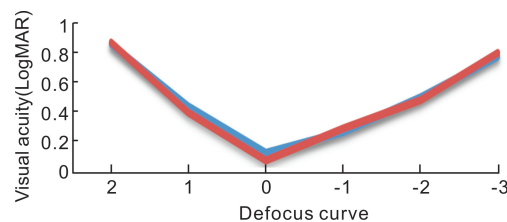
**DISCUSSION**

This examination exhibited the visual results of Toric IPCL implantation in stable keratoconus with a 6-month follow-up. This examination assessed efficacy, predictability, safety and stability of this system in patients with stable keratoconus. These discoveries in conjunction with excellent outcomes for refractive signs that influence the quality of life 12 empower Toric ICL to be the primary suggested Phakic IOL approved in the USA for patients younger than 60 years<sup>[13]</sup>. Posterior chamber Phakic IOLs can be viewed as a safe procedure to treat refractive errors in keratoconic patients with better restorative results, due to position of the IOL behind the iris<sup>[12,14-15]</sup>.

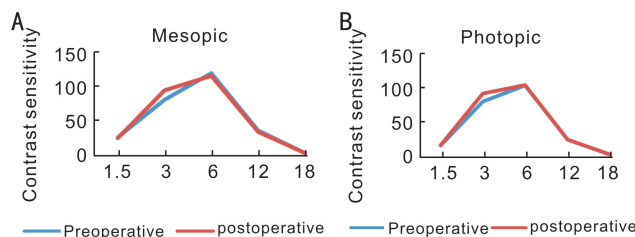
Toric IPCL is accessible with spherical powers from +15.0 to -30.0 D for adjustment of refractive error and an astigmatism power to 10.00 D that wide range is viewed as an awesome benefit at show. The visual acuity test is bitten by bit turning into the gold standard level for the appraisal of vision, giving



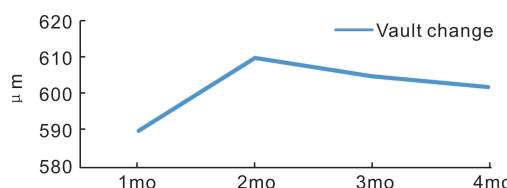
**Figure 2 Postoperative spherical equivalent during follow-up (3 and 6mo).**



**Figure 3 LogMAR (Logarithm of the minimum angle of resolution) visual acuity curve of +2, +1, 0, -1, -2, and -3 D in a non-cycloplegic condition in the preoperative and postoperative.**



**Figure 4 A: contrast sensitivity under mesopic illumination (3 cd/m<sup>2</sup>) (statistically significantly different at a level of 0.05); B: contrast sensitivity under photopic illumination (85 cd/m<sup>2</sup>).**



**Figure 5 Vault change during follow-up.**

exclusively a confined amount of information under artificial conditions (Table 2). Contrast sensitivity exhibited an assortment of visual performance information under real conditions. This inspired us to gain ground around there of medicine. To the best of our knowledge (Web of Science and PubMed), this is the first investigation of Toric IPCL in patients with stable keratoconus that focuses on visual function (contrast sensitivity, visual acuity, defocus curve and refraction). No decrease in contrast sensitivity was seen at any spatial frequency. Photopic and mesopic contrast sensitivity demonstrated a statistically significant betterment in value at 3 per degree. There is no totally consummate test for contrast sensitivity<sup>[16]</sup>. We picked this strategy, since it is easy to understand, time-saving and accessible, and it diminishes the examiners' mistake. Notwithstanding, in spite of the considerable number of contemplations, the test result was impacted by numerous different components that enhanced contrast sensitivity, other than refractive correction of auxiliary system, one-time CXL with riboflavin and UVA, enhance aberrations and contrast sensitivity<sup>[17-18]</sup>. We had three patients with pre-surgery astigmatism more noteworthy than

six (Table 2). A few subjects of s would do well to resilience to myopic defocus curve ( $-1$ ), which appears to be identified with the remaining refraction in these subjects.

The chief possibly complications after IPCL and ICL implantation are cataract formation, 15 intense increments in IOP and night vision disorder<sup>[19]</sup>. Anterior segment anatomy assessment with new propelled advances and consideration of the surgeon to notice signs before operation permits the choice of the best possible size and diminishes likely complications<sup>[20]</sup>. We believe that before operation, patients with shallower ACD and older patients and larger White to White ought to be made mindful of the likelihood of complication after this technique<sup>[21]</sup>. Cataract surgery in keratoconus prompts resurgence of visual acuity, particularly by various means, for example, Toric multifocal lenses<sup>[22]</sup>. Conceivable hazard factors for night vision unsettling influences after ICL are White to White measurement of the cornea, distinction between the optic zone width and the mesopic pupil size, corona and toricity of the ICL and glare<sup>[23]</sup> but fortunately, the new lenses make it possible to order lenses with larger optics, which minimizes the possibility of light transmission and glare in large pupils. The pre-surgery and postoperative are comprised of a complete ophthalmic examination.

The IPCL implantation is a plausible manage with less infringement in visual function since it doesn't change the curvature ratios between the front and backcorneas<sup>[24]</sup>. In this regard, albeit a few methodologies may demonstrate slightly better results for UCVA and refractive consistency, Toric IPCL implantation indicated dependable outcomes like those of bioptics. A single-step method with IPCL implantation may maintain a strategic distance from the potential complications for elective second surgeries. A pattern toward reduction of corneal transplantation for keratoconus looking at two changed periods was accounted for by some studies<sup>[25]</sup>. It is a guarantee that appears to be identified with contemporary administration modalities in prior recognition of movement and medications of keratoconus.

The clinical results of the present examination exhibit the efficacy, safety and predictability of Toric implantable Phakic contact lens in patients with stable keratoconus. One of the limitations of this study was a small number of patients and a short follow-up period that required further studies and a large number of patients in future studies.

## REFERENCES

- 1 Alió JL. What is keratoconus? A new approach to a not so rare disease. *Keratoconus* 2016;3-5
- 2 Mazzotta C, Traversi C, Baiocchi S, Bagaglia S, Caporossi O, Villano A, Caporossi A. Corneal collagen cross-linking with riboflavin and ultraviolet a light for pediatric keratoconus; ten-year results. *Cornea* 2018;37(5):560-566
- 3 Chen HT, Liu Y, Niu GZ, Ma JX. Excimer laser versus phakic intraocular lenses for myopia and astigmatism: a meta-analysis of randomized controlled trials. *Eye Contact Lens* 2018;44(3):137-143

- 4 Li XH, Yang HY, Rabinowitz YS. Longitudinal study of keratoconus progression. *Exp Eye Res* 2007;85(4):502-507
- 5 Mastropasqua L, Nubile M, Salgari N, Mastropasqua R. Femtosecond laser-assisted stromal lenticule addition keratoplasty for the treatment of advanced keratoconus: a preliminary study. *J Refract Surg* 2018;34(1):36-44
- 6 Davis LJ, Schechtman KB, Wilson BS, Rosenstiel CE, Riley CH, Libassi DP, Gundel RE, Rosenberg L, Gordon MO, Zadnik K. Longitudinal changes in visual acuity in keratoconus. *Invest Ophthalmol Vis Sci* 2006;47(2):489
- 7 Ramin S, Sangin Abadi A, Doroodgar F, Esmaeili M, Niazi F, Niazi S, Alinia C, Golestani Y, Taj Abadi R. Comparison of visual, refractive and aberration measurements of INTACS versus toric ICL lens implantation; a four-year follow-up. *Med Hypothesis Discov Innov Ophthalmol* 2018;7(1):32-39
- 8 Doroodgar F, Niazi F, Sanginabadi A, Niazi S, Baradaran-Rafii A, Alinia C, Azargashb E, Ghoreishi M. Comparative analysis of the visual performance after implantation of the toric implantable collamer lens in stable keratoconus: a 4-year follow-up after sequential procedure (CXL +TICL implantation). *BMJ Open Ophthalmol* 2017;2(1):e000090
- 9 Li DK, Li M, Liu ZK, Ling JJ, Ke F, Li F, Gu HM, Shao J, Yu JQ. Therapeutic effectiveness of toric implantable collamer lens in treating ultrahigh myopic astigmatism. *Biomedical Research* 2018;29(3)
- 10 Miao HM, Chen X, Tian M, Chen YJ, Wang XY, Zhou XT. Refractive outcomes and optical quality after implantation of posterior chamber phakic implantable collamer lens with a central hole (ICL V4c). *BMC Ophthalmol* 2018;18(1):141
- 11 Kamiya K, Ishii R, Shimizu K, Igarashi A. Evaluation of corneal elevation, pachymetry and keratometry in keratoconic eyes with respect to the stage of Amsler-Krumeich classification. *Br J Ophthalmol* 2014;98(4):459-463
- 12 Shafik Shaheen M, El-Kateb M, El-Samadouny MA, Zaghoul H. Evaluation of a toric implantable collamer lens after corneal collagen crosslinking in treatment of early-stage keratoconus: 3-year follow-up. *Cornea* 2014;33(5):475-480
- 13 Sanders DR, Peco M. United States Food and Drug Administration clinical trial of the implantable collamer lens (ICL) for moderate to high myopia. *Ophthalmology* 2004;111(9):1683-1692
- 14 Lee H, Kang DSY, Choi JY, Ha BJ, Kim EK, Seo KY, Kim TI. Analysis of pre-operative factors affecting range of optimal vaulting after implantation of 12.6-mm V4c implantable collamer lens in myopic eyes. *BMC Ophthalmol* 2018;18(1):163
- 15 Lovisolo CF, Zaldivar R. Complications of posterior chamber phakic IOLs. *Cham: Springer International Publishing* 2018;289-309
- 16 Maniglia M, Thurman SM, Seitz AR, Davey PG. Effect of varying levels of glare on contrast sensitivity measurements of young healthy individuals under photopic and mesopic vision. *Front Psychol* 2018;9:899
- 17 Malta JBNS, Kaz Soong H, Moscovici BK, Campos M. Two-year follow-up of corneal cross-linking and refractive surface ablation in patients with asymmetric corneal topography. *Br J Ophthalmol* 2019;103(1):137-142
- 18 Shafik Shaheen M, Lolah MM, Piñero DP. The 7-year outcomes of epithelium-off corneal cross-linking in progressive keratoconus. *J Refract Surg* 2018;34(3):181-186
- 19 Kaur M, Titiyal JS, Falera R, Sinha R, Sharma N. Indications for explant of implantable collamer lens. *Eye (Lond)* 2018;32(4):838-840

20 Zhang X, Chen X, Wang XY, Yuan F, Zhou XT. Analysis of intraocular positions of posterior implantable collamer lens by full-scale ultrasound biomicroscopy. *BMC Ophthalmol* 2018;18(1):114

21 Ghoreishi M, Abdi-Shahshahani M, Peyman A, Pourazizi M. A model for predicting sulcus-to-sulcus diameter in posterior chamber phakic intraocular lens candidates: correlation between ocular biometric parameters. *Int Ophthalmol* 2019;39(3):661-666

22 Farideh D, Azad S, Feizollah N, Sana N, Cyrus A, Mohammad G, Alireza BR. Clinical outcomes of new toric trifocal diffractive intraocular lens in patients with cataract and stable keratoconus: Six months follow-

up. *Medicine (Baltimore)* 2017;96(12):e6340

23 Lim DH, Lyu IJ, Choi SH, Chung ES, Chung TY. Risk factors associated with night vision disturbances after phakic intraocular lens implantation. *Am J Ophthalmol* 2014;157(1):135-141.e1

24 Kamiya K, Shimizu K, Igarashi A, Kitazawa Y, Kojima T, Nakamura T, Oka Y, Matsumoto R. Posterior chamber phakic intraocular lens implantation: comparative, multicentre study in 351 eyes with low-to-moderate or high myopia. *Br J Ophthalmol* 2018;102(2):177-181

25 Galvis V, Tello A, Prada AM, Rangel CM. Changing trends in keratoconus management. *Cornea* 2016;35(3):e6-e7