

# Efficacy of intravitreal injection of Aflibercept vs Ranibizumab in the treatment of diabetic retinopathy

Chang Huang<sup>1</sup>, Guo-Guo Yi<sup>2</sup>, Min Fu<sup>3</sup>

引用:黄畅,易果果,符敏. 玻璃体腔内注射阿柏西普或雷珠单抗治疗糖尿病视网膜病变疗效的 Meta 分析. 国际眼科杂志 2021;21(5):757-763

<sup>1</sup>The Second Clinical School, Southern Medical University, Guangzhou 510080, Guangdong Province, China

<sup>2</sup>Department of Ophthalmology, the Six Affiliated Hospital of Sun Yat-sen University, Guangzhou 510630, Guangdong Province, China

<sup>3</sup>Department of Ophthalmology, Zhujiang Hospital, Southern Medical University, Guangzhou 510220, Guangdong Province, China

**Correspondence to:** Guo - Guo Yi. Department of Ophthalmology, the Six Affiliated Hospital of Sun Yat-sen University, Guangzhou 510630, Guangdong Province, China. [yigg@mail.sysu.edu.cn](mailto:yigg@mail.sysu.edu.cn); Min Fu. Department of Ophthalmology, Zhujiang Hospital of Southern Medical University, Guangzhou 510220, Guangdong Province, China. [min\\_fu1212@163.com](mailto:min_fu1212@163.com)

Received: 2020-04-01 Accepted: 2021-04-09

## 玻璃体腔内注射阿柏西普或雷珠单抗治疗糖尿病视网膜病变疗效的 Meta 分析

黄畅<sup>1</sup>, 易果果<sup>2</sup>, 符敏<sup>3</sup>

(作者单位:<sup>1</sup>510080 中国广东省广州市,南方医科大学第二临床医学院;<sup>2</sup>510630 中国广东省广州市,中山大学附属第六医院眼科;<sup>3</sup>510220 中国广东省广州市,南方医科大学珠江医院眼科)

作者简介:黄畅,毕业于南方医科大学第二临床医学院,本科,研究方向:视网膜视神经疾病。

通讯作者:易果果,毕业于南方医科大学,博士,医师,研究方向:眼表疾病与糖尿病相关眼病. [yigg@mail.sysu.edu.cn](mailto:yigg@mail.sysu.edu.cn); 符敏,毕业于中南大学,硕士,副主任医师,研究方向:视网膜病. [min\\_fu1212@163.com](mailto:min_fu1212@163.com)

### 摘要

**目的:**采用 Meta 分析系统评估玻璃体腔内注射阿柏西普或雷珠单抗治疗糖尿病视网膜病变(DR)的疗效。

**方法:**使用 PubMed、MEDLINE、Web of Science、Cochrane、Nature Series、ScienceDirect、ESI 等数据库进行数据检索。共纳入 10 项研究行玻璃体腔内注射阿柏西普或雷珠单抗治疗,1240 例糖尿病性视网膜病变(DR)患者。使用 RevMan 5.3 进行 Meta 分析。

**结果:**合并结果显示 IVA 组(IVA,玻璃体腔内注射阿柏西普)黄斑中心厚度(CMT)显著降低( $P < 0.00001$ );与 IVR

组(IVR,玻璃体内注射雷珠单抗)相比,最佳矫正视力(BCVA)和视力(VA)没有明显改善。

**结论:**研究表明 IVA 和 IVR 对治疗 DR 均有成效。但阿柏西普有利于改善 CMT,而雷珠单抗更有利于提高 BCVA 或 VA。

**关键词:**阿柏西普;糖尿病视网膜病变;疗效;Meta 分析;雷珠单抗

### Abstract

• **AIM:** To systematically assess the effect of intravitreal injection of Aflibercept or Ranibizumab in the treatment of diabetic retinopathy (DR) by using Meta-analysis.

• **METHODS:** PubMed, MEDLINE, Web of Science, Cochrane, Nature Series, ScienceDirect, and ESI Databases were searched until May 2019. Ten studies included a total of 1 240 participants with DR had been administered in the Meta-analysis. Aflibercept or Ranibizumab *via* intravitreal injection. After selecting useful information, we used RevMan 5.3 to further analysis. Systematic review and Meta-analysis were used to design.

• **RESULTS:** The pooled results showed that central macular thickness (CMT) was significantly reduced ( $P < 0.00001$ ) in the intravitreal Aflibercept group (IVA); compared with the intravitreal Ranibizumab group (IVR), which did not greatly improve best corrected visual acuity (BCVA) and visual acuity (VA).

• **CONCLUSION:** This Meta-analysis suggests that both IVA and IVR are effective in the treatment of DR patients. Specifically, Aflibercept shows better improvements in CMT, while Ranibizumab is beneficial in increasing BCVA or VA.

• **KEYWORDS:** Aflibercept; diabetic retinopathy; efficacy; Meta-analysis; Ranibizumab

DOI:10.3980/j.issn.1672-5123.2021.5.03

**Citation:** Huang C, Yi GG, Fu M. Efficacy of intravitreal injection of Aflibercept vs Ranibizumab in the treatment of diabetic retinopathy. *Guoji Yanke Zazhi (Int Eye Sci)* 2021;21(5):757-763

### INTRODUCTION

Due to the rapid changes in lifestyle, there is great concern that diabetes could become an epidemic<sup>[1]</sup>. Diabetic retinopathy (DR) are some of the main causes of blindness in the developed countries, which characteristic of microaneurysm, thickening of basement membrane and cell loss, these could eventually lead to blindness<sup>[2]</sup>. Thus far the

most commonly used treatment option for DR is laser therapy<sup>[3]</sup>. However, photocoagulation has several limitations; one adverse impact is that laser treatment may affect peripheral vision and consequently cause a substantial decrease in night vision<sup>[4]</sup>. Laser can delay the progress of the disease, can't improve your vision, and a negative impact on peripheral vision, therefore must develop new treatments and drugs. It should be noted that VEGF plays an important role in its pathogenesis<sup>[5]</sup>. That is, long-term vasodilation can lead to changes in microaneurysms and vascular structures, which may cause luminal stenosis, haemodynamic changes, and the formation of neovascularization. Additionally, VEGF plays an important role in stimulating neovascularization<sup>[6]</sup>. Bleeding from new blood vessels can destroy the integrity of the vitreous, causing dissociative retinal detachment and impairing vision<sup>[7]</sup>. VEGF expression is triggered by hypoxia, and in proliferative diabetic retinopathy (PDR) which is expressed in vitreous and preretinal new vessels<sup>[8]</sup>. Therefore, it is necessary to effectively inhibit VEGF. Scientists are working to develop drugs that inhibit VEGF. In clinical trials, ranizumab and aflibercept were successively marketed.

Ranibizumab (Lucentis, Genentech/Roche) is designed to treat DR by manipulating the structure of a full-length monoclonal antibody (mAb) A.4.6.1 directed against human VEGF-A<sup>[9]</sup>. The fragment antigen binding (Fab) fragment of A.4.6.1 is referred to as Fab-12<sup>[10]</sup>. Fab-12 has been widely used in DR, DME, retinal vein occlusion (RVO) and AMD<sup>[11]</sup>. To some extent, this therapeutic has a few limitations in ophthalmic treatment<sup>[12]</sup>. In addition, Fab-12 has systematic drawbacks in some clinical studies, such as hypertension, proteinuria, inhibition of bone growth and infertility<sup>[13]</sup>. Aflibercept is a fusion protein formed by the recombination of the extracellular region of human VEGF receptor-1 and 2, which includes the human immunoglobulin Fc segment<sup>[14]</sup>. Intravitreal Aflibercept can improve vision in eyes with DME or DR<sup>[15]</sup>, but there are fewer reports on Aflibercept than Ranibizumab. There are no concrete reports of endophthalmitis, or events suggestive of endophthalmitis<sup>[16]</sup>. Clinical studies have shown that the two drugs have different anti-VEGF mechanisms and have significant efficacy in patients with DR<sup>[17]</sup>. The purpose of this paper is to compare the clinical efficacy of ranibizumab and Aflibercept according to BCVA, VA and CMT, and to provide evidence-based basis for individualized treatment of DR.

## SUBJECTS AND METHODS

**Data Source and Search Strategy** The Meta-analysis was designed according to the Preferred Reporting Items for Systematic Reviews and Meta-Analyses (PRISMA) statement<sup>[18]</sup>. MEDLINE, Web of Science, PubMed, Cochrane, Nature Series, ScienceDirect, and ESI Databases were searched for articles published until May 2019 combining the following terms [ (“Ziv-Aflibercept” or “Aflibercept” and “DR” or “Diabetes retinopathy” or “Diabetic retinopathy”) and “Ranibizumab” and “Randomized”]. No language restrictions were applied.

**Study Selection** The study included 1240 patients (age 38 to 58) with type 2 diabetes. They all came from different countries, including Egypt, Japan, England and the United States. They were published between two and three years ago. The best corrected visual acuity (BCVA), visual acuity (VA) and central macular thickness (CMT) were analyzed.

**Data Extraction** Measurement information, year of publication, number of treated and control eye patients, age, sex, country, and type of diabetes were collected from each study and entered into RevMan 5.3. Extractive results included efficacy after treatment with either aflibercept or ranizumab. There are three aspects of comparison, BCVA, VA and CMT.

**Quality Assessment** An assessment scale was designed with 11 items based on the Newcastle Ottawa Scale (NOS)<sup>[19]</sup>. “Yes” or “no” or “not clear” the answer should be “yes” or “no” or “not clear”, and if the answer is “yes”, then there will be a score of “1”; Otherwise, the item will score “0”. Huang C evaluates the quality of the included studies, and studies with scores above 8 are considered high quality studies.

**Data Synthesis and Analysis** Relative risks (RRs) of the effect of randomized treatments were calculated using the meta routine (STATA Statacorp, version 14.0) to account for the probability of events occurring in the treatment group versus the control group<sup>[20]</sup>. Relative risks (RRs) and 95% confidence intervals (CIs) for each outcome were calculated separately for each trial, with grouped data using the intention-to-treat principle<sup>[21]</sup>. The combined RRs are log-transformed and weighted by the inverse variance. Estimates of population effects were calculated using a random effects model. The hypothesis of homogeneity of different treatment effects was tested by Q-statistic, and further quantified by I<sup>2</sup> statistic. Q-statistic  $P < 0.05$  defined significant heterogeneity. I<sup>2</sup> indicates insignificant heterogeneity between 0% and 40%, moderate heterogeneity between 30% and 60%, significant heterogeneity between 50% and 90%, and significant heterogeneity between 75% and 100%<sup>[22]</sup>. The significance level for all outcome and heterogeneity analyses was set at  $P \leq 0.05$ .

**Sensitivity Analysis** In order to investigate the therapeutic effect of aflibercept on patients and whether there was a difference compared with ranizumab, we performed a Meta-analysis by stratified trials with the intracavitary injection of aflibercept and the comparison drug (ranizumab). We input one event for each study group with a zero trial result for sensitivity analysis to avoid any distortion due to the difference in size between the treatment and control groups.

**Publication Bias** To assess potential publication bias, funnel plots were developed and weighted linear regression was used, with the natural log of the odds ratio as the dependent variable and the reciprocal of the total sample size as the independent variable. This approach is an improved MacAskil test that gives a more balanced Type I error rate in

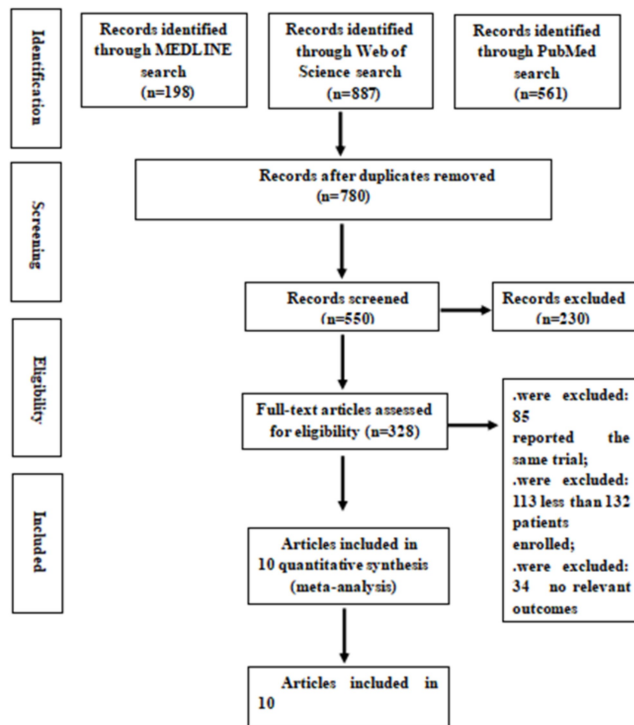


Figure 1 Flow chart of study selection.

Table 1 Characteristics of eligible studies

Studies	Groups	N	Age	Sex (M/F)	Diabetes type	Country	Measurement (intravitreal)	Year	Quality Score
Asharf	IVR IVA	10	51.7±6.2	2/8	II	Egypt	IVR/IVA	2017	6
Asharf	IVA	23 27	-	16/7 17/10	II	Egypt	IVA	2016	7
Bressler	IVB IVA	163 132	-	80/83 80/52	II	America	IVB/IVA	2019	8
Korobelnik	IVR IVA	60 70	51.2±4.3	30/30 40/30	II	America	IVR/IVA	2015	8
Lofty	IVB IVA	40 39	46.7±7.3	25/15 20/19	II	Egypt	IVB/IVA	2018	6
Morikoa	IVR IVA	10	-	3/7	II	Japan	IVR/IVA	2018	8
N Engl J	IVR IVA	44 46	53.2±4.5	20/24 20/26	II	England	IVR/IVA	2015	9
Shimizu	IVR IVA	33 20	-	10/23 11/9	II	Japan	IVR/IVA	2017	8
Wells	IVR IVA	110 114	43.6±4.8	60/50 50/64	II	America	IVR/IVA	2017	8
Bansal	IVR IVA	140 139	51.2±3.2	70/70 60/79	II	America	IVR/IVA	2015	7

the tail probability region than other publication bias tests<sup>[23]</sup>. The significance level for the publication bias analysis was set at  $P < 0.05$ .

**RESULTS**

**Study Characteristics and Quality Assessment** Of the 780 articles identified in the preliminary study, 328 were retrieved for more detailed evaluation and 10 randomized trials were included in the analysis. Patients over 18 years of age with DR

were included in the study (Figure 1). Table 1 shows the detailed characteristics of these studies. There are 6 papers with high marks. That includes 1240 people from Egypt, Japan, the United States and Britain. It should be noted that there were 7 trials including IVA and IVR. In addition, other trials selected only IVA or IVR during the course. The scale used for quality assessment is shown in Figure 2 and the results are shown in Table 1.

Items	Answer <sup>①</sup>	Score <sup>②</sup>
1. Was the study a cohort study?		
2. Was the spectrum of participants' representative?		
3. Were the inclusion and exclusion criteria clearly described?		
4. Were the source of data and recruitment period clearly described?		
5. Were all of the statistical analysis methods in the study clearly described?		
6. Were exposed and unexposed groups matched in the design or cofounders adjusted for analysis?		
7. Were there multiple ratings for PA for different categories of exposure?		
8. Was the DR case definition adequate?		
9. Was the PA definition adequate?		
10. Did all of the included population participate in or respond to the study? If not, were the withdrawals reported or discussed ? <sup>③</sup>		
11. Did the authors discuss the limitation and potential bias of the study?		
Total score		
①Each item in the scale should be answered with 'yes', 'no', or 'unclear'		
②An item would be scored '1' when the answer was 'yes'; otherwise, the item would be scored '0'		
③The answer to the item would be 'yes' if either of the two questions is answered with 'yes'		

Figure 2 Quality assessment scale.

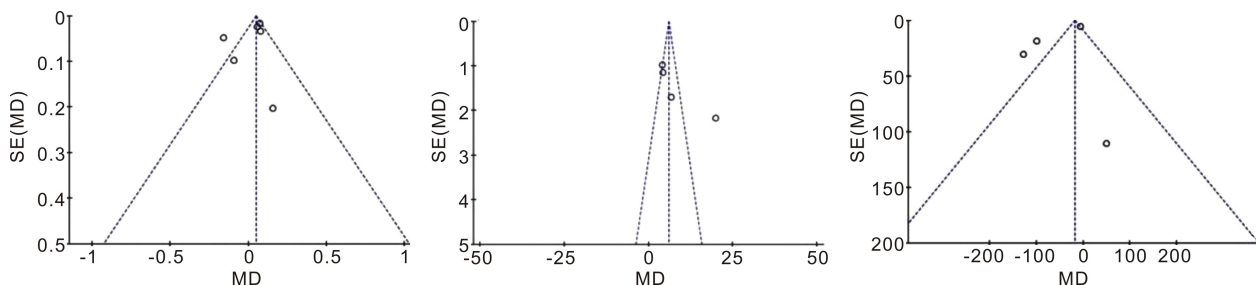


Figure 3 Funnel plot for comparison between Aflibercept and Ranibizumab in BCVA, VA and CMT.

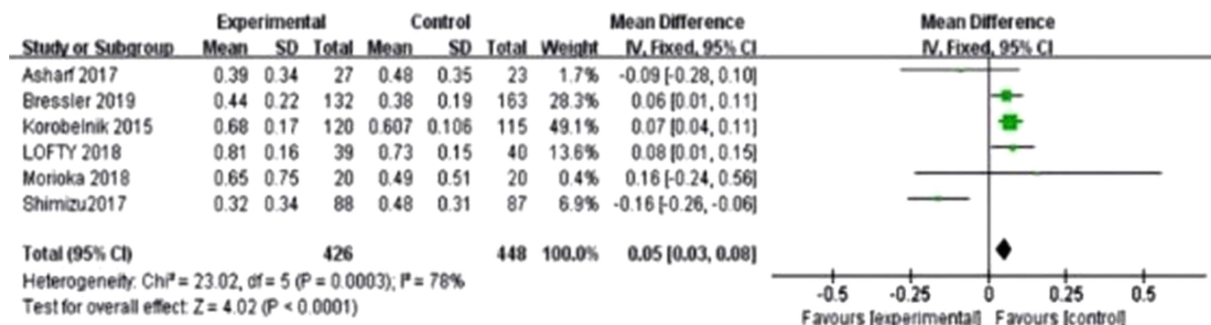


Figure 4 Forest plot summarizing the comparison between Aflibercept and Ranibizumab in BCVA Significance test for estimate  $P < 0.00001$ , Bars indicate the 95% CI.

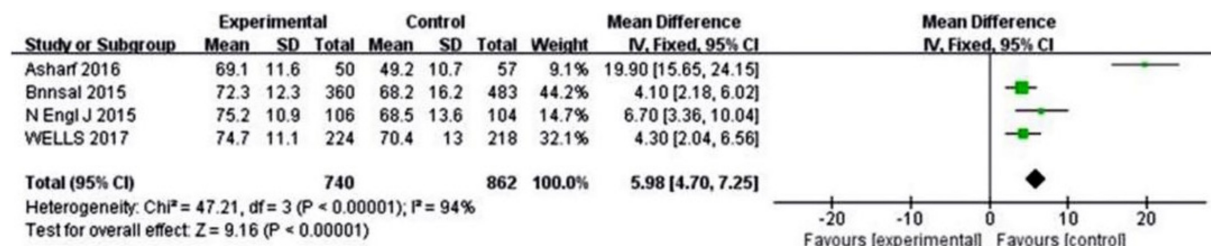


Figure 5 Forest plot summarizing the comparison between Aflibercept and Ranibizumab in VA Significance test for estimate  $P < 0.00001$ , Bars indicate the 95% CI.

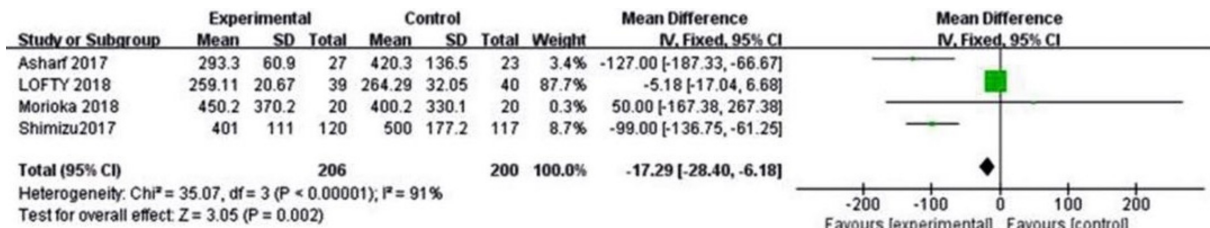
**Outcomes Analysis**

**Best corrected visual acuity** Six studies reported the BCVA of patients after receiving treatments. The heterogeneity test result of the combined effect amount is ( $P = 0.0003$ ,  $I^2 = 78%$ ), and the random effect model analysis is shown in Figure 3. The Meta-analysis result was [ $MD = 0.05$ , 95% CI (0.03, 0.08),  $P = 0.0003$ ]. The BCVA of patients in the Ranibizumab treatment group was higher than that of the Aflibercept group, and the difference was significant. The

detailed results are depicted in Figure 4.

**Visual acuity** Additionally, 4 studies reported patient VA after treatment administration. The heterogeneity test result of the combined effect amount was ( $P = 0.00001$ ,  $I^2 = 94%$ ), and the random effect model analysis is shown in Figure 3. The Meta-analysis result was [ $MD = 5.98$ , 95% CI (4.70, 7.25),  $P = 0.00001$ ]. The VA of patients in the Ranibizumab treatment group was higher than that of those in the Aflibercept group, and the difference was significant. The





**Figure 6 Forest plot summarizing the comparison between Aflibercept and Ranibizumab in CMT Significance test for estimate  $P < 0.00001$ , Bars indicate the 95% CI.**

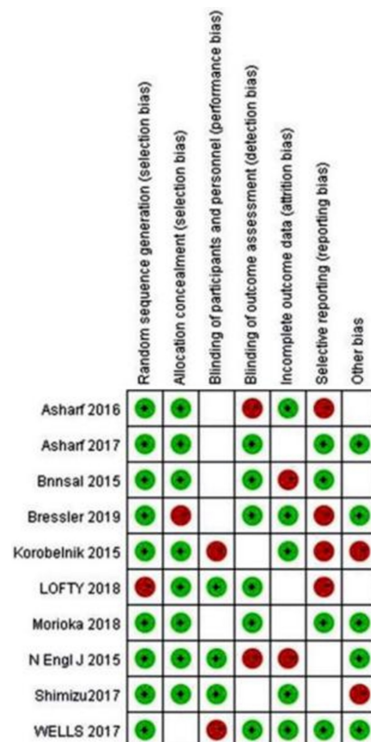
detailed results are depicted in Figure 5.

**Central macular thickness** Four studies reported the CMT of patients after receiving treatments. The heterogeneity test result of the combined effect amount was ( $P = 0.00001$ ,  $I^2 = 91\%$ ), and the random effect model analysis is shown in Figure 3. The Meta-analysis result was [ $MD = -17.29$ , 95%  $CI (-28.40, -6.18)$ ,  $P = 0.00001$ ]. The VA of patients in the Aflibercept treatment group was higher than that of those in the Ranibizumab group, and the difference was significant. The detailed results are depicted in Figure 6.

**Sensitivity and publication bias analysis** Sensitivity analysis was conducted for each indicator, and each included study was excluded respectively to determine the results of Meta-analysis. The results are reported using a random-effects model, which allows for more conservative estimates because the results of fixed and random-effects models are similar. Heterogeneity tests were used to assess heterogeneity between studies. We produced forest plots to assess multivariate adjusted relative risk and the corresponding 95%  $CI$ . Using regression analysis, we assessed whether IVR and IVA were associated with certain prognostic variables at the study level. We used Cochrane Q-statistic (we considered  $P < 0.05$  to indicate statistically significant heterogeneity) and  $I^2$  statistics to assess the heterogeneity of relative risk across studies. Figure 7 depicts the detailed results.

**DISCUSSION**

DR is the manifestation of organ damage in DM<sup>[24]</sup>. Laser or anti-VEGF drugs are popular for alleviating DR<sup>[25]</sup>. Intravitreal injection of anti-VEGF drugs has been shown to be more effective than laser photocoagulation of diabetic macula edema (DME), which was the standard treatment in the 1980s<sup>[26]</sup>. Moreover, using laser therapy alone may also lead to some complications or shortcomings. For instance, nausea, eye swelling, eye pain, tearing, and elevated intraocular pressure may occur during the procedure<sup>[27]</sup>. Because VEGF plays an important role in the development of DR, anti-VEGF drugs have been gradually applied in clinical practice and achieved good results. Against this background, Aflibercept and Ranibizumab were realized in a new era. Both drugs can treat DR by inhibiting VEGF. Ranibizumab (Lucentis, Genentech/Roche) is a high-affinity antigen associated with A monoclonal antibody fragment that neutralizes all bioactive forms of VEGF-A<sup>[28]</sup>. Ranibizumab has been widely used in the treatment of DME, DR and RVO<sup>[29]</sup>. In addition, the use of 0.5 mg Ranibizumab may



**Figure 7 Publication of bias risk maps per document.**

increase the incidence of cataracts<sup>[30]</sup>. Aflibercept is a newly-applied clinical drug that has recently been introduced to the market. Compared to previously marketed Ranibizumab, Aflibercept binding affinity for VEGF is substantially greater, and a mathematical model predicted that Aflibercept might have a substantially longer duration of action in the eye<sup>[31]</sup>. Aflibercept plays a role in localized treatment through intravitreal injection. After intravitreal injection, part of the intraocular and endogenous VEGF binds to inactive Aflibercept, which is called the VEGF complex. In addition, the other part of Aflibercept is absorbed into the body circulation<sup>[32]</sup>. Aflibercept is suitable for DR, DME, AMD and CRVO<sup>[33]</sup>. The most common adverse reaction of Aflibercept is eye pain, cataract, vitreous detachment, and increased intraocular pressure. The process of intravitreal injection may lead to endophthalmitis, so the whole procedure should observe aseptic rules<sup>[34]</sup>. BCVA, VA and CMT have been applied to evaluate the efficacy of anti-VEGF drugs<sup>[35]</sup>. The BCVA and VA after treatment in both groups were higher than those before treatment, which can indicate an improvement in vision<sup>[36]</sup>. In contrast, CMT after treatment was lower than that before treatment, which may be monitored

to determine the efficacy over time<sup>[37]</sup>.

To summarize our Meta-analysis, Aflibercept and Ranibizumab are both beneficial to treat DR patients. Meta-regression analysis showed that both Aflibercept and Ranibizumab had improvements in BCVA [ $MD=0.05$ ,  $95\%CI(0.03, 0.08)$ ,  $P=0.0003$ ], VA [ $MD=5.98$ ,  $95\%CI(4.70, 7.25)$ ,  $P=0.00001$ ], and CMT [ $MD=-17.29$ ,  $95\%CI(-28.40, -6.18)$ ,  $P=0.00001$ ]. Subgroup analysis confirmed that Aflibercept had a markedly better effect on CMT than did Ranibizumab ( $P<0.00001$ ), while Ranibizumab resulted in a wonderful improvement in BCVA ( $P<0.0001$ ) and VA ( $P<0.00001$ ). Therefore, the choice of ranizumab or aflisip should be evaluated separately based on the patient's baseline condition, *i.e.* BCVA and VA or CMT is of greater concern. In addition, patients' age, gender, type of diabetes in patients with diabetes, and the overall study design may affect the results of the Meta-regression. Finally, for practical reasons, qualified studies only cover those written in English, which can lead to bias. The publication bias funnel plot is very important and has a slight asymmetry, suggesting publication bias. Therefore, it is necessary to avoid publication bias from the experimental design stage. Meta-analysis showed that sample size had an effect on heterogeneity. Further research is needed to analyze this finding.

In this Meta-analysis, we screened the literatures strictly according to the inclusion criteria, and finally included 10 articles. The research literature is an open study, and some studies do not describe in terms of allocation concealment, so there may be execution bias. Another limitation is that the conclusions of this study need to be rigorously designed, large-sample, double-blind RCTs to verify.

In summary, a large sample study confirmed that the use of Aflibercept or Ranizumab in patients with diabetic retinopathy or dimethyl ether was associated with a significant reduction in CMT. In particular, Aflibercept was superior to Ranizumab in CMT. In addition, the efficacy of Ranizumab in BCVA and VA is better than that of Aflibercept, further demonstrating the efficacy of anti-VEGF drugs requires larger sample size, longer studies, so as to help physicians and patients better manage DR.

## REFERENCES

- 1 He J, Gu DF, Wu XG, Reynolds K, Duan XF, Yao CH, Wang JL, Chen CS, Chen J, Wildman RP, Klag MJ, Whelton PK. Major causes of death among men and women in China. *N Engl J Med* 2005;353(11):1124-1134
- 2 Cohen MP, Jasti K, Rye DL. Somatomedin on insulin-dependent diabetes mellitus. *J Clin Endocrinol Metab* 1977;45(2):236-239
- 3 Wolfensberger TJ, Hamilton AMP. Diabetic retinopathy-an historical review. *Semin Ophthalmol* 2001;16(1):2-7
- 4 Writing Committee for the Diabetic Retinopathy Clinical Research Network, Gross JG, Glassman AR, Jampol LM, Inusah S, Aiello LP, Antoszyk AN, Baker CW, Berger BB, Bressler NM, Browning D, Elman MJ, Ferris FL 3rd, Friedman SM, *et al.* Panretinal photocoagulation vs intravitreal Ranibizumab for proliferative diabetic retinopathy: a randomized clinical trial. *JAMA* 2015;314(20):2137-2146

- 5 Malone JJ, Morrison AD, Pavan P. Prevalence and significance of retinopathy in subjects with type 1 diabetes of less than 5 years duration screened for the diabetes control and complications trial. *Diabetes Care* 2001;24(3):522-526
- 6 Nakajima M, Cooney MJ, Tu AH, Chang KY, Cao J, Ando A, An GJ, Melia M, de Juan E Jr. Normalization of retinal vascular permeability in experimental diabetes with genistein. *Invest Ophthalmol Vis Sci* 2001;42(9):2110-2114
- 7 Takagi H. IFS01-5 Molecular mechanisms of retinal neovascularization in diabetic retinopathy. *Atheroscler Suppl* 2003;4(2):5
- 8 Eyetech Study Group. Preclinical and phase IA clinical evaluation of an anti-VEGF pegylated aptamer (EYE001) for the treatment of exudative age-related macular degeneration. *Retina* 2002;22(2):143-152
- 9 Writing Committee for the Diabetic Retinopathy Clinical Research Network, Gross JG, Glassman AR, Jampol LM, Inusah S, Aiello LP, Antoszyk AN, Baker CW, Berger BB, Bressler NM, Browning D, Elman MJ, Ferris FL, Friedman SM, Marcus DM, Melia M, Stockdale CR, Sun JK, Beck RW. Panretinal photocoagulation vs intravitreal ranibizumab for proliferative diabetic retinopathy: a randomized clinical trial. *JAMA* 2015;314(20):2137-2146
- 10 Korobelnik JF, Do DV, Schmidt-Erfurth U, Boyer DS, Holz FG, Heier JS, Midena E, Kaiser PK, Terasaki H, Marcus DM, Nguyen QD, Jaffe GJ, Slakter JS, Simader C, Soo Y, Schmelzer T, Yancopoulos GD, Stahl N, Vitti R, Berliner AJ, Zeitz O, Metz C, Brown DM. Intravitreal aflibercept for diabetic macular edema. *Ophthalmology* 2014;121(11):2247-2254
- 11 Kim KJ, Li B, Houck K, Winer J, Ferrara N. The vascular endothelial growth factor proteins; identification of biologically relevant regions by neutralizing monoclonal antibodies. *Growth Factors* 1992;7(1):53-64
- 12 Chen Y, Wiesmann C, Fuh G, Li B, Christinger HW, McKay P, de Vos AM, Lowman HB. Selection and analysis of an optimized anti-VEGF antibody: crystal structure of an affinity-matured fab in complex with antigen. *J Mol Biol* 1999;293(4):865-881
- 13 Mordenti J, Cuthbertson RA, Ferrara N, Thomsen K, Berleau L, Licko V, Allen PC, Valverde CR, Meng YG, Fei DT, Foure KM, Ryan AM. Comparisons of the intraocular tissue distribution, pharmacokinetics, and safety of 125I-labeled full-length and Fab antibodies in rhesus monkeys following intravitreal administration. *Toxicol Pathol* 1999;27(5):536-544
- 14 Mitchell P, Bandello F, Schmidt-Erfurth U, Lang GE, Massin P, Schlingemann RO, Sutter F, Simader C, Burian G, Gerstner O, Weichselberger A, RESTORE study group. The RESTORE study: ranibizumab monotherapy or combined with laser versus laser monotherapy for diabetic macular edema. *Ophthalmology* 2011;118(4):615-625
- 15 Kaiser PK. Antivascular endothelial growth factor agents and their development; therapeutic implications in ocular diseases. *Am J Ophthalmol* 2006;142(4):660-668
- 16 Haig J, Barbeau M, Ferreira A. Cost-effectiveness of ranibizumab in the treatment of visual impairment due to diabetic macular edema. *J Med Econ* 2016;19(7):663-671
- 17 Stewart MW, Rosenfeld PJ. Predicted biological activity of intravitreal VEGF Trap. *Br J Ophthalmol* 2008;92(5):667-668
- 18 Moher D, Liberati A, Tetzlaff J, Altman DG, PRISMA Group. Preferred reporting items for systematic reviews and Meta-analyses: the PRISMA statement. *PLoS Med* 2009;6(7):e1000097
- 19 Wells G, Shea B, O'Connell D, Robertson J, Peterson J, Welch V, Losos M, Tugwell P. The Newcastle-Ottawa Scale (NOS) for assessing the quality of nonrandomised studies in Meta-analyses. 2014

- 20 Sharp SS. Meta-analysis. STB reprints. 1998;7:100e108
- 21 Scott IU, Jackson GR, Quillen DA, Klein R, Liao J, Gardner TW. Effect of doxycycline vs placebo on retinal function and diabetic retinopathy progression in mild to moderate nonproliferative diabetic retinopathy. *JAMA Ophthalmol* 2014;132(9):1137
- 22 Stahel M, Becker M, Graf N, Michels S. Systemic interleukin 1 $\beta$  inhibition in proliferative diabetic retinopathy. *Retina* 2016;36(2):385-391
- 23 Schuch FB, Vancampfort D, Rosenbaum S, Richards J, Ward PB, Veronese N, Solmi M, Cadore EL, Stubbs B. Exercise for depression in older adults: a Meta-analysis of randomized controlled trials adjusting for publication bias. *Braz J Psychiatry* 2016;38(3):247-254
- 24 Peters JL, Sutton AJ, Jones DR, Abrams KR, Rushton L. Comparison of two methods to detect publication bias in Meta-analysis. *JAMA* 2006;295(6):676-680
- 25 Lechner J, O'Leary OE, Stitt AW. The pathology associated with diabetic retinopathy. *Vision Res* 2017;139:7-14
- 26 Varma R, Bressler NM, Doan QV, Gleeson M, Danese M, Bower JK, Selvin E, Dolan C, Fine J, Colman S, Turpcu A. Prevalence of and risk factors for diabetic macular edema in the United States. *JAMA Ophthalmol* 2014;132(11):1334-1340
- 27 Diabetic Retinopathy Clinical Research Network, Elman MJ, Aiello LP, Beck RW, Bressler NM, Bressler SB, Edwards AR, Ferris FL 3rd, Friedman SM, Glassman AR, Miller KM, Scott IU, Stockdale CR, Sun JK. Randomized trial evaluating ranibizumab plus prompt or deferred laser or triamcinolone plus prompt laser for diabetic macular edema. *Ophthalmology* 2010;117(6):1064-1077.e35
- 28 Eschenbach DA. Chronic vulvovaginal candidiasis. *N Engl J Med* 2004;351(9):851-852
- 29 Stewart MW. A review of ranibizumab for the treatment of diabetic retinopathy. *Ophthalmol Ther* 2017;6(1):33-47
- 30 Pirota M, Gunn J, Chondros P, Grover S, O'Malley P, Hurley S, Garland S. Effect of lactobacillus in preventing post - antibiotic vulvovaginal candidiasis: a randomised controlled trial. *BMJ* 2004;329(7465):548
- 31 Ferris FL, Fine SL, Hyman L. Age-related macular degeneration and blindness due to neovascular maculopathy. *Arch Ophthalmol Chic Ill* 1984;102(11):1640-1642
- 32 Nguyen QD, Shah SM, Browning DJ, Hudson H, Sonkin P, Hariprasad SM, Kaiser P, Slakter JS, Haller J, Do DV, Mieler WF, Chu KR, Yang K, Ingerman A, Vitti RL, Berliner AJ, Cedarbaum JM, Campochiaro PA. A phase I study of intravitreal vascular endothelial growth factor trap-eye in patients with neovascular age-related macular degeneration. *Ophthalmology* 2009;116(11):2141-2148.e1
- 33 Ashraf M, Souka AAR. Aflibercept in age - related macular degeneration; evaluating its role as a primary therapeutic option. *Eye (Lond)* 2017;31(11):1523-1536
- 34 Boyer D, Heier J, Brown DM, Clark WL, Vitti R, Berliner AJ, Groetzbach G, Zeitz O, Sandbrink R, Zhu XP, Beckmann K, Haller JA. Vascular endothelial growth factor Trap - Eye for macular edema secondary to central retinal vein occlusion: six - month results of the phase 3 COPERNICUS study. *Ophthalmology* 2012;119(5):1024-1032
- 35 Rim TH, Kim DW, Han JS, Chung EU. Retinal vein occlusion and the risk of stroke development: a 9-year nationwide population-based study. *Ophthalmology* 2015;122(6):1187-1194
- 36 Pielen A, Mirshahi A, Feltgen N, Lorenz K, Korb C, Junker B, Schaefer C, Zwiener I, Hattenbach LO, Group TRS. Ranibizumab for Branch Retinal Vein Occlusion Associated Macular Edema Study (RABAMES): six - month results of a prospective randomized clinical trial. *Acta Ophthalmol* 2015;93(1):e29-e37
- 37 Jung SH, Kim KA, Sohn SW, Yang SJ. Association of aqueous humor cytokines with the development of retinal ischemia and recurrent macular edema in retinal vein occlusion. *Investig Ophthalmol Vis Sci* 2014;55(4):2290-2296