

Scleral buckling with chandelier illumination system in rhegmatogenous retinal detachment surgery: a large case series

Valerio Piccirillo¹, Michele Lanza², Carlo Irregolare¹, Antonello Iovine¹, Agostino Diplomatico¹, Sandro Sbordone², Alfonso Savastano³

¹Minerva Hospital, Santa Maria Capua Vetere 81055, Italy

²Multidisciplinary Department of Medical, Surgical and Dental Sciences, University of Campania “Luigi Vanvitelli”, Napoli 80132, Italy

³Careggi Hospital, Florence 50100, Italy

Correspondence to: Michele Lanza. Multidisciplinary Department of Medical, Surgical and Dental Sciences, University of Campania “Luigi Vanvitelli”, Napoli 80132, Italy. mic.lanza@gmail.com

Received: 2018-05-18 Accepted: 2018-08-09

吊顶灯照明行巩膜扣带术治疗孔源性视网膜脱离

Valerio Piccirillo¹, Michele Lanza², Carlo Irregolare¹, Antonello Iovine¹, Agostino Diplomatico¹, Sandro Sbordone², Alfonso Savastano³

(作者单位:¹81055 意大利,圣玛利亚-卡普阿韦泰雷,密涅瓦医院;²80132 意大利,那不勒斯,坎帕尼亚 Luigi Vanvitelli 大学,外科与口腔科学,多学科医学部;³50100 意大利,佛罗伦萨,卡勒基医院)

通讯作者: Michele Lanza. mic.lanza@gmail.com

摘要

目的:评估治疗孔源性视网膜脱离(RRD)的巩膜扣带术中 使用吊顶灯照明系统的优势。

方法:在这一对照、回顾性研究中,72 例 72 眼于密涅瓦医院接受巩膜扣带术治疗的 RRD 患者分为两组。A 组在吊顶灯照明下行巩膜扣带术,B 组进行常规巩膜扣带术。两组均于术前、术后 1、3、7、14、30、90 和 180d 进行随访。指标包括其它手术操作、最佳框架眼镜矫正视力(BSVA)、手术时间、视网膜裂孔再次出现进行了分析和比较。

结果:术后 6mo,两组 BSVA 均较术前显著改善($P<0.01$)。两组再次出现视网膜裂孔的比例未见明显差异,但 A 组手术时间较 B 组明显缩短。

结论:通过我们观察得出结果,使用巩膜扣带术治疗 RRD 时,吊顶灯照明系统是一个有价值的工具,即使这些结果需要在更大人群中进一步研究证明。

关键词:吊顶灯照明系统;巩膜扣带术;孔源性视网膜脱离;视网膜手术

引用:Piccirillo V, Lanza M, Irregolare C, Iovine A, Diplomatico A, Sbordone S, Savastano A. 吊顶灯照明行巩膜扣带术治疗孔源性视网膜脱离. 国际眼科杂志 2018;18(10):1763-1766

Abstract

• **AIM:** To evaluate advantages of chandelier illumination system during scleral buckling (SB) procedures for rhegmatogenous retinal detachment (RRD) surgery.

• **METHODS:** In this comparative, retrospective study, data of 72 eyes of 72 patients undergoing SB for RRD at Minerva Hospital (Santa Maria Capua Vetere, Italy), divided in 2 groups of 36 eyes each were collected. In one group (group A) eyes underwent SB with chandelier, in the other one (group B) eyes underwent SB without using chandelier illumination system. Every eye of both groups was checked before surgery and at 1, 3, 7, 14, 30, 90 and 180d follow up. Parameters such as additional procedures, best spectacles visual acuity (BSVA) (measured with Snellen Lines as decimal fraction), surgical time and retinal breaks recurrences had been analyzed before and after surgery and statistical comparison have been run between two groups.

• **RESULTS:** A significant ($P<0.01$) improvement in BSVA was observed at 6mo follow up in both groups; comparing groups A and B, no significant clinical differences was found in recurrences rate whereas mean surgical time in group A was statistically lower than the group B ones.

• **CONCLUSION:** According to results observed, even if they need to be confirmed in further studies with larger population, chandelier illumination system could be considered a valuable tool for SB surgery in eyes affected by RRD.

• **KEYWORDS:** chandelier illumination system; scleral buckling; rhegmatogenous retinal detachment; retinal surgery

DOI:10.3980/j.issn.1672-5123.2018.10.02

Citation: Piccirillo V, Lanza M, Irregolare C, Iovine A, Diplomatico A, Sbordone S, Savastano A. Scleral buckling with chandelier illumination system in rhegmatogenous retinal detachment surgery: a large case series. *Guoji Yanke Zazhi(Int Eye Sci)* 2018; 18(10):1763-1766

INTRODUCTION

Rhegmatogenous retinal detachment (RRD) is a very important cause of not reversible visual impairment, surgery is mandatory to prevent permanent visual loss^[1-5]. Current surgical techniques include two main ones: scleral

buckling (SB) and pars plana vitrectomy (PPV), moreover it is possible to use different optional procedures such as cryo-retinopexy or retinal laser photocoagulation^[1-9]. Supremacy of one of the two techniques has not been proven but, in the last years, a strong trend in choosing PPV over SD for primary RRD surgery technique has been observed^[4-13]. Main reasons of this choice have been advances in the instrumentations and safety of PPV along with modern microscopes and wide-angle viewing systems that have enabled better intraoperative visualization of retinal breaks^[14]. These technical improvements allowed the surgeons to accurately close all the retinal breaks and to manage detached retina in a safer, easier and faster way^[14]. Moreover, transconjunctival, suture-less vitrectomy techniques provide faster wound healing, reduced conjunctival scarring, improved patient comfort, decreased postoperative inflammation and induced less postoperative astigmatic changes^[1-5].

On the other hand, the scleral buckling technique retains some advantages (it is an extraocular procedure and has lower cost for single surgery)^[1-5] and remains fundamental for the complete formation of the vitreo-retinal surgeons^[15]. For this reason, several modifications to the basic technique have been suggested, in particular to improve the retinal lesions visualization^[16-20]. The SB technique with chandelier has been described in only few published papers^[16-17,20], purpose of this study is to evaluate this new device in SB surgery for RRD in a large case series cases comparing this technique with standard sclera buckling one.

SUBJECTS AND METHODS

The study and data collection were carried out with approval from the appropriate Institutional Review Board (IRB) from Casa di Cura Minerva, (Santa Maria Capua Vetere, CE, Italy), informed consent for the surgical procedure and for the research was obtained from the patients, the study was in adherence to the tenets of the Declaration of Helsinki.

In this retrospective study, two groups of eyes with primary RDD requiring SB surgery without vitrectomy were selected. In group A 36 eyes of 36 patients underwent SB with chandelier illumination system and in group B 36 eyes 36 patients underwent standard SB surgery. The demographics and clinical details of eyes included in this study cohort are shown in Table 1.

Patients with significant media opacities such as vitreous hemorrhage or significant cataract and any coexisting ocular pathology such as glaucoma and uveitis were excluded from this study.

Before surgery, every patients underwent a complete preoperative assessment including best corrected visual acuity (BCVA) (measured as Snellen lines), slit-lamp examination, including assessment of the anterior segment, intraocular pressure measurement. Moreover, fundus evaluation with slit-lamp biomicroscopy and indirect ophthalmoscopy was performed in order to evaluate RD details such as presence of any pathologic features in the peripheral retina, PVR presence and to accurately localize and describe all details of retinal breaks detected.

Table 1 Demographics and clinical details of group A and group B eyes with statistical difference test value

Parameters	Group A	Group B	P
Participants	36	36	-
Age (mean ± SD, y)	59.05±9.57	58.02±7.26	0.12
Gender (F)	12	14	0.23
Pseudophakic eyes	10	12	0.15

Primary outcome was considered the successful retinal reattachment; secondary outcomes were considered the visual acuity improvements, surgery time and avoiding other complications.

All scleral buckling procedures were performed by 2 senior vitreoretinal surgeons (Piccirillo V and Irregolare C) using both techniques. In both groups all patients were operated under peribulbar anesthesia (0.8 mL of 10% ropivacaine). Scleral buckling surgery with chandelier illumination system performed in group A eyes as follow: after a 360° limbal peritotomy, traction sutures were passed under the rectus muscles, indeed 2.5 mm white encircling band (MIRA 240, Inc., Uxbridge, MA, USA) was fixed at 13.5 mm from limbus using a non absorbable suture (5-0 Mersilene, Ethicon, Somerville, NJ, USA) (Figure 1A). Sclerotomy for chandelier illumination was created with a 25 G semi-valved trocar (25 G trocar Synergetics, Bausch + Lomb Retina St. Louis, USA) at 3.5 and 4 mm posterior to the limbus for pseudophakic and phakic patients, respectively, in lower-temporal quadrant (Figure 1B). The 25 G optic fiber was connected to the light source (halogen lamp) of the device (Assistant, Optikon, Rome, Italy). Initially, the trocar blade was inserted obliquely into the sclera at an angle of about 30° to 45° up to the cannula mark. Then, the direction of the blade was adjusted perpendicular to the sclera as it has been inserted into the vitreous cavity (Figure 1C). Once the chandelier was inserted, the wide-field non contact direct viewing system (Eibos, Moller Wedel, Koeniz, Switzerland) was used for fundus evaluation through viscoelastic interface (Figure 1D). A detailed assessment of the fundus was done using indentation and the retina breaks were localized. External drainage of sub-retinal fluid as well as placement of silicone tires or sponges were performed as needed. Intraoperative cryo-retinopexy and retinal tamponade with injection of air or an expandable gas were additional procedures, performed at the surgeon's discretion. Gas tamponade was performed always with 20% diluted sulfur hexafluoride (Easygas SF6-Fluoron, Geuder, Heidelberg, Germany). At this stage, the fundus was checked to confirm retinal flattening along with the desired indentation effect (Figure 1E). The chandelier light was removed together with trocar and the sclerotomy was sutured (8-0 Vycril Ethicon, Somerville, NJ, USA) as needed. A drop of povidone-iodine has been then instilled followed by conjunctival closure with 8-0 suture and subconjunctival antibiotic injection (0.2 mL of 0.3% Gentamicin). Standard scleral buckling surgery was

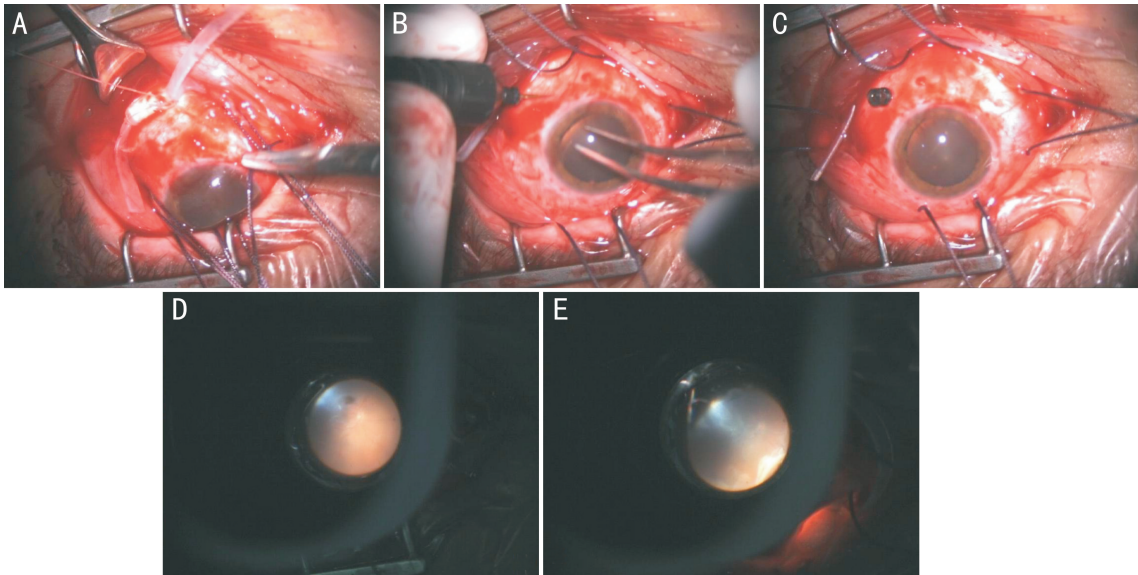


Figure 1 The procedure of scleral buckling A: Illustration of the 2.5 mm white encircling band fixation at 13.5 mm from limbus using a non-absorbable suture; B: Illustration of sclerotomy execution for chandelier illumination introduction in lower temporal quadrant; C: Illustration of the trocar placement creating the connection with the vitreous cavity; D: Illustration of fundus visualization with the chandelier illumination system and wide-field non contact direct viewing system; E: Illustration of fundus visualization with the chandelier illumination system and wide-field non contact direct viewing system at the end of surgery in order to check retinal flattening with the help of indentation technique.

Table 2 Main surgical outcomes in Group A and Group B eyes with statistical difference test value

Items	Group A	Group B	P
Recurrence of retinal break	6 (17%)	8 (22%)	0.08
Improvements in BCVA (Snellen lines in decimal fractions)	+0.27±0.17	+0.24±0.16	0.11
Minutes of surgery	78.43±11.66	96.82±13.83	<0.05

BCVA: Best correct visual acuity.

performed as previously described, without using additional illumination tools^[15].

Postoperatively, all patients routinely used chloramphenicol 0.5% and betamethasone 0.2% fixed combination eye drops 4 times daily, tropicamide 1% 2 times daily for 2–4wk and 500 mg cefaclor oral suspension. Routine follow up were at 1, 3, 7, 14, 30, 90 and 180d.

The groups A and B were compared with one-way factorial analysis of variance (ANOVA) for each parameter. Moreover intra-group time variation of parameters was evaluated with Student's *t*-test for repeated measures. For all tests the level of significance was set at $P < 0.05$. All analyses were performed using SPSS software (IBM Corp. Armonk, New York, USA) version 18.0.

RESULTS

Primary and secondary outcomes of the eyes of both groups are described in Table 2. The vast majority of eyes underwent drainage of sub-retinal fluid (89% in group A and 92% in group B); gas tamponade was performed in 19 eyes (53%) in group A and in 22 eyes (61%) in group B. Additional cryotherapy to seal retinal breaks was administrated in 2 cases both groups. No eyes with pre-existing cataract had significant progression of the lens opacities. In group A, mean visual acuity before surgery was 0.12±0.11 Snellen lines

(decimal fraction) ranging from 0.008 to 0.4 Snellen Lines; at 6mo follow up mean visual acuity was 0.39±0.25 Snellen Lines, ranging from 0.017 to 0.8 Snellen Lines. A significant ($P < 0.001$) visual acuity improvement has been observed. In group B, mean visual acuity before surgery was 0.10±0.09 Snellen lines (decimal fraction) ranging from 0.008 to 0.3 Snellen Lines; at 6mo follow up mean visual acuity was 0.34±0.35 Snellen Lines, ranging from 0.017 to 0.6 Snellen Lines. No significant difference in visual acuity was observed before surgery ($P = 0.16$) between the two groups. A significant ($P < 0.001$) visual acuity improvement after surgery has been observed in both groups. At 6-month follow up, no endophthalmitis have been observed. Patients with recurrence of retinal detachment underwent *via* pars plana vitrectomy; the visual acuity included in the statistical analysis was the last measured before the recurrences. No other kind of complications have been observed in eyes included in the study.

DISCUSSION

For many years, improvements purposed in retinal surgery have been focused only to PPV and they have been so many and so important, to make this procedure the first choice among the retinal surgical ones^[4-13]. Recently it is possible to find some variations interesting SB technique too, in order to

improve this very important procedure^[16-20]. This study is presenting the larger series of SB using a chandelier illumination system.

Nawrocki *et al*^[17] described the results of a new optical device in enlarging the surgeon visual field during SB surgery in 7 eyes affected by RRD, observing best results in aphakic eyes. Aras *et al*^[18] and Gogia *et al*^[19] both evaluated a combination of a 25-gauge illumination fiber inserted into the sclera at the pars plana with wide-angle viewing system in 16 eyes^[18] and in 25 eyes^[19] undergoing SB for RRD. They reported good results also if it is important to remind that when retinal periphery is imagined using non-contact based systems it is possible to observe image distortion that could interfere with a good surgical procedure.

Nagpal *et al*^[20] firstly describe the chandelier illumination system for SB surgery with very good results in 10 eyes. Narayanan *et al*^[15] firstly compare traditional SB surgery with SB with chandelier in 14 eyes affected by RRD, finding that the procedures with the new illumination device lasted less minutes and were more useful for teaching. In this study mean surgery time in group A (Table 2) was not so different by the one reported by Narayanan *et al*^[15], so it is lower of the standard SB surgery time recorded in group B and reported previously^[4-5,15]. Time saving could be due to the easier retinal breaks localization and visualization, moreover, this illumination system allow to better control in every surgical steps because it provide a great improvement in overall retinal visualization. Thus, this new device allow to perform not just faster SB surgery, but provide more confidence to the surgeons in their ability to detect retinal breaks too. Furthermore, thanks to this illumination system, physicians attending the surgery with the first operator can better watch the surgical fields too and this could be a really great advantage for the residency programs.

In conclusion, even if this is only a preliminary study, according to the results observed, chandelier illumination system seems to make RRD surgery with SB technique faster, thanks to an easier and better retinal visualization. Moreover this system allows to improve quality of teaching this technique. More papers are needed to state if this is a method that could be largely routinely used but these data, suggest that it is an interesting device to use in this kind of surgical procedure. It is important to underline that this is one of the first papers evaluating this surgical tool and it is presenting the larger populations study.

REFERENCES

- 1 Berrocal MH, Chenworth ML, Acaba LA. Management of giant retinal tear detachments. *J Ophthalmic Vis Res* 2017;12(1):93-97
- 2 Blindbaek S, Grauslund J. Prophylactic treatment of retinal breaks a systematic review. *Acta Ophthalmol* 2015;93(1):3-8

- 3 Mityr D, Fleck BW, Wright AF, Campbell H, Charteris DG. Pathogenesis of rhegmatogenous retinal detachment: predisposing anatomy and cell biology. *Retina* 2010;30(10):1561-1572
- 4 Sodhi A, Leung LS, Do DV, Gower EW, Schein OD, Handa JT. Recent trends in the management of rhegmatogenous retinal detachment. *Surv Ophthalmol* 2008;53(1):50-67
- 5 D'Amico DJ. Clinical practice. Primary retinal detachment. *N Engl J Med* 2008;359(22):2346-2354
- 6 Schwartz SG, Flynn HW Jr, Mieler WF. Update on retinal detachment surgery. *Curr Opin Ophthalmol* 2013;24(3):255-261
- 7 Fraser S, Steel D. Retinal detachment. *BMJ Clin Evid* 2010;24:2010
- 8 Mityr D, Charteris DG, Fleck BW, Campbell H, Singh J. The epidemiology of rhegmatogenous retinal detachment: geographical variation and clinical associations. *Br J Ophthalmol* 2010;94(6):678-684
- 9 Sodhi A, Leung LS, Do DV, Gower EW, Schein OD, Handa JT. Recent trends in the management of rhegmatogenous retinal detachment. *Surv Ophthalmol* 2008;53(1):50-67
- 10 Totsuka K, Inui H, Roggia MF, Hirasawa K, Noda Y, Ueta T. Supplemental sclera buckle in vitrectomy for the repair of rhegmatogenous retinal detachment: a systematic review of literature and meta-analysis. *Retina* 2015;35(11):2423-2431
- 11 Hatfe E, Sena DF, Fallano KA, Crews J, Do DV. Pneumatic retinopexy versus scleral buckle for repairing simple rhegmatogenous retinal detachments. *Cochrane Database Syst Rev* 2015;(5):CD008350
- 12 Adelman RA, Parnes AJ, Ducournau D, European Vitreo-Retinal Society (EVR) Retinal Detachment Study Group. Strategy for the management of uncomplicated retinal detachments: the European vitreo-retinal society retinal detachment study report 1. *Ophthalmology* 2013;120(9):1804-1808
- 13 Ramulu PY, Do DV, Corcoran KJ, Corcoran SL, Robin AL. Use of retinal procedures in medicare beneficiaries from 1997 to 2007. *Arch Ophthalmol* 2010;128(10):1335-1340
- 14 Chalam KV, Shah VA. Optics of wide-angle panoramic viewing system assisted vitreous surgery. *Surv Ophthalmol* 2004;49:437-445
- 15 Narayanan R, Tyagi M, Hussein A, Chhablani J, Apte RS. Scleral buckling with wide-angled endoillumination as a surgical educational tool. *Retina* 2016;36(4):830-833
- 16 Seider MI, Nomides RE, Hahn P, Mruthyunjaya P, Mahmoud TH. Scleral buckling with chandelier illumination. *J Ophthalmic Vis Res* 2016;11(3):304-309
- 17 Nawrocki J, Michalewska Z, Michalewski J. Optic Fibre Free Intravitreal Surgical System (OFFISS) in retinal detachment surgery. *Ophthalmic Surg Lasers Imaging* 2008;45:466-470
- 18 Aras C, Ucar D, Koytak A, Yetik H. Scleral buckling with a non-contact wide-angle viewing system. *Ophthalmologica* 2012;227(2):107-110
- 19 Gogia V, Venkatesh P, Gupta S, Kakkar A, Garg S. Endoilluminator-assisted scleral buckling: our results. *Indian J Ophthalmol* 2014;62(8):893-894
- 20 Nagpal M, Bhardwaj S, Mehrotra N. Scleral buckling for rhegmatogenous retinal detachment using vitrectomy-based visualization systems and chandelier illumination. *Asia Pac J Ophthalmol* 2013;2(3):165-168