

# Immediate intraocular pressure rise after intravitreal injection of ranibizumab and two doses of triamcinolone acetonide

Gul Arikan, Ali Osman Saatci, Ferit Hakan Oner

Department of Ophthalmology, School of Medicine, Dokuz Eylul University, Izmir 35340, Turkey

**Correspondence to:** Gul Arikan. Department of Ophthalmology, School of Medicine, Dokuz Eylul University, Izmir 35340, Turkey. gulozdenarikan@gmail.com

Received:2011-04-29 Accepted:2011-08-08

## Abstract

• **AIM:** To evaluate prospectively immediate intraocular pressure (IOP) changes after the intravitreal injection of ranibizumab, 2 and 4mg triamcinolone acetonide.

• **METHODS:** Patients who underwent intravitreal injection of 0.1mL (4mg) triamcinolone acetonide (TA, Group T4), 0.05mL (2mg) TA (Group T2) and 0.05mL (0.5mg) ranibizumab (Group R) comprised the study population. Overall, 229 eyes of 205 patients were injected. Fifty-four eyes (23.6%) were in Group T4, 69 eyes (30.1%) in Group T2 and 106 eyes (46.3%) in Group R. If IOP was less than 26mmHg immediately after the injection no further measurement was performed. If IOP was  $\geq$ 26mmHg, IOP was remeasured till the reading was below 26mmHg at 5, 15 and 30 minutes.

• **RESULTS:** Immediately after the injection, the IOP of 28 eyes (51.9%) in Group T4, 22 eyes (31.9%) in Group T2 and 51 eyes (48.1%) in Group R were over 25mmHg. At 30 minutes, IOP of one eye (1.9%) in group T4, two eyes (2.9%) in group T2 and two eyes (1.9%) in Group R were over 25mmHg. Immediate post-injection IOP was significantly higher in Group T4 and Group R when compared to Group T2 ( $P < 0.001$  and  $P < 0.001$ , respectively). IOP was significantly higher in eyes without vitreous reflux when compared to those with vitreous reflux in all groups ( $P < 0.001$ ).

• **CONCLUSION:** IOP may remarkably increase immediately after the intravitreal injection of 2 or 4mg triamcinolone acetonide, and 0.5mg ranibizumab. Absence of vitreous reflux is the most important predicting factor for immediate IOP rise after the injection.

• **KEYWORDS:** anti-VEGF agents; glaucoma; intraocular pressure; intravitreal injection; steroids

DOI:10.3969/j.issn.1672-5123.2011.09.001

Arikan G, Saatci AO, Oner FH. Immediate intraocular pressure rise after intravitreal injection of ranibizumab and two doses of triamcinolone acetonide. *Gucji Yanke Zazhi (Int J Ophthalmol)* 2011;11(9):1497-1500

## INTRODUCTION

Intravitreal injection therapy is getting more and more popular nowadays. Triamcinolone acetonide (TA) and various anti-VEGF agents are the most commonly employed drugs<sup>[1]</sup>. Perhaps, the most known side-effect of intravitreal injection therapy is the delayed intraocular pressure (IOP) elevation noted particularly after the TA injection. Though the most preferred TA dose is 4mg (0.1mL), 2mg (0.05mL) is also used by many to lessen the steroid side effects<sup>[2]</sup>. Delayed pressure rise after TA injection is studied extensively<sup>[3-7]</sup>, but immediate pressure rise occurring after any type of drug injection is relatively less studied<sup>[8-16]</sup>. We believe that factors affecting the immediate pressure rise after any injection has to be elucidated and thereby investigated the effect of 0.1mL (4mg) TA, 0.05mL (2mg) TA and 0.05mL (0.5mg) ranibizumab on immediate IOP prospectively.

## MATERIALS AND METHODS

**Materials** Patients undergoing intravitreal injection of 0.1mL (4mg) or 0.05mL (2mg) triamcinolone acetonide (Sinakort-A 40mg/mL, I. E. Ulagay, Istanbul, Turkey) and 0.05mL (0.5mg) ranibizumab (Lucentis 10mg/mL, Novartis, Basel, Switzerland) were included in this prospective study. The study followed the tenets of the Declaration of Helsinki and was approved by the Ethics Committee of the Dokuz Eylul University School of Medicine. All subjects underwent a complete ophthalmic examination prior to injection including slit-lamp biomicroscopy, applanation intraocular pressure measurement, indirect ophthalmoscopy and/or contact lens biomicroscopy, optical coherence tomography and fundus fluorescein angiography (if necessary). Before the injection, axial length measurements were obtained with ultrasound biometry (OcuScan, Alcon, Fortworth, Texas, USA). Mydriasis was achieved with phenylephrine 25g/L, tropicamide 5g/L and cyclopentolate 10g/L drops. All injections were performed in the operating room under topical anesthesia. Periocular skin and eyelids were scrubbed with 100g/L topical povidone-iodine. Povidone iodine (50g/L) was instilled into the cul-de-sac 5 minutes prior to injection. Sterile drape and eyelid speculum were used in each case. The injections were performed by one of us (GA) through the inferotemporal quadrant, either 3.5 or 4mm posterior to the limbus, depending upon the lens status. We used 26-gauge needles for TA and 30-gauge needles for ranibizumab injections. After the intravitreal injection, a sterile cotton

applicator was applied over the injection site. Presence or absence of vitreous reflux after the injection was noted.

**Methods** IOP was measured with Perkins hand held tonometer (Clement Clarke International, Harlow, England) in sitting position just before and immediately after the injection. Patients with baseline IOP > 21mmHg were excluded. However, glaucoma patients with well-controlled IOP were not excluded from the study. The measurable upper limit for Perkins tonometer was 52mmHg. We considered the maximum measurement as 52mmHg. If IOP was less than 26mmHg immediately after the injection no further measurement was performed. If IOP was  $\geq 26$ mmHg just after the injection, IOP was remeasured till the reading was below 26mmHg at 5, 15 and 30 minutes. If IOP was still over 25mmHg at the 30 minute IOP was rechecked with Goldmann applanation tonometry at the second post-injection hour and patients still with high IOP were put on antiglaucomatous medication.

**Statistical Analysis** Statistical analysis was performed with SPSS15.0 software (SPSS, Inc, Chicago, IL). Paired and unpaired *t* test, Wilcoxon test, Mann-Whitney *U* test, one-way ANOVA test, Kaplan-Meier survival analysis were used where appropriate. A multivariate logistic regression analysis with enter selection was also carried out to investigate factors associated with high IOP (> 25mmHg) immediately after injection.  $P < 0.05$  was regarded as statistically significant.

**RESULTS**

A total of 229 injections in 229 eyes of 205 patients (105 male, 100 female) were evaluated in this prospective study. Mean age was  $65.4 \pm 11.5$  (range, 25-88) years. The indication for intravitreal injection was: exudative age-related macular degeneration [100 patients (48.8%)], diabetic retinopathy [78 patients (38%)], retinal vein occlusion [14 patients (6.8%)], cystoid macular edema [6 patients (2.9%)], and others [7 patients (3.4%)]. Of the 229 eyes, 54 (23.6%) received 4mg TA (Group T4), 69 (30.1%), 2mg TA (Group T2), and 106 (46.3%), 0.5mg ranibizumab (Group R). Mean axial eye length of all study eyes was  $22.9 \pm 1.1$ mm (range: 19.8-26.8mm). Of the 229 eyes 150 (65.5%) were phakic, 79 (34.5%) pseudophakic. Mean axial length had no difference in each group. However, the number of pseudophakic eyes were significantly more in Group T4 compared to Group T2 and Group R. Immediate post-injection IOP was significantly higher in Group T4 and Group R when compared to Group T2 ( $P < 0.001$  and  $P < 0.001$ , respectively). There was no statistically significant difference between the Group T4 and Group R ( $P > 0.05$ ). When pre-injection and post-injection IOP was compared in each group separately, IOP rise was significant in Group T4 and Group R ( $P < 0.001$  and  $P < 0.001$ , respectively) but not in Group T2 ( $P > 0.05$ , Table 1).

When all study eyes considered, IOP of 101 eyes (44.1%) were > 25mmHg, 90 eyes (39.3%) were  $\geq 30$ mmHg immediately after the injection. IOP tends to drop rapidly and only five eyes (2.2%) had IOP > 25mmHg while three eyes

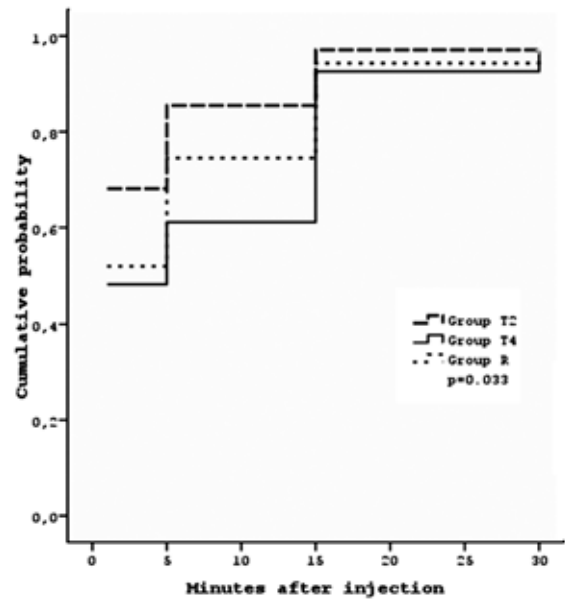


Figure 1 Cumulative probability with time for IOP to return to 25mmHg or less.

Table 1 Axial length, lens status and IOP

|                         | [ mean $\pm$ SD, n(%) ]      |                 |                              |
|-------------------------|------------------------------|-----------------|------------------------------|
|                         | Group T4                     | Group T2        | Group R                      |
| Eyes                    | 54 (23.6)                    | 69 (30.1)       | 106 (46.3)                   |
| Axial length (mm)       | 22.7 $\pm$ 1.2               | 23.0 $\pm$ 1.0  | 23.0 $\pm$ 1.0               |
| Lens status             |                              |                 |                              |
| Pseudophakic            | 44 (81.5) <sup>d</sup>       | 11 (15.9)       | 24 (22.6)                    |
| Phakic                  | 10 (18.5)                    | 58 (84.1)       | 82 (77.4)                    |
| IOP (mmHg)              |                              |                 |                              |
| Before injection        | 15.4 $\pm$ 2.7               | 15.8 $\pm$ 2.5  | 14.9 $\pm$ 2.4               |
| Just after injection    | 30.2 $\pm$ 18.9 <sup>b</sup> | 18.9 $\pm$ 13.6 | 28.0 $\pm$ 14.6 <sup>b</sup> |
| >25mmHg after injection |                              |                 |                              |
| immediately             | 28 (51.9)                    | 22 (31.9)       | 51 (48.1)                    |
| at 5 min                | 21 (38.9)                    | 10 (14.5)       | 27 (25.5)                    |
| at 15 min               | 4 (7.4)                      | 2 (2.9)         | 6 (5.7)                      |
| at 30 min               | 1 (1.9)                      | 2 (2.9)         | 2 (1.9)                      |

<sup>b</sup> $P < 0.001$  vs Before injection; <sup>d</sup> $P < 0.001$  vs Group T2, Group R.

Table 2 Vitreous reflux and its relationship to immediate IOP rise

|  | mean $\pm$ SD               |                             |                              |
|--|-----------------------------|-----------------------------|------------------------------|
|  | Group T4                    | Group T2                    | Group R                      |
| VR n (%)                               | 34 (68.5)                   | 56 (81.2)                   | 59 (55.7)                    |
| IOP in eyes with VR just               |                             |                             |                              |
| After injection (mmHg)                 | 21.4 $\pm$ 16.1             | 14.8 $\pm$ 10.9             | 19.7 $\pm$ 11.3              |
| IOP in eyes                            |                             |                             |                              |
| Without VR just after injection (mmHg) | 49.3 $\pm$ 6.0 <sup>b</sup> | 36.8 $\pm$ 9.1 <sup>b</sup> | 38.4 $\pm$ 11.2 <sup>b</sup> |

VR: vitreous reflux <sup>b</sup> $P < 0.001$  vs with vitreous reflux.

(1.3%)  $\geq 30$ mmHg at the 30<sup>th</sup> minutes (Table 1). At the second hour there was only a single eye still having IOP greater than 25mmHg. Most notably, this patient had primary open angle glaucoma. Figure 1 shows the cumulative probability with time for IOP to lower under 26mmHg. Overall, vitreous reflux was present in 149 eyes (65.1%). Absence of vitreous reflux seems to be a major factor for immediate IOP rise as IOP was significantly higher in eyes without vitreous reflux when compared to those with vitreous reflux for each subgroup ( $P < 0.001$ , Table 2).

In the multivariate logistic regression analysis, we investigated the association of the injected drug, vitreous reflux, lens status and axial eye length with high immediate post-injection IOP (IOP > 25mmHg). Vitreous reflux was the principal factor affecting the IOP rise immediately after the injection (odds ratio = 24.3,  $P < 0.001$ ). Intravitreal 4mg TA injection had a statistically significant effect on immediate IOP rise when compared to 2mg TA (odds ratio = 3.6,  $P = 0.021$ ). There was no difference between the ranibizumab injection and 2mg TA ( $P = 0.841$ ). Lens status (phakic or pseudophakic) and axial eye length were not found to be significant factors in our model ( $P = 0.112$  and  $P = 0.785$ , respectively). As there was only 6 eyes (2.6%) with preexisting glaucoma, we could not analyze the effect of glaucoma in this model. All six eyes with preexisting glaucoma had an increase in IOP immediately after the injection (29.0mmHg, 32.0mmHg, 40.0mmHg, 44.0mmHg, 44.0mmHg and 52.0mmHg). However, within 30 minutes after the injection, all IOP levels returned to normal level except one. No intraoperative complications related to injection was observed. None of the eyes required anterior chamber paracentesis.

#### DISCUSSION

Intravitreal injection of any drug may induce intraocular volume increase and therefore IOP rise is a strong possibility after any intravitreal drug injection. Although acute IOP spike is mostly transient it still may have a negative effect on ocular circulation as high IOP may compromise the optic nerve head and/or central retinal artery blood flow and hinder axonal transport. Eyes with prior glaucomatous optic nerve damage may be even more susceptible to pressure induced damage. In heavy daily routine IOP checks can not be employed in most clinics immediately after any intravitreal drug injection. We feel that it is meaningful to compare the short-term IOP changes immediately after the intravitreal injection of 2mg TA, 4mg TA and 0.5mg ranibizumab and look for the risk factors. In our study, IOP elevated immediately after the intravitreal injection in 44% of eyes, but in most of the eyes IOP returned to its normal level within 30 minutes of injection.

Numerous prospective studies investigated that the various aspects of short-term IOP changes occurring immediately after the intravitreal injection of TA and various anti-VEGF agents. In this study, we demonstrated that if vitreous reflux did not occur it was very likely that IOP would rise immediately after any drug injection. Supporting our results Benz *et al*<sup>[8]</sup> found that eyes without vitreous reflux have a tendency for IOP > 25mmHg at 30 minutes after injection when compared to eyes with vitreous reflux. Sharei *et al*<sup>[15]</sup> also pointed out that eyes without a subconjunctival reflux had a higher increase in IOP than those with any amount of reflux.

We evaluated two different doses of TA in the present study and to the best of our knowledge early IOP rise was not compared previously. As anticipated, the risk of IOP elevation was higher in eyes receiving 4mg TA when compared to 2mg TA. This difference is logical as volume of 2mg TA is

0.05mL in contrast to volume of 4mg (0.1mL) TA. Shorter axial eye length may be a risk factor for immediate IOP rise after the intravitreal injection. Eyes with short axial length have smaller intraocular volume, thus even the same volume may induce more IOP rise than those with longer axial length. However, we did not show any effect of axial length on IOP. Kotliar *et al*<sup>[14]</sup> evaluated IOP changes with Schi tz tonometer immediately after the intravitreal injection of 4mg (0.1mL) TA in 22 patients. All patients in their study group had IOP > 35mmHg immediately after the injection. Interestingly, they observed vitreous reflux only in one eye and all eyes but one underwent paracentesis to overcome IOP rise. They also detected that eyes with shorter axial eye length had higher IOP immediately after the injection. Gismondi *et al*<sup>[11]</sup> assessed the effect of axial eye length on IOP change immediately after the intravitreal injection of ranibizumab in 54 eyes. They found that IOP tends to be higher in eyes with short axial length.

Lens status may also affect the immediate IOP change after intravitreal injection. It is well-known that after phacoemulsification and IOL implantation anterior chamber deepens, angle widens and as a consequence aqueous outflow increases<sup>[17]</sup>. Thus, pseudophakic eyes are less prone to develop IOP elevation after intravitreal injection when compared to phakic eyes. In our study, we found that lens status did not have any effect on immediate IOP after the injection. Supporting our results, Gismondi *et al*<sup>[11]</sup> also found no difference in IOP between phakic and pseudophakic eyes after intravitreal injection of ranibizumab. Kerimoglu *et al*<sup>[9]</sup> evaluated IOP changes in eyes receiving intravitreal 4mg TA without vitreous reflux. Three minutes after the injection, all eyes had IOP > 30mmHg. However, 38.6% of phakic patients and none of the pseudophakic patients had IOP > 30mmHg 10 minutes after the injection. All of the study eyes had IOP < 30mmHg 20 minutes after the injection. They concluded that in eyes receiving intravitreal TA without vitreous reflux, IOP returned to safe levels more quickly in pseudophakic eyes than in phakic eyes.

Preexisting glaucoma may also be a risk factor for immediate IOP rise after the injection. There are conflicting results on this issue. In some studies<sup>[18,19]</sup>, it was showed that glaucoma was a risk factor for IOP elevation. However in some studies<sup>[13,20]</sup> it was found that preexisting glaucoma was not a risk factor. In our study, we could not analyze this, as there was only 6 eyes with the history of glaucoma. But when we evaluated the IOP course in these eyes, we noted that all of them had a significant IOP rise immediately after the injection. However, within 30 minutes after injection, IOP returned to normal level except one. In conclusion, IOP can show remarkable increase immediately after the intravitreal injection of 0.5mg ranibizumab, 4 and 2mg TA. However, in most eyes it returns to its normal level within 30 minutes after the injection. 2mg TA induces less pressure spike than 4mg TA due to smaller injected volume. Absence of vitreous reflux at the injection site is the most important predicting factor for

immediate IOP rise after any injection. Monitoring of post-injection IOP in every case may be time consuming and not practical, but, it is advisable to check the IOP when there no vitreous reflux is observed following any injection.

#### REFERENCES

- 1 Wu H, Chen TC. The effects of intravitreal ophthalmic medications on intraocular pressure. *Semin Ophthalmol* 2009;24(2):100-105
- 2 Hauser D, Bukelman A, Pokroy R, Katz H, Len A, Thein R, Parness-Yossifon R, Pollack A. Intravitreal triamcinolone for diabetic macular edema: comparison of 1, 2, and 4mg. *Retina* 2008;28(6):825-830
- 3 Jonas JB, Degenring RF, Kreissig I, Akkoyun I, Kampeter BA. Intraocular pressure elevation after intravitreal triamcinolone acetonide injection. *Ophthalmology* 2005;112(4):593-598
- 4 Gillies MC, Simpson JM, Billson FA, Luo W, Penfold P, Chua W, Mitchell P, Zhu M, Hunyor AB. Safety of an intravitreal injection of triamcinolone: results from a randomized clinical trial. *Arch Ophthalmol* 2004;122(3):336-340
- 5 Vasconcelos-Santos DV, Nehemy PG, Schachat AP, Nehemy MB. Secondary ocular hypertension after intravitreal injection of 4mg of triamcinolone acetonide: incidence and risk factors. *Retina* 2008;28(4):573-580
- 6 Rhee DJ, Peck RE, Belmont J, Martidis A, Liu M, Chang J, Fontanarosa J, Moster MR. Intraocular pressure alterations following intravitreal triamcinolone acetonide. *Br J Ophthalmol* 2006;90(8):999-1003
- 7 Inatani M, Iwao K, Kawaji T, Hirano Y, Ogura Y, Hirooka K, Shiraga F, Nakanishi Y, Yamamoto H, Negi A, Shimonagano Y, Sakamoto T, Shima C, Matsumura M, Tanihara H. Intraocular pressure elevation after injection of triamcinolone acetonide: a multicenter retrospective case-control study. *Am J Ophthalmol* 2008;145(4):676-681
- 8 Benz MS, Albin TA, Holz ER, Lakhanpal RR, Westfall AC, Iyer MN, Carvounis PE. Short-term course of intraocular pressure after intravitreal injection of triamcinolone acetonide. *Ophthalmology* 2006;113(7):1174-1178
- 9 Kerimoglu H, Ozturk BT, Bozkurt B, Okka M, Okudan S. Does lens status affect the course of early intraocular pressure and anterior chamber changes after intravitreal injection? *Acta Ophthalmol* 2011;89(2):138-142
- 10 Falkenstein IA, Cheng L, Freeman WR. Changes of intraocular pressure after intravitreal injection of bevacizumab (Avastin). *Retina* 2007;27(8):1044-1047
- 11 Gismondi M, Salati C, Salvat ML, Zeppieri M, Brusini P. Short-term effect of intravitreal injection of ranibizumab (Lucentis) on intraocular pressure. *J Glaucoma* 2009;18(9):658-661
- 12 Dwinger MC, Pieper-Bodeewes I, Eter N, Holz FG. Variations in intraocular pressure (IOP) and necessity for paracentesis following intravitreal triamcinolone injection. *Klin Monbl Augenheilkd* 2005;222(8):638-642
- 13 Hollands H, Wong J, Bruen R, Campbell RJ, Sharma S, Gale J. Short-term intraocular pressure changes after intravitreal injection of bevacizumab. *Can J Ophthalmol* 2007;42(6):807-811
- 14 Kotliar K, Maier M, Bauer S, Feucht N, Lohmann C, Lanzl I. Effect of intravitreal injections and volume changes on intraocular pressure:

clinical results and biomechanical model. *Acta Ophthalmol Scand* 2007;85(7):777-781

15 Sharei V, H hn F, K hler T, Hattenbach LO, Mirshahi A. Course of intraocular pressure after intravitreal injection of 0.05 mL ranibizumab (Lucentis). *Eur J Ophthalmol* 2010;20(1):174-179

16 Rosenfeld PJ, Brown DM, Heier JS, Boyer DS, Kaiser PK, Chung CY, Kim RY; MARINA Study Group. Ranibizumab for neovascular age-related macular degeneration. *N Engl J Med* 2006;355(14):1419-1431

17 Cho YK. Early intraocular pressure and anterior chamber depth changes after phacoemulsification and intraocular lens implantation in nonglaucomatous eyes: comparison of groups stratified by axial length. *J Cataract Refract Surg* 2008;34(7):1104-1109

18 Kim JE, Mantravadi AV, Hur EY, Covert DJ. Short-term intraocular pressure changes immediately after intravitreal injections of anti vascular endothelial growth factor agents. *Am J Ophthalmol* 2008;146(6):930-934

19 Bakri SJ, Pulido JS, McCannel CA, Hodge DO, Diehl N, Hillemeier J. Immediate intraocular pressure changes following intravitreal injections of triamcinolone, pegaptanib, and bevacizumab. *Eye* 2009;23(1):181-185

20 Frenkel REP, Mani L, Toler AR, Frenkel MPC. Intraocular pressure effects of pegaptanib (Macugen) injections in patients with and without glaucoma. *Am J Ophthalmol* 2007;143(6):1034-1035

## 兰尼单抗和曲安奈德玻璃体内注射后眼压的即时升高

Gul Arikan, Ali Osman Saatci, Ferit Hakan Oner

(作者单位:土耳其,伊兹密尔,Dokuz Eylul 大学医学院眼科)

通讯作者:Gul Arikan. gulozdenarikan@gmail.com

### 摘要

**目的:**前瞻性评估玻璃体腔内注射兰尼单抗、2 和 4mg 曲安奈德(TA)后眼压(IOP)的即时变化。

**方法:**接受玻璃体腔内注射 0.1mL(4mg)曲安奈德(T4组),0.05mL(2mg)TA(T2组)和 0.05mL(0.5mg)兰尼单抗(R组)的患者组成研究群体。总体而言,205 例 229 眼接受注射。T4 组 54 眼(23.6%),T2 组 69 眼(30.1%),及 R 组 106 眼(46.3%)。如果注射后即时眼压 <26mmHg 就不行进一步的测量。如果眼压 ≥26mmHg,就在 5,15 和 30min 后重新测量眼压,直到读数 <26mmHg。

**结果:**注射后即时眼压,T4 组 28 眼(51.9%),T2 组 22 眼(31.9%)和 R 组 51 眼(48.1%)超过 25mmHg。到 30min 时,T4 组 1 眼(1.9%),T2 组 2 眼(2.9%)和 R 组 2 眼(1.9%),眼压超过 25mmHg。T4 组和 R 组注射后即时眼压显著高于 T2 组( $P < 0.01$  和  $P < 0.01$ )。各组中无玻璃体回流眼的眼压显著高于有玻璃体回流眼( $P < 0.01$ )。

**结论:**玻璃体腔内注射 2 或 4mg 曲安奈德和 0.5mg 的兰尼单抗后眼压可能会立即显著提高。无玻璃体回流是注射后眼压即时上升的最重要的预测因素。

**关键词:**抗 VEGF 药物;青光眼;眼压;玻璃体腔内注射;类固醇