

Autogenous conjunctival flap covering in treatment of deep corneal ulcer

Yu-Zhao Sun, Xian-Jie Liu, Xue Bai, Na Cai

Department of Ophthalmology, the First Clinical College of China Medical University, China Medical University Eye Center, Shenyang 110001, Liaoning Province, China

Correspondence to: Yu - Zhao Sun. Department of Ophthalmology, the First Clinical College of China Medical University, China Medical University Eye Center, Shenyang 110001, Liaoning Province, China. sunyz91667@sina.com

Received: 2012-05-14 Accepted: 2012-09-14

Abstract

• **AIM:** To evaluate the therapeutic effect of autogenous conjunctival flap covering on deep corneal ulcer.

• **METHODS:** The data of 14 eyes of 14 patients with deep corneal ulcer who underwent autogenous conjunctival flap covering in China Medical University Eye Center from May 2010 to October 2011 were retrospectively analyzed. There were 6 cases of viral keratitis, 7 cases of fungal keratitis, 1 case of bacterial keratitis. Patients of fungal keratitis were rinsed with fluconazole, patients of viral or bacterial were rinsed with gentamycin before conjunctival flap covering. Part or whole conjunctival flap covering were done according to the size of corneal ulcer. Antibiotics were used for 4 weeks according to different keratitis post-operation. All the patients were followed-up 10-18 months postoperation, corneal ulceration repairation, conjunctival flap survival situation, complications and visual acuity were observed.

• **RESULTS:** Corneal ulcer in all cases cured by once surgery (100%). Autogenous conjunctival flap survived and stucked with ulcer closely 2 weeks post-operation (85.71%), except one case conjunctival flap fell off. The another 13 patients conjunctival flaps became transparent and retracted in different degree in the later following-up time. One recurred case of fungal keratitis three months post-operation was cured by dropping natamycin for 3 weeks. One case complicated with shallow anterior chamber three months post-operation. One case complicated with descemetocele ten months postoperation. One case complicated with glaucoma one year postoperation. All the patients preserved the globe, but vision improved unobviously.

• **CONCLUSION:** Autogenous conjunctival flap covering is effective for deep corneal ulcer. But long-term postoperative observation has certain complications.

• **KEYWORDS:** conjunctival flap covering; corneal ulcer

DOI:10.3969/j.issn.1672-5123.2012.10.01

Citation: Sun YZ, Liu XJ, Bai X, Cai N. Autogenous conjunctival

flap covering in treatment of deep corneal ulcer. *Guoji Yanke Zazhi (Int Eye Sci)* 2012;12(10):1819-1822

INTRODUCTION

Persistent bacterial, fungal or viral infections and inappropriate treatment always lead to deep corneal ulcers, even corneal perforation. Currently the main clinical treatment for corneal ulcers include amniotic membrane grafting surgery^[1], conjunctival flap covering, and corneal transplantation^[2]. Amniotic membrane grafting can provide a smooth growth bracket and some anti-inflammatory factors for corneal ulcer^[3], but amnion tissue is too soft and fragile to provide effective mechanical protection for deeper ulcer^[4]. Corneal transplantation could cure the corneal ulcer completely, but the less quantity of donor corneas limited the development. However, conjunctival flap possesses blood supply and certain tenacity, which is helpful to healing deep ulcers and providing a strong tension stress to create conditions for the second phase of corneal transplantation^[5].

In this study, we retrospectively analyzed 14 cases of deep corneal ulcer who underwent conjunctival flap covering in China Medical University Eye Center from May 2010 to October 2011, and evaluated the therapeutic effect of conjunctival flap covering on deep corneal ulcer.

SUBJECTS AND METHODS

Subjects Altogether 14 eyes of 14 cases including 8 males and 6 females aging from 36 to 73 (average 56.21±9.55) were retrospectively analyzed. 14 patients, including 6 viral keratitis, 7 cases of refractory fungal keratitis and 1 case of bacterial keratitis secondary to corneal foreign body, were diagnosed by direct light microscopy of corneal scraping specimens and medical history. Medical history of all cases were more than 1 month. Depth of corneal ulcers in all the cases more than 2/3 corneal thickness (CT), including 3 cases deep to 3/4 CT, 5 cases deep to Descemet's membrane and 6 cases with minute corneal perforation (diameter less than 1.0mm). Among the 5 patients with corneal perforation, one case complicated with choroidal detachment. The size of all the corneal ulcers range from 1.5mm to 7mm. The corneal ulcers in 11 cases located in center, 3 cases located in peripheral corneal. One viral keratitis and one fungal keratitis complicated with 2mm hypopyon. Pre-operation, vision acuity in all cases ranged from 0.02 to 0.15^[6], except one case with peripheral smaller ulcer was 0.8.

Methods

Preoperation Twelve cases had formed the corneal deep

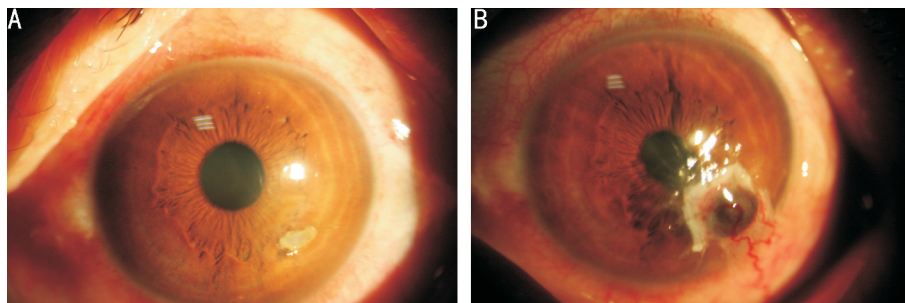


Figure 1 Case of bacterial keratitis secondary to corneal foreign body A: Preoperation. Diameter of ulcers were 1mm×2mm, deep to Descemet's membrane with minute corneal perforation at local. Vision acuity was 0.8; B: One year postoperation. Liguliform conjunctival flap for peripheral smaller ulcer. Complicated with glaucoma, for the anterior synechiae of iris corresponding to the ulcer.

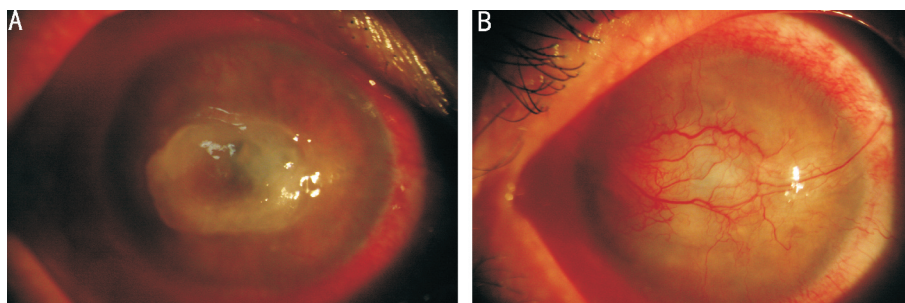


Figure 2 Case of viral keratitis A: Preoperation. Diameter of ulcers were 4mm×6mm, deep to Descemet's membrane. Vision acuity was 0.02; B: One year postoperation. Bridge form conjunctival flap. Vision acuity was 0.02.

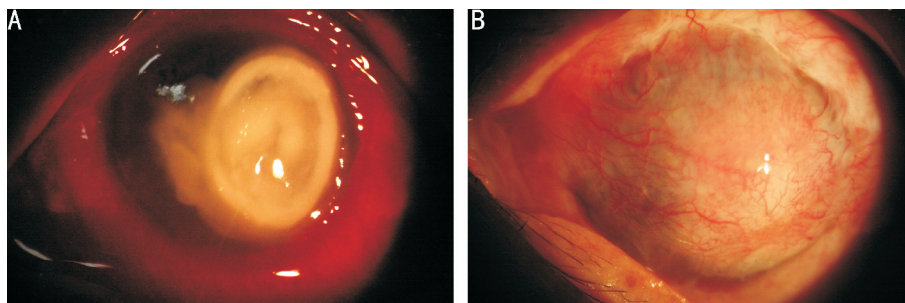


Figure 3 Case of fungal keratitis A: Preoperation. Diameter of ulcers were 5mm×9mm, deep to 3/4 CT. Vision acuity was 0.02; B: One year postoperation. Whole conjunctival flap. Vision acuity was 0.02.

ulcer when arrived at our hospital and undergone the emergency surgery. Only levofloxacin eyedrop was used for 3 times before operation in these cases. Another two cases were fungal keratitis, treated by natamycin (six times a day) and levofloxacin (four times a day) for four weeks, the ulcer became larger and deeper.

Operation Before conjunctival flap covering, cut necrotic tissue in ulcer and corneal epithelium beyond ulcer 1mm. For patients of fungal keratitis, corneal ulcers were cleaned thoroughly with 0.2mg/mL fluconazole (Pfizer, 200mg/100mL), while patients of viral or bacterial keratitis, corneal ulcers were cleaned thoroughly with gentamycin (OuYi Pharmaceutical Limited Company, 0.8%). 2% lidocaine injection with 1mL syringe was extracted and injected into the nearest point of focus under bulbar conjunctiva to make conjunctiva uplift. Part or whole conjunctival flap covering were done according to the size and location of corneal ulcer; liguliform conjunctival flap for peripheral smaller ulcer (diameter of

ulcers were less than 4mm) (Figure 1), bridge form conjunctival flap for central smaller ulcer (diameter of ulcers were 3-6mm) (Figure 2), and whole conjunctival flap for central larger ulcer (diameter of ulcers were large than 7mm) (Figure 3). The diameter or width of conjunctival flap was 1mm larger than the ulcer. The liguliform and bridge form conjunctival flap were designed uneven; the flap that covered above the deepest part of the ulcer was thickened by attaching part of tenon sac, while the flap that covered above the healthy cornea next to the ulcer was thin. The whole conjunctival flap covering were done as usual. Discontinuous sutured the flap onto the surface of cornea by 10-0 nylon wire. When finished suture, subconjunctival injected 1ml fluconazole (2mg/mL) for fungal keratitis, and dropped ganciclovir or ofloxacin eye gel for viral or bacterial keratitis. Pressure dressing for all the patients postoperation.

Postoperative management All the patients maintained pressure dressing for 2 days. Eye drops were applied on the

third day postoperation. For fungal keratitis, natamycin eyedrops was used, four times a day, sustained for 4 weeks; for bacterial keratitis, levofloxacin eyedrops was used, four times a day, sustained for 4 weeks; and for viral keratitis, ganciclovir eyedrop was used, four times a day, sustained for 2 weeks, and two times a day, sustained for another 2 weeks. Levofloxacin eyedrops was also used for all the fungal and viral keratitis patients, four times a day, sustained for 2 weeks. To take out the 10-0 nylon wire 14 days postoperation.

RESULTS

Ulcer Healing Corneal ulcer in all cases cured by once surgery (100%). 3 corneal ulcers in cases who undergone liguliform conjunctival flap covering and 5 corneal ulcers in cases who undergone bridge form conjunctival flap covering cured completely 2 weeks postoperation; 4 corneal ulcers in cases who undergone wider bridge form conjunctival flap covering and 2 corneal ulcers in cases who undergone whole conjunctival flap covering cured completely 3 weeks postoperation.

Conjunctival Flap Survival Three cases undergone liguliform conjunctival flap covering and 9 cases undergone bridge form conjunctival flap covering, and 2 cases undergone whole conjunctival flap covering.

All of the conjunctival flaps survived and stucked with ulcer closely 2 weeks post-operation (85.71%), except one case bridge form conjunctival flap fell off. In the following up time, the other 13 patients' conjunctival flaps became thin and transparent, and retracted in different degree.

Visual Acuity The postoperative visual acuity (0.04-0.2) of 13 patients, including 11 cases with central corneal ulcer and 2 cases with peripheral ulcer complicated with infiltration of the central corneal stroma. Compared with the preoperative vision (0.02 to 0.15), does not change significantly. One case with peripheral smaller deep ulcer (diameter of ulcers were 1.5mm, deep to Descemet's membrane) had the same visual acuity as preoperation of 0.8.

Complications

Short-term complications(0.5-3 months postoperation) One recurred case of fungal keratitis three months post-operation, shown as superficial corneal ulcer next to the original ulcer, was cured by dropping natamycin (qid) for 3 weeks. One case with corneal perforation and choroidal detachment preoperation, three months postoperation, sustained choroidal detachment and complicated with shallow anterior chamber, without recurring of ulcer and conjunctival flaps felling off.

Long-term complications(6 months later) Ten months postoperation, one case with peripheral deep ulcer (diameter of ulcers were 3mm, deep to Descemet's membrane) occurred descemetocele at original ulcer area for the obvious retraction of the conjunctival flap and underwent penetrating keratoplasty. One year postoperation, one case with peripheral smaller deep ulcer (diameter of ulcers were 1mm×2mm, deep to Descemet's membrane) preoperation complicated with glaucoma (7.14%), for the anterior synechiae of iris corresponding to the ulcer (Figure 1B).

DISCUSSION

Deep corneal ulcers caused by infection or trauma were series disease. If there were no effective treatment applied, corneal perforation or even eyeball loss may occurred. Conjunctival flap covering is a classic surgical treatment for corneal ulcers^[7], and still has the widespread application in clinical practice. In this study, 14 patients with deep corneal ulcer who underwent autogenous conjunctival flap covering in China Medical University Eye Center from May 2010 to May 2012 were retrospectively analyzed.

Our results shown that conjunctival flap covering curing all the corneal ulcers in 14 cases (100%), including the corneal perforation cases and the fungal keratitis cases who complicated large and deep ulcer (diameter of 8mm, deep to 3/4 CT). The key reason for good therapeutic effect of conjunctival flap covering is that conjunctival flap is rich in blood and lymphatic vessels which can transport conjunctival nutrient substance including cell component, growth factors and immune globulin to the corneal surface and improve their resistance to infection, meanwhile a rich blood supply can also reduce the local micro-environment proinflammatory mediators and protease to facilitate the inflammatory reaction subsided the ulcer healing^[8,9].

The conjunctival flap covering is a simple surgery for corneal ulcer, but the making of conjunctival flap may influence the effect of the operation. The thinner conjunctival flap is flexibility, but the toughness is weaker; the thicker conjunctival flap with part of tenon sac is strong, but less elastic. Comprehensive considering of the two factors, we designed a specific bridge form conjunctival flap for the 14 cases with deep corneal ulcers: In the deepest ulcer area applied thicker conjunctival flap adhesion with part of tenon sac, while in the shallow ulcer area and health corneal surface applied the thinner conjunctival flap. This kind of flap can not only avail the restoration of the deep ulcer, but also can reduce the tension of conjunctival flap and avoid conjunctival flap retreat or fall off early. So in 14 cases, conjunctival flap of 13 cases (85.71%) stucked with ulcer closely and survived. Although 14 cases of deep corneal ulceration preserved the eyes by autogenous conjunctive covering, but for the opacity of conjunctival organization, improvement of visual acuity was not obvious.

In addition, because of the weaker force of conjunctival organization compared with corneal organization, although the repairment of the cornea deep ulcer, but corneal organization of original lesions area was still very weak. In the long term follow-up, we find that conjunctival flap retreat is easy to cause descemetocele in the original ulcer area.

All in all, conjunctival flap covering could repair deep ulcer effectively and save the eye in emergency situations. However, in order to get better treatment effect for deep corneal ulcer, the corneal transplantation should be taken earlier post conjunctival flap covering.

REFERENCES

1 Fuchsluger T, Tuerkeli E, Westekemper H, Esser J, Steuhl KP,

- Meller D. Rate of epithelialisation and re-operations in corneal ulcers treated with amniotic membrane transplantation combined with betulinum toxin-induced ptosis. *Graefes Arch Clin Exp Ophthalmol* 2007;245(7):955-964
- 2 Iyer SA, Tuli SS, Wagoner RC. Fungal keratitis: emerging trends and treatment outcomes. *Eye Contact Lens* 2006;32(6):267-271
- 3 Yildiz EH, Nurozler AB, Ozkan Aksoy N, Altiparmak UE, Onat M, Karaguzel H. Amniotic membrane transplantation: indications and results. *Eur J Ophthalmol* 2008;18(5):685-690
- 4 Gris O, Güell JL, Lopez-Navidad A, Caballero F, Del Campo Z. Application of the amniotic membrane in ocular surface pathology. *Ann Transplant* 1999;4(3-4):82-84
- 5 Shi W, Wang T, Xie L, Li S, Gao H, Liu J, Li H. Risk factors, clinical features, and outcomes of recurrent fungal keratitis after corneal transplantation. *Ophthalmology* 2010;117(5):890-896
- 6 Mutoh T, Ishikawa I, Matsumoto Y, Chikuda M. A retrospective study of nine cases of *Acanthamoeba* keratitis. *Clin Ophthalmol* 2010;4:1189-1192
- 7 Au L, Wechsler D, Spencer F, Fenerty C. Outcome of bleb revision using scleral patch graft and conjunctival advancement. *J Glaucoma* 2009;18(4):331-335
- 8 Khodadoust A, Quinter AP. Microsurgical approach to the conjunctival flap. *Arch Ophthalmol* 2003;121(8):1189-1193
- 9 Zhou QH, Long XH, Zhu XH. Improved conjunctival transplantation for corneal ulcer. *J Cent South Univ (Med Sci)* 2010;35(8):814-818

自体结膜瓣覆盖术治疗深层角膜溃疡

孙昱昭,刘贤洁,白雪,才娜

(作者单位:110001 中国辽宁省沈阳市,中国医科大学附属第一医院眼科 中国医科大学眼科中心)

作者简介:孙昱昭,女,博士,副主任医师,研究方向:眼表疾病的临床研究及眼底病的基础研究。

通讯作者:孙昱昭. sunyz91667@sina.com

摘要

目的:评价自体结膜瓣覆盖术对深层角膜溃疡的治疗效果。

方法:分析于2010-05/2011-10在中国医科大学眼科中心行自体结膜瓣覆盖术的14例深层角膜溃疡患者的预后。14例患者中包括6例病毒性角膜炎患者,7例真菌性角膜炎患者和1例细菌性角膜炎患者。进行结膜瓣遮盖术前,真菌性角膜炎患者用氟康唑冲洗角膜溃疡,细菌和病毒性角膜炎患者用庆大霉素液体冲洗角膜溃疡。根据角膜溃疡大小不同采取部分或全部结膜瓣覆盖术。术后根据不同的角膜炎类型使用不同的抗菌素共4wk。所有的患者术后均随访观察结膜瓣存活情况、并发症及视力恢复情况,随访时间达10~18mo。

结果:所有患者经历1次手术后均痊愈(治愈率为100%)。除1例结膜瓣脱落外,其余患者术后2wk自体结膜瓣均存活并与角膜溃疡处贴附紧密(85.71%)。这13例患者的结膜瓣在随访观察期间内逐渐变得透明并发生了不同程度的退缩。1例真菌性角膜炎患者在术后3mo时角膜炎复发,在使用那他霉素眼液点眼3wk后痊愈。1例患者术后3mo时并发浅前房。1例患者术后10mo并发后弹力层膨出。1例患者术后1a并发了青光眼。所有的患者成功地保留了眼球,但视力提高不明显。

结论:自体结膜瓣覆盖术治疗深层角膜溃疡有效,但是术后长期观察存在一定的并发症。

关键词:结膜瓣覆盖;角膜溃疡