

芥子气兔角膜损伤和角膜中央厚度变化

刘菲,王菲,刘芳

作者单位:(261021)中国山东省潍坊市,解放军第89医院眼科
作者简介:刘菲,毕业于潍坊医学院,硕士,副主任医师,副主任,
研究方向:眼前节。
通讯作者:刘菲. cigamw@163.com
收稿日期:2013-09-16 修回日期:2013-11-29

Corneal lesions on rabbits after exposure to mustard gas and variation of central corneal thickness

Fei Liu, Fei Wang, Fang Liu

Department of Ophthalmology, PLA No. 89 Hospital, Weifang 261021, Shandong Province, China

Correspondence to: Fei Liu. Department of Ophthalmology, PLA No. 89 Hospital, Weifang 261021, Shandong Province, China. cigamw@163.com

Received:2013-09-16 Accepted:2013-11-29

Abstract

• **AIM:** To observe the regrowth progress of corneal epithelium and the change of center thickness on rabbit corneal lesions after exposure to mustard gas.

• **METHODS:** Twenty rabbits (40 eyes) were divided into two groups randomly, the experimental group included 10 cases (10 right eyes), the control group included 10 cases (10 right eyes), and the left eyes were normal group. The corneas of the rabbits were contacted the liquid mustard gas 400 μ L/L (0.2mL) and 200 μ L/L (0.2mL) for 4min in the experimental group and the control group respectively. Then the corneal white light and photofluorography at were conducted at 1, 2, 3, 4, 5, 6d; 1, 2, 3wk; 1, 3mo and the corneal center thickness was measured respectively.

• **RESULTS:** The area of corneal epithelium lesions in experimental group degraded from IV to 0 after 1wk. The lesions were appeared as flake sample repeatedly in 2wk, 3wk, 1mo, delayed to healing. And that area in control group degraded from III to 0 after 1wk. The lesions were appeared as pinpoint sample in 2wk, 3wk, 1mo. The central corneal thickness of experimental group was obviously higher than that of the normal and control group in 1 - 6d. There was statistically significant difference between the two groups ($P < 0.05$). In 1wk -

1mo the difference of three group was not statistically significant ($P > 0.05$). In 3mo the experimental and control group were higher than the normal group, but the difference was not statistically significant ($P > 0.05$).

• **CONCLUSION:** Mustard gas of different concentrations can lead different level corneal lesion and corneal thickness change. The corneal epithelium remodeling change appears within 1wk and completely recover in 1mo after the direct corneal contact. Corneal thickness gets right in 3mo.

• **KEYWORDS:** mustard gas; rabbit; corneal lesions; corneal thickness

Citation: Liu F, Wang F, Liu F. Corneal lesions on rabbits after exposure to mustard gas and variation of central corneal thickness. *Guoji Yanke Zazhi(Int Eye Sci)* 2014;14(1):28-30

摘要

目的:观察芥子气兔角膜损伤病变发生发展过程中角膜上皮的愈合情况和角膜中央厚度的变化。

方法:设实验组10眼,对照组10眼,正常组20眼。实验组和对照组分别用浓度400 μ L/L(0.2mL)芥子气液和浓度200 μ L/L(0.2mL)芥子气液接触角膜4min,于1,2,3,4,5,6d;1,2,3wk;1,3mo行角膜白光及荧光照相,并测量角膜中央厚度。

结果:实验组的角膜上皮损伤面积1wk内由IV级减小为0级,第2,3wk;1mo角膜上皮反复发生点片状剥脱。对照组的角膜上皮损伤面积3d内由III级减小为0级,第2,3wk;1mo角膜上皮仅发生针尖样的缺损。第3mo实验组和对照组角膜上皮均恢复光滑平面。角膜中央厚度第1~6d实验组明显高于对照组和正常组,差异有统计学意义($P < 0.05$)。第1wk~1mo实验组、对照组和正常组相比,差异无统计学意义。第3mo实验组、对照组高于正常组,但差异无统计学意义。

结论:不同浓度的芥子气液可致兔角膜上皮不同程度的损伤和角膜厚度变化,1wk内出现一过性角膜上皮层的重塑改变,1mo内完全恢复。3mo内角膜厚度基本恢复正常。

关键词:芥子气;兔;角膜损伤;角膜厚度

DOI:10.3980/j.issn.1672-5123.2014.01.07

引用:刘菲,王菲,刘芳.芥子气兔角膜损伤和角膜中央厚度变化.国际眼科杂志2014;14(1):28-30

0 引言

芥子气是一种亲脂和烷化的化学糜烂性毒剂,可以液滴态、雾态、蒸汽态长期储存。战争状态可通过多途径中毒,穿透能力强,病程长,易导致迅速大量战斗减员和长期伤残^[1,2]。眼部的损伤主要是出现严重畏光,出现结膜炎、视力模糊、畏光、暂时失明等症状。芥子气主要损伤角膜,可造成严重的后遗症,影响视功能。本研究采用不同浓度芥子气液致兔角膜损伤,观察其致伤程度,为平时人角膜芥子气损伤的病情变化提供更多参考资料依据。

1 材料和方法

1.1 材料 选购大小体质量相近的新西兰白兔 20 只,饲养方式保持原状。分实验组 10 只右眼,对照组 10 只右眼,对侧眼为正常组。

1.2 方法 兔实验模型建立:盐酸氯胺酮耳缘静脉注射麻醉,将一内径 8mm 长约 10cm 的玻璃管垂直置于兔右眼角膜中央,稍加压。然后实验组和对照组分别将浓度为 400 μ L/L 和 200 μ L/L 芥子气溶液(芥子气+丙二醇) 0.2mL 注入玻璃管内,使液体浸没角膜顶端 1mm 以上,4min 后立即用生理盐水连续冲洗 1min。芥子气液(浓度>90%)由解放军某部队提供,1,2-丙二醇溶液由天津致远化学有限公司提供。根据实验分组,于 1,2,3,4,5,6d;1,2,3wk;1,3mo 行角膜白光及荧光照相,并测量角膜中央厚度。角膜上皮损伤面积:0 级:无损伤或针尖样损伤;I 级: \leq 1 个象限;II 级: \leq 2 个象限;III 级: \leq 3 个象限;IV 级: \leq 4 个象限。

统计学分析:采用统计学软件 SPSS 17.0 建立数据库,通过两样本均数 *t* 检验进行分析, $P<0.05$ 为差异有统计学意义。

2 结果

2.1 角膜白光及荧光照相观察 兔角膜接触不同浓度的芥子气后 1d 可观察到角膜上皮的脱失及水肿,造成不同程度角膜上皮损伤(图 1)。实验组:角膜上皮损伤面积 1wk 内均由 IV 级减小为 0 级,第 2,3wk;1mo 角膜上皮反复发生点片状缺损,且延迟不愈。第 3mo 角膜上皮光滑平复。对照组:角膜上皮损伤面积 3d 内均由 III 级减小为 0 级,第 2,3wk;1mo 角膜上皮仅发生针尖样的缺损,且一般在 3d 内完全愈合。第 3mo 角膜上皮光滑平复。

2.2 角膜中央厚度 第 1,2,3,4,5,6d;1,2,3wk;1,3mo 测量角膜中央厚度进行比较(图 2)。第 1~6d 实验组明显高于对照组和正常组,差异有统计学意义($P<0.05$)。第 1wk~1mo 实验组、对照组和正常组相比,差异无统计学意义。第 3mo 实验组、对照组均高于正常组,但差异无统计学意义。

3 讨论

眼部是芥子气最易攻击的靶组织之一^[3]。本实验观察发现:浓度为 400 μ L/L 芥子气接触角膜 4min 可导致兔角膜中度损伤,主要表现为角膜上皮的损伤及基质层水肿。角膜上皮结构由桥粒、半桥粒连接于基底膜上。芥子

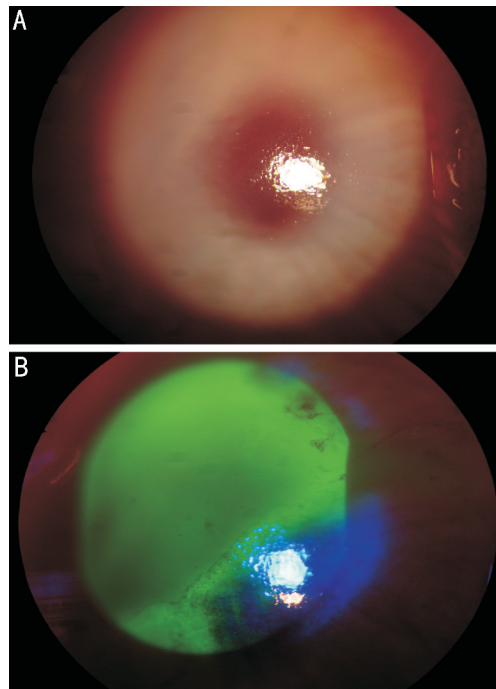


图 1 接触芥子气 1d 后观察兔角膜,可见角膜上皮脱失及基质层水肿 A:白光照相;B:荧光照相。

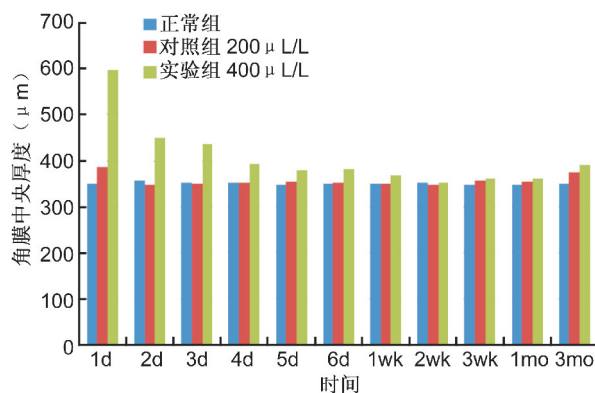


图 2 各组角膜中央厚度比较。

气角膜损伤不仅引起角膜上皮的急性剥脱且可导致基质层胶原疏松和成纤维细胞的减少,Javaidi 等^[4]报道观察到不同程度的角膜细胞丢失占 72%,归因于细胞内烷化剂的释放和氧化诱导剂的后期形成导致的角膜细胞遗传改变的表达^[5-8]。而且,这种细胞毒素可激活细胞凋亡通路^[9]和导致慢性进展的角膜细胞死亡。通过荧光素染色观察,我们发现浓度 400 μ L/L 芥子气比浓度 200 μ L/L 芥子气导致的角膜上皮的直接损伤要严重得多,面积损伤大,上皮脱落完全,恢复时间较长,而且急性恢复期后有一段长达 1mo 左右的时间反复发生角膜上皮的糜烂浸润,荧光素染色点片状或针尖状着色。芥子气角膜急性损伤后,上皮虽然能够快速修复,但角膜上皮反复发生糜烂浸润,说明兔角膜上皮细胞超微结构损伤是一种持续性损伤。

兔角膜与人角膜形态上有所差异,人中央角膜厚约 535 μ m,周边角膜厚约 657 μ m。人角膜周边比中央厚,而兔角膜均匀一致^[10,11]。因此,了解兔角膜解剖学和组织

形态学特征及与人角膜的差异性,对研究兔角膜芥子气损伤的模型有重要的指导意义。Kadar等^[12]使用浓度(370~420 $\mu\text{g/L}$)的芥子气接触兔眼2min,2~6h会出现眼睑肿胀、结膜充血、角膜腐蚀、炎细胞浸润,24~72h反应达到高峰。4h房水会发生炎细胞反应和氧化应激反应,28h反应缓解。通过动物实验角膜中央厚度比较,实验组角膜中央厚度由1d时 $596\pm 30\mu\text{m}$ 在2wk内全部恢复至正常范围,对照组在1wk内全部恢复至正常范围,一直到3mo都维持在一个稳定的状态,可以看到角膜基质层水肿、修复、增生的一个过程,从另一个方面证实芥子气角膜损伤不但伤及角膜上皮,而且角膜基质层也会受累。由此可见,芥子气可致角膜的侵蚀及炎症反应,引发角膜组织结构重塑改变^[13]。

目前,国内尚无芥子气对角膜损伤的厚度变化的相关报道,对于芥子气损伤后角膜炎的病程、临床特点、病理机制及医疗防护缺乏一个完整的认识,以后将有大量研究工作值得我们去深入探讨。

参考文献

- 1 Khateri S, Ghanei M, Keshavarz S, et al. Incidence of lung, eye, and skin lesions as late complications in 34,000 Iranians with wartime exposure to mustard agent. *J Occup Environ Med* 2003;45(11):1136-1143
- 2 Balali - Mood M, Hefazi M. The pharmacology, toxicology, and medical treatment of sulphur mustard poisoning. *Fundam Clin Pharmacol* 2005;19(6):297-315
- 3 Bhattacharya SK, Hom GG, Fernandez C, et al. Ocular effects of exposure to industrial chemicals: clinical management and proteomic

approaches to damage assessment. *Cutan Ocul Toxicol* 2007;26(3):203-225

- 4 Javadi MA, Yazdani S, Rezaei Kanavi M, et al. Long term outcomes of penetrating keratoplasty in chronic and delayed mustard gas keratitis. *Cornea* 2007; 26(9): 1074-1078
- 5 Petrali JP, Oglesby - Megee SB. Toxicity of mustard gas skin lesions. *Microsc Res Tech* 1997;37(3):221-228
- 6 Wilson SE, Mohan RR, Mohan RR, et al. The corneal wound healing response: cytokine-mediated interaction of the epithelium, stroma, and inflammatory cells. *Prog Retin Eye Res* 2001; 20(5): 625-637
- 7 Livingston PC, Walker HM. A study of the effects of liquid mustard gas upon the eyes of rabbits and of certain methods of treatment. *Br J Ophthalmol* 1940;24(2): 67-97
- 8 Borak J, Sidell FR. Agents of chemical warfare: sulfur mustard. *Ann Emerg Med* 1992;21(3): 303-308
- 9 Helena MC, Baerveldt F, Kim WJ, et al. Keratocyte apoptosis after corneal surgery. *Invest Ophthalmol Vis Sci* 1998;39(2): 276-283
- 10 Doughty MJ. Physiological state of the rabbit cornea following 4 $^{\circ}\text{C}$ moist chamber storage. *Exp Eye Res* 1989;49(5):807-827
- 11 Doughty MJ, Zaman ML. Human corneal thickness and its impact on intraocular pressure measures: a review and meta-analysis approach. *Surv Ophthalmol* 2000;44(5):367-407
- 12 Kadar T, Turetz J, Fishbine E, et al. Characterization of acute and delayed ocular lesions induced by sulfur mustard in rabbits. *Curr Eye Res* 2001;22(1):42-53
- 13 Milhorn D, Hamilton T, Nelson M, et al. Progression of ocular sulfur mustard injury: development of a model system. *Ann N Y Acad Sci* 2010; 1194(5):72-80