

Changes of outer retinal thickness with increasing age in normal eyes

Zi-Jing Li, Yu-Qing Lan, Jian-Hui Xiao, Peng Zeng, Xiang Gao, Yun-Ru Liao

Foundation item: Sun Yat-sen Clinical Research Foundation of Sun Yat-sen Memorial Hospital, Sun Yat-sen University (No. SYS-C-201705).

Department of Ophthalmology, Guangdong Provincial Key Laboratory of Malignant Tumor Epigenetics and Gene Regulation, Sun Yat-sen Memorial Hospital, Sun Yat-sen University, Guangzhou 510000, Guangdong Province, China

Correspondence to: Yu - Qing Lan. Department of Ophthalmology, Guangdong Provincial Key Laboratory of Malignant Tumor Epigenetics and Gene Regulation, Sun Yat-sen Memorial Hospital, Sun Yat-sen University, Guangzhou 510000, Guangdong Province, China. lyqglp@163.com

Received: 2018-01-31 Accepted: 2018-04-02

正常人外层视网膜厚度随年龄增长的相关性分析

李梓敬, 蓝育青, 肖剑晖, 曾鹏, 高翔, 廖韵如

基金项目: 中山大学孙逸仙纪念医院逸仙临床研究培育项目 (No. SYS-C-201705)。

(作者单位: 510000 中国广东省广州市, 中山大学孙逸仙纪念医院眼科 广东省恶性肿瘤表观遗传与基因调控重点实验室)

作者简介: 李梓敬, 毕业于中山大学, 硕士研究生, 医师。研究方向: 视网膜与玻璃体病变。

通讯作者: 蓝育青, 毕业于中山大学, 博士研究生, 主任医师, 教授。研究方向: 青光眼, 视网膜与玻璃体病变, 眼与全身病。lyqglp@163.com

摘要

目的: 研究正常人外层视网膜厚度和年龄的关系。

方法: 回顾分析 100 例 100 眼健康人的频域光学相干断层扫描的图像, 测量黄斑区及四个象限下列项目的距离: 内界膜到内外节连接体 (ELM-IS/OS), 内外节连接体到视锥细胞外节段 (IS/OS-COST), 视锥细胞外节段到色素上皮复合体 (COST-RPE) 和视网膜外层全层 (RT)。分析各层厚度和年龄、性别的关系。

结果: 女性 RT 比男性薄 (男: $234.47 \pm 16.79 \mu\text{m}$; 女: $223.13 \pm 15.43 \mu\text{m}$)。鼻侧视网膜外层全层、中心凹及四个象限处 ELM-IS/OS 的厚度与年龄呈显著负相关。中心凹及四个象限处 IS/OS-COST 和 COST-RPE 厚度与年龄、性别均无显著相关性。中心凹处 RT 厚度比其余象限显著变薄; ELM-IS/OS、IS/OS-COST 和 COST-RPE 中心凹处相比其余四象限厚度增厚。

结论: 在正常眼中, 鼻侧 RT 厚度和 ELM-IS/OS 厚度随年龄增长显著变薄, IS/OS-COST 和 COST-RPE 厚度不随年龄及性别变化而变化。

关键词: 外层视网膜; 年龄增长; 频域光学相干断层扫描; 正常眼

引用: 李梓敬, 蓝育青, 肖剑晖, 曾鹏, 高翔, 廖韵如. 正常人外层视网膜厚度随年龄增长的相关性分析. 国际眼科杂志 2018; 18(7): 1169-1173

Abstract

• **AIM:** To comprehensively investigate the relationship between outer retinal layer thickness and age in normal eyes.

• **METHODS:** One hundred normal eyes of 100 subjects who underwent spectral - domain optical coherence tomography (SD - OCT) were included in this retrospective study. The distances between the external limiting membrane (ELM) line and the photoreceptor inner segment/outer segment (IS/OS) line (ELM - IS/OS), the IS/OS line and the cone outer segment tips (COST) line (IS/OS - COST), the COST line and the retinal pigment epithelium (RPE) complex (COST - RPE) and the full retinal thickness (RT) were measured at the fovea and on four quarters. The relationship between thickness and age or sex was then analysed.

• **RESULTS:** A thinner RT was observed in women in a multiple regression analysis (men: $234.47 \pm 16.79 \mu\text{m}$; women: $223.13 \pm 15.43 \mu\text{m}$). The RT on the nasal quarter and the ELM-IS/OS thickness at the fovea and on the four quarters were significantly and negatively correlated with age. The IS/OS-COST and COST-RPE thicknesses at the fovea and on the four quarters were not significantly correlated with age or sex, respectively. The RT at the fovea was significantly thinner than on the four quarters. The ELM - IS/OS, IS/OS - COST and COST - RPE thicknesses at the fovea were significantly thicker than on the four quarters.

• **CONCLUSION:** In normal eyes, the RT thickness on the nasal quarter and the ELM - IS/OS thickness were significantly and negatively correlated with age. The IS/OS - COST and COST - RPE thicknesses were not significantly correlated with age or sex.

• **KEYWORDS:** outer retinal thickness; increasing age; spectral-domain optical coherence tomography; normal eyes

DOI:10.3980/j.issn.1672-5123.2018.7.01

Citation: Li ZJ, Lan YQ, Xiao JH, Zeng P, Gao X, Liao YR. Changes of outer retinal thickness with increasing age in normal eyes. *Guoji Yanke Zazhi(Int Eye Sci)* 2018;18(7):1169-1173

INTRODUCTION

Optical coherence tomography (OCT) is an objective, non-invasive method to perform real-time cross-sectional imaging of retinal tissue morphology at high resolution. It can also provide a qualitative assessment of the retinal microstructure. Therefore, OCT has become an indispensable diagnostic technique for monitoring and detecting retinal diseases.

The evaluation of retinal thickness is crucial because the reduction of thickness may indicate some retinal diseases. Inner and outer retinal layers may be affected by certain diseases independently. For instance, a thinning inner retinal layer is a sensitive indicator for glaucoma. Notwithstanding, retinal thickness may decrease with increasing age in normal eyes. Reduction of the full retinal thickness and inner retinal thickness with ageing has been reported in many research reports. In a study with time-domain OCT (TD-OCT) examination^[1], retinal thickness decreased by 0.26 to 0.46 μm per year, and the retinal nerve fibre layer (RNFL) decreased by 0.09 μm per year. Another study using spectral-domain optical coherence tomography (SD-OCT)^[2] also showed that the inner retinal thickness decreased with ageing. However, the relationship between outer retinal thickness and age has not been confirmed. Recently, Kenmochi *et al*^[3] reported that the outer retinal thickness might be reduced in older eyes. In contrast, in Higashide's study^[4], women seemed to have less outer retinal thickness than men, although thickness and age were not significantly related. The reasons for the variation remained unclear.

Current advances in OCT technology have enabled investigators to acquire much higher resolution images, especially of the outer retina. Compared to traditional OCT such as TD-OCT and frequency-domain OCT (FD-OCT), SD-OCT has provided more detailed imaging of three highly reflective lines in the outer retina, namely, the inner segment/outer segment (IS/OS) line, cone outer segment tips (COST) line and the retinal pigment epithelium (RPE) complex^[5].

The purpose of the study was to comprehensively investigate the relationship between outer retinal layer thickness and age in normal eyes.

SUBJECTS AND METHODS

This was a retrospective study of 100 normal eyes in 100 subjects who were referred to the Ophthalmology Clinic of Sun Yat-sen Memorial Hospital for routine ocular examinations between June and December 2016. Each included eye was one randomly selected eye of subjects who were found to be normal after clinical ocular examination. Additionally, each included subject was not less than 18 years old and not more than 85 years old. Refractive error of each included subject was to be less than +2 dioptres and more than -4 dioptres, and axial length was to be not more than 24.5 mm and not less than 23.5 mm. Patients with pseudophakia, glaucoma, uveitis, all kinds of retinopathy, high myopia, amblyopia, strabismus or serious refractive media opacities were

excluded. Patients with histories of ocular surgery, hypertension, diabetes mellitus or other serious systemic diseases were also excluded. This study was performed in accordance with the World Medical Association's Declaration of Helsinki and was approved by the Institutional Review Board of Sun Yat-sen Memorial Hospital.

All patients underwent SD-OCT examinations by using Cirrus OCT (Carl Zeiss Meditec, Inc., Dublin, California, USA) in our hospital. A 6-mm horizontal and vertical scan was performed through the fovea for each subject in both eyes. OCT images with signal strength <6 were excluded. A line tangential to the RPE at the fovea was drawn. OCT images were also excluded when the RPE was tilted $>5^\circ$ because the contrast of the reflective lines was relatively lower in tilted images. The thicknesses of the external limiting membrane (ELM) line and the photoreceptor inner segment/outer segment (IS/OS) line (ELM-IS/OS), the IS/OS line and the cone outer segment tips (COST) line (IS/OS-COST), the retinal pigment epithelium (RPE) complex (COST-RPE) and the full retinal thickness (RT) were measured manually at the fovea horizontally and vertically. The ELM, IS/OS and COST lines were completely separated in all eyes. However, the RPE and COST lines were not completely separated in some normal eyes. Therefore, the RPE line was measured from the outer border and the COST line was measured from the inner border for COST-RPE measurement. Additionally, the ELM, IS/OS, COST and RPE lines were measured from the centre for ELM-IS/OS, IS/OS-COST and RT measurements. The measurements were also performed 2-mm nasal/superior and 2-mm temporal/inferior to the fovea (Figures 1 and 2).

Intra- (Intra-CCs) and interclass correlation coefficients (Inter-CCs) were used to assess the reproducibility of thickness measurements. Measurements were performed by 2 investigators independently, and each layer was measured twice by the same investigator. The investigators were masked to patient information, including name, age and sex.

Statistical Analyses Multiple regression analyses were used to assess whether the RT, ELM-IS/OS, IS/OS-COST and COST-RPE thicknesses were correlated with age, sex, spherical equivalent or axial length. One-way analysis of variance with Tukey post hoc analysis was performed to determine the significance of the differences in different layers among the fovea (horizontally and vertically), 2-mm nasal/superior and 2-mm temporal/inferior areas. The statistical analyses were performed using SPSS 16.0 (SPSS Inc., Chicago, IL, USA). $P < 0.05$ was considered statistically significant.

RESULTS

Clinical Characteristics One hundred normal eyes from 100 subjects were examined by Cirrus OCT. Among these subjects, there were 53 men and 47 women. The mean age was 52.28 ± 16.36 (range from: 18 to 85) y. The mean age was 52.20 ± 16.42 y in men (range from: 18 to 85 y, median: 54 y) and 51.69 ± 15.99 y in women (range from: 18 to 80 y,

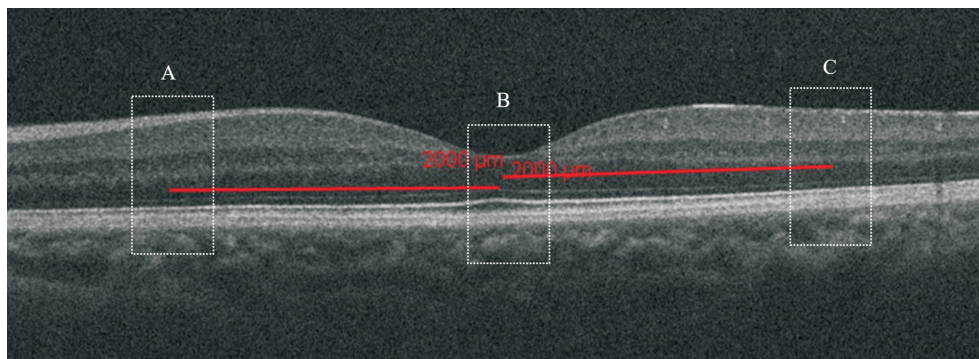


Figure 1 Measurements performed at the fovea (B), 2-mm nasal/superior (A) and 2-mm temporal/inferior (C) to the fovea in normal eyes.

Table 1 Thickness of each layer

Parameters	Fovea (horizontally)	Fovea(vertically)	2 mm temporal	2 mm nasal	2 mm superior	2 mm inferior
Mean RT (μm)	229.14±17.06	225.73±11.52	300.96±19.00	336.48±21.52	325.14±20.44	326.72±20.36
Mean ELM-IS/OS thickness (μm)	41.28±3.36	40.09±3.13	35.87±3.76	36.40±3.58	35.41±3.65	35.91±3.05
Mean IS/OS-COST thickness (μm)	45.38±5.68	45.32±6.58	37.65±4.51	37.05±4.16	37.55±4.26	37.25±4.16
Mean COST-RPE thickness (μm)	46.94±6.36	46.22±6.76	44.49±5.06	44.33±4.50	44.37±4.78	44.23±5.01

ELM; External limiting membrane; IS/OS; Photoreceptor inner segment/outer segment; COST; Cone outer segment tips; RPE; Retinal pigment epithelium complex.

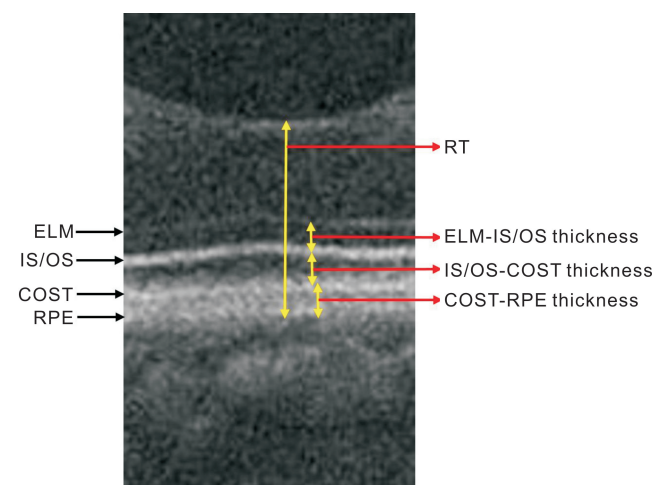


Figure 2 Thickness measurements of each layer at the fovea in normal eyes ELM: External limiting membrane; IS/OS: Photoreceptor inner segment/outer segment; COST; Cone outer segment tips; RPE; Retinal pigment epithelium complex; RT: Full retinal thickness.

median; 54y). The mean refractive error (spherical equivalent) was 0.9 ± 2.8 (range from -4 to +2) dioptres. The mean axial length was 23.95 ± 0.35 (range from: 23.5 to 24.5) mm.

Reproducibility The Intra-CCs and Inter-CCs for RT, ELM-IS/OS, IS/OS-COST and COST-RPE at the fovea, 2 mm nasal to the fovea and 2 mm temporal to the fovea were ≥ 0.80 . Therefore, the reproducibility of the measurements was guaranteed.

Ageing and Other Effects on Outer Retinal Layer Thickness A statistically significant relationship was found between the RT at the fovea and sex in multiple regression analysis [standardized coefficient $\beta = -0.33$, $P < 0.01$; regression coefficient $B = -0.1$, 95% CI for $B (-1.05,$

$-0.07)$]. Women were likely to have lower RT at the fovea (men: $234.47 \pm 16.79 \mu\text{m}$; women: $223.13 \pm 15.43 \mu\text{m}$). Additionally, the RT on the 2 mm nasal quarter was significantly and negatively correlated with age [$\beta = -0.26$, $P < 0.05$; $B = -0.34 (-0.59, -0.08)$]. However, the RT on the temporal, the superior and the inferior was not significantly correlated with sex or age.

The ELM-IS/OS thicknesses at the fovea and on the 2 mm nasal, temporal, superior and inferior quarters were significantly and negatively correlated with age [fovea: $\beta = -0.28$, $P < 0.01$, $B = -0.06 (-0.10, -0.02)$; nasal: $\beta = -0.39$, $P < 0.01$, $B = -0.09 (-0.13, -0.05)$; temporal: $\beta = -0.31$, $P < 0.01$, $B = -0.07 (-0.12, -0.03)$; superior: $\beta = -0.36$, $P < 0.01$, $B = -0.08, (-0.11, -0.05)$; inferior: $\beta = -0.29$, $P < 0.01$, $B = -0.07, (-0.11, -0.03)$]. However, these values were not significantly correlated with sex.

The IS/OS-COST and COST-RPE thicknesses at the fovea and on the 2 mm nasal, temporal, superior and inferior quarters were not significantly correlated with age or sex, respectively. In addition, thickness of different layers were not significantly correlated with spherical equivalent or axial length.

Horizontal Symmetry Analysis The mean RT, the mean ELM-IS/OS thickness, the mean IS/OS-COST thickness and the mean COST-RPE thicknesses at the fovea and four quarters are listed in Table 1.

The RT at the fovea (horizontally or vertically) was significantly thicker than on the nasal, temporal, superior and inferior quarters ($P < 0.01$). Additionally, the RT on the 2 mm nasal/superior/inferior quarter was significantly thicker than on the 2 mm temporal quarter ($P < 0.01$) (Figure 3). The ELM-IS/OS, the IS/OS-COST and the COST-RPE

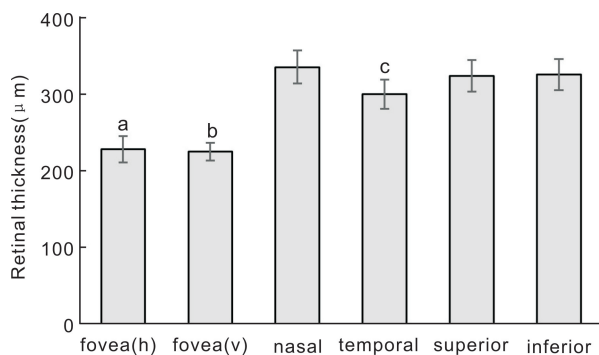


Figure 3 Full retinal thickness at the fovea (horizontally or vertically) and 2-mm nasal, 2-mm temporal, 2-mm superior and 2-mm inferior to the fovea in normal eyes Error bar is the mean ± SD; ^{a,b} $P < 0.01$ compared to nasal, temporal, superior and inferior; ^c $P < 0.01$ compared to nasal, superior and inferior.

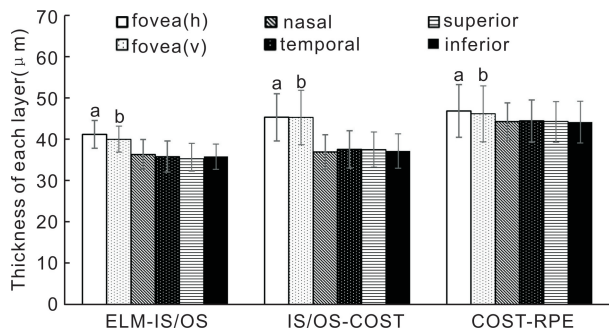


Figure 4 Thickness at the fovea (horizontally or vertically) and 2-mm nasal, 2-mm temporal, 2-mm superior and 2-mm inferior to the fovea in normal eyes Error bar is the mean ± SD; ^{a,b} $P < 0.01$ compared to nasal, temporal, superior and inferior. ELM: External limiting membrane; IS/OS: Photoreceptor inner segment/outer segment; COST: Cone outer segment tips; RPE: Retinal pigment epithelium complex.

thicknesses at the fovea were significantly greater than on the nasal, temporal, superior and inferior quarters ($P < 0.01$). However, no significant differences were found among the four quarters for the ELM-IS/OS, IS/OS-COST and COST-RPE thicknesses (Figure 4).

DISCUSSION

The RT at the fovea was significantly lower in women than men, which was consistent with previous studies^[3,6-10]. No clear explanation for this result has been given in prior research. In Song's study^[7], the phenomenon was considered to be consistent with the observation that women have a higher risk of developing macular holes than men. Pokharel *et al*^[6] speculated that the smaller and thinner female physique was one of the major reasons. Detailed ocular biometry between men and women will be required to demonstrate these differences in the future.

However, many conflicting reports^[8-9] have shown that there was no relationship between the RT at the fovea and sex. The variation remained unclear. However, according to Ulas's study^[10], RT changed during the menstrual cycle. RT in the mid-luteal phase was greater than during the early follicular phase but not significantly. Additionally, Ulas attributed the change of choroidal thickness during the menstrual cycle to the

level of hormones. Regard of Ulas's conclusion, hormonal effects may account for the change of RT during the menstrual cycle because vessels in the retina and choroid may be affected simultaneously. Therefore, the changing RT during the menstrual cycle may partially explain the uncertain relationship of RT at the fovea between men and women.

In our study, the RT on the 2 mm nasal quarter was significantly and negatively correlated with age while the RT on the other quarters were not significantly correlated with sex or age. Some researchers^[1-2,11-12] showed that a statistically significant association between retinal nerve fibre layer (RNFL) or ganglion cell complex (GCC) thickness and age was found in OCT measurements. Kampougeris *et al*^[13] found that RNFL thickness decreased by 1.92 μm per decade of life. Kim *et al*^[14] also found that GCC layer thickness decreased by 1.59 μm for every decade. Therefore, greater RNFL or GCC thickness on the nasal quarter compared to the other quarters may be a crucial reason for the different relationship between age and RT on the other quarters. Song's study^[7] suggested that axial length correlated negatively with outer macular thickness and overall macular thickness. However, no obvious correlation was found in our study, which may be related to the small range of axial length we have defined.

Recent research^[13] has shown that the IS/OS band, often attributed to the boundary between inner segments (IS) and outer segments (OS) of the photoreceptors, actually aligns with the ellipsoid portion of the IS and that the COST band corresponds to an ensheathment of the OS. In our study, the ELM-IS/OS thicknesses at the fovea and on four quarters were significantly correlated with age, which suggested that the IS of the photoreceptor cells may become shorter with increasing age. In contrast, the IS/OS-COST thickness at the fovea and on four quarters was not significantly correlated with age, which indicated that the OS might "grow longer" with shorter IS. Similar results were noticed in a previous study^[3]. Saadane *et al*^[15] confirmed that OS degeneration and unesterified cholesterol accumulation in the OS simultaneously existed in mouse models. IS and OS degeneration reduced the IS and OS length, while unesterified cholesterol accumulation increased the thickness, which thus provided evidence for the "unchanged" IS/OS-COST thickness.

The COST-RPE layer consists of the cone sheaths, RPE cells and the Bruch membrane. In Kenmochi's study^[3], COST-RPE thickness decreased with increasing age, which he attributed to atrophy of the cone sheaths. However, no significant differences between COST-RPE thickness and age were shown in our study. It has been reported that RPE cells and the Bruch membrane become thicker with increasing age because of the phagocytosis of RPE cells^[16-17]. Therefore, atrophy of the cone sheaths reduces the thickness, while phagocytosis by RPE cells increases the thickness, which helps to balance the thickness of the COST-RPE layer and contributes to one of the possible explanations for our finding. The ELM-IS/OS, the IS/OS-COST and the COST-RPE

were significantly thicker at the fovea than on the four quarters, which may indicate that cone packing density was higher at the fovea and decreased with increasing retinal eccentricity^[18-19]. Additionally, the thicknesses of the ELM-IS/OS, IS/OS-COST and COST-RPE on the four quarters were not significantly different, in agreement with another study^[3]. However, the reason for this finding was not discussed in previous studies.

There are some limitations in this study. First, the layers were thin, and their thicknesses were measured manually. Furthermore, the RPE and COST lines were sometimes not completely separated, and the definition of the band measurements may result in differences. The above factors may account for the variation of the results. Currently, no automated methods have been developed to differentiate retinal bands clearly, especially in thin layers such as these. Consequently, advanced OCT machines and measurement software with reasonable prices should be developed for further investigation, especially in developing countries. Another limitation is that potential confounding factors such as refractive error and axial length may be involved in the study. The relationship between axial length and retinal thickness is still controversial as reported in previous research^[4,6,15]. However, we strictly established a small range to minimize the effect of axial length when the eyes were included. More detailed indicators should be accessed in future studies.

The relationship between the outer retinal layer thickness and age in normal eyes has been comprehensively investigated by using SD - OCT measurements. In conclusion, the RT thickness on the nasal quarter and the ELM-IS/OS thickness were significantly and negatively correlated with age in normal eyes. The IS/OS-COST and COST-RPE thicknesses were not significantly correlated with age or sex. Additionally, women were likely to have lower RT at the fovea.

REFERENCES

- 1 Eriksson U, Alm A. Macular thickness decreases with age in normal eyes: a study on the macular thickness map protocol in the Stratus OCT. *Br J Ophthalmol* 2009; 93(11): 1448-1452
- 2 Bafiq R, Mathew R, Pearce E, Abdel-Hey A, Richardson M, Bailey T, Sivaprasad S. Age, sex, and ethnic variations in inner and outer retinal and choroidal thickness on spectral-domain optical coherence tomography. *Am J Ophthalmol* 2015;160(5):1034-1043 e1031
- 3 Kenmochi J, Ito Y, Terasaki H. Changes of outer retinal thickness with increasing age in normal eyes and in normal fellow eyes of patients with unilateral age-related macular degeneration. *Retina* 2016;37(1):47-52
- 4 Higashide T, Ohkubo S, Hangai M, Ito Y, Shimada N, Ohno-Matsui K, Terasaki H, Sugiyama K, Chew P, Li KK, Yoshimura N. Influence of clinical factors and magnification correction on normal thickness profiles of macular retinal layers using optical coherence tomography. *PLoS One* 2016;11(1):e0147782

- 5 Shin YU, Cho HY, Lee BR. Outer photoreceptor layer thickness mapping in normal eyes and eyes with various macular diseases using spectral domain optical coherence tomography: a pilot study. *Graefes Arch Clin Exp Ophthalmol* 2013;251(11):2529-2537
- 6 Pokharel A, Shrestha GS, Shrestha JB. Macular thickness and macular volume measurements using spectral domain optical coherence tomography in normal Nepalese eyes. *Clin Ophthalmol* 2016; 10: 511-519
- 7 Song WK, Lee SC, Lee ES, Kim CY, Kim SS. Macular thickness variations with sex, age, and axial length in healthy subjects: a spectral domain-optical coherence tomography study. *Invest Ophthalmol Vis Sci* 2010;51(8):3913
- 8 Sull AC, Vuong LN, Price LL, Srinivasan VJ, Gorczynska I, Fujimoto JG, Schuman JS, Duker JS. Comparison of spectral/Fourier domain optical coherence tomography instruments for assessment of normal macular thickness. *Retina* 2010;30(2):235-245
- 9 Grover S, Murthy RK, Brar VS, Chalam KV. Comparison of retinal thickness in normal eyes using stratus and spectralis optical coherence tomography. *Invest Ophthalmol Vis Sci* 2010;51(5):2644
- 10 Ulas F, Dogan U, Duran B, Keles A, Agca S, Celebi S. Choroidal thickness changes during the menstrual cycle. *Curr Eye Res* 2013; 38(11):1172-1181
- 11 Song H, Chui TY, Zhong Z, Elsner AE, Burns SA. Variation of cone photoreceptor packing density with retinal eccentricity and age. *Invest Ophthalmol Vis Sci* 2011;52(10):7376-7384
- 12 Wong A, Chan C, Hui SP. Relationship of gender, body mass index, and axial length with central retinal thickness using optical coherence tomography. *Eye* 2004;19(3):292-297
- 13 Kampougeris G, Spyropoulos D, Mitropoulou A, Zografou A, Kosmides P. Peripapillary retinal nerve fibre layer thickness measurement with SD - OCT in normal and glaucomatous eyes: distribution and correlation with age. *Int J Ophthalmol* 2013;6(5): 662-665
- 14 Kim NR, Kim JH, Lee J, Lee ES, Seong GJ, Kim CY. Determinants of perimacular inner retinal layer thickness in normal eyes measured by Fourier-domain optical coherence tomography. *Invest Ophthalmol Vis Sci* 2011;52(6):3413-3418
- 15 Saadane A, Mast N, Dao T, Ahmad B, Pikuleva IA. Retinal hypercholesterolemia triggers cholesterol accumulation and esterification in photoreceptor cells. *J Biol Chem* 2016;291(39):20427-20439
- 16 Ramrattan RS, van der Schaft TL, Mooy CM, de Bruijn WC, Mulder PG, de Jong PT. Morphometric analysis of Bruch's membrane, the choriocapillaris, and the choroid in aging. *Invest Ophthalmol Vis Sci* 1994;35(6):2857-2864
- 17 Finnemann SC, Bonilha VL, Marmorstein AD, Rodriguez-Boulan E. Phagocytosis of rod outer segments by retinal pigment epithelial cells requires alpha(v)beta5 integrin for binding but not for internalization. *Proc Natl Acad Sci USA* 1997;94(24):12932-12937
- 18 Spaide RF, Curcio CA. Anatomical correlates to the bands seen in the outer retina by optical coherence tomography: literature review and model. *Retina* 2011;31(8): 609-1619
- 19 Srinivasan VJ, Monson BK, Wojtkowski M, Bilonick RA, Gorczynska I, Chen R, Duker JS, Schuman JS, Fujimoto JG. Characterization of outer retinal morphology with high-speed, ultrahigh-resolution optical coherence tomography. *Invest Ophthalmol Vis Sci* 2008; 49(4): 1571-1579