

Outcomes of scleral buckle technique performed by trainee doctors in retinal detachment

Kumar Aalok¹, Singh Vipin², Gupta Sanjiv Kumar²

引用: Kumar A, Singh V, Gupta SK. 实习医师施行巩膜扣带术治疗视网膜脱离的效果. 国际眼科杂志 2020;20(9):1477-1481

¹Department of Ophthalmology, Hind Institute of Medical Sciences, Barabanki 225003, India

²Department of Ophthalmology, King George Medical University, Lucknow 226003, India

Correspondence to: Kumar Aalok. Department of Ophthalmology, Hind Institute of Medical Sciences, Barabanki 225003, Uttar Pradesh, India. dr.aalok01@gmail.com

Received: 2019-12-25 Accepted: 2020-03-19

实习医师施行巩膜扣带术治疗视网膜脱离的效果

Kumar Aalok¹, Singh Vipin², Gupta Sanjiv Kumar²

(作者单位:¹225003 印度巴拉班基, Hind 医学科学研究所眼科;²226003 印度勒克瑙, 乔治国王医科大学眼科)

通讯作者: Aalok Kumar. dr.aalok01@gmail.com

摘要

目的: 评估实习医师施行巩膜扣带术治疗视网膜脱离的效果。

方法: 非比较回顾性病例。评估 2017-07/2018-02 在印度三级护理中心接受巩膜扣带术修复的孔源性视网膜脱离(RRD)患者的人口学、临床特征和效果。对所有患者的记录进行了筛查。统计分析采用 Fisher 确切干预, Mann-Whitney 检验和 Logistic 回归分析。

结果: 共 41 例患者, 其中男 32 例(78%), 女 9 例(22%)。在我们的研究中, I 期解剖成功率为 95%, 视力明显提高。2 例患者术后出现并发症—眼压升高、新裂孔以及再次脱离, 经玻璃体切除术(PPV)内填塞及激光成功治疗。

结论: 研究表明, 通过指导, 实习医生对 RRD 患者行巩膜扣带术无论从术后解剖成功率、视力还是并发症发生率来看, 均能获得较高的成功率。因此, 尽管现有的治疗方法多种多样, 但对于实习医生来说, 巩膜扣带术是一种可接受的治疗 RRD 的主要方法。

关键词: 巩膜扣带术; 孔源性视网膜脱离; 实习医师; 视网膜疾病; 眼部手术

Abstract

• **AIM:** To evaluate the outcomes of patients operated for retinal detachment by scleral buckle technique done by trainee doctors pursuing postgraduate course in ophthalmology.

• **METHODS:** This study was a non-comparative retrospective case series to evaluate the demography, clinical features and outcomes of patients underwent rhegmatogenous retinal detachment (RRD) repaired by scleral buckle technique from July 2017 to February 2018 at a tertiary care center in India. Records of all these patients were screened. Statistical analyses were performed and using Fisher's exact test, Mann-Whitney test and Nominal Logistic regression.

• **RESULTS:** Totally of 41 patients were included out of which, 32 (78%) were males and 9 (22%) were females. In our study primary anatomical success rate was 95%, with significant visual gain. Postoperative complications were raised intraocular pressure ($n=2$), new breaks ($n=2$) and re-detachment in 2 patients which was successfully managed by pars plana vitrectomy (PPV) with internal tamponade and laser.

• **CONCLUSION:** The study showed that scleral buckle surgeries done by trainee doctors under supervision can achieve a high success rate in patients of RRD both in terms of postoperative anatomical success, visual acuity and complication rates. Thus, scleral buckle surgery can be an acceptable primary procedure for trainee doctors for management of RRD in selected cases despite the various treatment options now available.

• **KEYWORDS:** scleral buckling; rhegmatogenous retinal detachment; trainee doctors; retinal disease; eye surgery DOI:10.3980/j.issn.1672-5123.2020.9.02

Citation: Kumar A, Singh V, Gupta SK. Outcomes of scleral buckle technique performed by trainee doctors in retinal detachment. *Guoji Yanke Zazhi(Int Eye Sci)* 2020;20(9):1477-1481

INTRODUCTION

The incidence of retinal detachment is between 0.6 to 1.8 people per 10 000 per year^[1]. Rhegmatogenous retinal detachment (RRD) is treated primarily either by external approach (scleral buckling), internal approach pars plana vitrectomy (PPV) or combined approach^[2]. Pars plana vitrectomy is becoming the choice for surgeons from last few decades and scleral buckling is losing importance^[3-4]. Trend at present is towards PPV with emergence of small incision techniques and wide field viewing systems^[5-6]. Still scleral buckling is an effective and most favored procedure for selected cases of rhegmatogenous retinal detachments having anterior breaks and low grade proliferative vitreoretinopathy^[7-9]. Scleral buckling has many advantages

Table 1 Inclusion and exclusion criteria

Inclusion criteria	Exclusion criteria
RRD with retinal breaks and lattices with holes	Any previous RRD surgery, GRT, posterior holes
PVR, grades A or B ^[14]	Vitreous hemorrhage, choroidal detachment

RRD: Retinal detachment; PVR: Proliferative vitreoretinopathy; GRT: Giant retinal tear.

over PPV, including reduced risk of cataract formation and endophthalmitis as it is a non-invasive technique^[10-12]. It has faster rehabilitation compared to PPV, which requires intravitreal gas or silicone oil^[13]. Objective of our study was to evaluate the outcomes of scleral buckle technique done by trainee doctors at a tertiary care hospital.

SUBJECTS AND METHODS

Our study was a non-comparative retrospective case series of the outcomes of scleral buckle technique done by trainee doctors for RRD repair performed from July 2017 to February 2018 at King George Medical University, Lucknow, India. Approval from Ethics Committee was taken for the study. Records of all the patients who underwent scleral buckle surgeries done by trainee doctors under supervision were screened. Inclusion and exclusion criteria for this study were summarised in Table 1. Indications for scleral buckle surgery included subjects with RRD with anterior holes, lattice with holes and RRD with grade A and grade B PVR (proliferative vitreoretinopathy). Patient’s demographics, anatomical success rate, visual outcome and complications were identified and recorded. Anatomical success was defined as a reattached retina (posterior pole) at the final postoperative visit. The data sheet was completed and results analyzed. Statistical analyses were performed using Fisher’s exact test, Mann – Whitney test and nominal Logistic regression.

RESULTS

The total number of subjects included in the study after screening the records of subjects operated during the 8mo period was 41, out of which 32 (78%) were males and rest females. Age of the patients ranged from 5-76 years including 4 children with mean age of 43.40 years. The right eye was involved in 20 (48.78%) patients. The cases were operated by three trainee surgeons. The duration of symptoms ranged from 3d to 4mo. 5 (12.19%) patients presented with symptoms within 1wk, while 32 (78.04%) presented between 1-4wk. 4 (9.75%) patients presented between 4-16wk. All patients underwent surgery within 1wk of reporting to our hospital.

More than half of the patients were myopes (n = 25) (60.97%), ranging from -0.5 D to -6.25 D, averaging -3.03 D of myopia with standard deviation of 1.58. 14 (34.14%) patients were emmetropes and 2 (4.87%) patients were hypermetropes. History of trauma was elicited in two patients. Past history of retinal detachment and treatment in the other eye was seen in 5 (12.19%) patients. Presenting symptoms are summarized in Table 2.

Of the 41 patients, 4 (9.75%) patients had macula attached RRD at the time of presentation. The rest 37 (90.24%)



Figure 1 Quadrant involved in tears/breaks.

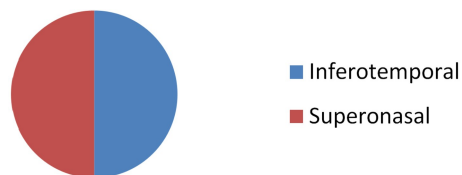


Figure 2 Quadrants involved in retinal dialysis.

Table 2 Presenting symptoms

Symptoms	Number of patients
Floaters	32
Visual loss	37
Curtain	12
Flashes	12
Asymptomatic	2

patients had macula detached RRD. The refractive status of both the patients with dialysis were emmetropia. The RDs resulting from dialysis was found in 2 cases (4.87%) and those resulting from lattice with holes in 10 cases (24.40%). RRD due to break/ hole was found in 29 (70.73%) cases. It was interesting to note that there was area specific predilection for the tears, dialysis and holes in this series of RD (Figures 1, 2). Moreover, some patients had more than one quadrant involved.

All the surgeries were done in local anesthesia except the 4 patients (children) who got operated under general anesthesia. Variations in buckle surgery was reported according to the location of holes, presence of lattice and amount of sub retinal fluid (SRF) present (Table 3).

All 40 buckles were applied segmentally, while one buckle was radially tied. Solid Silicon tyres (Silibend) made of solid silicone rubber were used for external tamponade. Cryotherapy in the fellow eye was done in 10 patients prophylactically for vulnerable areas. The complications included sub retinal hemorrhage (n = 2), retrobulbar hemorrhage during local anesthesia delivery (n = 1) and one buckle displaced anteriorly with granuloma formation leading to buckle extrusion (n=1)^[15]. No vitreous hemorrhage (n=0) and no choroidal hemorrhage (n=0) was recorded. Thus, 38 patients had no complications intra-operatively. Postoperative complications were raised intra ocular pressure (n = 2), re-detachment (n=2) and new breaks in 2 patients.

Table 3 Variations in buckle surgery

Parameters	Number of patients
Cryo with buckle with SRF drainage	34
Encircilage with Cryo with buckle with SRF drainage	7

SRF; Sub retinal fluid.



Figure 3 Postoperative visual acuity after 3mo of surgery for retinal detachment.

Table 4 Visual acuity on follow up after 3mo postoperative

Visual acuity (LogMar)	Number of patients
0.0	2
0.2-0.5	18
0.6-0.8	17
<1.0	3
3.0	1

Residual SRF at macula was observed in 10 patients which gradually resolved in 8 patients within 1mo and 2 patients ended with persistent detachment, who underwent PPV and achieved good visual. Squint developed in none of our patients.

Follow up Follow up was done on 1d, 7d, 1mo and 3mo postoperatively. Regular follow up is necessary to ensure that the retina is in place and also to sort out unsuccessful cases. Anatomical success was defined as a reattached retina (posterior pole) at the final postoperative visit. Forty-one patients were followed up till three months and their visual acuity was analyzed (Table 4). The mean visual acuity improvement was 0.7 ± 0.8 . This difference was statistically significant ($P < 0.05$).

DISCUSSION

Scleral buckling is an effective procedure for selected cases of rhegmatogenous retinal detachments having anterior breaks. In cases of retinal dialysis, scleral buckling is the treatment of choice, with a better prognosis and success rate^[16-18]. Limitations of scleral buckling includes longer learning curve as compared to PPV. It also demands more surgical expertise compared to PPV, which have the advantage of intraoperative visualization of retinal breaks^[19].

Our study showed 95.12% ($n = 39$) success rate in relation to primary anatomical success with settled retina. Buckle related complications includes strabismus^[20-21], infection, hemorrhage *etc.* But in our study, it was minimal (only one patient required buckle extrusion).

We did not had any visual field related complications. Our case series had sub macular fluid in 10 patients of which 8 resolved within 1mo and the rest ended with re-detachment. The incidence, duration, pattern and consequences of persistent, localized sub macular fluid after scleral buckle

surgery for RD has been reported in the literature in a prospective observational cohort series^[22-25]. In our study, OCT was used to report the sub macular fluid. Out of 10 patients with SRF, 2 had persistent fluid at 3mo in which PPV was done. With proper follow up and postoperative management all patients achieved good visual acuity within 1mo. Literature search for outcome of scleral buckle shows that in a retrospective noncontrolled case series involving 93 patients having previous macula off rhegmatogenous retinal detachment the SRF drainage procedure did not affect postoperative visual outcome. Multivariate logistic regression analysis revealed that it was the total duration of macular detachment which was the only important variable affecting the visual outcome^[26].

In another study of rhegmatogenous retinal detachment patients with primary, uncomplicated, macula detached treated by scleral buckle technique the patients achieved good postoperative visual acuity if repaired within the first 10d of macular detachment and the age of the patient did not significantly affected anatomical outcomes^[27]. In a large case series of 186 eyes 82% achieved primary anatomical success (retinal reattachment) with scleral buckle technique at follow up of 20 years^[28]. The national RD Audit, UK reported primary reattachment in 82% and the final re-attachment after repeat surgery as 91%^[29].

In another randomized controlled trial of 546 patients, surgical outcomes for primary RRDs with scleral buckle technique was achieved in 97.8% of the patients^[30]. A retrospective study done on 115 patients concluded that the incidence of retinal breaks and detachments done by vitreoretinal fellows doing standard 3 port primary PPVs is low and comparable to that of fellowship trained surgeons^[31].

In another retrospective case series 179 eyes of 174 patients were operated either by PPV alone or by PPV combined with scleral buckle. Single surgery anatomical success rate was similar in both the groups^[32]. A retrospective study was done in fifty eyes of fifty patients who underwent scleral buckle surgery. Primary retinal reattachment of 41 patients was achieved in single surgery^[33]. In another retrospective study submacular fluid was observed to persist for longer duration in the group operated by scleral buckle technique as compared to the group operated by PPV^[34].

On Pubmed search for surgeries done by trainee doctors in Ophthalmology we found a retrospective study which was done on 414 patients concluded that the trainee assistant medical officers – ophthalmologists doing ECCE and MSICS offer significant improvement in the visual acuity of their patients comparable with those reported by higher level surgeons

elsewhere^[35]. To date, there is no study evaluating the outcomes of scleral buckle surgeries done by trainee doctors. From results of our study, we observed that a high success rate in terms of primary anatomical retinal reattachment and visual acuity can be achieved by scleral buckle technique even by trainee doctors if done under supervision, irrespective of any duration of symptoms (within 1wk–4mo) at the time of presentation. Our study does not find any correlation between anatomical success rate and duration of presentation of symptoms of RRD patients

For retinal dialysis also, this technique achieved great success. However, the latter appears to have some effect on the overall visual acuity of the patient after repair with scleral buckle technique.

This is the first study reporting the various outcomes of scleral buckle surgeries done by trainee doctors pursuing M. S ophthalmology. Scleral buckling is a very effective noninvasive technique of choice to treat selected cases of RRD mostly with anterior breaks and RRD with low grade PVR. This technique should not be a neglected skill for the present and future vitreo-retinal surgeons, but it should be encouraged among junior vitreo retinal surgeons and trainee doctors despite the advent of advancing techniques and technology of PPV.

REFERENCES

1 Mitry D, Charteris DG, Fleck BW, Campbell H, Singh J. The epidemiology of rhegmatogenous retinal detachment: geographical variation and clinical associations. *Br J Ophthalmol* 2010; 94 (6): 678–684

2 Kunikata H, Abe T, Nakazawa T. Historical, current and future approaches to surgery for rhegmatogenous retinal detachment. *Tohoku J Exp Med* 2019;248(3):159–168

3 Huang CM, Fu T, Zhang TH, Wu XY, Ji Q, Tan RL. Scleral buckling versus vitrectomy for macula-off rhegmatogenous retinal detachment as assessed with spectral-domain optical coherence tomography: a retrospective observational case series. *BMC Ophthalmol* 2013;13:12

4 Cankurtaran V, Citirik M, Simsek M, Tekin K, Teke MY. Anatomical and functional outcomes of scleral buckling versus primary vitrectomy in pseudophakic retinal detachment. *Bosn J Basic Med Sci* 2017; 17 (1):74–80

5 Park SJ, Cho SC, Choi NK, Park KH, Woo SJ. Age, sex, and time-specific trends in surgical approaches for rhegmatogenous retinal detachment: a nationwide, population-based study using the national claim registry. *Retina (Philadelphia, Pa)* 2017;37(12):2326–2333

6 Park SW, Kwon HJ, Kim HY, Byon IS, Lee JE, Oum BS. Comparison of scleral buckling and vitrectomy using wide angle viewing system for rhegmatogenous retinal detachment in patients older than 35 years. *BMC Ophthalmol* 2015;15:121

7 Conart JB, Hubert I, Casillas M, Berrod JP. Results of scleral buckling for rhegmatogenous retinal detachment in phakic eyes. *J Fr Ophthalmol* 2013;36(3):255–260

8 Park SW, Lee JJ, Lee JE. Scleral buckling in the management of rhegmatogenous retinal detachment: patient selection and perspectives. *Clin Ophthalmol* 2018;12:1605–1615

9 Sabrosa NA, Wong C. Scleral Buckling for RRD: Yes, no or maybe? 2014. Available at: <https://www.reviewofophthalmology.com/article/scleral-buckling-for-rrd-yes-no-or-maybe>

10 Azad RV, Chanana B, Sharma YR, Vohra R. Primary vitrectomy versus conventional retinal detachment surgery in phakic rhegmatogenous retinal detachment. *Acta Ophthalmol Scand* 2007;85(5):540–545

11 Heimann H, Bartz-Schmidt KU, Bornfeld N, Weiss C, Hilgers RD, Foerster MH. Scleral Buckling versus Primary Vitrectomy in Rhegmatogenous Retinal Detachment Study Group. Scleral buckling versus primary vitrectomy in rhegmatogenous retinal detachment: a prospective randomized multicenter clinical study. *Ophthalmology* 2007; 114(12):2142–2154

12 Miki D, Hida T, Hotta K, Shinoda K, Hirakata A. Comparison of scleral buckling and vitrectomy for retinal detachment resulting from flap tears in superior quadrants. *Jpn J Ophthalmol* 2001;45(2):187–191

13 Pak KY, Lee SJ, Kwon HJ, Park SW, Byon IS, Lee JE. Exclusive use of air as gas tamponade in rhegmatogenous retinal detachment. *J Ophthalmol* 2017;2017:1341948

14 Di Lauro S, Kadhim MR, Charteris DG, Pastor JC. Classifications for proliferative vitreoretinopathy (PVR): an analysis of their use in publications over the last 15 years. *J Ophthalmol* 2016;2016:7807596

15 Kazi MS, Sharma VR, Kumar S, Bhende P. Indications and outcomes of scleral buckle removal in a tertiary eye care center in South India. *Oman J Ophthalmol* 2015;8(3):171–174

16 James M, O'Doherty M, Beatty S. Buckle-related complications following surgical repair of retinal dialysis. *Eye (Lond)* 2008; 22 (4):485–490

17 Kwon H, Shin MK, Park SW, Byon IS, Lee JE, Oum BS. Prognostic factors of anatomical success in scleral buckling for high myopic rhegmatogenous retinal detachment. *J Korean Ophthalmol Soc* 2016;57 (10):1586–1691

18 Park SW, Kwon HJ, Byon IS, Lee JE, Oum BS. Impact of age on scleral buckling surgery for rhegmatogenous retinal detachment. *Korean J Ophthalmol* 2017;31(4):328–335

19 Lee SJ, Kwon HJ, Park KY, Park SW, Byon IS, Lee JE. Prognostic factors of anatomical success in microincisional vitrectomy for rhegmatogenous retinal detachment. *J Korean Ophthalmol Soc* 2016;57 (10):1613

20 Papakostas TD, Vavvas D. Postoperative complications of scleral buckling. *Semin Ophthalmol* 2018;33(1):70–74

21 Özkan SB. Restrictive problems related to strabismus surgery. *Taiwan J Ophthalmol* 2016;6(3):102–107

22 Benson SE, Schlottmann PG, Bunce C, Xing W, Charteris DG. Optical coherence tomography analysis of the macula after scleral buckle surgery for retinal detachment. *Ophthalmology* 2007;114(1):108–112

23 Nwosu SNN, Akudinobi C, Ndulue J. Incidence and pattern of retinal detachment in a tertiary eye hospital in Nigeria. *Niger J Ophthalmol* 2014;22(2):69

24 Misato Kobayashi, Takeshi Iwase, Kentaro Yamamoto, Eimei Ra, Norifumi Hirata, Hiroko Terasaki. Influence of submacular fluid on recovery of retinal function and structure after successful rhegmatogenous retinal reattachment. *PLoS One* 2019;14(7):e0218216

25 Tee JJ, Veckeneer M, Laidlaw DA. Persistent subfoveal fluid following retinal detachment surgery: an SD-OCT guided study on the incidence, aetiological associations, and natural history. *Eye (Lond)* 2016;30(3):481–487

26 Yang CH, Lin HY, Huang JS, Ho TC, Lin CP, Chen MS, Yang CM. Visual outcome in primary macula-off rhegmatogenous retinal detachment treated with scleral buckling. *Taiwan Yi Zhi* 2004;103(3): 212–217

- 27 Hassan TS, Sarrafzadeh R, Ruby AJ, Garretson BR, Kuczynski B, Williams GA. The effect of duration of macular detachment on results after the scleral buckle repair of primary, macula - off retinal detachments. *Ophthalmology* 2002;109(1):146-152
- 28 Schwartz SG, Kuhl DP, McPherson AR, Holz ER, Mieler WF. Twenty-year follow-up for scleral buckling. *Arch Ophthalmol* 2002;120(3):325-329
- 29 Thompson JA, Snead MP, Billington BM, Barrie T, Thompson JR, Sparrow JM. National audit of the outcome of primary surgery for rhegmatogenous retinal detachment. II. Clinical outcomes. *Eye (Lond)* 2002;16(6):771-777
- 30 Pastor JC, Fernández I, Rodríguez de la Rúa E, Coco R, Sanabria-Ruiz Colmenares MR, Sánchez-Chicharro D, Martinho R, Ruiz Moreno JM, García Arumi J, Suárez de Figueroa M, Giraldo A, Manzanás L. Surgical outcomes for primary rhegmatogenous retinal detachments in phakic and pseudophakic patients; the Retina 1 Project-report 2. *Br J Ophthalmol* 2008;92(3):378-382
- 31 Wilkinson JT, Richards AB, Choi D, Robertson JE Jr, Flaxel CJ. Incidence of retinal detachment after fellow-performed primary pars plana vitrectomy. *ISRN Ophthalmol* 2013;2013:353209
- 32 Lindsell LB, Sisk RA, Miller DM, Foster RE, Petersen MR, Riemann CD, Hutchins RK. Comparison of outcomes: scleral buckling and pars Plana vitrectomy versus vitrectomy alone for primary repair of rhegmatogenous retinal detachment. *Clin Ophthalmol* 2017;11:47-54
- 33 Khan B, Anand VS, Wasil A, Kashyap M. Excellent results of scleral buckling in the era of microincision vitreous surgery. *Egyptian Retina Journal* 2017;4(1):6
- 34 Huang CM, Fu T, Zhang TH, Wu XY, Ji Q, Tan RL. Scleral buckling versus vitrectomy for macula - off rhegmatogenous retinal detachment as assessed with spectral - domain optical coherence tomography: a retrospective observational case series. *BMC Ophthalmol* 2013;13(1):12
- 35 Mavrakanas N, Dhalla KA, Jecha J, Kapesa I, Odouard C, Murdoch I. Results and safety profile of trainee cataract surgeons in a community setting in East Africa. *Indian J Ophthalmol* 2016;64(11):818-821