

# Inhibitory effects of pioglitazone on alkaline burn-induced corneal neovascularization in rats

*Yi-Xia Zhang, Ming-Chang Zhang*

Department of Ophthalmology, Union Hospital, Affiliated Hospital of Tongji Medical College, Huazhong University of Science and Technology, Wuhan 430022, Hubei Province, China

**Correspondence to:** Ming-Chang Zhang, Department of Ophthalmology, Union Hospital, Affiliated Hospital of Tongji Medical College, Huazhong University of Science and Technology, Wuhan 430022, Hubei Province, China. mingchangzhang@hotmail.com

Received:2008-04-09 Accepted:2008-05-14

## Abstract

- **AIM:** To investigate the effects of pioglitazone on corneal neovascularization (CNV) induced by alkaline burn in rats and on expression of vascular endothelial growth factor (VEGF) and basic fibroblast growth factor (b-FGF).
- **METHODS:** CNV was induced by alkaline burn in rats which were then administered pioglitazone subconjunctivally. Corneal angiogenesis was evaluated and observed with a slit lamp microscope and the VEGF and b-FGF level were determined by immunohistochemistry and Western blot at different intervals.
- **RESULTS:** The CNV of the rats was shown two days after alkaline burn, and reached its highest level in 7-10 days. The mean values of the area and length of neovascularization and the VEGF and b-FGF levels in the pioglitazone-treated group were significantly lower than those in the control group at various time.
- **CONCLUSION:** Local application of pioglitazone could remarkably inhibit CNV, probably by means of downregulation of VEGF and b-FGF expression.
- **KEYWORDS:** pioglitazone; CNV; VEGF; b-FGF

Zhang YX, Zhang MC. Inhibitory effects of pioglitazone on alkaline burn-induced corneal neovascularization in rats. *Int J Ophthalmol* 2008;1(2):99-103

## INTRODUCTION

The cornea normally has no blood vessels, because of the presence of anti-angiogenesis factor and a barrier of anti-breakthrough factors in the corneal stroma. However, the balance could be disturbed in certain pathologic conditions, such as infection, external injury, graft rejection, and angiopoiesis. Corneal neovascularization (CNV) is a major cause of blindness and is a high risk factor for graft rejection after allograft corneal transplantation<sup>[1]</sup>. Therefore researchers have been seeking better methods to suppress CNV. Pioglitazone is a composite ligand of peroxisome proliferator-activated receptor-gamma (PPAR $\gamma$ ) used as an euglycemic agent in the treatment of diabetes. Recent studies showed that pioglitazone could inhibit the proliferation of vascular endothelial cells and angiopoiesis in cancer and arteriosclerosis patients. We applied pioglitazone to the rats with CNV induced by alkaline burn and investigated the inhibitory effects on the pathogenesis of CNV and the probable mechanisms.

## MATERIALS AND METHODS

**Materials** Sprague Dawley (SD) rats were obtained from the Experimental Animal Science Center of Tongji Medical College, Huazhong University of Science and Technology (Wuhan, China); Pioglitazone, Rabbit anti-rat VEGF and b-FGF monoclonal antibodies were purchased from Sigma and Santa Cruz Biotechnology (USA) respectively; SP immunohistochemistry kit was provided by Wuhan Boster Company (Wuhan, China). Total 96 healthy SD rats of random sex (150-180g), aged 2-3 months were used for the experiments.

**Methods** The rats were anesthetized by intraperitoneal injection with 100g/L chloral hydrate, and a topical application of 2.5g/L amethocaine hydrochloride. An alkaline burn was created in one eye of each rat by touching the central area of the cornea surface with a 3.0mm-diameter circular filter disc saturated with 1 mol/L NaOH

for 60 seconds. Cornea and conjunctival sac were then irrigated with 20mL physiological saline immediately after burning. The rats after alkaline burn in one eye were randomly divided into a treated group and a control group, each group having 48 rats. The treated group was administered subconjunctivally with 0.1mL pioglitazone (0.2g/L) immediately after alkaline burn and the control group was given physiological saline subconjunctivally every day. Eight animals of each group were sacrificed at day 0, 2, 5, 7, 10, and 14 after observation and measurement of CNV length. Each experimental cornea was divided into two halves in the middle. One half was placed into 40g/L paraformaldehyde phosphate buffer and the specimens were dehydrated and embedded in paraffin wax. The paraffin sections were prepared, then stained with HE, and observed with light microscope and detected with immunohistochemistry. The other half was homogenated on ice immediately for extraction of total protein of the cornea.

**Biomicroscopic examination** Before treatment each day the rats' eyes were examined, measured and serial photographs of the cornea were taken under the slit-lamp biomicroscope. Condition of corneal opacity, CNV, and conjunctival congestion were observed; several vessels having extensive branching were considered as CNV progress. The longest but least continuous curvature of CNV towards the center of corneal opacity was recorded as  $l$ . CNV was quantified by calculating the wedge-shaped area of vessel growth with the formula:  $S = C/12 \times 3.1416 [r^2 - (r-l)^2]$ , where  $S$  is the area,  $C$  is time (in hours),  $r$  is the radius of the cornea, and  $l$  is the length of new vessels.

**Immunohistochemical staining technique** Immunohistochemical staining was performed on 4mm thick paraffin sections. The sections were immersed in a solution of 3mL/L  $H_2O_2$  for 10 minutes to block endogenous peroxidase activity and then rinsed in distilled water. After thorough washing, the sections were incubated with normal goat serum for 10 minutes at room temperature to avoid non-specific binding of antibodies. Then, they were incubated in 37°C water baths for 1.5 hour with primary antibodies and washed three times for 5 minutes each in phosphate-buffered saline (PBS). In the negative controls we replaced the primary antibody with PBS. Then, they were incubated in 37°C water baths for 20 minutes with streptavidin-biotin-

peroxidase conjugated secondary antibodies and washed three times for 5 minutes each in PBS. The sections were stained with DAB and the duration was controlled for 8 minutes approximately. Finally, all sections were counterstained with hematoxylin. The slides were examined under a microscope and photographed after thorough washing. Positive cells exhibited brown granules in plasma and negative cells had only blue nuclei. Gray scale of rat cornea was examined using an HMIAS-2000 image analysis system with three random highpower fields of every sheet.

**Western blot analyses of VEGF and b-FGF in the cornea** The total protein content of lysates were extracted from corneas of the treated and control groups respectively by PBS with 1g/L SDS and 1g/L Triton according to the manufacturer's protocol at 0, 2, 5, 7, 10, 14 days after alkaline burn. The protein content of lysates was determined by Bradford protein assay method. Aliquots of the lysates were diluted 1:3 with sample buffer and heated for 5 minutes at 95°C. Equal amount of protein from lysates were subjected to 1 hour SDS-PAGE (120g/L separated gel) prepared in advance. The separated proteins were then transferred to polyvinylidene difluoride membranes. The blots were incubated for 2 hours at room temperature in blocking solution (Tris-buffered saline with 1mL/L Tween-20 containing 50g/L dry milk; TBST). They were incubated at 4°C for 24 hours with primary antibodies (VEGF and b-FGF) diluted with washing buffer (1:500). After incubation with the primary antibody, the blots were washed with TBST and incubated with biotinylated alkaline phosphatase-conjugated secondary antibodies diluted with washing buffer (1:800) for two hours in homeothermal swing bed. The blots were subsequently developed by enhanced chemiluminescence's system and scanned into a computer where band densities were processed by image software. The experiment was repeated once.

**Statistical Analysis** All data were expressed as the mean $\pm$ s. The data were statistically evaluated by analysis of variance. SPSS version 11.5 for Windows was used, and  $P < 0.05$  was considered significant.

## **RESULTS**

**Biomicroscopic Examination** Twenty-four hours after alkaline burn, vessels in the limbus of the cornea were congested and new vessels began to grow from the limbus to

**Table 1** The areas of NVs(mm<sup>2</sup>,mean±SD)and the longest lengths of NVs(mm, mean±SD) at various time in two groups after alkaline burn (n=8)

Group	Area of NVs ( mm <sup>2</sup> )			Longest length of NVs ( mm )		
	7d	10d	14d	7d	10d	14d
Control	47.09±3.69	44.67±2.69	35.39±3.15	2.25±0.22	2.20±0.22	1.64±0.27
Treatment	32.51±5.09	30.64±4.49	26.58±4.20	1.91±0.22	1.70±0.19	1.27±0.16

*P*<0.01

**Table 2** The expression of VEGF at various intervals in two groups (mean grey value mean±SD, n=20)

Group	2d	5d	7d	10d	14d
Control	158.22±4.21	119.28±3.41	131.46±3.55	143.32±2.98	166.31±3.57
Treatment	165.33±3.71	152.11±2.87	137.39±2.27	165.45±3.04	174.76±2.86

*P*<0.01

**Table 3** The expression of b-FGF in the control and treated group (mean grey value mean±SD, n=20)

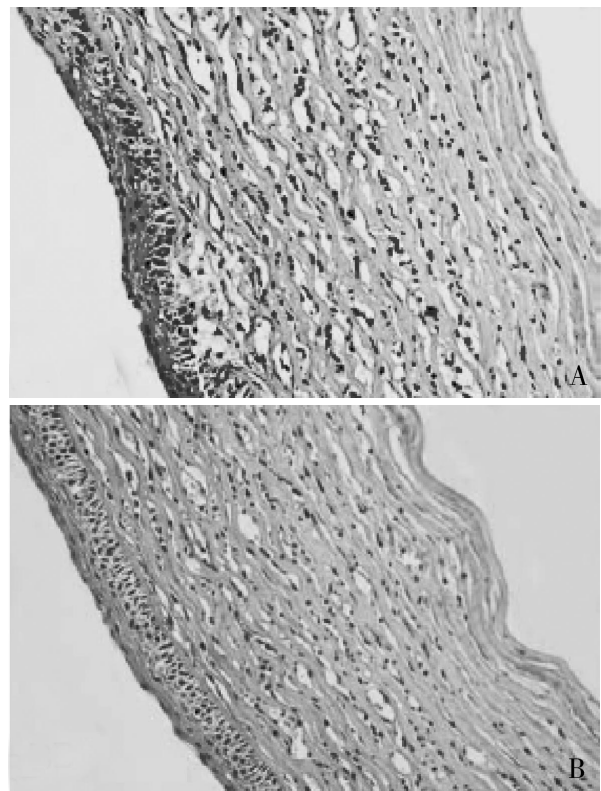
Group	2d	5d	7d	10d	14d
Control	179.29±5.23	156.43±3.95	143.55±3.52	149.47±2.51	158.57±3.54
Treatment	180.02±7.21	166.49±4.35	151.34±2.74	158.56±3.34	160.33±2.67

*P*<0.01

the transparent cornea. At day 2 they had a few branches and were anastomosed with each other. The areas of NV were increasing from day 2-7. The growth rate of NV areas was the fastest during day 3-7 and reached its peak at day 7. After day 10, the areas of CNV diminished, and some vessels became thinner, several of which were degenerated. In the pioglitazone treated group the cornea had less edema and inflammatory cell infiltration. The CNV emerged at day 3 after alkaline burn, and the areas of CNV were depressed and new vessels decreased in number, with narrow lumens in the treated group. The areas of CNV and the longest lengths of CNV were evaluated by variance at day 7, 10 and 14 in both groups and CNV was significantly reduced by treatment with pioglitazone (*P*<0.01) as seen in Table 1.

#### Immunohistochemical Analysis of VEGF and b-FGF

VEGF had no expression in epithelium, substantia propria layer and endothelium in the untreated rats. The positive expression of VEGF emerged in the corneal epithelium and substantia propria layer of treated rats at two days after alkaline burn. The VEGF expressions were correlated with duration of alkaline burn and reached their highest values at day 5. The expression of VEGF in the treated group *vs* control group was lower at several intervals (*P*<0.01) and the peak was delayed as seen in Table 2 and Figure 1 A and B. A few cells showed b-FGF in the normal corneal epithelium but not in the substantia propria layer. Inflammatory cell filtration and the evident expression of b-FGF were detected at day 2 after alkaline burn, located on the corneal epithelium, substantia propria layer and endothelium and



**Figure 1** Expressions of VEGF in corneal epithelium and stroma at 5 days after alkaline burn in the cornea in the control (A) and treatment (B) groups, showing Buffy staining (×400)

reached the highest level at day 7. The expression of b-FGF in the treated group was lower than in the control group at various time (*P*<0.01) as seen in Table 3.

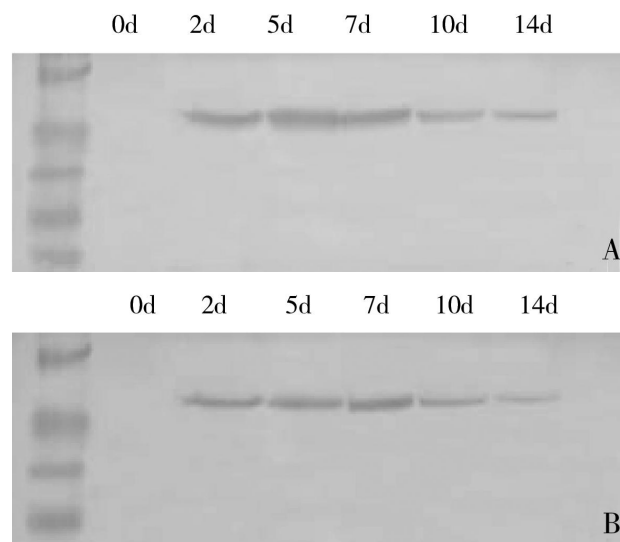
Western Blot Analyses of VEGF and b-FGF The bands of VEGF were thinner and less distinct in the Pioglitazone treated group as compared to the control group at various

time. The expression of VEGF peaked at day 5 in the control group and only at day 7 in the treated group as shown in Figure 2A and B. The expression of b-FGF was detected later than VEGF. In this study the expressions of b-FGF were lower in the treated group vs control group at various time and evident expression was seen at day 5 and reached its peak during day 7-10 as shown in Figure 3A and B.

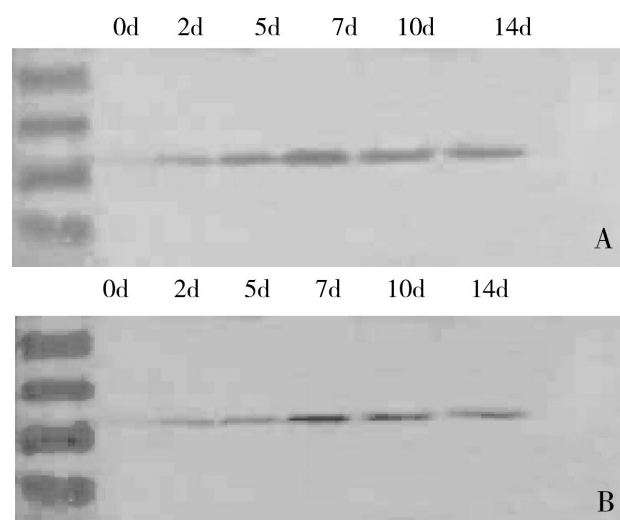
**DISCUSSION**

CNV is a major cause of vision loss in humans. Various mediators are involved in the mechanism of CNV, e.g. mediators of inflammation, cytokine, and angiogenin. The VEGF and b-FGF are important angiogenesis factors in the course of vascularization. Angiogenesis is a multiple factor process and VEGF is a core regulator. VEGF is the most specific and direct vascular endothelial cell-stimulating factor, which is directly bound to the surface receptor on the epithelial cells, thus advancing angiogenesis. High level expression of VEGF is necessary for developing and retaining CNV induced by an alkaline burn whereas decreasing levels of VEGF may cause the gradual degeneration of new vessels. b-FGF is a patented growth factor promoting vascular endothelial cell proliferation. The expressions of VEGF and b-FGF were coordinated to both the areas and lengths of CNV. Neovascularization was induced after a polymer micropellets implanted into corneal stroma. The expression of b-FGF was noticeable at 5 days after alkaline burn which is the time of CNV occurs<sup>[2,3]</sup>. Studies done by Qiu *et al*<sup>[4]</sup> showed that b-FGF was critical for regulation of the duration of CNV proliferation and expansion to inflammatory CNV.

PPAR $\gamma$  is a member of the Peroxisome proliferator-activated receptors (PPARs) superfamily that is ligand-activated transcription factors<sup>[5]</sup>. Pioglitazone, a synthetic ligand for PPAR $\gamma$ , has been initially described as an important regulator of adipogenic differentiation and glucose homeostasis. In addition, pioglitazone was implicated in the control of inflammatory processes<sup>[6]</sup> and in the modulation of the expression of various cytokines such as tumor necrosis factor alpha (TNF-alpha)<sup>[7]</sup> but its effect and role in the mechanism of CNV integrity has not been studied extensively. Vascularization is a vital process for volume increase and metastatic potential of tumors. PPAR-gamma ligands have anti-cancer properties as potent angiogenesis



**Figure 2 Expressions of VEGF at different intervals after corneal alkaline burn in the control (A) and treatment (B) groups**



**Figure 3 Expressions of b-FGF at different intervals after corneal alkaline burn in the control (A) and treatment (B) groups**

inhibitors *in vitro* and *in vivo*<sup>[8]</sup>. Murata *et al*<sup>[9]</sup> studied PPAR-gamma expression in human retinal pigment epithelial cells (RPEs) and bovine choroidal endothelial cells (CECs), and showed that two PPAR-gamma ligands inhibited choroidal neovascularization induced by laser photocoagulation. Sarayba *et al*<sup>[10]</sup> placed intrastromal polymer micropellets containing vascular endothelial growth factor (VEGF) and pioglitazone into the cornea of rats and found that the area and density of neovascularization were decreased. Pioglitazone offers a new approach for decreasing neovascularization by VEGF-induction. In this study the mean areas of neovascularization were reduced by

30.9% -31.4% and the longest lengths of CNV were decreased by 15.1% - 22.2% at day 7 and 10 in the pioglitazone treated group as compared to the control group at the corresponding time. These morphology data demonstrate that pioglitazone decreased remarkably the occurrence and development of CNV after alkaline burn. Meanwhile the expression of VEGF and b-FGF were considerably suppressed and delayed in the treated group, so this synergetic inhibiting effect on CNV was long-standing and sufficient. Down regulation of the pro-angiogenic expressions of VEGF and b-FGF was the probable mechanism. As detailed studies on biological mechanisms underlying angiogenesis of PPAR $\gamma$  and activators have shown, pioglitazone is a very promising, new approach to CNV therapy.

#### REFERENCES

- 1 George AJ, Arancibia-Cárcamo CV, Awad HM, Comer RM, Fehevari Z, King WJ, Kadifachi M, Hudde T, Kerouedan-Lebossé C, Mirza F, Oral HB, Rayner SA, Tan P, Tay E, Larkin DF. Gene delivery to the corneal endothelium. *Am J Respir Crit Care Med* 2000;162(4 Pt 2):194-200
- 2 Teicher BA, Alvarez E, Menon K, Esterman MA, Considine E, Shih C, Faul MM. Antiangiogenic effects of a protein kinase C $\beta$ -selective small molecule. *Cancer Chemother Pharmacol* 2002;49:69-77
- 3 Cheng JS, Xu JT. Corneal neovascularization. *Ophthalmol Chin* 2001;10:137-143
- 4 Qiu PJ, Yao K, Zhu LJ, Zhou CY, Qiu SJ. Expression and significance of basic fibroblast growth factor in rat cornea after cautery with alkali. *Chin Ophthalmic Res* 2002;20(2):101-104
- 5 Meissner M, Stein M, Urbich C, Reisinger K, Suske G, Staels B, Kaufmann R, Gille J. PPAR $\alpha$  activators inhibit vascular endothelial growth factor receptor-2 expression by repressing Sp1-dependent DNA binding and transactivation. *Circ Res* 2004;94(3):324-332
- 6 Bongartz T, Coras B, Vogt T, Schölmerich J, Müller-Ladner U. Treatment of active psoriatic arthritis with the PPAR $\gamma$  ligand pioglitazone: an open-label pilot study. *Rheumatology (Oxford)* 2005;44(1):126-129
- 7 Redondo S, Ruiz E, Santos-Gallego CG, Padilla E, Tejerina T. Pioglitazone induces vascular smooth muscle cell apoptosis through a peroxisome proliferator-activated receptor- $\gamma$ , transforming growth factor- $\beta$ 1, and a Smad2-dependent mechanism. *Diabetes* 2005;54(3):811-817
- 8 Margeli A, Kouraklis G, Theocharis S. Peroxisome proliferator activated receptor- $\gamma$  (PPAR- $\gamma$ ) ligands and angiogenesis. *Angiogenesis* 2003;6(3):165-169
- 9 Murata T, He S, Hangai M, Ishibashi T, Xiao-Ping Xi, Kim S, Hsueh WA, Ryan SJ, Law RE, Hinton DR. Peroxisome proliferator-activated receptor- $\gamma$  ligands inhibit choroidal neovascularization. *Invest Ophthalmol Vis Sci* 2000;41(8):2309-2317
- 10 Sarayba MA, Li L, Tungsiripat T, Liu NH, Sweet PM, Patel AJ, Osann KE, Chittiboyina A, Benson SC, Pershadsingh HA, Chuck RS. Inhibition of corneal neovascularization by a peroxisome proliferator-activated receptor- $\gamma$  ligand. *Exp Eye Res* 2005;80(3):435-442