

Quantitative research on effects of pyrrolidine dithiocarbamate on the aqueous flare in a PVR model with LFCM

Jian Jiao, Wu Liu, Bin Mo, Lin Yang

Eye Center, the Affiliated Beijing Tongren Hospital, Capital University of Medical Sciences, Beijing 100730, China

Correspondence to: Wu Liu. Eye Center, the Affiliated Beijing Tongren Hospital, Capital University of Medical Sciences, Beijing 100730, China. wuliubj@yahoo.com

Received: 2008-07-18 Accepted: 2008-08-12

Abstract

• **AIM:** To study the inhibitory effect of pyrrolidine dithiocarbamate (PDTC) on the inflammatory reaction in an experimental proliferative vitreoretinopathy (PVR) model with laser flare cell meter (LFCM).

• **METHODS:** A total of 20 pigmented rabbits were divided into two groups randomly, with 10 rabbits in each group. After the creation of retinal holes, 0.1mL PDTC was injected intravitreally into the right eyes of Group 1 (A1) and the left eyes of Group 1 (A2), and 0.1mL balanced saline solution (BSS) into the right eyes of Group 2 (B1). One hour later, 0.1mL BSS was injected into the eyes of A1, and 5000U IL-1 β in 0.1mL BSS was injected intravitreally into the eyes of A2 and B1. Clinical evaluation and LFCM examination were performed before retinal injury (P0) and at 4, 24 hours, 1, 2 and 4 weeks after the second injection (P4h, P24h, P1wk, P2wk and P4wk). Histopathologic and immunohistochemical examination were also performed at these time points.

• **RESULTS:** PDTC could inhibit the inflammatory reaction obviously from P24h to P2wk. The eyes of A1 and A2 recovered earlier than those of B1. Although inflammatory reaction in the 3 groups resolved completely by the end of P2wk measured with the slit-lamp microscope, the eyes of B1 still showed obvious aqueous flare judged by the LFCM compared with those of A1 and A2. Histopathologic and immunohistochemical examination showed that nuclear factor- κ B (NF- κ B) was activated by IL-1 β and the PDTC had inhibitory effect on it without obvious toxicity to retina.

• **CONCLUSION:** Inflammatory reaction is involved in the rabbit model of PVR induced by injecting intravitreally IL-1 β and the PDTC can relieve it significantly. The LFCM provides a new, sensitive, objective and non-invasive method to quantify the inflammatory reaction in the PVR model.

• **KEYWORDS:** interleukin-1 β ; inflammatory reaction; NF- κ B; pyrrolidine dithiocarbamate; laser flare cell meter

Jiao J, Liu W, Mo B, Yang L. Quantitative research on effects of pyrrolidine dithiocarbamate on the aqueous flare in a PVR model with LFCM. *Int J Ophthalmol* 2008;1(3):219-225

INTRODUCTION

Proliferative vitreoretinopathy (PVR) is one of the major causes of surgery failure for the repair of retinal detachment [1]. It has been clearly documented that inflammatory reaction plays an important role in PVR [2]. IL-1 β is involved in the acute phase response and is chemotactic for neutrophils, monocytes, and retinal pigment epithelial (RPE) cells *in vitro*. It stimulates proliferative responses in many tissues [3], and has been found in ocular fluids during inflammation, trauma and PVR. Kosnosky *et al* [4] had designed a model of PVR that relied on the actions of endogenous cells without lensectomy or vitrectomy. In this model, intraocular injection of IL-1 β and formation of retinal holes triggered a cascade of events including RPE hyperplasia, matrix metalloproteinases induction, and epiretinal membrane (ERM) formation that lead to PVR.

The NF- κ B is a pivotal regulator of many different genes, and a wide array of mediators related to inflammation require its activation for their expression in the inflammation [4]. Pyrrolidine dithiocarbamate (PDTC), an antioxidant and specific inhibitor of NF- κ B, has been shown to reduce retinal neovascularization without discernible toxicity in a mouse model [5] and to relieve the severity of inflammatory reaction during the PVR [6].

Slit-lamp microscopy is a standard and traditional method to assess inflammatory reaction in the anterior chamber (AC) of the eyes clinically. However, this technique is subjective and primarily qualitative, and may produce variable interobserver results. Laser flare cell meter (LFCM) is a new instrument developed by Sawae *et al* [7], which has been used to measure aqueous flare and cells in AC. It has been characterized as a sensitive, objective, and non-invasive

instrument to quantify inflammatory reaction [7,8]. Our purpose is to quantify the inflammatory reaction and to investigate the effects of PDTC on the aqueous flare in an experimental rabbit model of PVR with LFCM.

MATERIALS AND METHODS

Development of PVR Model Twenty pigmented rabbits weighing 2-2.5kg with either sex provided by the Experimental Animal Center of Tongren Hospital were used. The animals were clinically examined, especially the ocular structures, to ensure the absence of ophthalmopathy. The experimental rabbits were divided into 2 groups randomly, with 10 rabbits in each group. Experiments were done under sterile conditions and general anesthesia with intramuscular injection of 50mg/kg of 50g/L ketamine hydrochloride and 5mg/kg of 5g/L diazepam. Local anesthesia with Alcaine (Alcon, USA) was also given and pupils were dilated using a 1:1 solution of 10g/L phenylephrine hydrochloride and 25g/L cyclopentolate hydrochloride. Eyes were injected through the upper pars plana, 3mm from the limbus, by directing a 30-gauge needle toward the center of the vitreous cavity. One full-thickness hole (approximately 2 disc diameters in size) in the neurosensory retina was created by aspiration inferior to the nerve fiber layer using a 30-gauge cannula under the indirect ophthalmoscope.

After the creation of retinal holes, 0.1mL PDTC (1mmol/L, Sigma, USA) was injected intravitreally into eyes of A1 and A2, and 0.1mL balanced saline solution (BSS) into the eyes of B1. One hour later, 0.1mL BSS was injected intravitreally into the eyes of A1 (serving as the negative control), and 5 000U recombinant human IL-1 β (rh IL-1 β , CytoLab Ltd, USA) in 0.1mL BSS was injected intravitreally into the eyes of A2 (serving as the treated group) and the eyes of B1 (serving as the non-treated positive control) under the same condition as just now.

Clinical Evaluation Rabbits were examined by means of slit-lamp microscope, slit-lamp photography, indirect ophthalmoscope and fundus photography at P0, P4h, P24h, P1wk, P2wk and P4wk. Clinical observations were made regarding anterior segment inflammatory reaction, clarity of the cornea and lens, pupillary dilation, vascular tortuosity and dilation and hemorrhage of iris, distortion of medullary wings, presence of intravitreal haze and aggregate, formation of ERMs, tears and traction retinal detachment, etc.

LFCM LFCM examination was performed at P0, P4h, P24h, P1wk, P2wk and P4wk. The principle and mechanism of the LFCM had been described in detail by Sawa *et al* [7,8]. The light scattered by the solutes in the aqueous humor, composed primarily of protein and cells, was measured by a photo-counting photomultiplier. The intensity of the light scattered is proportional to the protein and cells

concentrations. Five measurements were performed in the mid-portion of the AC at every time point to calculate the mean value.

Histopathology and Immunohistochemistry Two eyes of each group were enucleated after the rabbits were killed by injecting air into the ear marginal vein at P4h, P24h, P1wk, P2wk and P4wk. Histopathologic examination of PVR and the toxicity of PDTC were performed after hematoxylin-eosin staining. To determine the inhibitory effect of PDTC on NF- κ B, immunohistochemical examination was performed with the monoclonal antibody against the p65 subunit of activated NF- κ B.

Statistical Analysis All data were expressed as mean \pm SD, and SPSS 10.0 statistical software was used. Independent samples *t*-test was used to analyze the difference among the 3 groups. *P*<0.05 was considered as statistically significant.

RESULTS

Slit-Lamp Microscopy and Slit-Lamp Photography

During the first 24 hours after surgery, the eyes of B1 showed an intense inflammatory reaction in the anterior segment. The perilimbal blood vessels began to show signs of engorgement at P4h and peaked at P24h, which was similar to the report of Kosnosky *et al* [1]. Inflammatory reaction in AC including protein, fibrous material and some cells began to increase steadily. Edema of upper conjunctiva and the corneal epithelium also occurred at P4h. The inflammation of the anterior segment was extremely serious at P24h: aqueous flare was obvious (Figure 1) and many fibrous materials were found in the lower portion of the AC or attached to the lens anterior capsule. Edema appeared in iris and its blood vessel was tortuous and the pupil was difficult to dilate (Figure 2, 3). The edema of the corneal epithelium disappeared at P24h. The inflammation of the anterior segment remained at this level for 3 to 4 days, then decreased slowly and resolved by the end of P2wk just with slit-lamp microscope alone.

As Kosnosky *et al* [1] reported, all the eyes in the controls showed few or no reactions. However, we found that the aqueous flare of the eyes in A1 (4 of 10 eyes) and A2 (9 of 10 eyes) was also obvious at P4h compared with normal eyes. Edema of the corneal epithelium also occurred (8 of 10 eyes in A1 and 10 eyes in A2) and hyperemia was also found at the upper conjunctiva in the eyes of A1 and A2 at P4h. All those disorders disappeared at P24h just with slit-lamp microscope alone (Figure 4). Therefore, we thought that those reactions were mainly related to the stimulus of operation, but not to the BSS or PDTC.

Indirect Ophthalmoscopy and Fundus Photography

Examinations of eyes in B1 using indirect ophthalmoscope showed moderate vitreous haze at P4h, but the retinas could

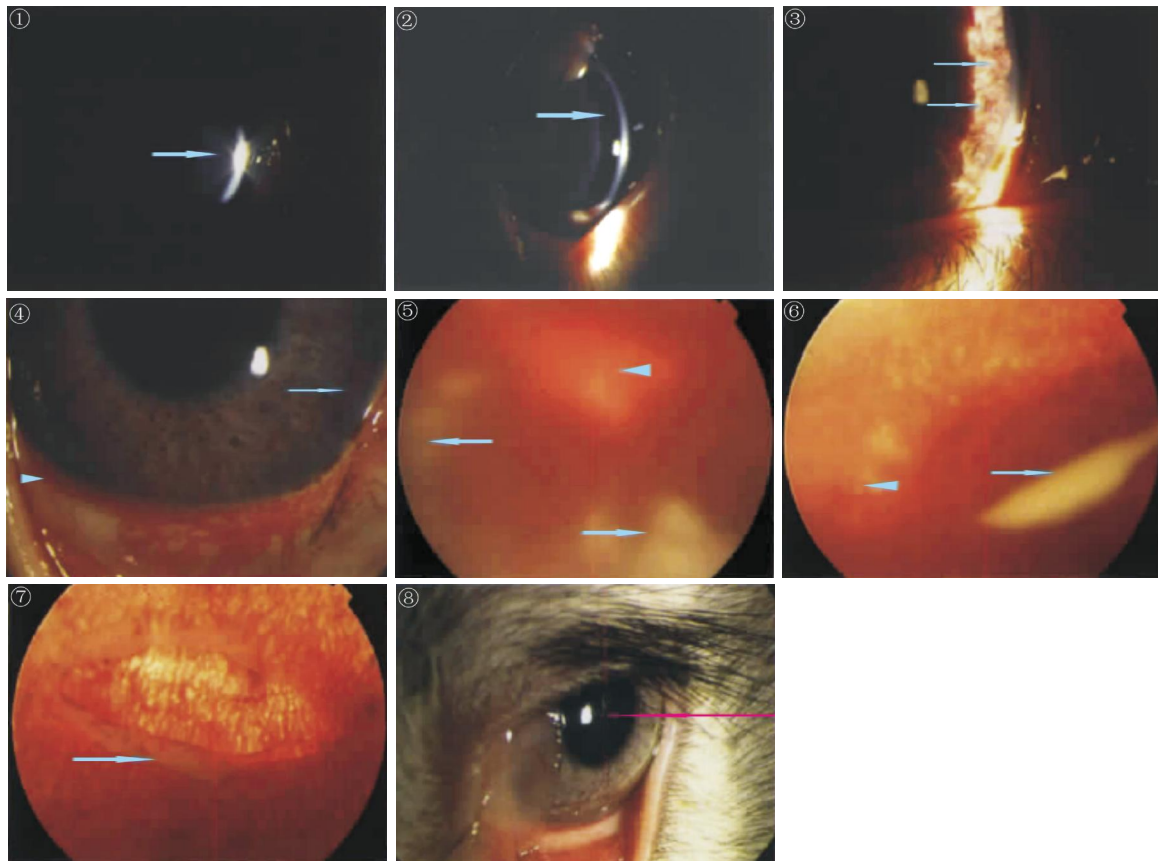


Figure 1 An eye in B1 at P24h showing obvious aqueous flare in AC (arrow)

Figure 2 Slit-lamp photograph of the anterior segment of an eye in B1 at P24h showing ciliary congestion (arrowhead), edema of iris, tortuosity and engorgement of the blood vessel in iris (arrow)

Figure 3 Slit-lamp photograph of the same eye in Figure 2 showing more apparent tortuosity and engorgement of the blood vessel in iris (arrows)

Figure 4 An eye in A2 at P24h showing no aqueous flare in AC (arrow)

Figure 5 Fundus photograph of an eye in B1 at P24h showing vitreous haze and aggregates (arrows). The retinal hole only showed vague outline (arrowhead) for the vitreous haze

Figure 6 Fundus photograph of an eye in B1 at P1wk showed vitreous haze and aggregates (arrows) began to relieve but still existed. The retinal hole still showed vague outline only (arrowhead)

Figure 7 Fundus photograph of an eye in A2 at P24h showing a retinal hole with the upturned edges of the neurosensory retina (arrow) but no vitreous haze or aggregates

Figure 8 The long eyelashes of rabbits might scatter the laser beam (long arrow) and interfere with the measurement

be examined clearly. At P24h, all the eyes in B1 showed an intense inflammatory reaction in the vitreous (Figure 5). The vitreous haze was so extreme that the retinas could hardly be examined, and all the eyes exhibited white aggregates in the midst of vitreous cavity. The haze and the aggregates were steadily increased and peaked at P2-4d, then the haze decreased slowly and the aggregates began to be absorbed (Figure 6). The aggregates disappeared completely by the end of P4wk. Highly refractile points suggesting cells or unabsorbed breakdown products were present in the vitreous body at P2wk (2 of 4 eyes), and became obvious in size at P4wk (2 of 2 eyes). ERMs developed in 2 eyes in the B1 at P4wk. ERMs originated from the retinal holes, extended into

the vitreous body, and formed adhesions to other portion of the retina. Local traction retinal detachment around the retinal holes also developed in both of the 2 eyes.

Aggregation but no haze also appeared in 1 eye of the A2 at P24h, but was little in size and absorbed completely at P1wk. Then the posterior segment of all the eyes in A1 and other eyes in A2 showed only trace reaction by the needle and the holes of the neurosensory retinas could be found with upturned edges but without vitreous haze or aggregates at P24h (Figure 7). No ERMs developed in any eyes in A1 or A2 at P4wk.

LFCM The long eyelashes of rabbits might influence the results of measurement (Figure 8). The changes of aqueous

Table 1 Time course of aqueous flare (photon count/ ms) and the cell count (1/0.075mm³)

Group		Time points					
		P0	P4h	P24h	P1wk	P2wk	P4wk
		n=10	n=10	n=8	n=6	n=4	n=2
A1	flare	1.470 ± 1.178	35.689 ± 32.724	4.934 ± 1.448	1.519 ± 0.762	1.117 ± 0.947	0.850 ± 0.449
	cell	0.9447 ± 1.004	5.024 ± 5.147	1.768 ± 0.797	1.297 ± 1.554	1.083 ± 1.950	0.667 ± 0.471
A2	flare	1.530 ± 1.336	58.840 ± 52.043	18.374 ± 3.289	4.011 ± 1.384	1.683 ± 0.475	0.850 ± 0.117
	cell	1.111 ± 0.944	5.512 ± 6.543	4.267 ± 1.456	0.984 ± 0.764	0.250 ± 0.167	0.667 ± 0
B1	flare	1.500 ± 1.232	105.387 ± 117.14	183.720 ± 41.491	23.637 ± 11.883	3.350 ± 1.233	2.217 ± 0.495
	cell	1.029 ± 0.947	8.518 ± 6.495	76.056 ± 51.455	7.137 ± 2.392	0.583 ± 0.569	0.500 ± 0.235

All the data were shown as mean ± SD

flare and the cell count measured with the LFCM were shown in Table 1 and Figure 9,10. As the cell count was not fully reliable, we evaluated the inflammation just with the aqueous flare. The comparisons between the 3 groups at different time points were shown in Table 2, from which we could conclude that eyes in the 3 groups had no significant difference at P0, and then they could be merged into 1 group (G0). It should be notified that the eyes in G0 were the normal eyes before injected intravitreally actually. Then we compared the eyes in the 3 groups at different time points after injecting intravitreally with the eyes in G0 and got the data in Table 3. From these data we concluded that the inflammatory reaction was involved in the PVR model induced by injecting intravitreally IL-1β, and that the PDTC could relieve the inflammation significantly. Of course, because of the limited sampling size, the data at P2wk and P4wk might need further confirmation.

Histopathology and Immunohistochemistry Histopathological and immunohistochemical examination showed that NF-κB was activated by IL-1β and the PDTC had inhibitory effect on it without obvious toxicity to the retinas. Data were not shown because we had no special interest in them in this paper.

DISCUSSION

In Kosnosky's model albino rabbits were used. Baudouin *et al*^[9] developed a model of PVR by intravitreally injecting solution of platelet-rich plasma into the eyes of pigmented and albino rabbits. In that model, albino rabbits showed fewer retinal detachments and less intense cellular proliferation and ERMs formation. It was thought to be a result of the lower activity of RPE cells in albino rabbits. Therefore, pigmented rabbits were used also in our experiment to ensure a more efficient model.

In Kosnosky's model, 250U of rh IL-1β (Eli Lilly, USA) in 0.1mL BSS were injected intravitreally. Although 5 000U of

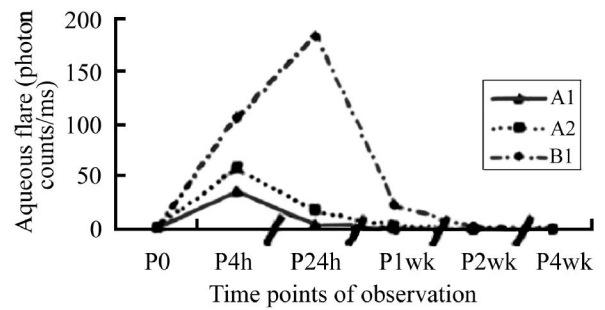


Figure 9 Changes in aqueous flare after intravitreal injection of IL-1β

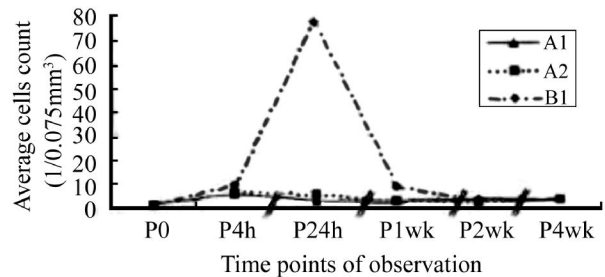


Figure 10 Changes in aqueous cells after intravitreal injection of IL-1β

Table 2 P values for the comparison of aqueous flare count between the 3 groups at various time points

Comparison	Time points					
	P0	P4h	P24h	P1wk	P2wk	P4wk
A1-A2	0.957	0.249	0.000	0.003	0.326	1.000
A1-B1	0.891	0.087	0.000	0.006	0.028	0.253
A2-B1	0.937	0.266	0.000	0.010	0.045	0.321

Table 3 P values for the comparison of the eyes in 3 groups after intravitreal injection at different time points with the eyes before intravitreal injection (G0)

Comparison	Time points				
	P4h	P24h	P1wk	P2wk	P4wk
A1-G0	0.000	0.000	0.973	0.559	0.219
A2-G0	0.000	0.000	0.000	0.068	0.471
B1-G0	0.000	0.000	0.000	0.049	0.596

rh IL-1 β (CytoLab Ltd, USA) in 0.1mL BSS were injected the same way in our model, the inflammatory reaction was not as serious as that in Kosnosky's model. This might result mainly from the difference of the activities of IL-1 β . In Kosnosky's model, the activity of IL-1 β was determined by a thymocyte proliferation assay^[10] using cells from C3H/HeJ mice. The activity of IL-1 β we used was determined by the dose-dependent stimulation of the proliferation of murine D10S cells. Different cell lines might result in different activity units.

The maintenance of the normal aqueous humor depends on the integrity of the blood-aqueous barrier that resides in the non-pigmented epithelium of the ciliary body and the capillary endothelium of the iris vessels. Inflammation of the anterior segment of the eyes causes breakdown of the blood-aqueous barrier, which results in an increase in the protein concentration and in the number of cells in aqueous humor. Slit-lamp microscopy has been the method to evaluate the degree of the inflammation, but it is qualitative and subjective. Little *et al*^[11] found the blood-aqueous barrier breakdown in rhegmatogenous retinal detachment using the technique of anterior segment fluorophotometry, another quantitative method to evaluate the permeability of the blood-aqueous barrier. But fluorescein maybe had adverse effects on some patients and repeated blood samplings were required. The LFCM provided us a new, sensitive, objective and non-invasive method to quantify the inflammatory reaction. Amann *et al*^[12] found breakdown of the blood-aqueous barrier in retinal detachment with LFCM, but they did not describe the continuous procedure.

Increased levels of cytokines were found in the vitreous cavity of the eyes with PVR^[13] and a variety of cytokines had been identified on ERMs removed surgically from patients with PVR as well as on the ERMs produced experimentally^[14]. NF- κ B was widely expressed and was a pivotal regulator of many different genes. NF- κ B was usually retained in an inactive form in the cytoplasm through association with a inhibitory- κ B protein (I κ B)^[15]. After stimulation, I κ B was phosphorylated as serines 32 and 36 by I κ B Kinase (IKK), ubiquitinated, and degraded by the 26S proteasome complex. Removal of I κ B protein from the complex enabled NF- κ B to translocate to the nucleus where it controlled the transcription of many cytokines and adhesion molecules. Researches had shown that IL-1 β , TNF- α , LPS and hypoxia could degrade I κ B and activate NF- κ B^[16] and NF- κ B was involved in the formation of retinal neovascularization^[5] and ERMs in PDR^[17].

The mechanism of NF- κ B inhibition by PDTC was thought to be as follows^[18]: PDTC suppressed reversibly the release

of an inhibitory subunit I κ B from the latent cytoplasmic form of NF- κ B in cells treated with inflammatory mediators. PDTC was known to possess at least two chemical properties: one was potent antioxidative activity. Reactive oxygen intermediates had been proposed to mediate the NF- κ B activation induced by a variety of proinflammatory stimuli, including IL-1, LPS and TNF- α ^[19, 20]. The second was a heavy metal chelating activity.

From the results we found that PDTC could inhibit the inflammatory reaction obviously from P24h to P2wk. The inflammatory reaction in the 3 groups decreased slowly and resolved by the end of P2wk just with the slit-lamp microscope. However, the eyes in B1 still showed obvious aqueous flare compared with those in A1 and A2 judged by the LFCM at P2wk, which meant that LFCM was more sensitive than the slit-lamp microscope in detection and quantification of weak inflammation. At the same time, the differences between A1 and A2 were still obvious from P24h to P1wk. From this result we could conclude that PDTC inhibited the activity of NF- κ B obviously but not completely. In the experiment of Yashida *et al*^[5], administration of 1nmol PDTC resulted in a maximal reduction of 71% of NF- κ B-positive cells, and a further increase in the amount at 10nmol PDTC did not increase its inhibitory effect on NF- κ B. This suggested that there were other inflammatory factors that were not induced by NF- κ B, such as Sp1 and hypoxia-inducible factor-1^[19], accounting for the inflammation during the PVR or that NF- κ B could be activated in other ways that could not be blocked by the PDTC. Improvement of the delivery system of PDTC and combination with other NF- κ B inhibitors, such as anti-sense oligonucleotides, oligodeoxyribonucleotide and decoy oligodeoxyribonucleotides, might be more effective.

Standard deviations were much apparent in the 3 groups at P4h compared with other time points, which meant great data variation at P4h. For the same reason, although the means of the data in the 3 groups at P4h seemed different, there were no significantly statistical differences between them. We think that there are several factors accounting for the apparent standard deviations. The first is the individual difference. Some rabbits might be more sensitive to the stimulations and therefore showed obvious inflammation in the AC while other less sensitive ones showed little reaction within the limited time. The second is the error in the measurement. According to the mechanism of the LFCM, the scattered light was measured by a photo-counting photomultiplier. Then a measurement error would occur if the laser beam was scattered by any other things from the optical scanner to the photomultiplier. In fact, edema of the

corneal epithelium was found in most eyes of the 3 groups at P4h in our observation and the opaque epithelium then might affect the measurement. Additionally, the long eyelashes of rabbits might scatter the light and hence cause a measurement error (Figure 8). So we believe the results at P4h are not completely reliable and the inhibitory effects of PDTC in this PVR model at P4h should not be evaluated.

We also considered several other problems to which attention needs to be paid when LFEM was used to quantify the inflammation in the PVR model. First, when the inflammation was extremely intense, the random measurement error would be obvious, particularly in the cell count. According to the mechanism of the LFCM, if any particle scattering laser beam causes a peak which exceeds 4 photon counts per 400 μ s, the cell will be counted [7,8]. The inflammatory reaction of the eyes in B1 at P24h was so severe that much fibrous material was found in the lower portion of the AC, and it might be counted as cells and then interfered with the result. According to Sawa's reports [7,8], when the difference between values of background laser scattering exceeded 20%, the measurement should be abandoned. For some rabbits in B1 at P4h or P24h, although we repeated the operation for many times, the cell count and the value of background laser scattering were still unacceptable. Ni *et al* [21] also found that the LFCM reported cells in AC in the intravenous endotoxin-induced uveitis (EIU) rabbit model of ocular inflammation despite negative cytological and histological results, and the LFCM also recorded cells in bovine serum albumin solutions which contained neither cells nor latex particles. They suggested that though the LFCM might be useful, its cell measurements were not accurate in cases of severe inflammatory reaction. Consequently, we did not quantify the inflammation or evaluate the inhibitory effect of PDTC on NF- κ B with the cell count in our experiment either.

Second, the long eyelashes of rabbits might interfere with the measurement as we had described, especially when the inflammatory reaction was severe, spasmus nictitans and photophobia were obvious and the long eyelashes would bring more troubles to the operations. So removing the eyelashes and giving local anesthesia might be useful. Although local anesthesia could cause edema and opacity of corneal epithelium and interfere with the results theoretically, we found it made little difference in our experiment actually. We assumed that measurements were performed immediately after the local anesthesia was given, and the changes caused by local anesthesia did not occur.

Of course, the sample size was limited in our experiments. Especially for the histopathology and immunohistochemi-

stry examination, two eyes were enucleated at every time point and then only two eyes remained to be measured in every group at P4wk. Moreover, more time points of observation are required to capture the continuous changes of the inflammatory reaction during the PVR, such as P12h, P48h, P72h and P3wk, etc.

In conclusion, inflammatory reaction is involved in the experimental rabbit model of PVR and PDTC can significantly relieve the inflammation, which is related to the inhibitory effects on the activity of NF- κ B. Although there are some problems which need to be overcome, the LFCM provides us with a new, sensitive, objective and non-invasive method to quantify the inflammatory reaction of the AC in the PVR model.

Acknowledgements: The authors would like to thank Dr. Wen-Bin Wei and Hong Wang for their help.

REFERENCES

- 1 Kosnosky W, Li TH, Pakalnis VA, Fox A, Hunt RC. Interleukin-1 β changes the expression of metalloproteinases in the vitreous humor and induces membrane formation in eyes containing preexisting retinal holes. *Invest Ophthalmol Vis Sci* 1994;35:4260-4267
- 2 Baudouin C, Fredj-Reygrobellet D, Gordon WC, Baudouin F, Peyman G, Lapalus P, Gastaud P, Bazan NG. Immunohistologic study of epiretinal membranes in proliferative vitreoretinopathy. *Am J Ophthalmol* 1990;110:593-598
- 3 Kirchof B, Kirchof E, Ryan SJ, Dixon JF, Barton BE, Sorgente N. Macrophage modulation of retinal pigment epithelial cell migration and proliferation. *Graefes Arch Clin Exp Ophthalmol* 1989;27:60-61
- 4 May JM, Ghosh S. Signal transduction through NF- κ B. *Immunol Today* 1988;10:80-88
- 5 Yoshida A, Yoshida S, Ishibashi T, Kuwano M, Inomata H. Suppression of retinal neovascularization by the NF- κ B inhibitor pyrrolidine dithiocarbamate in mice. *Invest Ophthalmol Vis Sci* 1999;40(7):1624-1629
- 6 Liu W, Yin XT, Dong DS, Li B, Li LQ. Preliminary experimental study of the effect of NF- κ B on intraocular inflammation and proliferative retinopathy. *Ophthalmol CHV* 2002;11(3):169-172
- 7 Sawa M, Tsurimaki Y, Tsuru T, Shimizu H. New quantitative method to determine protein concentration and cell number in aqueous *in vivo*. *Jpn J Ophthalmol* 1988;32(2):132-142
- 8 Sawa M. Clinical application of laser flare cell meter. *Jpn J Ophthalmol* 1990;34:346-363
- 9 Baudouin C, Khosravi E, Pisella PJ, Ettaiche M, Elena PP. Inflammation measurement and immunocharacterization of cell proliferation in an experimental model of proliferative vitreoretinopathy. *Ophthalmic Res* 1998;30(6):340-350
- 10 Gery I, Waksman BH. Potentiation of the T-lymphocyte response to mitogens: Part II: The cellular source of potentiating mediator (s). *J Exp Med* 1972;136:143-155
- 11 Little BC, Ambrose VM. Blood-aqueous barrier breakdown associated with rhegmatogenous retinal detachment. *Eye* 1991;5:56-62
- 12 Amann T, Nguyen NX, Kuchle M. Tyndallometry and cell count in the anterior chamber in retinal detachment. *Klin Monatsbl Augenheilkd* 1997;210(1):43-47
- 13 Elnor SC, Elnor VM, Jaffe GJ, Stuart A, Kunkel SL, Strieter RM. Cytokines in proliferative diabetic retinopathy and proliferative vitreoretinopathy. *Curr Eye Res* 1995;14(11):1045-1053
- 14 Limb GA, Alam A, Earley O, Green W, Chignell AH, Dumonde DC. Distri-

bution of cytokine proteins within epiretinal membranes in proliferative vitreoretinopathy. *Curr Eye Res* 1994;13(11):791-798

15 Haskill S, Beg AA, Tompkins SM, Morris JS, Yurochko AD, Sampson-Johannes A, Mondal K, Ralph P, Baldwin AS Jr. Characterization of an immediate-early gene induced in adherent monocytes that encodes I kappa B-like activity. *Cell* 1991;65(7):1281-1289

16 Wang XC, Jobin C, Allen JB, Roberts WL, Jaffe GJ. Suppression of NF-kappaB-dependent proinflammatory gene expression in human RPE cells by a proteasome inhibitor. *Invest Ophthalmol Vis Sci* 1999;40:4777-4786

17 Harada C, Harada T, Mitamura Y, Quah HM, Ohtsuka K, Kotake S, Ohno S, Wada K, Takeuchi S, Tanaka K. Diverse NF-kappa B expression in epiretinal membranes after human diabetic retinopathy and proliferative vitreoretinopathy. *Mol Vis* 2004;15(10):31-36

18 Kawai M, Nishikomori R, Jung EY, Tai G, Yamanaka C, Mayumi M, Heike T. Pyrrolidine dithiocarbamate inhibits intercellular adhesion molecular-1 biosynthesis induced by cytokines in human fibroblasts. *J Immunol* 1995;154:2333-2341

19 Schulze-Osthoff K, Los M, Baeuerle PA. Redox signaling by transcription factors NF-kappaB and AP-1 in lymphocytes. *Biochem Pharmacol* 1995;50:735-741

20 Yoshida S, Ono M, Shono T, Izumi H, Ishibashi T, Suzuki H, Kuwano M. Involvement of interleukin-8, vascular endothelial growth factor, and basic fibroblast growth factor in tumor necrosis factor alpha-dependent angiogenesis. *Mol Cell Biol* 1997;17(7):4015-4923

21 Ni M, Bloom JN, Lele S, Sotelo-Avila C. A laboratory evaluation of the Kowa laser flare-cell meter for the study of uveitis. *Graves Arch Clin Exp Ophthalmol* 1992;230(6):547-551