

# Combined lens and vitreoretinal surgery in patients with traumatic cataract and intraocular foreign body

Shi-Hong Zhao, Yuan Zhang, Jin-Hui Wu, Dong-Yan Pan, Xin Liu, Yu Xu

**Foundation items:** National Natural Science Foundation of China (No.30572000); Army Medical Hygiene Research Foundation (No. 06Z025)

Department of Ophthalmology, Changhai Hospital Affiliated to the Second Military Medical University, Shanghai 200433, China

**Correspondence to:** Shi-Hong Zhao. Department of Ophthalmology, Changhai Hospital Affiliated to the Second Military Medical University, Shanghai 200433, China. zhaosh2001@sina.com

Received:2008-12-07 Accepted:2009-01-12

## Abstract

•AIM: To analyze the postoperative anatomical and functional outcomes as well as complications after combined phacoemulsification, pars plana vitrectomy (PPV), removal of the intraocular foreign body (IOFB) and intraocular lens (IOL) implantation in patients with traumatic cataract and intraocular foreign body.

•METHODS: Medical records of 13 patients (13 eyes) with traumatic cataract and IOFB who had undergone combined phacoemulsification, PPV, foreign body extraction and IOL implantation were retrospectively analyzed. The postoperative follow-up ranged from 2 to 12 months. The main measurements of outcomes were the extraction success of cataract and intraocular foreign body, intraoperative and postoperative complications and the final best corrected visual acuity (BCVA).

•RESULTS: The mean age of 13 patients(10 male, 3 female) was 36.8 years (range: 17-65 years). All eight IOFBs were removed. Four intraocular lenses were implanted after vitrectomy intraoperatively. In 5 cases, intraocular lenses were implanted during the second operation. Intraocular lenses were not implanted in 4 cases. BCVA at last ranged from 0.8 to hand movement. BCVA was 0.5 or better in four eyes, 0.1 to 0.4 in five eyes, less than 0.1 in four eyes. Intraoperative complications were encountered in 3 patients. They had vitreous hemorrhage. Postoperative complications were encountered in 2 patients. They had retinal detachment. The reoperations of the two patients were successful.

•CONCLUSION: The combined phacoemulsification, PPV, re-

moval of IOFB and IOL implantation is safe and effective for patients with traumatic cataract and intraocular foreign body. The visual outcome depended primarily on the corneal or scleral wound and underlying posterior segment pathology and sites.

•KEYWORDS: traumatic cataract; intraocular foreign body; phacoemulsification; vitrectomy; intraocular lens

Zhao SH, Zhang Y, Wu JH, Pan DY, Liu X, Xu Y. Combined lens and vitreoretinal surgery in patients with traumatic cataract and intraocular foreign body. *Int J Ophthalmol* 2009;2(1):61-64

## INTRODUCTION

Penetrating eye injuries caused by intraocular foreign bodies are often complicated with traumatic cataract. The primary indication for the removal of cataract is significant lens opacification that diminishes visualization of the posterior segment and hinders the operation of foreign body extraction. Phacoemulsification has many advantages over lensectomy and extracapsular cataract extraction. Smaller incision induces less astigmatism, and makes the globe more stable. Postoperative rehabilitation is also faster<sup>[1,2]</sup>. Lensectomy is the removal of the cataract during a vitrectomy procedure. The lens is usually removed completely, with its anterior and posterior capsule. Pars plana vitrectomy (PPV) is the leading method for the management of intraocular foreign bodies<sup>[3,4]</sup>. This study retrospectively reviewed the visual outcome and the intraoperative and postoperative complications in patients with penetrating eye injury with an intraocular foreign body and traumatic cataract. These patients had combined phacoemulsification, pars plana vitrectomy, intraocular foreign-body extraction. Some patients had intraocular lens (IOL) implantation.

## PATIENTS AND METHODS

We reviewed 13 patients with penetrating eye injury and retained intraocular foreign body. The patients had clinically significant lens opacification and intraocular for-

foreign body with concomitant vitreoretinal pathology. Ten patients were male and three patients were female. The mean age was 36.8 years (range: 17-65 years). The right eye was involved in 9 patients and the left eye in 4 patients. All patients underwent a complete general ophthalmological examination before the surgical procedure. Ultrasound examination (B-scan, Figure 1) and computerized tomography (CT)(Figure 2) were performed to assess posterior segment status and evaluate the intraocular foreign body. The intraocular lens (IOL) power was calculated by the SRK II formula. The normal fellow eye was used to calculate the IOL power when fundus pathology precluded the accurate measurements.

All patients were operated on under the peribulbar block. In 3 cases, the foreign body entered through the sclera. Scleral wounds were sutured with interrupted 8-0 absorbable sutures. In 4 patients, corneal penetrating wound was self-sealed and required no further treatment. In 6 cases, corneal penetrating wound was closed with interrupted 10-0 nylon sutures(Table 1).

Phacoemulsification for cataract was performed before the vitreoretinal procedure. A scleral incision was followed by continuous curvilinear capsulorhexis and hydrodissection. Phacoemulsification was done in the capsular bag, followed by the irrigation/aspiration of the remaining cortical lens material. Very low phaco-power was used for the nuclei that were relatively soft. In some cases, only irrigation and aspiration mode of the phacoemulsification machine was used for the cataract removal. The incision was closed with a single 8-0 absorbable suture before the vitrectomy.

A standard 3 port PPV was performed, which included removing intraocular foreign body with a forceps (scleral incision of pars plana was expanded for bigger intraocular foreign body), peeling of the posterior hyaloid membrane, epiretinal membrane peeling, photocoagulation, cryotherapy, fluid-gas exchange and gas or silicone oil injection in appropriate cases. Endolaser was used in cases with a retinal rupture or where an intraocular foreign body was found embedded in the retina. A foldable acrylic intraocular lens was implanted in some cases after vitrectomy. After surgery, sclerotomies and conjunctival incisions were closed, and dexamethason was injected subconjunctivally. Postoperatively all patients received topical tobramycin+dexamethason drops for 2 weeks.

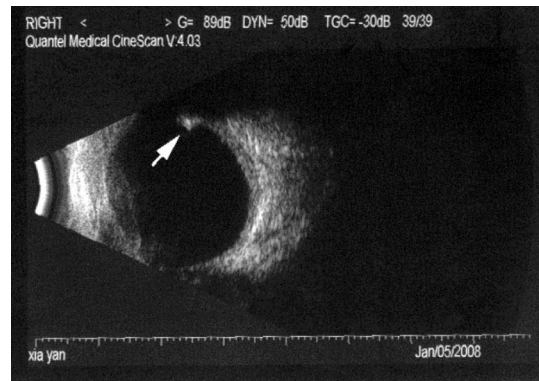


Figure 1 B-scan ultrasonography of an intraocular foreign body (arrow) embedded in the retina of the patient No. 5

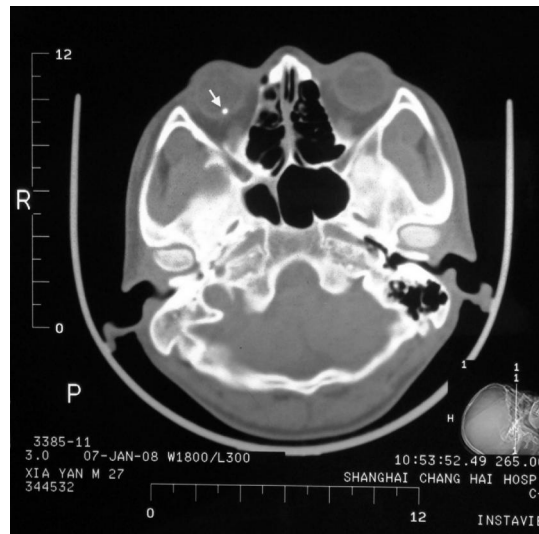


Figure 2 Computerized tomography of an intraocular foreign body (arrow) embedded in the retina of the patient No. 5

Postoperative follow-up ranged from 2 to 12 months. The intraoperative and postoperative complications, postoperative anterior segment findings in slit-lamp biomicroscopy, intraocular pressure, posterior segment findings in indirect ophthalmoscopy and the final BCVA were recorded.

## RESULTS

All IOFBs were removed. In 5 cases, only irrigation and aspiration mode of the phacoemulsification machine was used for the cataract removal. An enlargement of the posterior capsule tear was observed in only 1 case (No. 6). Lensectomy was performed. Four intraocular lenses were implanted after vitrectomy intraoperatively. Intraocular lenses were implanted during the second operation in 5 cases. Intraocular lenses were not implanted in 4 cases. Wound leakage, IOL decentration or capsule con-

**Table 1 Characteristics of the patients**

Patient No.	age	wound size(mm)	entry site	time to surgery	preoperative visual acuity	postoperative visual acuity
1	35	2	S	4d	0.04	0.5
2	42	3	C	11d	HM	0.04
3	18	2	C	15h	0.06	0.4
4	54	4	S	6d	0.04	0.3
5	27	3	C	2d	HM	0.1
6	32	3	C	12h	LP	HM
7	17	1	S	23d	0.1	0.8
8	51	4	C	18d	HM	0.08
9	65	2	S	12d	0.06	0.3
10	25	2	S	5d	0.2	0.6
11	28	3	C	21h	LP	0.06
12	38	1	C	16d	HM	0.1
13	46	3	S	4d	0.2	0.5

C:cornea; S:sclera; HM:hand movement; LP:light perception

traction were not seen in any of our cases. In 6 cases fluid-gas exchange with perfluorocarbon ( $C_3F_8$ ) was performed. In one case silicone oil tamponade was performed.

BCVA at the last follow-up ranged from 0.8 to hand movement. BCVA was 0.5 or better in four eyes, 0.1 to 0.4 in five eyes, less than 0.1 in four eyes. The BCVA of sclera injury was better than that of cornea (Table 1). The best postoperative visual acuity of No. 6 and No. 11 patients were poor even though the time to surgery is 12 hours and 21 hours. Because the IOFB injured the central cornea and the macular region. The IOFB of No.7 patient was in the vitreous and it injured sclera (1mm wound size), so his BCVA was 0.8. Vitreous hemorrhage was observed in the three patients. Raising the infusion bottle increased the intraocular pressure, and the hemorrhage subsided in both patients. All these intraoperative complications were solved immediately without further consequences. Postoperative complications were observed in 2 patients. In patients No. 2 and No.6, retinal detachment occurred on the postoperative day 69 and 115 respectively. In both patients reoperations were performed with vitrectomy and endolaser. In the patient No. 2 the vitreous was filled with perfluorocarbon ( $C_3F_8$ ). The other case was filled with silicone oil tamponade. In these two patients, visual acuity was less than 0.1 at the last follow-up.

## DISCUSSION

We reviewed outcomes and complications of 13 patients with significant lens opacification and intraocular foreign body with concomitant vitreoretinal pathology, who underwent phacoemulsification, PPV, removal of the IOFB and implantation of the intraocular lens in some cases. Removal of a cataract is necessary for safe performance of vitrectomy to get an adequate view and better access to the vitreous base, especially in the inferior quadrants during vitrectomy. Removal is also helpful for the fast visual rehabilitation after vitrectomy. Cataract surgery by phacoemulsification was performed before the vitrectomy in this series. It is possible that small incision phacoemulsification surgery with foldable IOLs allow better retinal visualization after cataract extraction than older techniques<sup>[5,6]</sup>. However, it has also been stated that phacoemulsification is not suitable in the presence of a lens-vitreous mixture, evidence of zonular dehiscence or large posterior capsule tear. In these circumstances, phaco-probe aspiration of vitreous would cause excessive vitreous traction and might tear the retina<sup>[7,8]</sup>. In our cases, we observed an enlargement of the posterior capsule tear in only 1 case (No.6). Lensectomy was performed.

An important consideration in cases of combined surgery is the timing of IOL implantation. We suggested that IOL implantation should be delayed until the vitrectomy was completed, as this avoids light reflexes and the prismatic effects from the lens that might complicate visualization of the posterior pole, especially the most peripheral retina. Another aspect of combined surgeries is the type of the incision and the IOL to be used. Silicone oil

tends to condense on silicone IOLs. Therefore, silicone IOLs must be avoided in combined operations. Instead, acrylic polymer IOL should be used. Scleral tunnel with hydrophobic acrylic IOLs were used in all our cases. Scleral incisions were safe in the combined surgery and were associated with less postoperative inflammation. We performed intraocular lenses implantation in 9 eyes. In 4 cases, intraocular lenses were implanted after vitrectomy intraoperatively. In 5 cases, intraocular lenses were implanted after operation secondly. Using biometry of the injured eye after primary repair was more accurate than using biometry of the fellow eye to determine the power of the lens for IOL implantation in various open-globe injuries. Patients received secondary IOL implantation in a separate procedure several months after the original vitreoretinal surgery for primary repair of the corneal or scleral wound. According to the varied degree of trauma and risks of infection, secondary IOL implantation after the repair of a corneal or scleral wound is optimal to prevent complications of a simultaneous procedure. However, because of various ongoing ocular injuries, visual improvement after IOL implantation was limited by such events as irregular astigmatism resulting from central or paracentral corneal scar, vitreoretinal pathology<sup>[9-11]</sup>. We used acrylic intraocular lenses in 9 patients, as it is a better choice in patients where retinal endotamponade with silicone oil can be expected. Combined simultaneous cataract and vitreous surgery with modern foldable intraocular lenses offers faster visual rehabilitation<sup>[12,13]</sup>. The vision of 13 patients with traumatic cataract in open-globe injury was improved after surgical intervention and subsequent IOL implantation.

Vitrectomy should be performed within 14 days after ocular trauma. Early vitrectomy can lower the probability of proliferative vitreoretinopathy and retinal detachment, which are frequent in severe trauma<sup>[7,10,14,15]</sup>. Foreign bodies that hit the retina stayed in the retina resulting in retinal damage in No.6 patient. We believe that further damage to the retina by surgery during foreign-body extraction and fibrotic tissue scars caused by endophotocoagulation prevented more favorable visual acuity results. Five out of 13 patients had a visual acuity of 0.1 to 0.4. Four patients had a visual acuity of 0.5 or better. In 4 patients, visual acuity was less than 0.1. The BCVA of sclera injury was better than that of corneal. The reasons for poor visual outcome were central or paracentral

corneal scar, intraretinal foreign body in the macular region, retinal detachment, massive retinal fibrosis despite a careful removal of the posterior vitreous body.

In conclusion, combined phacoemulsification, PPV, removal of IOFB and IOL implantation was safe and effective in cases of penetrating ocular trauma resulting from an intraocular foreign body. Visual outcome was mainly related to the corneal or scleral wound and the underlying posterior segment pathology and sites.

**REFERENCES**

- 1 Bencic G, Vatavuk Z, Mandic Z. Novel approach in the treatment of intravitreal foreign body and traumatic cataract: three case reports. *Croat Med J* 2004;45(3): 283–286
- 2 Chu J, Wen ZW. Analysis of non-phacoemulsification with small incision in treatment of 200 cases of cataract. *Int J Ophthalmol(Guoji Yanke Zazhi)* 2007;7(3): 857– 858
- 3 Axer-Siegel R, Dotan G, Rosenblatt I, Benjamini Y, Weinberger D. Combined pars plana vitrectomy and cataract surgery: outcome of phacoemulsification versus manual extracapsular cataract extraction through a sclerocorneal tunnel. *Ophthalmic Surg Lasers Imaging* 2006;37(2):94–98
- 4 Ma X, Liu ZX, Huang YF, Li ZH. Vitrectomy for the treatment of posttraumatic endophthalmitis. *Int J Ophthalmol(Guoji Yanke Zazhi)* 2007;7(2):331–333
- 5 Dskov H, Vlkov E. Surgical treatment of combined injuries of the anterior and posterior segment of the eye with intraocular metallic foreign body. *Cesk Slov Oftalmol* 2006;62(1):42–47
- 6 Wu HQ, Zhao YL, Wang T. Clinical analysis of vitreoretinal surgery in the treatment of complicated ocular trauma. *Int J Ophthalmol (Guoji Yanke Zazhi)* 2007;7(6):1731–1733
- 7 Du HJ, Hui YN, Wang L, Wang YS. Vitreous surgery for complicated foreign bodies in the posterior segment in 81 cases. *Int J Ophthalmol (Guoji Yanke Zazhi)* 2005;5(1):115–117
- 8 Li SX, Chen T, Yu JH, Zhao GP. The diagnostic value of multislice spiral CT on intraocular foreign bodies. *Int J Ophthalmol (Guoji Yanke Zazhi)* 2005;5(3):455–456
- 9 Chuang LH, Lai CC. Secondary intraocular lens implantation of traumatic cataract in open-globe injury. *Can J Ophthalmol* 2005;40(4):454–459
- 10 Li Z, Zhu XH, Tang LS. Application of divesting retinal inner limiting membrane in intraocular foreign body associated with siderosis bulbi in macular. *Int J Ophthalmol(Guoji Yanke Zazhi)* 2006;6(6):1434–1435
- 11 Aldakaf A, Almogahed A, Bakir H, Carstoccea B. Intraocular foreign bodies associated with traumatic cataract. *Oftalmologia* 2006;50(4):90–94
- 12 Merani R, Hunyor AP, Playfair TJ, Chang A, Gregory-Roberts J, Hunyor AB, Azar D, Cumming RG. Pars plana vitrectomy for the management of retained lens material after cataract surgery. *Am J Ophthalmol* 2007;144(3):364–370
- 13 Tseng HY, Wu WC, Hsu SY. Comparison of vitrectomy alone and combined vitrectomy, phacoemulsification and intraocular lens implantation for proliferative diabetic retinopathy. *Kaohsiung J Med Sci* 2007;23(7):339–343
- 14 Demetriades AM, Gottsch JD, Thomsen R, Azab A, Stark WJ, Campochiaro PA, de Juan E Jr, Haller JA. Combined phacoemulsification, intraocular lens implantation, and vitrectomy for eyes with coexisting cataract and vitreoretinal pathology. *Am J Ophthalmol* 2003;135(3):291–296
- 15 Hsu SY, Wu WC. Comparison of phacoemulsification and planned extracapsular cataract extraction in combined pars plana vitrectomy and posterior chamber intraocular lens implantation. *Ophthalmic Surg Lasers Imaging* 2005;36(2): 108–113