

# HIV/AIDS and ocular complications

*Sui-Yi Tan<sup>1</sup>, Shu-Wen Liu<sup>1</sup>, Shi-Bo Jiang<sup>1,2</sup>*

**Foundation items:** Supported by Natural Science Foundation of China (No. 30672496, U0832001 and 30729001); Culture Grant for Key Projects by Ministry of Education of China (No.706047)

<sup>1</sup> School of Pharmaceutical Sciences, Southern Medical University, Guangzhou 510515, Guangdong Province, China

<sup>2</sup> Viral Immunology Laboratory, Lindsley F. Kimball Research Institute, New York Blood Center, New York, NY 10065, USA

**Correspondence to:** Shu-Wen Liu. School of Pharmaceutical Sciences, Southern Medical University, Guangzhou 510515, Guangdong Province, China. liusw@smu.edu.cn; Shi-Bo Jiang. Viral Immunology Laboratory, Lindsley F. Kimball Research Institute, New York Blood Center, New York, NY 10065, USA. sjiang@nybloodcenter.org

Received:2009-02-10 Accepted:2009-02-13

## Abstract

• The introduction of highly active antiretroviral therapy (HAART) has greatly changed the pattern and natural history of ocular diseases of HIV-infected patients, resulting from the immune recovery and reduction of opportunistic infections. However, ophthalmic complication continues to be concern in AIDS even in the HAART era, especially in developing areas, where absolute majority of HIV-positive patients live. Lack of test facilities and experience, poor conditions of hygiene, different microbiological environment, absence of effective treatment etc., characterize the ophthalmic manifestation of HIV-infected patients in developing countries from that in developed regions and thus pose a great challenge to the ophthalmic treatment in developing area. Not only varied from region to region, ocular complications are distinctive between adults and children. At the same time, the side effects due to the application of HAART pose their own risks of ocular complication and should, therefore, be given more research attention.

• **KEYWORDS:** HIV/AIDS; ocular complication; retinopathy; neoplasm; opportunistic infection; HAART

Tan SY, Liu SW, Jiang SB. HIV/AIDS and ocular complications. *Int J Ophthalmol* 2009;2(2):95-105

**Abbreviations:** AIDS-acquired immunodeficiency syndrome; ARN-acute retinal necrosis; CMV-cytomegalovirus; EBV-epstein-barr virus; HAART-highly active antiretroviral therapy; HHV-8-human herpes virus-8; HIV-human immunodeficiency viruses; HPV-human papilloma viruses; KS-Kaposi's sarcoma; HZO-herpes zoster ophthalmicus; MC-molluscum contagiosum; NHL-non- Hodgkin's lymphoma; PORN-progressive outer retinal necrosis; PIs-protease inhibitors; SCC-squamous cell carcinoma; OSSN-ocular surface squamous neoplasia; VZV-varicella zoster virus

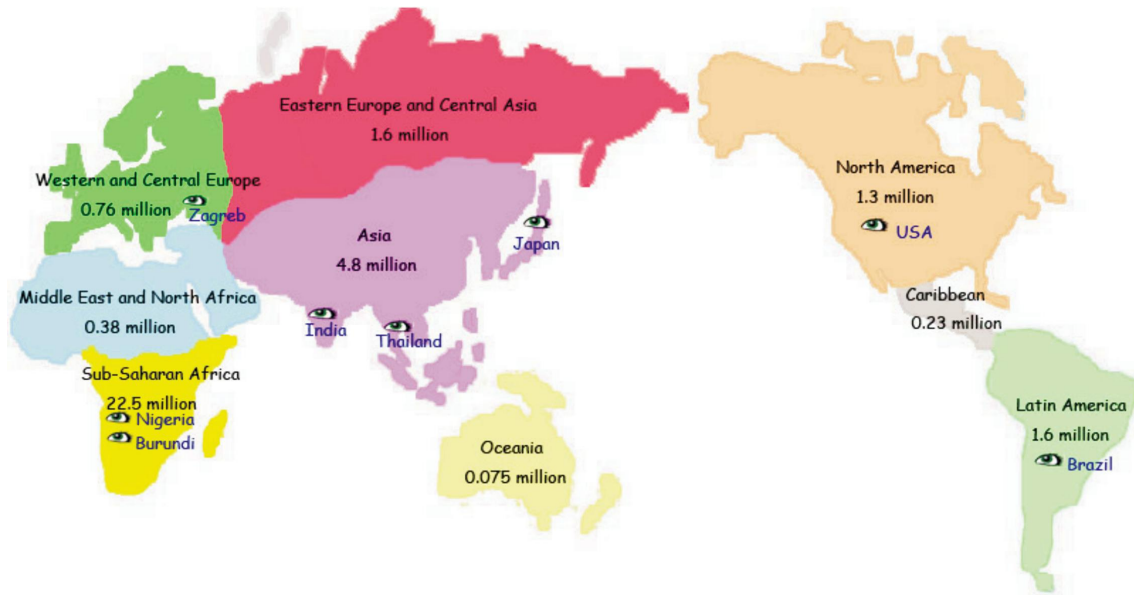
## INTRODUCTION

Human immunodeficiency virus (HIV) continues to be one of the most devastating evils that pose great threat to public health worldwide, especially in the developing countries, which amounts to more than 95% of global HIV infections. Being the most severe infected region, Sub-Saharan Africa accounts for more than two thirds of HIV infections and three quarters of all AIDS deaths in 2007. The HIV epidemic in South and Southeast Asia is among the second largest in the world, India making up half of the HIV-infected population in Asia (Figure 1).

Complications commonly involve the eyes in HIV-infected persons. Autopsy revealed that up to 95% of AIDS patients have some form of ocular abnormalities<sup>[1]</sup>. Ocular lesions are varied and affect almost all parts of the eye. In the early stages of HIV infection, ophthalmic manifestations may be asymptomatic, thus hampering prompt medical attention and, ultimately, leading to a variety of tissue-destructive conditions, including visual impairment and even blindness. Since HIV has been isolated from retina, it is believed that ocular complication results either from a general decrease of host immunity or, more likely, direct ocular infection by HIV through the blood-aqueous barrier and/or blood-retinal barrier. Ocular complication of HIV/AIDS differs from region to region. Most of the reports on ophthalmic manifestations of HIV infection come from developed countries, especially in the pre-HAART era. However, in recent years more and more cases and reports on ocular complication of HIV infection are being documented in developing countries, revealing an increasing attention and concern of the ocular status of HIV patients in these regions in which most of HIV-positive population live nowadays.

## RISK PREDICTOR OF OCULAR COMPLICATIONS IN HIV-POSITIVE PATIENTS

The number of CD4 T cells which are the primary targets and reservoirs of HIV infection, serves as the key marker of the host's immune competence to respond to opportunistic pathogens. It's been many years that CD4 T lymphocytes counts has been proved a reliable and important predictor of the risk for developing and indicator for managing ocular complications of HIV infection. Different ocular complications may develop at different CD4 threshold.



**Figure 1 Global HIV infection** Places marked with eyes are those ocular surveys of HIV- infected patients conducted in recent years

However, CD4 threshold may not always be the absolute criterion for predicting ocular complications since reconstituted CD4+ lymphocytes due to HAART may fail to provide protective immunity. Some reports revealed that HIV-positive patients with CD4+ counts higher than 200 cells/ $\mu$ L developed cytomegalovirus retinitis.

Also, the incidence of ocular disorders correlates with the WHO clinical stage of HIV/AIDS. Stage 4 patients suffer the great chance to be affected. The prevalence of ocular manifestations in patients with stage 3 is greater than those with stages 1 and 2 [2]. Some studies suggest that homosexuality may place HIV patients at higher risk for ocular problems[3].

**HIGHLY ACTIVE ANTIRETROVIRAL THERAPY**

Thus far, AIDS is not yet curable, and there is no effective vaccine for prevention. However, the introduction of HAART over the past decade has resulted in a dramatic reduction in the morbidity and mortality and an improved quality of life of HIV/AIDS patients. As a consequence of HAART, the pattern and nature history of ocular problems of HIV infection has significantly altered[4]. HAART usually consists of three different kinds of antiretroviral drugs, nucleoside reverse transcriptase inhibitors, non-nucleoside reverse transcriptase inhibitors and protease inhibitors. The use of HAART has resulted in the ability of the host to regain immunity and suppress viral loads.

Some reports associated with ocular observation in HIV-positive patients in different countries both in pre-HAART and HAART era have been summarized (Table 1 and 2). Although different reports examined using different protocol, there is obviously a profound changing face of

ophthalmic problems of HIV infection due to the availability of HAART. The incidence of ocular complication of HIV-positive patients has decreased from as high as 80% before the HAART era to less than 40% in the HAART era in general. Cytomegalovirus (CMV) retinitis and microvasculopathy continue to be the major types of ocular complications in HIV patients in the HAART era even with a significant declining incidence. However, we should keep in mind that despite the widespread use of HAART in developed countries, in many parts of the developing world, up to 80% of people infected with HIV who are in clinical need of treatment do not yet have access to antiretroviral drugs. Besides the cost of HAART, some factors such as restrictive licensing policies hamper the development and use of HAART in developing regions. Therefore, the ophthalmic manifestation of HIV infection in developing countries, especially in Sub-Saharan Africa, is characterized itself from that in developed countries by the higher incidence and more prevalence of opportunistic infections in the HAART era. Many factors, such as lack of effective antiviral therapies, lack of test facilities and experience, poor hygiene conditions, different microbiological environment, patients' nutritional status, may contribute to this distinction.

**CYTOMEGALOVIRUS RETINITIS AND OTHER OPPORTUNISTIC INFECTIONS**

Once the immune system of HIV-infected patients is weakened by either pre-existing or newly infected pathogens, such as bacteria, fungi, viruses, parasites, spirochetes, and mycobacteria, these pathogens can be reactivated and spread to the eye via the bloodstream, causing acute or chronic,

**Table 1a Ophthalmic findings with HIV infection in some countries which have conducted surveys in the pre-HAART era**

| Place                                                    | Africa             |         | Asia                                              |                 |                           |                 |
|----------------------------------------------------------|--------------------|---------|---------------------------------------------------|-----------------|---------------------------|-----------------|
|                                                          | Dakar              | Burundi | Japan                                             | Taiwan          | Singapore                 | India           |
| Sample size ( <i>n</i> = surveyed HIV-infected patients) | 67                 | 154     | 65                                                | 89              | 118                       | 100             |
| Time                                                     | 1989.11-1991.12    | --      | Before 1993                                       | 1994.03-1997.12 | 1995.05-1996.10           | 1993.12-1998.05 |
| Number of patients(%)                                    |                    |         |                                                   |                 |                           |                 |
| Ocular complication                                      | 52.23              |         | 77.0                                              |                 | 21.2<br>(Ocular symptoms) | 28              |
| CMVR                                                     | 63(Retinal damage) | 1       | 46.0                                              | 20.8            | 31.4                      | 17              |
| Microvasculopathy                                        | 22.70              | 10      | Cotton-wool spots: 50;<br>Retinal hemorrhages: 59 | 32.8            | 15.3                      | 15              |
| Neuro-ophthalmic manifestations                          |                    | 8.62    |                                                   |                 | 5.90                      | 0               |
| IRU                                                      |                    |         |                                                   |                 |                           |                 |
| Cataract                                                 |                    |         |                                                   |                 |                           |                 |
| Keratoconjunctivitis sicca                               |                    | 5.17    |                                                   |                 | 2.5                       | 15.35           |
| ARN                                                      |                    |         |                                                   |                 |                           |                 |
| HZO                                                      | 8.50               | 1       |                                                   |                 |                           |                 |
| Conjunctivitis                                           |                    |         |                                                   |                 |                           |                 |
| Toxoplasmosis                                            |                    |         |                                                   |                 |                           |                 |
| Herpes virus retinitis                                   |                    |         |                                                   |                 |                           |                 |
| OSSN                                                     |                    |         |                                                   |                 |                           |                 |
| KS                                                       |                    |         |                                                   |                 |                           |                 |
| Lymphoma                                                 |                    |         |                                                   |                 | 0.85                      |                 |
| Reference                                                | 84                 | 7       | 85                                                | 86              | 87                        | 3               |

**Table 1b Ophthalmic findings with HIV infection in some countries which have conducted surveys in the pre-HAART era**

| Place                                                    | Latin America     |                           |                 | Western and central Europe |
|----------------------------------------------------------|-------------------|---------------------------|-----------------|----------------------------|
|                                                          | Sao Paulo, Brazil | Sao Paulo, Brazil         | Brazil          | Zagreb                     |
| Sample size ( <i>n</i> = surveyed HIV-infected patients) | 445               | 1100                      | 58              | 50                         |
| Time                                                     | Before 1993       | 1995-1997                 | 1995.06-1998.02 | 1995-1997                  |
| Number of patients(%)                                    |                   |                           |                 |                            |
| Ocular complication                                      | 52.0              | 79.42 (Ocular complaints) | 82.75           | 63.50                      |
| CMVR                                                     | 25.0              | 22.36                     | 34.48           | 57.20                      |
| Microvasculopathy                                        | 1.10              | 10                        |                 |                            |
| Neuro-ophthalmic manifestations                          | 3.80              |                           |                 |                            |
| IRU                                                      |                   |                           |                 |                            |
| Cataract                                                 |                   |                           |                 |                            |
| Keratoconjunctivitis sicca                               |                   |                           |                 |                            |
| ARN                                                      |                   |                           |                 |                            |
| HZO                                                      |                   |                           |                 |                            |
| Conjunctivitis                                           |                   |                           | 1.72            |                            |
| Toxoplasmosis                                            | 8.50              | 4.36                      | 7.24            |                            |
| Herpes virus retinitis                                   | 3.60              |                           | 5.17            |                            |
| OSSN                                                     |                   |                           |                 |                            |
| KS                                                       |                   |                           |                 |                            |
| Lymphoma                                                 |                   |                           |                 |                            |
| Reference                                                | 88                | 89                        | 4               | 90                         |

serious or indistinctive, ocular diseases. CMV retinitis is still one of the most serious opportunistic infection in HIV/AIDS even in the HAART era. Some opportunistic infections, such as varicella zoster virus, toxoplasmosis, are more prevalent in the developing regions, which may arise from complicated ecological, racial, nutritional and socioeconomic factors which favor the viral transmission and reactivation in HIV-infected patients. The common ocular opportunistic pathogens and sites of infection in HIV/AIDS patients were summarized in Table 3.

**Cytomegalovirus** Co-infection of cytomegalovirus (CMV), a herpes virus, is a major cause of morbidity and mortality

of HIV/AIDS patients. The virus can be in a latent state in infected individuals, presumably for life. With immunodeficiency, dissemination and tissue destructive infection can occur. CMV causes a characteristic necrotizing retinitis with clinical symptoms of visual field defects, decreased visual acuity, retinal detachment, floaters and photophobia. CMV retinitis accounts for 75%-85% of cytomegalovirus disease and over 90% of blindness in AIDS patients [5]. It usually develops when the CD4+ cell counts fall below 50 cells/ $\mu$ L. HIV patients with a low CD4+ cells may have the same incidence of CMV as those in the pre-HAART era. Periodic examinations are recommended for those with CD4+ counts

## HIV/AIDS and ocular complications

**Table 2a Ophthalmic findings with HIV infection in some countries which have conducted surveys in the HAART era**

| Place                                                    | Africa            |         |                 | Latin America   | Western and Central Europe |                 |
|----------------------------------------------------------|-------------------|---------|-----------------|-----------------|----------------------------|-----------------|
|                                                          | Sub-Sahara Africa | Nigeria | Nigeria         | Brazil          | Zagreb                     | Austria         |
| Sample size ( <i>n</i> = surveyed HIV-infected patients) | --                | --      | 526             | 149             | 47                         | 539             |
| Time                                                     | 2008              | 2007    | 1997.12-2002.08 | 1998.03-2005.05 | 1998-2000                  | 1996.01-2002.12 |
| Number of patients(%)                                    |                   |         |                 |                 |                            |                 |
| Ocular complication                                      | 29-71             |         | 4               | 17.25           | 36.5                       | 40.3            |
| CMVR                                                     | 0-16.5            |         | 0.2             | 7.38            | 7.6                        | 10.8            |
| Microvasculopathy                                        |                   | 75      |                 |                 |                            | 26.9            |
| Neuro-ophthalmic manifestations                          |                   |         |                 |                 |                            |                 |
| IRU                                                      |                   |         |                 |                 |                            | 0.7             |
| Cataract                                                 |                   |         |                 |                 |                            |                 |
| Keratoconjunctivitis sicca                               |                   |         |                 |                 |                            | 17.8            |
| ARN                                                      |                   |         |                 |                 |                            |                 |
| HZO                                                      |                   | 62      | 2.7             |                 |                            |                 |
| Conjunctivitis                                           |                   |         |                 | 5.37            |                            |                 |
| Toxoplasmosis                                            |                   | 42      |                 | 3.35            |                            |                 |
| Herpes virus retinitis                                   |                   |         |                 | 0.67            |                            |                 |
| OSSN                                                     | 4-7.8             |         | 0.8             |                 |                            |                 |
| KS                                                       |                   |         | 0.4             |                 |                            |                 |
| Lymphoma                                                 |                   |         |                 |                 |                            |                 |
| Reference                                                | 28                | 91      | 53              | 4               | 90                         | 92              |

**Table 2b Ophthalmic findings with HIV infection in some countries which have conducted surveys in the HAART era**

| Place                                                    | Asia            |                     |                 |               |                 |
|----------------------------------------------------------|-----------------|---------------------|-----------------|---------------|-----------------|
|                                                          | Japan           | Chiang Mai Thailand | India           | Eastern India | Western India   |
| Sample size ( <i>n</i> = surveyed HIV-infected patients) | 322             | 395                 | 100             | 175           | 112             |
| Time                                                     | 1997.07-1998.12 | 2000.03-2001.02     | 2004.10-2005.12 | --            | 2008.04-2008.06 |
| Number of patients(%)                                    |                 |                     |                 |               |                 |
| Ocular complication                                      | 15.8            | 44.6                | 45              | 29.14         | 8               |
| CMVR                                                     | 5.3             | 33.0                | 20              |               | 2               |
| Microvasculopathy                                        | 10.9            | 8.0                 | 11              |               | 5               |
| Neuro-ophthalmic manifestations                          |                 | 3                   | 12              | 7             |                 |
| IRU                                                      |                 | 4                   | 5               |               | 3               |
| Cataract                                                 |                 |                     | 6               |               |                 |
| Keratoconjunctivitis sicca                               |                 | 2                   |                 |               |                 |
| ARN                                                      |                 |                     | 3               |               |                 |
| HZO                                                      |                 |                     |                 |               |                 |
| Conjunctivitis                                           |                 |                     |                 |               |                 |
| Toxoplasmosis                                            |                 |                     |                 |               |                 |
| Herpes virus retinitis                                   |                 |                     |                 |               |                 |
| OSSN                                                     |                 |                     |                 |               |                 |
| KS                                                       | 0.31            |                     |                 |               |                 |
| Lymphoma                                                 |                 |                     |                 |               |                 |
| Reference                                                | 93              | 94                  | 95              | 96            | 2               |

below 100 cells/ $\mu$ L, especially if CMV-antibody positive. Some studies suggest that HIV RNA blood level is also an important predictor of CMV retinitis since HIV can transactivate CMV<sup>[6]</sup>. In the pre- HAART era, CMV retinitis is less common in Africa than in North America and Europe, which may be the cause that HIV patients died before the development of CMV retinitis in the poor regions<sup>[7]</sup>. AIDS patients often die of tuberculosis which appears at an early stage of HIV infection in developing regions. Nowadays, HAART has most significantly changed the incidence, progression and management of CMVR by decreasing the incidence of CMV retinitis by 75% -90% . However, CMV retinitis remains the most important issues in HIV-patients with over 30% prevalence in some

developing regions due to the unavailability of HAART.

**Varicella Zoster Virus** Varicella zoster virus (VZV) is a common infection in humans. Once exposed to VZV, latency can persist throughout life. Reactivation of VZV in the trigeminal ganglion can result in herpes zoster ophthalmicus (HZO), which may be the initial manifestation of HIV infection. HZO affects 5% -15% of HIV-positive patients<sup>[8]</sup>. Immunocompromised patients and older people are more prone to VZV reactivation<sup>[9]</sup>. Incidence of HZO is six times greater in HIV/AIDS patients than in healthy people. In Nigeria, herpetic eye disease constituted half of the ocular cases and there is strong association between HZO and HIV infection<sup>[10]</sup>. Studies found that over 60% patients with HZO are HIV-positive in Nigeria<sup>[11,12]</sup>. The anterior

**Table 3 Common ocular opportunistic pathogens and sites of infection in HIV/AIDS patients**

| Category     | Pathogens                         | Infected Sites                                                                                                                                                        |                                                          |
|--------------|-----------------------------------|-----------------------------------------------------------------------------------------------------------------------------------------------------------------------|----------------------------------------------------------|
|              |                                   | Anterior                                                                                                                                                              | Posterior                                                |
| Virus        | Cytomegalovirus                   | Corneal infiltration <sup>[97]</sup> , conjunctivitis, iritis <sup>[98]</sup> , epithelial keratitis, stromal keratitis <sup>[99]</sup> , papillitis <sup>[100]</sup> | Retinitis, optic neuritis <sup>[101]</sup>               |
|              | Varicella-zoster virus            | Keratitis, conjunctivitis, scleritis, blepharitis                                                                                                                     | Optic neuritis <sup>[102]</sup> , retinitis, retinopathy |
| Bacteria     | Molluscum contagiosum virus       | Eyelid MC, conjunctival MC <sup>[17]</sup> , limbal MC <sup>[16]</sup>                                                                                                |                                                          |
|              | Herpes Simplex Virus              | Keratitis                                                                                                                                                             |                                                          |
|              | <i>Neisseria gonorrhoeae</i>      | Keratoconjunctivitis                                                                                                                                                  |                                                          |
| Fungi        | <i>Acanthamoeba</i>               | Keratitis                                                                                                                                                             |                                                          |
|              | Cryptococcus neoformans           | Limbal cryptococcosis, eyelid cryptococcosis, granulomatous conjunctivitis, iritis, multifocal choroiditis                                                            | Retinitis, optic neuritis                                |
|              | <i>Cryptococcus albidus</i>       | Scleral ulceration                                                                                                                                                    |                                                          |
| Protozoa     | <i>Histoplasma capsulatum</i>     | Limbal, conjunctiva infection                                                                                                                                         |                                                          |
|              | <i>Pneumocystis carinii</i>       | Conjunctival infection                                                                                                                                                |                                                          |
| Spirochetes  | <i>Treponema pallidum</i>         | Iridocyclitis, papillitis, perineuritis, retrobulbar                                                                                                                  | Uveitis, retinitis, optic neuritis                       |
| Mycobacteria | <i>Mycobacterium tuberculosis</i> | Choroidal granulomas, panophthalmitis, conjunctival tuberculosis, panophthalmitis <sup>[25]</sup>                                                                     | Uveitis, subretinal abscess <sup>[25]</sup>              |
| Protozoa     | <i>Toxoplasma gondii</i>          | Orbital infection, choroiditis, iritis <sup>[23]</sup>                                                                                                                | Uveitis, optic nerve <sup>[23]</sup>                     |

presentations in AIDS-associated HZO include, for example, conjunctivitis, scleritis, epithelial keratitis, stromal keratitis, uveitis, blepharitis, etc. <sup>[9]</sup> Treatment of HZO in AIDS patients usually starts with prompt and aggressive intravenous antiviral treatment, followed by an oral maintenance regimen. However, when the infection continues and spreads to the posterior parts, necrotizing herpetic retinopathy (NHR) may occur. It is reported that 4% -17% of HIV-positive individuals develop NHR after HZO. Acute retinal necrosis (ARN) and progressive outer retinal necrosis (PORN) are the two distinct forms of NHR. Usually the former occurs in those with only mild immune deficiency and elevated CD4+ counts, while the latter happens in those who are severely immunosuppressed. However, both forms have been identified simultaneously in an AIDS patient <sup>[13]</sup>. PORN has a rapid and progressive course leading to devastating vision loss, which, in most cases, is difficult to treat <sup>[14]</sup>. Intravitreal injection with combined antiviral drugs may be more effective in treating this aggressive disease and quantitative measurements of VZV DNA from aqueous humor appear helpful in the management of PORN<sup>[14]</sup>.

**Molluscum Contagiosum** Molluscum contagiosum (MC) virus is another opportunistic pathogen that can cause MC in HIV-infected patients. MC is a contagious disorder that can occur in both pediatric and adult HIV/AIDS patients, but it is more prevalent in children in undeveloped areas. A cross-sectional hospital based study in Uganda showed that over 10% of pediatric HIV patients had MC <sup>[15]</sup>. MC virus commonly infects the eyelid, and, rarely, the conjunctiva, corneal and limbus <sup>[16]</sup>. Symptoms include chronic follicular

conjunctivitis, corneal micropannus and epithelial keratitis<sup>[17]</sup>. MC is suggested to be a sign of advanced AIDS and appears in advanced HIV infection when CD4+ counts are less than 80cells/ $\mu$ L <sup>[18,19]</sup>. Eyelid lesion can be treated as the first manifestation of AIDS <sup>[20]</sup>. The disease is more aggressive in AIDS patients with immunosuppression, and there is usually multiple lesion involvement <sup>[17,21]</sup>. No drug is effective in treatment of MC. Traditional treatments, such as local excision, laser or cryotherapy, can be applied to MC in AIDS patients. If treatment is not prompt enough, severe complications will ensue. Nevertheless, the high recurrence may make the original treatment a failure<sup>[21,22]</sup>.

**Ocular Toxoplasmosis** *Toxoplasma gondii* is a common parasites infection in HIV/AIDS patients <sup>[23]</sup>. Ocular toxoplasmosis accounts for 1% -3% infection in AIDS patients. Single or multiple lesion of retinitis may affect both eyes with massive areas of retinal necrosis. Combination therapy of pyrimethamine with sulfadiazine and/or clindamycin is effective and lifelong maintenance treatment is necessary to prevent recurrence. System evaluation is suggested once the ocular toxoplasmosis is defined due to the high incidence of concomitant CNS toxoplasmosis<sup>[24]</sup>.

**Ocular Tuberculosis** Tuberculosis, a mycobacterial infection caused by *Mycobacterium tuberculosis*, has a higher incidence in AIDS patients than the general population, especially in developing region <sup>[25]</sup>. 46% of HIV-positive patients in the developing world are co-infected with tuberculosis and as many as 23% HIV-tuberculosis co-infection patients had disseminated ocular tuberculosis<sup>[25,26]</sup>. Ocular tuberculosis can occur even with very high CD4+ cell counts. Regular ocular examination for ocular tuberculosis

is necessary in HIV infected cases in the developing regions despite the relative high CD4+ counts and prescription of HAART.

**Fungi** Cryptococcosis is the most common fungal infection occurring in 5%-10% of all AIDS patients [27]. Lungs and CNS are the two most common sites for cryptococcus infection. The fungi causing ocular infection in HIV-positive patients is believed to be the spread from the infected CNS. Cryptococcal encephalitis is one of the major causes of AIDS mortality. A Sub-Sahara African study show that in Zimbabwe, 45% of meningitis in adults is cryptococcal, and cryptococcal meningitis is the third leading cause of death in HIV patients in rural Uganda. In Rwanda, 9% of patients with cryptococcal meningitis developed visual loss and sixth nerve palsy [28]. In the eyes, cryptococcal encephalitis frequently presents as papilledema, multifocal choroiditis, visual loss, optic nerve irruption and optic atrophy [29]. Not only can HIV invade the nervous system, but HIV-1 gp41 ectodomain also plays a role in enhancing *Cryptococcus neoformans* invasion of human brain microvascular endothelial cells [30]. Nevertheless, patients can regain their visual function follow optimal therapy.

**Bacteria** The differences in ocular bacterial flora between HIV-infected subjects and healthy populations have been controversial. Although some studies have suggested no significant differences between the two [31,32]. Comerie-Smith *et al* [33] reported that even asymptomatic HIV-positive patients had increased colony counts of bacterial flora in the lids. *Candida albicans*, *Candida parapsilosis*, *Staphylococcus aureus*, *Pseudomonas aeruginosa*, *Capnocytophaga*, alpha-hemolytic streptococci, and *Acanthamoeba* have been isolated from infected corneas in patients with AIDS [34]. An adult AIDS patient with gonococcal infection developed keratoconjunctivitis. Pre-existing keratoconjunctivitis sicca and viral keratitis, microvascular abnormalities, which present epithelial leakage giving rise to bacterial entry, and crack cocaine usage, are the risk factors for bacterial ocular infection in HIV/AIDS patients. Since systemic antibiotics are ineffective to ocular flora in HIV-infected patients [31], aggressive medication or surgical intervention should be considered once the diagnosis is made.

### MICROVASULOPATHY

Microvasculopathy, also known as AIDS retinopathy, is the most common ocular complication, and it can affect 40%-60% of AIDS patients and HAART has greatly decrease its incidence [35]. Its frequency increases according to the stage of HIV progression. Notably, a decreasing CD4+ count correlates with the occurrence of HIV-related retinopathy,

especially in those with CD4+ counts less than 200 cells/mm<sup>[336]</sup>. It is a noninfectious microvascular disorder characterized by cotton-wool spots, microaneurysms, retinal hemorrhages, telangiectatic vascular changes, and the presence of capillary nonperfusion [1]. Although commonly found in the retina, microvasculopathy may present in conjunctiva and optic disk. Because of the isolation of HIV from human retina and the detection of its antigen in retinal endothelial cells, it is believed that HIV infection of endothelial cells may contribute to this ocular abnormality. Microvascular abnormalities in those with HIV-associated retinopathy include loss and degeneration of pericytes, swollen endothelial cells, thickened basement membranes, shrunken capillary lumina in retinal vessels and tubuloreticular structures, all of which are found in almost all HIV-positive patients [36,37]. Reduced leukocyte density in macular capillaries, which may lead to retinal hypoxia, and increased polymorphonuclear leukocyte rigidity, which can cause microvascular damage by releasing proteases, toxic oxygen radicals, as well as influence microvascular blood flow, are commonly found in HIV-positive patients [36,38]. Even without retinopathy or optic nerve disease, obvious thinning of the retinal nerve fiber layer is found in HIV-positive patients [39,40]. Other factors, such as damage from immune complexes and hemorrhagic abnormalities, can also contribute to the vascular alterations. Both the structural proteins and the regulatory proteins of HIV itself play a role in the viral ocular infection. It has been reported that HIV gp120 can activate apoptosis in endothelial cells and change the function barrier of the microvascular endothelial cell monolayer by increasing vasopermeability [41]. Moreover, HIV Tat protein, a transcriptional activator of viral gene expression produced early after infection, exerts both proliferative and apoptotic effects on endothelial cells [41,42]. It has been shown *in vitro* to induce changes of the tight junction proteins in the retinal pigment epithelium (RPE), which is responsible for altering the blood-retinal barrier and subsequent HIV trafficking into the eyes [43,44]. Microvasculopathy is often asymptomatic and no treatment is involved in most cases [36,45]. However, it may be the initial cause of other ocular complications in HIV-positive patients, such as CMV infection, retinal and optic nerve damage and various vision abnormalities, including abnormal color vision, reduced contrast sensitivity, and visual field abnormalities [46]. The severity of vascular damage correlates well with the multiple opportunistic infections in AIDS patients [47].

**Table 4 Comparison of three common ocular tumors in HIV/AIDS patients**

|           | Kaposi's sarcoma                                                                                                                       | Non-Hodgkin's lymphoma                                         | Squamous cell carcinoma                                                                     |
|-----------|----------------------------------------------------------------------------------------------------------------------------------------|----------------------------------------------------------------|---------------------------------------------------------------------------------------------|
| Etiology  | HHV-8 (CMV, HHV-6, HHV-7, HPV associated)                                                                                              | EBV                                                            | HIV, HPV (other noninfectious factors include exposure to UV, genetic susceptibility)       |
| Sites     | Eyelids, the bulbar, tarsal, and conjunctiva, the plica semilunaris, the caruncle, the lacrimal sac, (rarely orbit and lacrimal gland) | Conjunctiva, eyelid, orbit, uvea, retina, choroid, optic nerve | Eyelids, conjunctiva                                                                        |
| Treatment | Cryotherapy, surgical excision, radiation, systemic chemotherapy, intralesional injection of interferon alpha-2a                       | Radiation, chemotherapy                                        | Excision, cryotherapy, topical medication (such as mitomycin-C, 5-fluorouracil, interferon) |

**Table 5 Ophthalmic findings with pediatric HIV infection in some countries which have conducted surveys in the HAART era**

| Time                 | Place                              | Sample size( <i>n</i> =surveyed HIV-infected children) | Major ocular findings                                                                                                        |
|----------------------|------------------------------------|--------------------------------------------------------|------------------------------------------------------------------------------------------------------------------------------|
| In the pre-HAART era |                                    |                                                        |                                                                                                                              |
| 1984-1990            | Developing region Rwanda, Africa   | 162                                                    | 38% of perivasculitis; 1.9% of CMVR; 1.2% of HZO and conjunctival xerosis                                                    |
| 1993.12-1999.10      | Developing region India            | 12                                                     | 50% of ocular complication, 33% of anterior uveitis and CMV retinitis, 17% of retinal detachment, 17% of vitreous hemorrhage |
| Before 1989          | Developing region USA              | 87                                                     | 20% of ocular prevalence; 2.3% of CMVR                                                                                       |
| 1991.09-1996.08      | Developed region USA               | 33                                                     | 30.3% of ocular prevalence                                                                                                   |
| 1983-1994            | Developed region Milan, Italy      | 117                                                    | 7.7% of ocular involvement                                                                                                   |
| In HAART era         |                                    |                                                        |                                                                                                                              |
| Before 2000          | Developing region Tanzania, Africa | 62                                                     | 38% of ocular findings, macular oedema and retinal haemorrhages being the common lesions                                     |
| 2001.05-2001.10      | Developing region Uganda, Africa   | 158                                                    | 35% of ocular prevalence, 31% of perivasculitis, 4% of CMVR, 12% of MC, 4% of neuro-optic manifestation                      |
| 1995-2004            | Developed region Milan, Italy      | 117                                                    | No ocular cases                                                                                                              |

## NEOPLASM

Cancer in individuals living with HIV/AIDS is a common source of morbidity and mortality. Although ocular malignancies are rare, they occur in the late stage of AIDS. The etiologies, primary sites, and treatments of three common ocular tumors in HIV/AIDS patients were summarized in Table 4.

**Ocular Surface Squamous Neoplasia** Squamous cell carcinoma which is characterized as a low-grade malignancy is the third most common AIDS-related neoplasm [48]. When the eyes are involved in the disease, the most common sites are the anterior parts, especially the conjunctiva and the eyelids. The pathogenesis of ocular surface squamous neoplasia (OSSN) is not well understood. However, exposure to ultraviolet radiation, genetic susceptibility and infection by HIV and HPV are the recognized factors that contribute to the high risk of developing OSSN [49]. Squamous cell conjunctival carcinoma is much more commonly seen in tropical, subtropical and poorer areas than in developed countries such as Europe and the United States [50]. It is reported that HIV positive patients have as high as 13-fold increased risk of developing OSSN than the normal group [51]

and the occurrence rate of OSSN reach 7.8% in AIDS patients [52]. HIV patients from sub-Saharan Africa seem to be at increased risk of OSSN. OSSN is more aggressive in HIV patients. In some cases, OSSN can be the initial clinical manifestation of HIV infection [53]. Although the DNA of HPV, predominantly type 16, has been found in ocular surface squamous neoplasias, the roles of HPV in the pathogenesis of OSSN have been controversial [50]. Diagnosis of OSSN can easily be mistaken with conjunctivitis and Pterygium [54] and the common treatment is the surgical excision of the lesion. As a result of the high recurrence after the surgery, cryotherapy, radiation and chemotherapy are also suggested and periodic follow-up examination is needed [55]. When the disease progresses and intraocular invasion occurs, such as perineural invasion, the disease may lead to death [56].

**Kaposi's Sarcoma** Kaposi's sarcoma (KS) is one of the most common and important AIDS-related neoplasms and can be considered as an AIDS-defining illness [57]. Since human herpes virus-8 (HHV-8) has been identified in all four clinical-epidemiological forms of KS and since the viral load is correlated to the risk and severity of KS, HHV-8 is

considered to be the etiology of KS. However, only some HHV-8-positive populations develop KS. Therefore, HHV-8 is necessary, but not sufficient, for the development of KS<sup>[58,59]</sup>. Other pathogens, such as CMV, HHV-6, HHV-7 and human papilloma viruses (HPV), may also be associated with the development of KS. Prior to the AIDS epidemic, KS was extremely rare. Now, however, KS is commonly seen, especially in AIDS patients. The incidence of KS in AIDS patients is about 20 000 times higher than that found in the general population. The pathogenesis of AIDS-KS may represent a series of events involving interaction of immunosuppression, altered expression and response to cytokines, and the co-transactivation between HIV and HHV-8<sup>[60,61]</sup>. HIV-1 Tat protein has been shown to be a potent mitogen for human KS-derived cell lines and facilitates the development of KS by protecting KS cells from apoptosis<sup>[62]</sup>. Before the era of HAART, approximately 20% of HIV-positive patients suffer asymptomatic KS of the eyelids or conjunctiva<sup>[63]</sup>. Ocular involvement accounts for 10%-20% of AIDS-related KS cases even in the era of highly active antiretroviral therapy (HAART)<sup>[64-66]</sup>, mostly the anterior parts, such as eyelids, the bulbar, tarsal, and forniceal conjunctiva, the plica semilunaris, the caruncle, the lacrimal sac, and rarely the orbit and lacrimal gland<sup>[67,68]</sup>. Eyelid and conjunctiva are the most commonly affected sites, and HHV-8 has been detected in KS of the eyelid and conjunctiva in an AIDS patient<sup>[69]</sup>. Ocular KS usually presents as a red mass and can easily be mistaken for hemorrhage<sup>[65]</sup>. No specific therapy is available for ocular KS, although HAART may be used for treatment of AIDS-associated KS. If the lesion is painful or causes functional disruption, cryotherapy, surgical excision, radiation and/or chemotherapy are suggested<sup>[66,70]</sup>.

**Lymphoma** Non-Hodgkin's lymphoma (NHL), a kind of malignancy of B-cell origin associated with Epstein-Barr virus (EBV) infection<sup>[71]</sup>, is the second most common malignant disorder associated with AIDS<sup>[72]</sup>. Ocular NHL may arise from the central nervous system (CNS) and/or retina, termed as primary CNS lymphoma, or may appear as intraocular metastasis from systemic lymphomas via blood circulation to the uvea, which is termed primary intraocular lymphoma. NHL can present in posterior and anterior parts, but are mostly confined to the conjunctiva and eyelid. Co-existence of intraocular and orbital non-Hodgkin's lymphoma has been reported in AIDS patients. Massive necrosis involving the retina, choroid, and optic nerve, as well as several solid retinal pigment epithelial detachments and retinal vasculitis, could be observed<sup>[73]</sup>. The pathogenesis

of AIDS-related lymphoma is unknown. Some studies, however, have found that HIV-1 Vpu and Tat protein can support the expansion of malignant B cells<sup>[74]</sup>. HIV has no direct oncogenic effect since HIV sequences have never been detected within the neoplastic lymphoid cells<sup>[75]</sup>. Lack of immuno-surveillance and viral infection, other than HIV, may be key factors contributing to lymphomagenesis<sup>[76]</sup>. No specific treatment, but only the traditional radiation and chemotherapy are recommended.

### NEURO-OPHTHALMIC ABNORMALITIES

Histological studies have shown that up to 75%-90% of HIV/AIDS patients have brain damage, including the optic nerve. Sixty percent of HIV patients with neurological symptoms have some form of neuro-ophthalmological deficit. Many factors, such as CNS infection by HIV alone or with other co-infecting pathogens, neoplasms, inflammatory processes etc. may contribute to the neuro-ocular manifestation in HIV/AIDS patients<sup>[77]</sup>. Optic neuropathy, papilledema, and cranial nerve palsies are the most commonly found cases. Optic neuropathies can be caused by viral, bacterial or fungal infections, commonly found are CMV and *Cryptococcus neoformans* invasion. Cryptococcal meningitis can also be the cause of papilledema. Along with the HIV ongoing replication, neurotoxins are produced to cause apoptosis in specific neural tissues that lead to axonal loss, neuronal damage, and finally, neuro-ophthalmologic abnormalities.

### CAUTIONS OF HAART

Drug resistance, adverse side effects and drug-drug interaction have been universal problems with the application of HAART for HIV infected patients. Clinicians should be particularly aware of the side effects of HAART related to the eyes. For instance, the toxicity of nucleoside reverse transcriptase inhibitor therapy in terms of the potential inhibition of host mitochondrial DNA polymerase is well known. There are reports that long-term use of zidovudine may account for the late complication of Leber's hereditary optic neuropathy, which is caused by an induced mutation in the mitochondrial DNA<sup>[78,79]</sup>. So, HIV-infected patients with a family history of Leber's hereditary optic neuropathy should be warned of this ocular disorder. Zidovudine and protease inhibitors (PIs) used alone can induce endothelial cell proliferation, causing a dysregulation of angiogenesis, which makes HIV-positive patients more prone to hemangiomas such as KS<sup>[41,80]</sup>. The continued use of PIs may also increase the incidence of herpes zoster in AIDS patients. Application of nevirapine can lead to Stevens-Johnson syndrome-induced dry eye<sup>[81]</sup>. Surprisingly,



combination of HAART and anti-tuberculosis therapy in AIDS patients may actually weaken ocular condition [82]. On the other hand, the discontinuation of HAART can lead to ocular opportunistic infections, such as cryptococcal meningitis, which may result in choroiditis [27]. Immune recovery uveitis may occur in HIV/AIDS patients with CMV retinitis who have experienced immune recovery due to HAART [5]. Therefore, individualized treatment and regular monitoring should always be undertaken in HIV/AIDS patients.

### OPHTHALMIC FINDINGS IN PEDIATRIC HIV INFECTIONS

The introduction of HAART seems to have a more significant impact on the nature of ocular manifestation in pediatric HIV infection in developed countries than that in the poor countries. A study in Milan, Italy, showed that there was 7.7% cases of ocular complication in the pre-HAART era while no case was found since the introduction of HAART in HIV-infected children [83]. However, similar incidence rate of ocular complication was found in African HIV-infected children regardless of HAART (Table 5).

CMV retinitis occur far less frequently in HIV-positive children than in adults and it is diagnosed predominantly in patients with CD4 cells counts below 20cell/ $\mu$ L, owing to the immature immune status and less frequent exposure to CMV in pediatric HIV-infected patients. The most significant ocular finding is the high incidence of perivasculitis and/or sheathing of retinal vessels in Africa and anterior uveitis in India. Nutritional status is probably the most important factor that contributes to the high prevalence of ocular involvement in HIV-positive children in developing countries.

### CONCLUSION

HIV/AIDS-related ophthalmologic problems will remain an important issue for the coming decades. Nowadays, the study of ocular complications in HIV/AIDS patients mainly focuses on the clinical features and prevalence, but seldom the potential mechanism of the pathogenesis, perhaps due to the lack of proper animal system models. In any case, it is only when we clearly understand what happens during the ocular/HIV pathogenic process that we can find successful therapeutic strategies. This will require the long-term commitment of both virologists and ophthalmologists.

### REFERENCES

- 1 Biswas J, Fogla R, Gopal L, Narayana KM, Banker AS, Kumarasamy N, Madhavan HN. Current approaches to diagnosis and management of ocular lesions in human immunodeficiency virus positive patients. *Indian J Ophthalmol* 2002; 50:83-96
- 2 Shah SU, Kerkar SP, Pazare AR. Evaluation of ocular manifestations and

- blindness in HIV/AIDS patients on HAART in a tertiary care hospital in western India. *Br J Ophthalmol* 2009;93 (1):88-90
- 3 Biswas J, Madhavan HN, George AE, Kumarasamy N, Solomon S. Ocular lesions associated with HIV infection in India: a series of 100 consecutive patients evaluated at a referral center. *Am J Ophthalmol* 2000; 129:9-15
- 4 Rodrigues ML, Rodrigues ML, Figueiredo JF, de Freitas JA. Ocular problems in Brazilian patients with AIDS before and in highly active antiretroviral therapy (HAART) era. *Braz J Infect Dis* 2007;11:199-202
- 5 Jabs DA, Van Natta ML, Kempen JH, Reed PP, Lim JJ, Murphy RL, Hubbard LD. Characteristics of patients with cytomegalovirus retinitis in the era of highly active antiretroviral therapy. *Am J Ophthalmol* 2002; 133:48-61
- 6 Holland GN, Vaudaux JD, Jeng SM, Yu F, Goldenberg DT, Folz IC, Cumberland WG, McCannel CA, Helm CJ, Hardy WD. Characteristics of untreated AIDS-related cytomegalovirus retinitis. I. Findings before the era of highly active antiretroviral therapy (1988 to 1994). *Am J Ophthalmol* 2008;145:5-11
- 7 Cochereau I, Mlika-Cabanne N, Godinaud P, Niyongabo T, Poste B, Ngayiragije A, Dazza MC, Aubry P, Larouze B. AIDS related eye disease in Burundi, Africa. *Br J Ophthalmol* 1999; 83 (3):339-342
- 8 Ng WT, Versace P. Ocular association of HIV infection in the era of highly active antiretroviral therapy and the global perspective. *Clin Experiment Ophthalmol* 2005;33:317-329
- 9 Wiafe B. Herpes Zoster Ophthalmicus in HIV/AIDS. *Community Eye Health* 2003;16:35-36
- 10 Nwosu NN. HIV/AIDS in ophthalmic patients: The Guinness Eye Centre Onitsha experience. *Niger Postgrad Med J* 2008; 15:24-27
- 11 Umeh RE. Herpes zoster ophthalmicus and HIV infection in Nigeria. *Int J STD AIDS* 1998;9:476-479
- 12 Owoeye JF, Ademola-Popoola DS. Herpes zoster infection and HIV seropositivity among eye patients--University of Ilorin Teaching Hospital experience. *West Afr J Med* 2003;22:136-138
- 13 Gariano RF, Berreen JP, Cooney EL. Progressive outer retinal necrosis and acute retinal necrosis in fellow eyes of a patient with acquired immunodeficiency syndrome. *Am J Ophthalmol* 2001; 132 (3):421-423
- 14 Yin PD, Kurup SK, Fischer SH, Rhee HH, Byrnes GA, Levy-Clarke GA, Buggage RR, Nussenblatt RB, Mican JM, Wright ME. Progressive outer retinal necrosis in the era of highly active antiretroviral therapy: successful management with intravitreal injections and monitoring with quantitative PCR. *J Clin Virol* 2007;38:254-259
- 15 Ikoona E, Kalyesubula I, Kawuma M. Ocular manifestations in paediatric HIV/AIDS patients in Mulago Hospital, Uganda. *Afr Health Sci* 2003;3(2):83-86
- 16 Merisier H, Cochereau I, Hoang-Xuan T, Toubblanc M, Ruggeri C. Multiple molluscum contagiosum lesions of the limbus in a patient with HIV infection. *Br J Ophthalmol* 1995; 79:393-394
- 17 Schulz D, Sarra GM, Koerner UB, Garweg JG. Evolution of HIV-1-related conjunctival molluscum contagiosum under HAART: report of a bilaterally manifesting case and literature review. *Graefes Arch Clin Exp Ophthalmol* 2004; 242:951-955
- 18 Koopman RJ, van Merrienboer FC, Vreden SG, Dolmans WM. Molluscum contagiosum; a marker for advanced HIV infection. *Br J Dermatol* 1992; 126 (5): 528 -529
- 19 Perez-Blazquez E, Villafuella I, Madero S. Eyelid molluscum contagiosum in patients with human immunodeficiency virus infection. *Orbit* 1999;18 (2):75-81
- 20 Leahey AB, Shane JJ, Linstead A, Trachtman M. Molluscum contagiosum eyelid lesions as the initial manifestation of acquired immunodeficiency syndrome. *Am J Ophthalmol* 1997;124 (2):240 -241
- 21 Schornack MM, Siemsen DW, Bradley EA, Salomao DR, Lee HB. Ocular manifestations of molluscum contagiosum. *Clin Exp Optom* 2006;89(6):390 -393

- 22 Bardenstein DS, Elmets C. Hyperfocal cryotherapy of multiple Molluscum contagiosum lesions in patients with the acquired immune deficiency syndrome. *Ophthalmology* 1995;102 (7):1031–1034
- 23 Lee MW, Fong KS, Hsu LY, Lim WK. Optic nerve toxoplasmosis and orbital inflammation as initial presentation of AIDS. *Graefes Arch Clin Exp Ophthalmol* 2006;244:1542–1544
- 24 Cochereau-Massin I, LeHoang P, Lautier-Frau M, Zerdoun E, Zazoun L, Robinet M, Marcel P, Girard B, Katlama C, Lepout C, . Ocular toxoplasmosis in human immunodeficiency virus-infected patients. *Am J Ophthalmol*1992; 114: 130–135
- 25 Babu RB, Sudharshan S, Kumarasamy N, Therese L, Biswas J. Ocular tuberculosis in acquired immunodeficiency syndrome. *Am J Ophthalmol* 2006; 142:413–418
- 26 Welton TH, Townsend JC, Bright DC, Anderson SF, Nguyen AT, Ilsen PF. Presumed ocular tuberculosis in an AIDS patient. *J Am Optom Assoc*1996;67(6): 350–357
- 27 Chronister CL. Discontinuation of highly active antiretroviral therapy leads to cryptococcal meningitis/choroiditis in an AIDS patient. *Optometry* 2006;77: 438–445
- 28 Nkomazana O, Tshitswana D. Ocular complications of HIV infection in sub-Saharan Africa. *Curr HIV/AIDS Rep* 2008; 5:120–125
- 29 Andreola C, Ribeiro MP, de Carli CR, Gouvea AL, Curi AL. Multifocal choroiditis in disseminated *Cryptococcus neoformans* infection. *Am J Ophthalmol* 2006;142:346–348
- 30 Jong AY, Wu CH, Jiang S, Feng L, Chen HM, Huang SH. HIV-1 gp41 ectodomain enhances *Cryptococcus neoformans* binding to HBMEC. *Biochem Biophys Res Commun* 2007;356:899–905
- 31 Gritz DC, Scott TJ, Sedo SF, Cevallos AV, Margolis TP, Whitcher JP. Ocular flora of patients with AIDS compared with those of HIV-negative patients. *Cornea* 1997;16:400–405
- 32 Campos MS, Campos e Silva Lde, Rehder JR, Lee MB, O'Brien T, McDonnell PJ. Anaerobic flora of the conjunctival sac in patients with AIDS and with anophthalmia compared with normal eyes. *Acta Ophthalmol (Copenh)*1994;72(2): 241–245
- 33 Comerie-Smith SE, Nunez J, Hosmer M, Farris RL. Tear lactoferrin levels and ocular bacterial flora in HIV positive patients. *Adv Exp Med Biol* 1994;350: 339–344
- 34 Tandon R, Vajpayee RB, Gupta V, Vajpayee M, Satpathy G, Dada T. Polymicrobial keratitis in an HIV-positive patient. *Indian J Ophthalmol* 2003;51 (1):87–88
- 35 Kozak I, Sample PA, Hao J, Freeman WR, Weinreb RN, Lee TW, Goldbaum MH. Machine learning classifiers detect subtle field defects in eyes of HIV individuals. *Trans Am Ophthalmol Soc* 2007;105:111–118
- 36 Dejaco-Ruhswurm I, Kiss B, Rainer G, Krepler K, Wedrich A, Dallinger S, Rieger A, Schmetterer L. Ocular blood flow in patients infected with human immunodeficiency virus. *Am J Ophthalmol* 2001;132:720–726
- 37 Maturi RK, Font RL. Ultrastructural features and prevalence of tubuloreticular structures in the ocular vasculature of patients with AIDS: a study of 23 cases. *Br J Ophthalmol* 1996;80:252–255
- 38 Tufail A, Holland GN, Fisher TC, Cumberland WG, Meiselman HJ. Increased polymorphonuclear leucocyte rigidity in HIV infected individuals. *Br J Ophthalmol* 2000;84:727–731
- 39 Plummer DJ, Bartsch DU, Azen SP, Max S, Sadun AA, Freeman WR. Retinal nerve fiber layer evaluation in human immunodeficiency virus-positive patients. *Am J Ophthalmol* 2001;131:216–222
- 40 Besada E, Shechtman D, Black G, Hardigan PC. Laser scanning confocal ophthalmoscopy and polarimetry of human immunodeficiency virus patients without retinopathy, under antiretroviral therapy. *Optom Vis Sci*2007;84:189–196
- 41 Bussolino F, Mitola S, Serini G, Barillari G, Ensolì B. Interactions between endothelial cells and HIV-1. *Int J Biochem Cell Biol* 2001;33 (4):371–390
- 42 Wu RF, Ma Z, Myers DP, Terada LS. HIV-1 Tat activates dual Nox pathways leading to independent activation of ERK and JNK MAP kinases. *J Biol Chem* 2007;282 (52):37412–37419
- 43 Matzen K, Dirxk AE, oude Egbrink MG, Speth C, Gotte M, Ascherl G, Grimm T, Griffioen AW, Sturzl M. HIV-1 Tat increases the adhesion of monocytes and T-cells to the endothelium in vitro and in vivo: implications for AIDS-associated vasculopathy. *Virus Res* 2004;104(2):145–155
- 44 Bai L, Zhang Z, Zhang H, Li X, Yu Q, Lin H, Yang W. HIV-1 Tat protein alter the tight junction integrity and function of retinal pigment epithelium: an *in vitro* study. *BMC Infect Dis* 2008; 8 :77
- 45 Banker AS. Posterior segment manifestations of human immunodeficiency virus/acquired immune deficiency syndrome. *Indian J Ophthalmol*2008;56 (5): 377–383
- 46 Holland GN. AIDS and ophthalmology: the first quarter century. *Am J Ophthalmol* 2008;145:397–408
- 47 Schmidt D. The mystery of cotton-wool spots – a review of recent and historical descriptions. *Eur J Med Res* 2008;13(6):231–236
- 48 De Silva DJ, Tumuluri K, Joshi N. Conjunctival squamous cell carcinoma: atypical presentation of HIV. *Clin Experiment Ophthalmol* 2005;33(4):419–420
- 49 Newton R. A review of the aetiology of squamous cell carcinoma of the conjunctiva. *Br J Cancer*1996;74(10):1511–513
- 50 Tornesello ML, Duraturo ML, Waddell KM, Biryahwaho B, Downing R, Balinandi S, Lucas SB, Buonaguro L, Buonaguro FM. Evaluating the role of human papillomaviruses in conjunctival neoplasia. *Br J Cancer* 2006;94(3):446–449
- 51 Guech-Ongey M, Engels EA, Goedert JJ, Biggar RJ, Mbulaiteye SM. Elevated risk for squamous cell carcinoma of the conjunctiva among adults with AIDS in the United States. *Int J Cancer* 2008;122(11):2590–2593
- 52 Chisi SK, Kollmann MK, Karimurio J. Conjunctival squamous cell carcinoma in patients with human immunodeficiency virus infection seen at two hospitals in Kenya. *East Afr Med J*2006;83(5):267–270
- 53 Osahon AL, Onunu AN. Ocular disorders in patients infected with the human immunodeficiency virus at the University of Benin Teaching Hospital, Benin City, Nigeria. *Niger J Clin Pract* 2007;10(4):283–286
- 54 Zhang Z, Li B, Shi J, Xu X, Li L, Gao F. Intraocular extension of conjunctival squamous cell carcinoma. *Ophthalmologica* 2007;221(3):200–203
- 55 Gichuhi S, Irlam JJ. Interventions for squamous cell carcinoma of the conjunctiva in HIV-infected individuals. *Cochrane Database Syst Rev*2007;18(2): CD005643
- 56 Kaines A, Davis G, Selva D, Leibovitch I, Dodd T, Malhotra R. Conjunctival squamous cell carcinoma with perineural invasion resulting in death. *Ophthalmic Surg Lasers Imaging* 2005;36(3):249–251
- 57 Curtis TH, Durairaj VD. Conjunctival Kaposi sarcoma as the initial presentation of human immunodeficiency virus infection. *Ophthal Plast Reconstr Surg* 2005; 21:314–315
- 58 Feller L, Lemmer J. Insights into pathogenic events of HIV-associated Kaposi sarcoma and immune reconstitution syndrome related Kaposi sarcoma. *Infect Agent Cancer* 2008;3:1
- 59 Sarwar N, Stebbing J, Bower M. Translational review of AIDS-related Kaposi's sarcoma. *Update on Cancer Therapeutics* 2007;2:53–60
- 60 Tirelli U, Bernardi D, Spina M, Vaccher E. AIDS-related tumors: integrating antiviral and anticancer therapy. *Crit Rev Oncol Hematol* 2002;41(3):299–315
- 61 Aversa SM, Cattelan AM, Salvagno L, Crivellari G, Banna G, Trevenzoli M, Chiarion-Sileni V, Monfardini S. Treatments of AIDS-related Kaposi's sarcoma. *Crit Rev Oncol Hematol* 2005;53(3):253–265
- 62 Deregibus MC, Cantaluppi V, Doublier S, Brizzi MF, Deambrosio I, Albini A, Camussi G. HIV-1-Tat protein activates phosphatidylinositol 3-kinase/AKT-dependent survival pathways in Kaposi's sarcoma cells. *J Biol Chem* 2002; 277(28):25195–25202

- 63 Dugel PU, Gill PS, Frangieh GT, Rao NA. Ocular adnexal Kaposi's sarcoma in acquired immunodeficiency syndrome. *Am J Ophthalmol* 1990;110(5):500-503
- 64 Pantanowitz L, Dezube BJ. Kaposi sarcoma in unusual locations. *BMC Cancer* 2008;8:190
- 65 Kagu MB, Nggada HA, Garandawa HI, Askira BH, Durosinmi MA. AIDS-associated Kaposi's sarcoma in Northeastern Nigeria. *Singapore Med J* 2006; 47(12):1069-1074
- 66 Biswas J, Sudharshan S. Anterior segment manifestations of human immunodeficiency virus/acquired immune deficiency syndrome. *Indian J Ophthalmol* 2008;56(5):363-375
- 67 Scheschonka A, Mosch M, Krieglsteiner S, Turowski B, Zanella FE. Pre- and posttreatment MR imaging in AIDS-related Kaposi sarcoma of the conjunctiva and lacrimal gland. *AJNR Am J Neuroradiol* 2003;24(7):1327-1329
- 68 Jeng BH, Holland GN, Lowder CY, Deegan WF, III, Raizman MB, Meisler DM. Anterior segment and external ocular disorders associated with human immunodeficiency virus disease. *Surv Ophthalmol* 2007;52:329-368
- 69 Minoda H, Usui N, Sata T, Katano H, Serizawa H, Okada S. Human herpesvirus-8 in Kaposi's sarcoma of the conjunctiva in a patient with AIDS. *Jpn J Ophthalmol* 2006;50(1):7-11
- 70 Brun SC, Jakobiec FA. Kaposi's sarcoma of the ocular adnexa. *Int Ophthalmol Clin* 1997;37:25-38
- 71 Bonnet F, Jouvencel AC, Parrens M, Leon MJ, Cotto E, Garrigue I, Morlat P, Beylot J, Fleury H, Lafon ME. A longitudinal and prospective study of Epstein-Barr virus load in AIDS-related non-Hodgkin lymphoma. *J Clin Virol* 2006; 36(4):258-263
- 72 Peterson OD, Kirwan OD. A rare ocular manifestation of non-Hodgkins' lymphoma. *Clinical Eye and Vision Care* 1999;11:199-206
- 73 Matzkin DC, Slamovits TL, Rosenbaum PS. Simultaneous intraocular and orbital non-Hodgkin lymphoma in the acquired immune deficiency syndrome. *Ophthalmology* 1994;101(5):850-855
- 74 Smith JR, Henderson WW, Rosenbaum JT, Neuwelt EA, Moses AV. Cultured human endothelial cells expressing HIV-1 Vpu and Tat support the expansion of malignant B cells from primary central nervous system lymphoma. *Br J Ophthalmol* 2008; 92:297-299
- 75 Dal Maso L, Franceschi S. Epidemiology of non-Hodgkin lymphomas and other haemolymphopoietic neoplasms in people with AIDS. *Lancet Oncol* 2003; 4(2): 110-119
- 76 Pietersma F, Piriou E, van Baarle D. Immune surveillance of EBV-infected B cells and the development of non-Hodgkin lymphomas in immunocompromised patients. *Leuk Lymphoma* 2008;49(6):1028-1041
- 77 Mwanza JC, Nyamabo LK, Tylleskar T, Plant GT. Neuro-ophthalmological disorders in HIV infected subjects with neurological manifestations. *Br J Ophthalmol* 2004;88(11):1455-1459
- 78 Mackey DA, Fingert JH, Luzhansky JZ, McCluskey PJ, Howell N, Hall AJ, Pierce AB, Hoy JF. Leber's hereditary optic neuropathy triggered by antiretroviral therapy for human immunodeficiency virus. *Eye* 2003;17:312-317
- 79 Shaikh S, Ta C, Basham AA, Mansour S. Leber hereditary optic neuropathy associated with antiretroviral therapy for human immunodeficiency virus infection. *Am J Ophthalmol* 2001;131:143-145
- 80 Di Simone N, De Santis M, Tamburrini E, Di Nicuolo F, Lucia MB, Riccardi P, D'Ippolito S, Cauda R, Caruso A. Effects of antiretroviral therapy on tube-like network formation of human endothelial cells. *Biol Pharm Bull* 2007;30(5): 982-984
- 81 Jain V, Shome D, Natarajan S. Nevirapine-induced Stevens-Johnson syndrome in an HIV patient. *Cornea* 2008;27(3):366-367
- 82 Biswas J, Sudharshan S, Babu RB. Ocular lesions in AIDS: Indian scenario. *Am J Ophthalmol* 2008;146(2):331
- 83 Esposito S, Porta A, Bojanin J, Gualtieri L, Cesati L, Vismara E, Principi N. Effect of highly active antiretroviral therapy (HAART) on the natural history of ocular manifestations in HIV-infected children. *Eye* 2006;20:595-597
- 84 Ndoye NB, Sow PS, Ba EA, Ndiaye MR, Wade A, Coll-Seck AM. [Ocular manifestations of AIDS in Dakar]. *Dakar Med* 1993;38:97-100
- 85 Nagata Y, Fujino Y, Matsumoto S, Nishi M, Ono A, Mochizuki M, Oka S, Kimura S, Shimada K. Ocular manifestations in Japanese patients with human immunodeficiency virus infection. *Jpn J Ophthalmol* 1993; 37:275-281
- 86 Chiou SH, Liu CY, Hsu WM, Chan YJ, Chou CK, Chung YM, Liu JH, Liu WT, Chen SC, Wong WW. Ophthalmic findings in patients with acquired immunodeficiency syndrome. *J Microbiol Immunol Infect* 2000;33:45-48
- 87 Lim SA, Heng WJ, Lim TH, Leo YS, Wong SY. Ophthalmic manifestations in human immunodeficiency virus infection in Singapore. *Ann Acad Med Singapore* 1997;26:575-580
- 88 Muccioli C, Belfort JR, Lottenberg C, Lima J, Santos P, Kim M, de Abreu MT, Neves R. [Ophthalmological manifestations in AIDS: evaluation of 445 patients in one year]. *Rev Assoc Med Bras* 1994;40(3):155-158
- 89 Matos KT, Santos MC, Muccioli C. Ocular manifestations in HIV infected patients attending the department of ophthalmology of Universidade Federal de Sao Paulo. *Rev Assoc Med Bras* 1999;45:323-326
- 90 Mesaric B, Lisic M, Kniewald T, Ugrinovic N, Begovac J. Ocular manifestations in patients with human immunodeficiency virus infection before and after the introduction of highly active antiretroviral therapy. *Lijec Vjesn* 2005;127:123-128
- 91 Adepoju FG, Olawumi HO, Adekoya BJ. HIV seropositivity and related eye diseases in Uith, Ilorin. *Niger Postgrad Med J* 2007;14:163-165
- 92 Kahraman G, Krepler K, Franz C, Ries E, Maar N, Wedrich A, Rieger A, Dejacó-Ruhswurm I. Seven years of HAART impact on ophthalmic management of HIV-infected patients. *Ocul Immunol Inflamm* 2005; 13:213-218
- 93 Miyamoto C, Yashiro S, Nagata Y, Nagataki S. Ocular complications in patients infected with human immunodeficiency virus seen at the Acquired Immunodeficiency Syndrome Clinical Center. *Nippon Ganka Gakkai Zasshi* 2001; 105:483-487
- 94 Ausayakhun S, Watananikorn S, Ittipunkul N, Chaidaroon W, Patikulasila P, Patikulasila D. Epidemiology of the ocular complications of HIV infection in Chiang Mai. *J Med Assoc Thai* 2003; 86:399-406
- 95 Gharai S, Venkatesh P, Garg S, Sharma SK, Vohra R. Ophthalmic manifestations of HIV infections in India in the era of HAART: analysis of 100 consecutive patients evaluated at a tertiary eye care center in India. *Ophthalmic Epidemiol* 2008;15(4):264-271
- 96 Biswas PN, Saha B, Ghosh S, Mallik S, Nandi K, Niyogi DK, Bhaduri G. Ophthalmic manifestations in people living with HIV attending a tertiary care centre of Eastern India. *J Indian Med Assoc* 2008;106(5):292-294
- 97 Inoue T, Hayashi K, Omoto T, Kosaki R, Higaki S, Shimomura Y. Corneal infiltration and CMV retinitis in a patient with AIDS. *Cornea* 1998;17:441-442
- 98 Cheng L, Rao NA, Keefe KS, Avila CP, Jr., MacDonald JC, Freeman WR. Cytomegalovirus iritis. *Ophthalmic Surg Lasers* 1998; 29:930-932
- 99 Wilhelmus KR, Font RL, Lehmann RP, Cernoch PL. Cytomegalovirus keratitis in acquired immunodeficiency syndrome. *Arch Ophthalmol* 1996; 114:869-872
- 100 Patel SS, Rutzen AR, Marx JL, Thach AB, Chong LP, Rao NA. Cytomegalovirus papillitis in patients with acquired immune deficiency syndrome. Visual prognosis of patients treated with ganciclovir and/or foscarnet. *Ophthalmology* 1996; 103:1476-1482
- 101 Park KH, Bang JH, Park WB, Kim HB, Kim NJ, Ahn JK, Chang KH, Oh MD, Choe KW. Retrobulbar Optic Neuritis and Meningoencephalitis Following Progressive Outer Retinal Necrosis due to CMV in a Patient with AIDS. *Infection* 2008;36(5):475-479
- 102 Franco-Paredes C, Bellehumeur T, Merchant A, Sanghi P, DiazGranados C, Rimland D. Aseptic meningitis and optic neuritis preceding varicella-zoster progressive outer retinal necrosis in a patient with AIDS. *AIDS* 2002;16(7): 1045-1049