

Gel and porous polyethylene implants for anophthalmic cavity reconstruction—evaluation using the B scan ultrasound

Lucieni Cristina Barbarini Ferraz¹, Silvana Artioli Schellini¹, Erika Hoyama¹, Sheila Lordelo Wludarski², Carlos Roberto Padovani³

¹ Department of Ophthalmology, Faculdade de Medicina de Botucatu, Universidade Estadual Paulista, São Paulo State, Brazil

² Department of Pathology, Faculdade de Medicina de Botucatu, Universidade Estadual Paulista, São Paulo State, Brazil

³ Department of Biostatistics, Faculdade de Medicina de Botucatu, Universidade Estadual Paulista, São Paulo State, Brazil

Correspondence to: Silvana Artioli Schellini. Department of Ophthalmology, Faculdade de Medicina de Botucatu, Universidade Estadual Paulista, São Paulo State, Brazil. sartioli@fmb.unesp.br

Received:2009-08-16 Accepted:2009-09-26

Abstract

• **AIM:** To evaluate the host response of the gel and porous polyethylene implants in anophthalmic cavities using the B scan ultrasound.

• **METHODS:** Thirty-six white rabbits underwent unilateral enucleation with placement of gel or porous polyethylene spheres implants. The animals were submitted to clinical examination weekly and to ultrasound evaluation on 30, 60 and 90 days after surgery.

• **RESULTS:** All rabbits with gel polyethylene spheres, except one, showed implant extrusion probably because the gel spheres have hydrated and increased in volume. The B ultrasound of the gel polyethylene implant did not show vessels inside during the following period. Five animals (27.8%) with porous polyethylene spheres presented implant extrusion after 30 days of surgery. According to B ultrasound, the porous polyethylene implant showed irregular and heterogeneous architecture and reflective peaks similar to vascularized tissues.

• **CONCLUSION:** More studies are required to determine the ideal volume of gel polyethylene implant necessary to correct the diminished orbital content in the anophthalmic cavity. The B ultrasound effectiveness showed in this study for anophthalmic socket implants evaluation provides useful information for further *in vivo* studies and might substitute expensive methods of implants vascularization evaluation.

• **KEYWORDS:** polyethylene implant; B ultrasound; rabbit; anophthalmic cavity

Ferraz LCB, Schellini SA, Hoyama E, Wludarski SL, Padovani CR. Gel and porous polyethylene implants for anophthalmic cavity reconstruction—evaluation using the B scan ultrasound. *Int J Ophthalmol* 2009;2(4):291–293

INTRODUCTION

Many different materials have been suggested to replace volume in the anophthalmic cavity and the integrated spheres, mainly the porous polyethylene, were the focus of the researches in the last years^[1]. However, the porous polyethylene has a rough surface and conjunctival dehiscence can take place when prosthesis contact with the conjunctiva occurs.

A gel polyethylene implant was then thought in order to create a less traumatic contact between the implant and the conjunctival mucosa^[2].

The integrated implants present progressive vascularization into the spheres, resulting in sphere-hosted integration. This integration pattern has been evaluated before by expensive methods, including computerized tomography scan and/or magnetic resonance imaging^[3-5].

The purpose of this study was: ① to evaluate clinically the gel and porous polyethylene spheres implanted in enucleated cavities of rabbits and; ② to evaluate the host response integration pattern of the implants using B scan ultrasound.

MATERIALS AND METHODS

An experimental study was performed using 36 Norfolk albino rabbits. The procedures and the animals' maintenance were in accordance with the ARVO resolution on Use of Animals in Research and approved by a local Ethics Committee.

The animals underwent unilateral enucleation followed by implantation of 12mm spheres of gel polyethylene (Polietigel-

Homus Biotecnologia-SP, Brazil) (18 animals) or porous polyethylene (Polipore-Homus Biotecnologia-SP, Brazil) (18 animals).

Both spheres were composed of the same chemical structural material, but the gel implants were recovered with a membrane-like structure that was used to contain the gel or semi-liquid state polyethylene.

Surgical procedure: All animals were submitted to surgeries under general anesthesia and were performed by the same surgeon. The right eye of each rabbit was enucleated and an unwrapped polyethylene sphere-gel or porous-was implanted. The conjunctiva and Tenon' capsule were closed using a non-absorbable 6-0 (Polycron-Ethicon) running suture. The animals were sacrificed 90 days after surgery.

Methods of evaluation: The animals were submitted to clinical examination weekly and to B ultrasound evaluation on 30, 60 and 90 days after the surgical procedure.

Statistical Analysis The results were submitted to Occurrence Frequency analysis^[6].

RESULTS

Gel Polyethylene Spheres

Clinical evaluation All rabbits with gel polyethylene spheres, except one (94.4%), showed implant extrusion between 15 and 90 days after surgery (average of 20 days). Although the initially implanted spheres had 12mm in diameter, the expelled spheres showed around 20mm. Orbital infection or inflammation was not observed in any of these animals.

Ultrasound evaluation The gel polyethylene spheres did not present vascularization during the following period, showing low reflectivity image inside the implant and high reflective pattern posterior to the implant until 90 days after the surgery (Figure 1).

Porous Polyethylene Spheres

Clinical evaluation Five animals (27.8%) with porous polyethylene spheres presented implant extrusion after 30 days of surgery. Conjunctival dehiscence occurred in two animals (11.1%) and one of them was excluded due to systemic infection not related to the surgical procedure.

Ultrasound evaluation Spheres vascularization was observed though neovessels filling theirs porous, indicating sphere-hosted integration. Porous polyethylene showed medium reflectivity (40%-60%) until 90 days after surgery, although the image was more echo-dense at the time. An irregular internal structure indicating heterogeneous architecture was also present, despite of the sound attenuation observed during the examination (Figure 2).

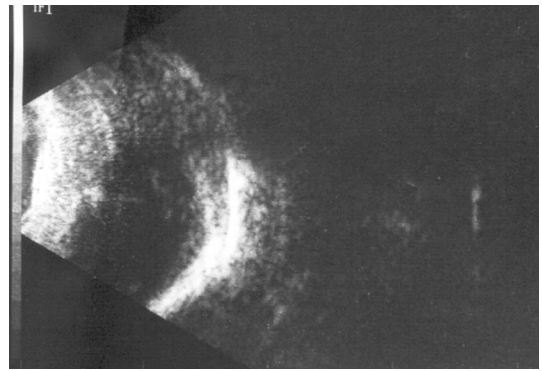


Figure 1 B scan ultrasound of a gel polyethylene sphere 90 days after surgery

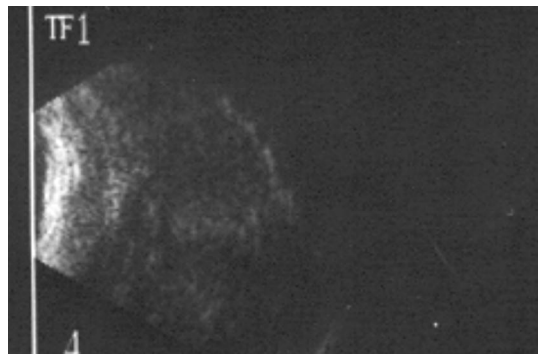


Figure 2 B scan ultrasound of a porous polyethylene sphere 90 days after surgery

DISCUSSION

In this study, we compared the porous polyethylene, already commercially available, and the polyethylene sphere in the gel form. Both spheres were made by the same professional and consisted basically of the same chemical substance. However, the porous polyethylene sphere presented a rough external surface and the gel polyethylene, a smooth surface because of its membrane-like wrapper material, employed to contain the gel or semi-liquid polyethylene.

The main cause of gel implant extrusion seemed to be the sphere volume increase after implantation. The spheres showed an increase in size which caused suture dehiscence due to mechanical forces and elicited their extrusion. The extrusion was probably a combination of factors: the increase of the spheres size that hydrated and became bigger than the orbital volume and the lack of implants integration to the host tissues, observed by the high early expulsion rate after surgeries.

The integration rate of a biomaterial is measured by the pattern of vascularization between the implant and the host tissues. Many studies described the vascularization pattern using histological methods^[7-9]. Others used the computerized tomography and/or the magnetic resonance imaging^[3-5].

However, there are only few studies using conventional ultrasound scan to evaluate the vascularization pattern inside the sphere implants^[10].

A previous reports showed that the porous polyethylene implant vascularization occurred during the first month after surgeries^[9,11], we decided to start the B ultrasound evaluation around this time. This method provided useful information for further studies *in vivo*. The vascularized porous polyethylene implants showed low reflective peaks similar to blood pattern^[12]. Therefore, the B ultrasound evaluation showed us that the Polietigel implants did not vascularize, in contrast to the Polipore implants that presented increased neovessels colonization inside.

The polyethylene spheres in the gel form hydrated and increased in volume after orbital implantation procedure. More studies need to be performed to determine the ideal biomaterial size necessary to replace the orbital volume deficiency in the anophthalmic cavity reconstruction.

The B scan ultrasound technique is an alternative method to substitute the more expensive methods employed to evaluate the spheres vascularization pattern.

Acknowledgements: The authors thank Romualdo Rossa, MD (in memorian) for providing the polyethylene spheres.

REFERENCES

1 Karesh JW, Dresner SC. High-density porous polyethylene (Medpore) as a

- successful anophthalmic socket implant. *Ophthalmology*1994;101(10):1688-1696
- 2 Schellini SA, Xavier AP, Hoyama E, Rossa R, Pellizon C, Marques ME, Padovani CR. Gelatinous polyethylene in the treatment of the anophthalmic cavity. *Orbit* 2002;21(3):189-193
- 3 Aimbinder DJ, Haik BG, Mazzoli RA. Anophthalmic socket and orbital implants. Role of CT and MR imaging. *Radiol Clin North Am*1998;36(6):1133-1147
- 4 De Potter P, Duprez T, Cosnard G. Postcontrast magnetic resonance imaging assessment of porous polyethylene orbital implant (Medpor). *Ophthalmology*2000; 107(9):1656-1660
- 5 Flanders AE, De Potter P, Rao VM, Tom BM, Shields CL, Shields JA. MRI of orbital hydroxyapatite implants. *Neuroradiology* 1996;38(3):273-277
- 6 Norman GR, Streiner DL. Biostatistics: the bare essentials. St. Louis: Mosby 1994:260
- 7 Mawn LA, Jordan DR, Gilberg S. Proliferation of human fibroblasts *in vitro* after exposure to orbital implants. *Can J Ophthalmol*2001;36(5):245-251
- 8 Rubin PA, Popham JK, Bilyk JR, Shore JW. Comparison of fibrovascular ingrowth into hydroxyapatite and porous polyethylene orbital implants. *Ophthalm Plast Reconstr Surg*1994;10(2):96-103
- 9 Schellini SA, Marques ME, Padovani CR, Taga EM, Rossa R. Comparison of synthetic hydroxyapatite and porous polyethylene implants in eviscerated rabbit eyes. *Ophthalm Plast Reconstr Surg*2003;19(2):136-139
- 10 Yamamoto ES, Hoyama E, Schellini SA, Padovani CR. Avalia o ultrassonografica do implante orbitario em cavidade anofthalmica. *Rev Bras Oftalmol*2001;60: 637-642
- 11 Murray TG, Cicciarelli NL, Croft BH, Garonzik S, Voigt M, Hernandez E. Design of a magnetically integrated microporous implant. *Arch Ophthalmol*2000; 118(9):1259-1262
- 12 Byrne SF, Green Ronald. Examination techniques for the orbit. In: Ultrasound of the eye and the orbit. St. Louis: Mosby 2002:15-45,273-289