

Neovascularization profile in rat allogenic penetrating keratoplasty

Yan Zhang¹, Xiao-He Lu¹, Xiang Li²

¹ Department of Ophthalmology, Zhujiang Hospital, Southern Medical University, Guangzhou 510282, Guangdong Province, China

² Department of Pharmacy, Nanfang Hospital, Southern Medical University, Guangzhou 510515, Guangdong Province, China

Correspondence to: Xiao-He Lu. Department of Ophthalmology, Zhujiang Hospital, Southern Medical University, Guangzhou 510282, Guangdong Province, China. luxiaohe63@hotmail.com

Received:2009-08-17 Accepted:2009-09-07

Abstract

• **AIM:** To observe the neovascularization process with no intervention in rat allogenic penetrating keratoplasty.

• **METHODS:** Allogenic penetrating keratoplasties were successfully performed in 34 female SPF SD rats with no intervention after operations. Corneal neovascularization (CNV) process was noted on day 4, 7, 15 and 30 with operating microscope. The vascular area surface was calculated using the formula $C/12 \times 3.14 \times [r^2 - (r - l)^2]$.

• **RESULTS:** CNV was noted in 29 out of 34 rats (85%). Firstly, the new vessels distributed around the cornea like a brush then gradually extended towards the center. The vessels were distorted and massive with branched tails, they continued growing to reticulated veins in peak time then gradually atrophied. The average neovascularization area (SE) on day 4, 7, 15 and 30 was $11.8 \pm 3.5\text{mm}^2$, $18.5 \pm 4.0\text{mm}^2$, $14.4 \pm 4.3\text{mm}^2$ and $6.0 \pm 1.8\text{mm}^2$, respectively and $12.7 \pm 1.9\text{mm}^2$ in total. The average percentage that new vessels accounting the whole cornea area (SE) was $30.8\% \pm 8.7\%$, $65.3\% \pm 12.8\%$, $59.4\% \pm 14.5\%$, $36.2\% \pm 10.9\%$ and $48.7\% \pm 6.4\%$ in total.

• **CONCLUSION:** In rat allogenic penetrating keratoplasties without intervention, CNV presents on day 4 and reaches the maximum area on day 7. Then the vessels gradually atrophies, about 50% of the maximum area still remains on day 30.

• **KEYWORDS:** rat; allogenic penetrating keratoplasty; neovascularization

Zhang Y, Lu XH, Li X. Neovascularization profile in rat allogenic penetrating keratoplasty. *Int J Ophthalmol* 2009;2(4):348–351

INTRODUCTION

Corneal neovascularization (CNV) after keratoplasty not only makes cornea lose transparency and impair vision directly, but also promotes the rejection and lead to failure of cornea transplantation in the end. However, inhibition of CNV has always been a difficult and hot spot in ophthalmic research. In this article, we observe and analyze the CNV process in rat allogenic penetrating keratoplasty model. Through the development and apoptosis of it, we hope to get some hints on CNV inhibition.

MATERIALS AND METHODS

Materials All experiments were performed on 6-8 week old female SD rat, weighting 180-200g. There were 51 rats in total, 17 as donors and 34 as recipients. All animals were purchased from Nanfang Hospital Experimental Animal Center.

Methods Pentobarbital solution (30g/L) was injected into rat's peritoneal cavity for anesthesia. The average dose was 0.32mL (range from 0.1mL to 0.5mL). When the rat fell asleep, the eyelids of right eye were wiped twice with alcohol swab and then conjunctival sac was washed with 2g/L liquor nitrofurazoni. Average dose of 0.04mL lidocaine solution 20g/L (range from 0.01mL to 0.2mL) was injected into the muscle pyramid along the orbital wall inward towards the optic foramen. Digital pressure was applied for 3-5 minutes to prevent bleeding.

Allogenic Penetrating Keratoplasty

Donor preparation Both corneas of donor rat were used in the experiment. When rat stopped winking after anesthesia, the eye was fixed with a forceps. A 3.75mm diameter corneal trephine was applied on the centre of cornea and rotated clockwise and anticlockwise up to 2/3 of total thickness of cornea. Then, the anterior chamber was opened with a triangular shaped surgical blade and sodium hyaluronate was injected into anterior chamber. The corneal button was cut with vanas scissor. The donor corneal button was kept in a mixture of ringer's solution and sodium hyaluronate gel for 20 minutes.

Recipient preparation Keratoplasty procedure was

performed in right eye only in all the rats. The procedure was the same as donor rat, but a 3.25mm diameter corneal trephine was used to take out the corneal button and sodium hyaluronate gel was injected into anterior chamber to replace the aqueous.

Penetrating keratoplasty The corneal graft was fixed in placed by interrupted sutures, eight sutures per eye (needle arc 3/8 •0.7 ×4,11/0 nylon monofilament non-absorbable suture, Ningbo Medical Suture Needle Factory). The sodium hyaluronate was washed with saline and replaced with sterile air.

Postoperative Followup After operation, secretions in conjunctiva sac were washed with saline everyday. The new vessel's growth and change was observed with operating microscope on day 4, 8, 15 and 30. The vascular area surface was calculated using the formula $C/12 \times 3.14 \times [r^2 - (r-l)^2]$. In this formula, C was the clock hours CNV accounted, r was cornea radius (mm) and l was the vertical length (mm) that CNV extended from limbus to cornea center. The percentage that CNV accounting the whole cornea area was calculated.

Statistical Analysis Normality test was carried out with Kolmogorov-Smirnov test, when $P > 0.05$ data was considered distributed normally. Statistical values of CNV area and percentage that CNV accounting the whole cornea area were calculated.

RESULTS

Neovascularization Rate Penetrating keratoplasty was successfully performed in the right eye. Two rats were excluded since one died and the other's document was not completed. The rest 34 rats were observed until 30 days after operation and 29 of them had growth of CNV, which accounted 85% of the total. Only three rats did not show any CNV, which accounted only 15%.

Appearance of Neovascularization Conjunctive vessel extending towards the limbus expanded significantly and divided into several branches (Figure 1). At the beginning, CNV surrounded the limbus like the hair of a brush and it was quite difficult to identify every vessel clearly (Figure 2). Then some of vessels gradually thickened and distorted, with branch liked tails (Figure 3). The vessels extended from the limbus towards the centre of cornea and gradually invaded the donor cornea (Figure 4), which looked like dense reticulum and invaded the whole cornea (Figure 5).

Corneal Neovascularization Area Kolmogorov-Smirnov Normality test of CNV area on day 4, 7, 15 and 30 after keratoplasty showed P values > 0.200 (for all the days

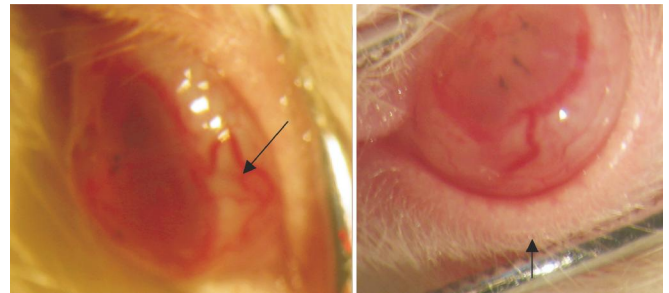


Figure 1 Conjunctive vessel extending towards the limbus significantly expanded and divided into several branches (arrow)

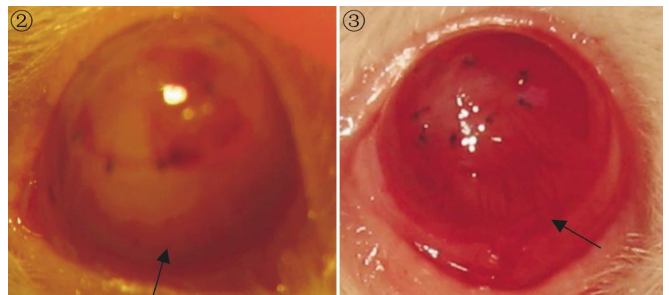


Figure 2 Corneal new vessels surrounded limbus like the hair of a brush (arrow)

Figure 3 New vessels thickened with branch liked tails (arrow)

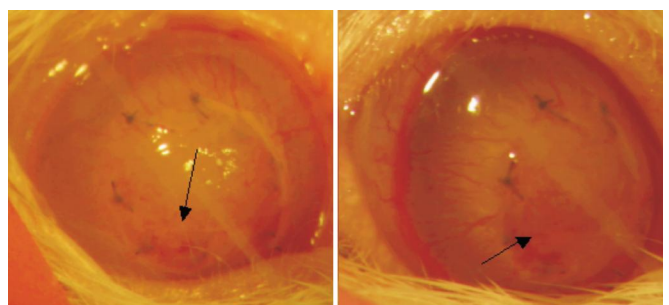


Figure 4 New vessels invaded into the donor cornea (arrow)

individually), on the whole the P value was 0.126. Therefore, CNV area data were considered distributed normally (Figure 6). The CNV area on different observation days was different (Figure 7).

Normality Test of Percentages that Corneal Neovascularization Accounting the Whole Cornea Area Kolmogorov-Smirnov Normality test of CNV accounting the whole cornea area on day 4, 7, 15 and 30 after keratoplasty showed P values 0.200, 0.180, 0.156 and 0.200 respectively; on the whole the P value was 0.193. Therefore, CNV area data were considered distributed normally (Figure 8). The CNV accounting the whole cornea area percentage on different observation days was also different (Figure 9).

DISCUSSION

CNV makes cornea lose transparency and affects vision directly. However, new vessels invading into cornea will

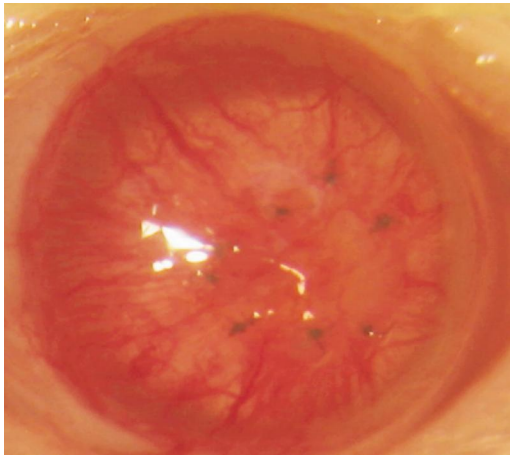


Figure 5 New vessels looked like dense reticulum and invaded the whole cornea

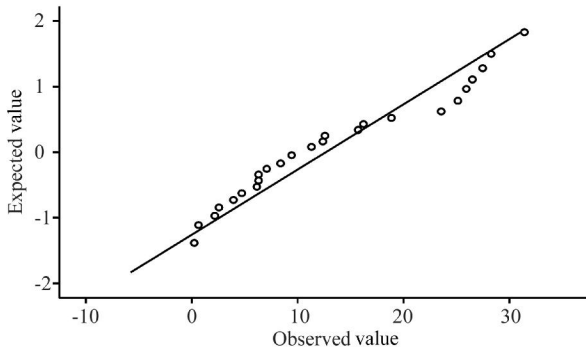


Figure 6 CNV area data are normality distributed

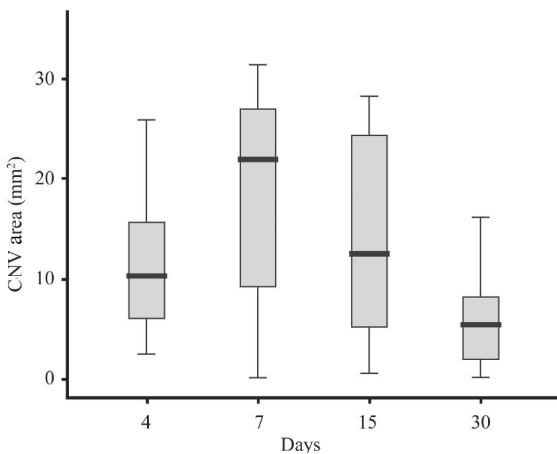


Figure 7 CNV area on different days

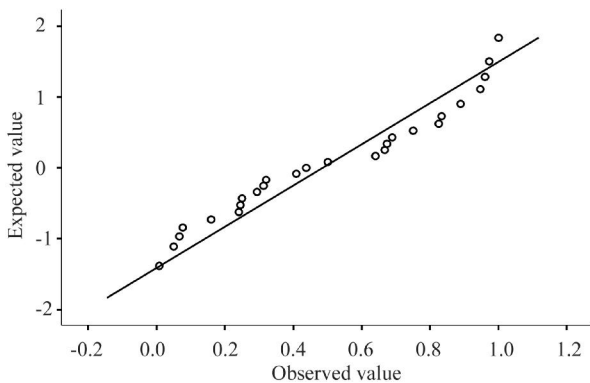


Figure 8 CNV accounting the whole cornea area

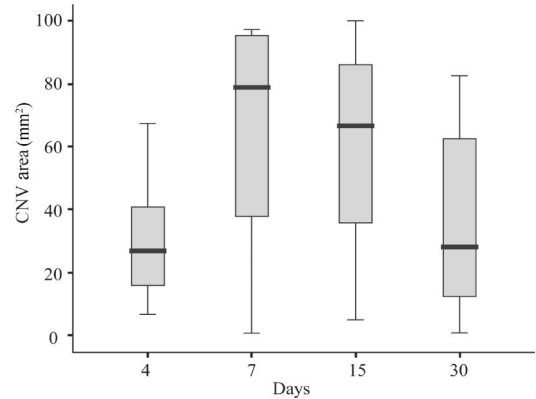


Figure 9 CNV accounting the whole cornea area percentage on different days

never disappear but only degenerate into ghost vessels^[1] Therefore, prevention of new vessels formation is very important. CNV also lead to the failure of keratoplasty. Recently some researchers think that CNV triggered by wound repairing and inflammation mechanism maybe the immediate cause of transplantation rejection^[2]. Though cornea is recognized to be immune privileged for a long time, great deal of clinical researches have proved that the most important reason of corneal transplantation failure still is nonreversible rejection. Corneal transplantation's prospective efficacy is not as optimistic as we used to think. Even though transplantation's successive rate is quite high in short term, graft survival area exceeding 90% one year after operation is not common in clinical practice^[1]. Williams and Coster^[2] reported that eyes which develop rejection must have neovascularization and inflammation. The molecular mechanism of "vascular privilege" and "immune privilege" are overlapped in many cases^[3]. Neovascularization in corneal transplantation should be considered to be even more important because it leads to rejection phenomenon of the graft.

Profuse capillary plexuses around the limbus are originated from ciliary arteries, which come from ophthalmic arteries. The capillary plexuses can generate CNV from angiogenesis^[4]. With stimulation of angiogenesis factors such as inflammation factors, the balance between vascular growth factor and inhibiting factor is broken. Vascular endothelial cells fill up the vessels increasing their permeability. With the effect of many enzymes, vascular basilar membrane disaggregates, endothelial cells exert pseudopodias through the gap of basilar membrane towards vascular stimulating factor's direction. The endothelial cells go forward continuously and form a two poles aligned cell column. While at the same time, cell column's anterior extremity

displays branching and has blood flow with the formation of lumen. In the end, leucocytes in surrounding tissues decorates the new vessels; pericytes originated from parent vessels cover the new vessels and form basilar membrane. The new vessels become matured later^[5].

CNV are divided into superficial NV and deep stromal NV according to their different positions in cornea. The superficial NV originate from superficial peripheral pannus and manifest as single or multiple distorted vessels with branched like tails and extend into superficial stroma under corneal epithelium. It is caused by chronic superficial irritation and is commonly seen in corneal inflammation and anterior segment operations. Most CNV are of this kind (Figure 3). Deep stromal NV can develop in any stroma level. The vessels are straight and branched, accompanied by nerve fibers occasionally. It is common in scleritis, tuberculosis and syphilis patients' eyes^[4,6].

From this experiment's allogenic penetrating keratoplasty rat model, we find that no macroscopic NV can be found on the first three days after operation. From the fourth day, conjunctiva vessels extend towards the limbus, thicken and enlarge significantly and divide into overall branches, which are significantly prominent than normal (Figure 1). CNV surround limbus like the hair of a brush at the beginning (Figure 2) then extend towards the centre of cornea gradually. They are distorted and massive vessels with branched tails (Figure 3), extend from the periphery area towards the center and invade implant finally (Figure 4). On day 8 the quantity and density of NV reach the peak, vessels cross like reticulum and spread the whole cornea (Figure 5). Then the vessels gradually atrophy to become linear lines.

From Figure 4 the CNV change with time significantly. Because of the differences in cornea radiuses, percentages that CNV accounting the whole cornea area could reflect its change tendency more objectively. On day 4 the NV accounting 31% of the whole cornea area on average, the maximum value is 67%. On day 7 the CNV reach the maximum area, which is 65.3% on average and the maximum was 97%. CNV begin to atrophy on day 15, though the average percentage still is 59.5%. We could see from Figures 3 and 4 that the total area has decreased. The NV areas decrease significantly on day 30, the average percentage is 36%, which only was a half of its peak value.

Though macroscopic CNV appear on 3-4 days postoperative, neoangiogenesis process starts immediately since it is

triggered by wound repairing and inflammation mechanism. Anti-inflammation therapy should be started as early as possible to prevent angiogenesis. Because sutures are left for a long time, the time of anti-inflammation therapy should be extended as long as possible. As an important inflammation factor, IL-1 could interrupt vascular endothelial cell directly, stimulate the migration and hyperplasia of them and increase the synthesis of many angiogenesis factors (VEGF, IL-8, FGF, MMPs)^[6,9]. Anti-inflammation drugs such as NSAIDs had inhibitory effect on NV induced by vascular endothelial growth factor^[10].

In this experiment, we only observed until 30 days after operation, four observation days were settled and the spans were quit long, both of these designs would affect the accuracy of test. The formula $C/12 \times 3.14 \times [r^2 - (r-l)^2]$ to calculate CNV area assumed that the NV had uniformed density^[11], but in fact the density of NV varied greatly. This also maybe a factor affecting the objectivity of final results.

REFERENCES

- 1 Williams KA, Coster DJ. The immunobiology of corneal transplantation. *Transplantation* 2007;84(7):806-813
- 2 Cursiefen C, Cao J, Chen L, Liu Y, Maruyama K, Jackson D, Kruse FE, Wiegand SJ, Dana MR, Streilein JW. Inhibition of hemangiogenesis and lymphangiogenesis after normal-risk corneal transplantation by neutralizing VEGF promotes graft survival. *Invest Ophthalmol Vis Sci* 2004;45(8):2666-2673
- 3 Cursiefen C. Immune privilege and angiogenic privilege of the cornea. *Chem Immunol Allergy* 2007;92:50-57
- 4 Zhang SX, Ma JX. Ocular neovascularization: implication of endogenous angiogenic inhibitors and potential therapy. *Prog Retin Eye Res* 2007;26(1):1-37
- 5 Zhang Y, Lu XH. Progression of corneal neovascularization mechanism and regulation. *Rec Adv Ophthalmol* 2008;28(9):708-714
- 6 Chévez-Barrios P. Are we getting closer to prevention and treatment of corneal neovascularization? *Clin Experiment Ophthalmol* 2007;35(8):689-690
- 7 Ma DH, Chen JK, Zhang F, Lin KY, Yao JY, Yu JS. Regulation of corneal angiogenesis in limbal stem cell deficiency. *Prog Retina Eye Res* 2006;25(6):563-590
- 8 Nakao S, Kuwano T, Tsutsumi-Miyahara C, Ueda S, Kimura YN, Hamano S, Sonoda KH, Sajio Y, Nukiwa T, Strieter RM, Ishibashi T, Kuwano M, Ono M. Infiltration of COX-2-expressing macrophages is a prerequisite for IL-1 β -induced neovascularization and tumor growth. *J Clin Invest* 2005;115(11):2979-2991
- 9 Kuwano T, Nakao S, Yamamoto H, Tsuneyoshi M, Yamamoto T, Kuwano M, Ono M. Cyclooxygenase 2 is a key enzyme for inflammatory cytokine-induced angiogenesis. *FASEB J* 2004;18(2):300-310
- 10 Pakneshan P, Birsner AE, Adini I, Becker CM, D'Amato RJ. Differential suppression of vascular permeability and corneal angiogenesis by nonsteroidal anti-inflammatory drugs. *Invest Ophthalmol Vis Sci* 2008;49(9):3909-3913
- 11 D'Amato RJ, Loughnan MS, Flynn E, Folkman J. Thalidomide is an inhibitor of angiogenesis. *Proc Natl Acad Sci U S A* 1994;91(9):4082-4085