

Vitrectomy of rhegmatogenous retinal detachment in morning glory syndrome

Xiao-Li Yang¹, Xi Zhang²

¹ Department of Ophthalmology, the Affiliated Hospital of North Sichuan Medical College, Nanchong 637000, Sichuan Province, China

² Department of Ophthalmology, the First People's Hospital Affiliated to Shanghai Jiaotong University, Shanghai 200080, China

Correspondence to: Xiaoli Yang. Department of Ophthalmology, the Affiliated Hospital of North Sichuan Medical College, Nanchong 637000, Sichuan Province, China. yxloculist@yahoo.com.cn
Received:2010-01-18 Accepted:2010-02-19

Abstract

• We report a case of retinal detachment in morning glory syndrome (MGS). We think that identification of the retinal break, removal of the traction force by vitrectomy, the use of long-acting gas as endotamponade, all contributed to the successful treatment of the disease. The pathogenic mechanisms of the disease and the function of B-scan to the diagnosis are included.

• **KEYWORDS:** morning glory syndrome; retinal detachment; vitrectomy

DOI:10.3980/j.issn.2222-3959.2010.01.21

Yang XL, Zhang X. Vitrectomy of rhegmatogenous retinal detachment in morning glory syndrome. *Int J Ophthalmol* 2010;3(1):89-91

INTRODUCTION

Morning glory syndrome (MGS) is a congenital anomaly, in which the optic nerve head is enlarged and excavated, it is named for similarity in appearance to the trumpet shaped morning glory flower^[1]. The incidence of the anomaly is unknown, but most authors agree that is rare. Usually unilateral, it is characterized by an excavated nerve-head defect with a central tuft of white fibroglial tissue, with straight retinal vessels radiating from the edge of the anomaly. Retinal detachment has been reported in 26-38% of patients with MGS^[2]. However, the pathogenesis of retinal detachment in these cases has been controversial. We report a case with retinal detachment that was successfully treated.

Case Report

A 35-year-old male patient presented with a history of 6 days photopsia and visual field defect of his right eye. A complete ocular examination was performed. The patient

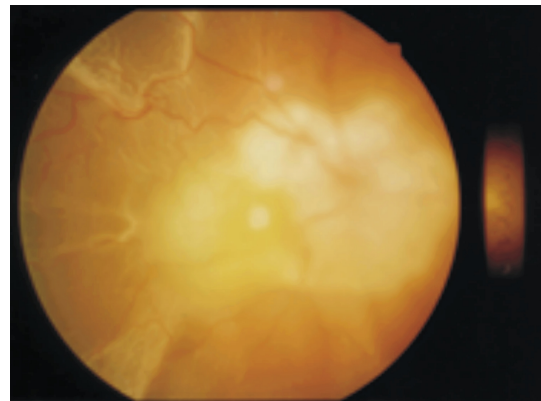


Figure 1 Fundus photography of the right eye The large excavated disc anomaly with retinal vessels radiating from its periphery (white ring), yellowish macula and completely retinal detachment

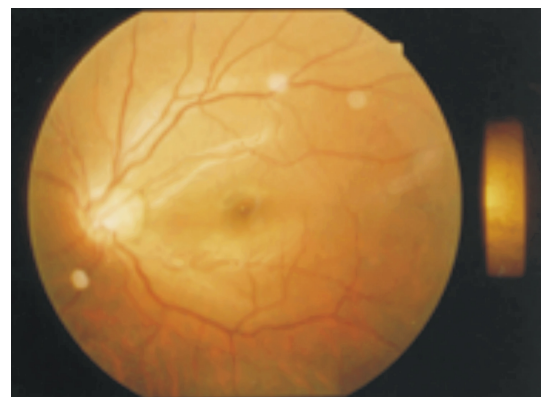

Figure 2 Fundus photography of left eye (normal)

was high myopic (-20.0 diopters) and his best-correct vision was CF/10cm in the right eye. Slit-lamp examination and intraocular pressure were normal. The fundus showed a retinal detachment adjacent to the morning glory disk anomaly. There was a tiny slitlike break near the margin of excavation at the temporal side. The macular of the patient looks yellowish (Figure 1). The left eye was unremarkable (Figure 2). The patient did not have hearing problems and systemic examination was unremarkable. The patient was diagnosed with the morning glory syndrome with retinal detachment and amblyopia in right eye. The patient underwent a pars plana vitrectomy with removal of the posterior hyaloid, fluid-air exchange, laser endophotocoagulation to the temporal margin of the excavated disk and

Vitrectomy of rhegmatogenous retinal detachment in MGS

injection 20% perfluoropropane. Subretinal fluid was evacuated through the tiny slitlike break. Post-operatively, the patient was kept on a face-down position for 3 weeks. The retina was reattachment and the best corrected vision was 0.08 during the follow-up for 4 months.

DISCUSSION

Morning glory syndrome is a rare congenital anomaly with the optic nerve. Many ocular abnormalities have been reported. These include strabismus, cataract, nystagmus, lens coloboma, eye lid hemangioma, aniridia, microphthalmos, Duane's retraction syndrome and retinal detachment [3-4]. Retinal detachment is the most common ocular complication and is thought to be difficult to repair because retinal breaks were not detected in most cases. Several pathogenic mechanisms have been proposed to explain the high risk of developing retinal detachment in patient with MGS: (1) Continuous traction exerted by the gradually increasing axial retro-displacement of the optic nerve [4,5]. (2) Abnormal communication between the sub-arachnoid space of the optic nerve and the subretinal space may occur allowing central serous fluid accumulation sub-retinally [2,6]. (3) Liquefied vitreous entering the intraretinal space at the edge of the optic nerve [4]. (4) Leakage of fluid from blood vessels within the anomalous optic disc or from the peripapillary choroid may be responsible for the sub-retinal fluid. A small retinal hole in tissue lying in the optic disc anomaly may provide a fluid pathway between the vitreous cavity and sub-retinal space in some eyes with MGS. Our patient was high myopic and has a slitlike break in the optic disc anomaly, so the small hole would allow the liquefied vitreous to enter the subretinal space and cause a rhegmatogenous detachment. The macula may also be abnormal in MSG patients. Yamana and colleagues correlated a larger elevated peripapillary white ring with an abnormal macula lacking a reflex and with the retinal tissue appearing yellowish. Our patient's appearance of macula was similar to their patients (Figure 1). The color of the macula was thought to be due to yellow pigments in the ganglion cells[7].

For the accurate diagnosis of MGS, except for the special appearance of fundus, we can check A /B-scan ultrasonography and FFA of MGS patients. These examines could show the imageological features of MGS from different aspects, which helps clinicians to differentiate it from other diseases such as optic disc coloboma. For example, the special imageological features of B-scan ultrasonogram : the vitreous cavity extended to the posterior pole and optic papilla projected to the basal part of muscle cones , thus the posterior part of vitreous cavity looked like an upside-down bottleneck. The echogenic band of retinal

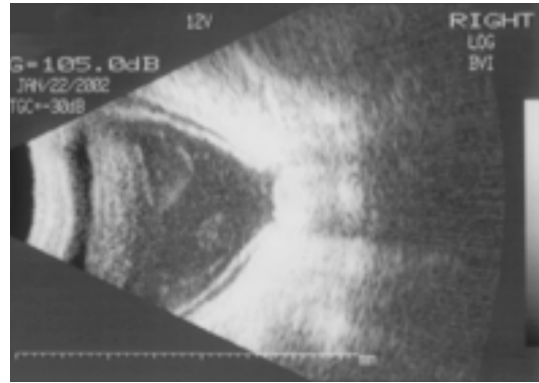


Figure 3 B-scan ultrasonogram of the right eye The vitreous cavity extended to the posterior pole and optic papilla, projected to the basal part of muscle cones and thus the posterior part of vitreous cavity looked like an upside-down bottleneck; The echogenic band of retinal detachment could also be seen

detachment could also be seen (Figure 3). B-scan ultrasonography, in particularly, is considered to be reliable imageological method for the accurate diagnosis of MGS complicated with retinal detachment .

Retinal detachment related to MGS was thought to be difficult to repair, some of the patient required multiple operations to achieve retinal reattachment and had a poor visual outcome. Coll and colleagues reported a patient of retinal detachment in MGS, there was a pigmented membrane covering the optic disc and a slit-like retinal break was observed within the cup. Unfortunately, the silicone oil leaked into the sub-retinal space through the retinal opening. They emphasized the importance of traction membrane removal to prevent a sub-retinal migration of silicone oil [2]. In our patient, the retina was successfully reattached after a single operation and the vision improved. We think that the successful outcome may be attributed to the following factors. (1) Identification of the retinal break. The lack of contrast between the white scleral background and the anomalous disc may make identification difficult. Ho reported that Optical coherence tomography was beneficial in the detection of subtle slit-like breaks at the margin of excavation in retinal detachment in MGS and also provided a good guidance in confirming the closure of the retinal break [8].(2) Removal of epipapillary fibroglial tissue and its traction forces .(3) Use of gas, rather than silicone oil, as endotamponade. The lower interfacial tension is not adequate to prevent bubbles of silicone oil from passing through the retinal break and the buoyant force of silicone oil is insufficient to flatten the peripapillary retina. The long-acting gas with high surface tension is preferred for retinal reattachment.

The vision is usually poor in patients with MGS. The vision loss may be due to the presence of retinal abnormalities in

the macular or amblyopia secondary to anisometropia or strabismus. Many doctors think that MSG is non-progressive and does not require treatment. But Loudot and colleagues reported a clinical observation of a 2.5-year-old girl, referred for the diagnosis of MGS in the left eye with severe amblyopia, but after 1 year treatment with functional amblyopia therapy, visual acuity improved from 1/10 to 7/10⁹. So in view of MSG with a high risk for developing retinal detachment and association with some ocular abnormalities, accurate diagnosis, monitoring and amblyopia therapy are essential for children with Morning glory syndrome.

REFERENCES

- 1 Kindler P. Morning glory syndrome: unusual congenital optic disk anomaly. *Am J Ophthalmol* 1970; 69(3):376-384
- 2 Coll GE, Chang S, Flynn TE, Brown GC. Communication between the subretinal space and the vitreous cavity in the Morning glory syndrome. *Gracé's Arch Clin*

Exp Ophthalmol 1995; 233(7):441-443

- 3 Hope-Ross M, Johnston SS. The morning glory syndrome associated with sphenothmoidal encephalocele. *Ophthalmic Paediatr Genet* 1990; 2(2): 147-153
- 4 Debney S, Vingrys AJ. Case report: the morning glory syndrome. *Clin Exp Optom* 1990;73(1):31-35
- 5 Haik BG, Greenstein SH, Smith ME, Abramson DH, Ellsworth RM. Retinal detachment in the morning glory disc anomaly. *Ophthalmology* 1984;91 (12): 1638-1647
- 6 Manschot WA. Morning glory syndrome: a histopathological study. *Br J Ophthalmol* 1990; 74(1):56-58
- 7 Yamana T, Nishimura M, Ueda K, Chijiwa T. Macular involvement in morning glory syndrome. *Jpn J Ophthalmol* 1983; 27(1):201-209
- 8 Ho TC, Tsai PC, Chen MS, Lin LL . Optical coherence tomography in the detection of retinal break and management of retinal detachment in morning glory syndrome. *Acta Ophthalmol Scand* 2006; 84(2): 225-227
- 9 Loudot C, Fogliarini C, Baeteman C, Mancini J, Girard N, Denis D. Rehabilitation of functional amblyopia in morning glory syndrome. *J Fr Ophthalmol* 2007; 30(10) :998-1001