

# Detection of 8-hydroxydeoxyguanosine enzyme in recurrent pterygium raising a question on its role on recurrence

*Omar M S Ismaeel<sup>1</sup>, Hasnan Jaafar<sup>2</sup>, Mohtar Ibrahim<sup>1</sup>*

<sup>1</sup>Department of Ophthalmology, School of Medical Sciences, Universiti Sains Malaysia, 16150, Kubang Kerian, Kelantan, Malaysia

<sup>2</sup> Department of Pathology, School of Medical Sciences, Universiti Sains Malaysia, 16150 Kubang Kerian, Kelantan, Malaysia

**Correspondence to:** Omar M S Ismaeel. Department of Ophthalmology, School of Medical Sciences, Universiti Sains Malaysia, 16150, Kubang Kerian, Kelantan, Malaysia. omarobaidi@yahoo.co.uk

Received:2010-07-17 Accepted:2010-08-20

## Abstract

• **AIM:** To detect the presence of 8-hydroxydeoxyguanosine enzyme (8-OHdG) in recurrent pterygium and its role on recurrence.

• **METHODS:** Ninety-two samples were collected of which 55 from primary pterygium, 12 from recurrent and 25 from normal conjunctiva. A cross sectional study was embarked to detect the presence of the 8-OHdG enzyme in primary, recurrent pterygium and the normal conjunctival tissue by immunohistochemistry test.

• **RESULTS:** The immunohistochemistry test showed positive results: 35 in primary, 2 in recurrent pterygia and 4 in normal conjunctiva, respectively. Significant association between primary pterygium and 8-OHdG enzyme (63.6% of samples are positive) and no significant relation was detected with recurrent pterygium (16.7% of samples are positive).

• **CONCLUSION:** 8-OHdG enzyme is associated with primary pterygium. It is also present in normal conjunctival tissue. For the first time it is detected in recurrent pterygia. This may raise question whether 8-OHdG enzyme has a role in recurrence of pterygium.

• **KEYWORDS:** 8-OHdG; primary and recurrent pterygia

DOI:10.3980/j.issn.2222-3959.2010.03.15

Ismaeel OMS, Jaafar H, Ibrahim M. Detection of 8-hydroxydeoxyguanosine enzyme in recurrent pterygium raising a question on its role on recurrence. *Int J Ophthalmol* 2010;3(3):245-248

## INTRODUCTION

Pterygium is a common external ocular disease affecting people around the world. It is observed that there is an increased prevalence of pterygium with decreasing latitudes and described the presence of a "pterygium belt" located between 37 degrees north and south of the equator [1-4]. They suggested this variation may be attributable to greater ultraviolet radiation exposure nearer the equator [5]. Sun light promotes its effect by UVB radiation that causes oxidative damage to the DNA of the cells. As a result of this damage an enzyme called 8-OHdG is produced. It is highly mutagenic that lead to increased cellular proliferation and development of pterygium. The sun light contains UVB component which has a photo oxidative damaging effects on ocular surface either by direct or indirect effect by damaging the DNA of the epithelial cells which is mediated by reactive oxygen species (ROS) that leads to the production of 8-Hydroxydeoxyguanosine (8-OHdG) enzyme.

This enzyme is sensitive and stable biomarker for evaluating the degree of DNA oxidative damage. 8-OHdG enzyme is considered a highly mutagenic factor because it frequently mispairs with adenine during DNA replication, ultimately giving rise to the G-C to T-A transversion mutations. This mutation may result in increase cellular proliferation and angiogenesis that lead to pterygium development [6]. The increase in 8-OHdG enzyme content in DNA has been shown to increase cancer risk [6]. In human genome there is a base excision repair system to correct 8-OHdG enzyme. The human 8-Oxoguanine glycosylase 1 (hOGG1) is the key component responsible for the removal of 8-OHdG enzyme in DNA. The hOGG 1 molecule can recognize 8-OHdG enzyme and then catalyses both the release of 8-OHdG and the cleavage of DNA at resulting apurinic site, the enzyme itself is very sensitive to UVB irradiation which cause photolysis of tryptophan residues at the active site and leads to hOGG 1 inactivation. This inactivation may render the DNA more susceptible to 8-OHdG enzyme mutagenic effect [6,7]. The rate of recurrent pterygium after excision of

## Detection of 8-OHdG in recurrent pterygium

primary pterygium is variable and may be low (2%) or high up to 30-70% depending on the method of treatment of the primary pterygium [8]. The exact cause of recurrence is not established yet, we hypothesized that the damaging effect of UVB light irradiation result in production of 8-OHdG enzyme that has mutagenic effect and result in abnormal cellular growth and angiogenesis that lead to development of recurrent pterygium after excision of the primary pterygium.

### MATERIALS AND METHODS

Cross sectional study was performed to determine the expression of 8-OHdG enzyme in primary and recurrent pterygia and its relation to pterygia development. (Ethical committee approval had been obtained before starting the study). Samples of primary, recurrent pterygia and normal conjunctival (control) tissues were harvested from the patients who were eligible for surgery. The samples were collected from our indicated patients who gave formal consents. The patients had been selected from eye clinic in (Hospital Universiti Sains Malaysia) and were planned for surgical excision of pterygium and conjunctival graft.

Normal conjunctival tissues were obtained from normal conjunctiva after consent was obtained from patients who underwent cataract or pterygium surgeries. They were taken from superior nasal and inferior nasal conjunctiva to detect the difference in the expression of 8-OHdG, between normal and pterygium tissues. We excluded secondary and temporal pterygia, patients with previous surgery other than pterygium excision and conjunctival inflammation due to other causes.

Preoperatively after the eyes were cleansed and draped, local anesthesia was injected into the body of the pterygium to balloon the pterygium. The pterygium was dissected starting at the head by using Tooke's knife; the head was completely separated from the cornea followed by the body. The underlying tissue was dissected and removed to clear up the surface of the cornea and sclera. Once dissection was completed, the pterygium was excised by using conjunctival scissors. The bare surface of the sclera was covered by free conjunctival graft which was dissected and harvested from superior or inferior conjunctiva and fixed in place by using either Tisseel glue or vicryl 8-0 interrupted sutures.

The excised tissues were kept in sterile container contains 70% alcohol and transported to pathology laboratory for tissue processing. Polylysine slides were prepared from the sections for immunohistochemistry test. All the sections were pretreated with proteinase K (pretreatment reagent) for 40 minutes. Immunohistochemistry test was performed to detect 8-OHdG enzyme. According to the protocol of Merck Company (Merck, Selangor, Malaysia) the specimens were

**Table 1 The distribution of 8- OHdG enzyme in the three groups of the study**

Groups	Primary	Recurrent	Control	n(%)
Positive enzyme	35(63.6)	2(16.7)	4(16)	41(44.6)
Negative enzyme	20(36.4)	10(83.3)	21(84)	51(55.4)
Total	55	12	25	92

incubated with diluted blocking serum in PBS for 20 minutes; this step is to suppress non specific binding of immunoglobulin.

After rinsing the specimens with three changes of Phosphate balanced saline (PBS), 5 minutes for each rinse to remove excess serum. The sections were incubated with primary antibody (Goat Anti 8-OHdG primary Antibody) for 60 minutes at room temperature. After that the specimens were rinsed with three changes of PBS, 5 minutes each rinse to remove all unbound primary antibody. Then sections were incubated with secondary antibody for 30 minutes at room temperature. The sections were incubated with Avidin and biotinylated horse raddish peroxidase H for 30 minutes to form large macromolecules after that the sections were incubated with diaminibenzidine tetrahydrochloride (DAB). The horse radish peroxidase converts the DAB substrate into an insoluble dark brown precipitate that is deposited around binding site of primary antibody. The presence of DAB localizes the site of expression of the antigen within the tissue section. Sections had been stained with haematoxylin solution for 3 minutes. Haematoxylin stains the nuclei of the cells a purple color to provide contrast to the brown DAB staining and permits the cellular architecture to be seen. Then sections were incubated in 95% ethanol two changes, 10 seconds each, to remove excess water and cause the tissue to shrink slightly enhancing the intensity of the staining. Another incubation in 100% ethanol with two changes, 10 seconds each. After that the sections were incubated in xylene for two changes, 10 seconds each, to complete gradual removal of water, tissue shrinkage and for enhancement the intensity of the staining.

**Statistical Analysis** Statistical analysis was done by Chi-square test.  $P < 0.05$  was considered statistically significant.

### RESULTS

Ninety two patients participated in this study, forty eight of them were male and forty four were female.

The patients were divided into three groups (Table 1): Group A: Fifty-five patients with primary Pterygium participated in the first group. The mean age of participants in this group was 55.3 year. Twenty-seven participants were male (49%) and twenty eight participants were female (51%); Group B:

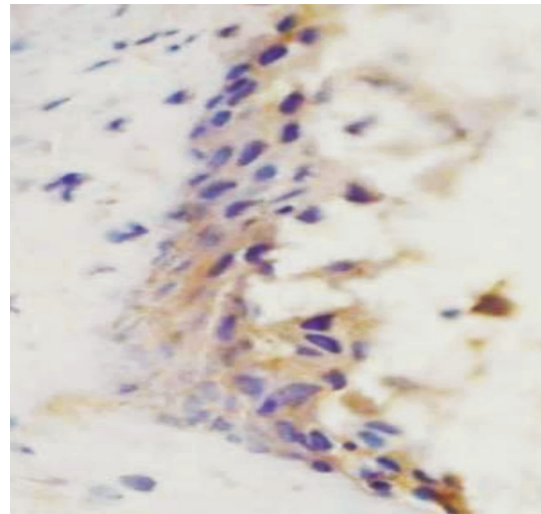
Twelve patients with recurrent pterygium participated in the third group. The mean age of participants in this group was (53.5) year. Nine participants were male (75%) and 3 participants were female (25%) of this group; Group C: Twenty-five patients with normal conjunctiva participated in the second group. The mean age of participants in this group was 64.3 years. Twelve participants were male (48%), and thirteen participants were female (52%).

Positive results in primary pterygia group were higher than positive results in both recurrent pterygium group and normal conjunctiva (control) group. Positive results were indicated by brownish staining of the epithelial cells under light microscope (Figure 1). Negative control slides were used to control non specific binding of 8-OHdG enzyme. All the reagents and the antibodies that had been used in this study were provided by Merck Company (Merck, Selangor, Malaysia).

There was significant association of 8-OHdG enzyme with primary pterygium ( $P < 0.001$ ) as compared to control group while there was no significant association of 8-OHdG enzyme with recurrent pterygium ( $P = 0.959$ ). To compare the association of 8-OHdG enzyme with primary pterygium and recurrent pterygium results showed significant association with primary pterygium ( $P = 0.003$ ).

## DISCUSSION

The association of 8-OHdG enzyme with primary pterygium had been demonstrated in few studies which concluded that the exposure to sun light play an important role in the pathogenesis of primary pterygium by its oxidative damaging effect reflected by the detection of the 8-OHdG enzyme in the tissues but non of these studies correlated the 8-OHdG enzyme with the recurrence of the pterygium. Kau *et al*<sup>[6]</sup> found abundant immuno-reactivity of 8-OHdG enzyme in primary pterygium tissues (100 % of samples were positive) and significantly higher levels of 8-OHdG enzyme in the DNA of primary pterygium tissues (mean value 55.93ng/mg DNA). Tsai *et al*<sup>[7]</sup> found in his study 23.1% of the specimens (primary pterygium) were positive for 8-OHdG enzyme and Perra *et al*<sup>[9]</sup> detected the 8-OHdG enzyme in 67.74% of the primary pterygium samples. These findings accord with our findings in the primary pterygium. The results of these studies support the hypothesis that oxidative damage of cellular DNA which might be brought by UVB exposure plays a role in the pathogenesis of primary pterygium indicated by detection of 8-OHdG enzyme. The difference in the percentage of positive samples might be attributed to different methods of immunohistochemistry with variable sensitivity and genetic variation of different



**Figure 1 Positive staining for 8-OHdG enzyme** (Cells cytoplasm stained with brown color)

genes that affect the expression of 8-OHdG enzyme.

Regarding the expression of the 8-OHdG enzyme in normal conjunctiva Tsai *et al*<sup>[7]</sup>, and Perra *et al*<sup>[9]</sup> both could not detect the presence of 8-OHdG enzyme in any normal sample on the other hand Kau *et al*<sup>[6]</sup> detected the 8-OHdG enzyme in 100 % of normal conjunctival samples, in spite of this the level of 8-OHdG enzyme was low (11.40ng/mg DNA) in normal conjunctiva as compared to primary pterygium samples. The average level of 8-OHdG enzyme in primary pterygium was 4.7 fold higher than that in normal conjunctiva. All the normal conjunctiva samples were harvested from areas adjacent to the primary pterygium.

In our study, we found that 16% of normal conjunctiva tissues were positive to 8-OHdG enzyme, 75% of positive conjunctival samples were obtained from normal conjunctiva adjacent to primary pterygium while 25% of positive conjunctiva samples were obtained from inferior conjunctiva. Presence of 8-OHdG enzyme in normal conjunctiva indicates oxidative stress on epithelial cells of the normal conjunctiva which is not fully expressed to produce its mutagenic effect. This may be due to repair mechanism of the mutant gene conducted by hOGG 1 enzyme. The presence of 8-OHdG enzyme may precede the development of pterygium by certain period of time.

In our study, we found 16.7% (2 cases) of recurrent pterygia are positive for 8-OHdG enzyme. To our knowledge this is the first time that 8-OHdG enzyme was detected in recurrent pterygium. A "non significant" result does not mean that there is no association in the population Hulley *et al*<sup>[10]</sup>. Our results could hold the possibility of two explanations: (1) It can be presumed that 8-OHdG enzyme still play a role in pathogenesis of recurrent pterygium; (2) There is a

## Detection of 8-OHdG in recurrent pterygium

---

possibility that 8-OHdG enzyme is not playing an important role in the pathogenesis of recurrent pterygium which raises a question about the causes that lead to development of recurrent pterygium other than 8-OHdG enzyme related mechanism.

In conclusion, there was a significant association between the presence of 8-OHdG enzyme and primary pterygium. Despite of no significant association between the presence of 8-OHdG enzyme and recurrent pterygium, the role of the 8-OHdG enzyme in recurrence could not be discounted. Detection of 8-OHdG enzyme in normal conjunctiva indicates an oxidative stress to epithelial cells that might be expressed later as pterygium.

Acknowledgement: We would like to express our appreciation to the staff of operative theatre in Hospital Universiti Sains Malaysia. We are so grateful to the staff of Pathology laboratory for their great assistance to perform this study. The study was funded by the USM short term grant 304/PPSP/6131630.

### REFERENCES

- 1 Cameron ME. Pterygium throughout the world. *Springfield* 1965
- 2 Darrell RW, Bach RCA. Pterygium among veterans. *Arch Ophthalmol* 1963;70(2):158-169
- 3 Anderson JR. A pterygium map. *Acta Ophthalmol (Copen)* 1954;3:404-405
- 4 Detels R, Dhir SP. Pterygium a geographical study. *Arch Ophthalmol* 1967;78(4):485-491
- 5 Wong TY, Foster PJ, Johnson GJ, Seah SK, Tah DT. The prevalence and risk factors for pterygium in an adult Chinese population in Singapore. *Am J Ophthalmol* 2001;131(2):176-183
- 6 Kau HC, Tsai CC, Lee CF, Kao SC, Hsu WM, Liu JH, Wei YH. Increased oxidative DNA damage, 8-hydroxydeoxy- guanosine, in human pterygium. *Eye* 2006;20(7):826-831
- 7 Tsai YY, Cheng YW, Lee H, Tsai FJ, Tseng SH, Lin CL, Chang KC. Oxidative DNA damage in pterygium. *Mol Vis* 2005;11:71-75
- 8 Yasemin O, Seda M, Unsal H, Dilek I, Binnur O, Ozgur I, Jale K, Orhan Z. A comparative study of tissue glue and vicryl suture for closing limbal-conjunctival autografts and histologic evaluation after pterygium excision. *Cornea* 2008;27(5):552-558
- 9 Perra MT, Maxia C, Corbu A, Minerba L, Demurtas P, Colombari R, Martas D, Bravo S, Piras F, Sirigu P. Oxidative stress in pterygia. Relation ship between P 53 and 8-OHdG. *Mol Vis* 2006;12:1136-1142
- 10 Browner WS, Newman TB, Hulley SB. Getting ready to estimate sample size hypothesis and underline principles. In: Hulley S B, Cummings S R, Browner W S, Grady DG, Newman T B. *Designing clinical research*. New York: Lippincott Williams – Wilkins 2007:58