

New surgical therapy for conjunctival lymphangiectasia

Jing Song, Ji-Feng Yu, Gai-Ping Du, Yi-Fei Huang

Foundation item: National Natural Science Foundation of China (No. 30973245, 30471855)

Department of Excimer Laser Center, Clinical Division of Surgery, Chinese People's Liberation Army General Hospital, Beijing 100853, China

Correspondence to: Yi-Fei Huang. Department of Excimer Laser Center, Clinical Division of Surgery, Chinese People's Liberation Army General Hospital, Beijing 100853, China. huangyf301yk@hotmail.com

Received:2010-11-15 Accepted:2010-11-28

Abstract

- **AIM:** To report 7 cases of conjunctival lymphangiectasia, introduce a simple operation method and discuss the result of the pathological examination.
 - **METHODS:** Clinical data including medical history, physical examination, previous surgery history were collected in 7 patients with conjunctival lymphangiectasia. Ocular data including visual acuity, Slit-lamp biomicroscopy were released, as were results of histopathology studies. Surgical method was also introduced by video.
 - **RESULTS:** Seven eyes of 7 patients (4 male and 3 female) with biopsy-proven conjunctival lymphangiectasia underwent the resection. Despite different surgical intervention, the optima method has been founding to treatment conjunctival lymphangiectasia. It is to reduce recurrence that the most concerned problem. In these 7 cases reported, patients kept healthy for 18 months without any one recurrence, whose visual acuity were not affected. Pathological report showed cystic tissue consists of squamous epithelium with significant hyperplasia.
 - **CONCLUSION:** This operation method is simple and easy to complete, as it is deserved to accept for surgeons and patients on the basis of its advantages.
 - **KEYWORDS:** conjunctival lymphangiectasia; meibography; operation method; pathological examination
- DOI:10.3980/j.issn.2222-3959.2010.04.22

Song J, Yu JF, Du GP, Huang YF. New surgical therapy for conjunctival lymphangiectasia. *Int J Ophthalmol* 2010;3(4):365-367

INTRODUCTION

Conjunctival lymphangiectasia is presumably caused by obstruction of lymphatic channels, but the actual cause

often remains unknown. Although it often resolves spontaneously, on occasion the conjunctiva becomes chronically swollen and may cause many discomforts. Patients may complain of foreign body sensation, irritation, etc. We described 7 patients with conjunctival lymphangiectasia, presented to the Department of Excimer Laser Center, People's Liberation Army General Hospital, who were symptomatic and had conjunctival resections for treatment. The average age was 62.0 ± 7.0 years, and average time of follow-up was about 18.0 ± 2.5 months. Despite different surgical intervention, the optima method has been founding to treatment it. It is to reduce recurrence that the most concerned problem. The surgical method introduced in this article can be performed easily in out-patients department and bring fewer invasions and hurt to patients.

CASE 1

A 62-year-old oriental male complained of foreign body sensation in his right eye for 3 days and finding a blister for 1 day.

Past history: His general health was good. In the past he had three attacks of iridocyclitis, which had been treated with ointment, drops, the nature of which were unknown. No cause for the uveitis was discovered and there had been no recurrence for 15 years. There was no history of trauma and other significant family medical history.

Ophthalmologic examination: The visual acuity was 6/6 unaided in both eyes. The cornea, anterior segment, lens, and fundus were normal. The ocular tension measured with the Goldmann applanation tonometer was 12mmHg (right) and 14 mmHg (left). No other abnormality of the right eye was found. Neither the regional lymph glands nor the parotid gland were enlarged.

Slit lamp microscope: The right bulbar conjunctiva was locally edematous with clear boundaries, in which surface can be found obviously conjunctival hyperemic. The chemosis was confined to the bulbar in the interpalpebral region, about $0.3 \times 0.3 \times 0.3$ cm (Figure 1).

Meibography: This method uses an infrared filter and an infrared charge-coupled device video camera to take photographs mainly of meibomian glands [1]. In our report, Meibography had shown that oedematous conjunctiva was full of homogeneous liquid with many compartments (Figure 2).

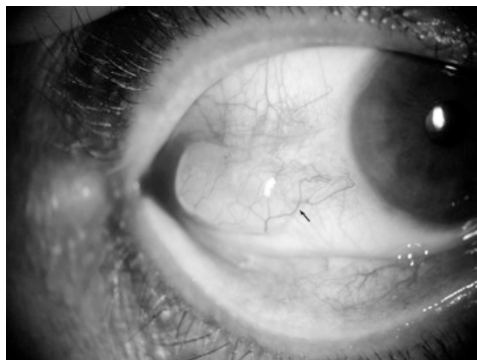


Figure 1 The right bulbar conjunctiva was locally oedematous with clear boundaries. Its surface can be found obviously conjunctival congestion (black arrow). The chemosis was confined to the bulbar in the interpalpebral region, about 0.3×0.3×0.3cm

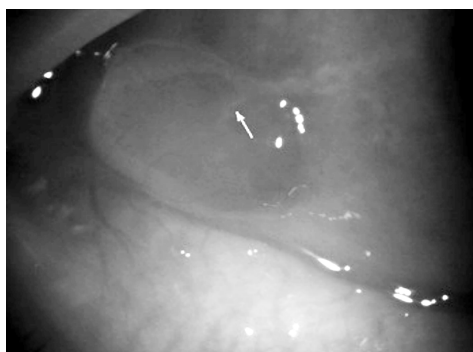


Figure 2 Meibography had shown that oedematous conjunctiva was full of homogen fluid with many compartments (white arrow)

CASE 2

A 58-year-old oriental female complained of her right eye with chemosis for 20 days.

Past surgical history: She was performed a radical excision because of an undesigned mass about 3×3×2cm located at margin of tongue (2001-07-21). Pathological report showed that squamous mucosa with chronic inflammation and subepithelial fibrosis.

Ophthalmologic Examination: No obviously physical signs of eyes can be found except the similiar appearance of right bulbar conjunctiva.

Slit lamp microscope: The right bulbar conjunctiva was locally edematous with clear boundaries; about 0.6 ×0.3 × 0.2cm (Figure 3). The other cases had no especial symptoms necessary to go into details.

The tissue was excised and sent to pathology in formalin for pathologic diagnosis. In each case, the clinical suspicion of conjunctival lymphangiectasia was confirmed by the ophthalmic pathologist's description of noninflammatory large lymphatic vessels, cystic tissue consisted of squamous epithelium with significant hyperplasia (Figure 4).

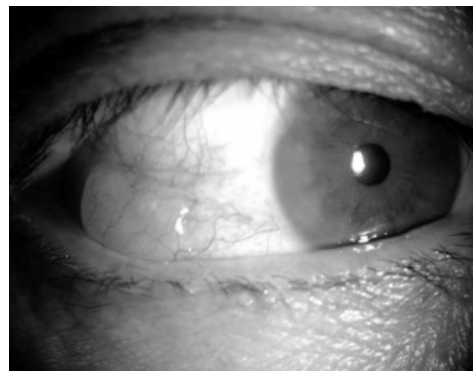

Figure 3 The left one showed the pathologic report issued by Pathology department, top right one showed the surgical specimen, and photomicrograph (bottom right) showed histopathologic appearance of excised conjunctiva with cystic tissue consists of squamous epithelium with significant hyperplasia (HE×200)

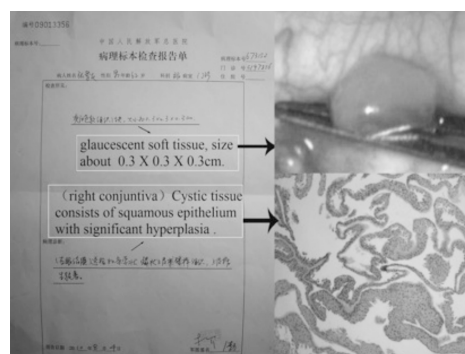


Figure 4 The right bulbar conjunctiva was locally edematous with clear boundaries, size about 0.6×0.3×0.2cm



Figure 5 Titanium Alloy Suture Forceps, angled, 11 mm, 100mm Riede Instruments Schlossbuehlstr, Emmingen - Liptingen Germany

In our report, all patients had been treated with topical anesthesia drops before resection of the lesions. Titanium Alloy High Precisions Suture Forceps, angled (Figure 5) can be expected to complete this task. First, 0.4mm inclined syringe needle was used to blunt separate of bulbar conjunctiva surrounding lymphatic vessels. We noticed that lymphangiectasia had intact cyst wall. Second, the suture forceps was used to remove the intact lesion. The procedure of surgery was simple, and easy to implement, the most critical of which was to make sure the cyst wall to be intact in order to reduce the recurrence (video).

The symptoms and signs of conjunctival lymphangiectasia have been resolved after treatment in outpatient department in all 7 eyes without visual acuity affected. There were no any recurrences in this follow-up case series.

DISCUSSION

As described by Duke Elder conjunctival lymphangiectasia is an uncommon disease, which occurs as a result of a connection between conjunctival lymphatic and blood vessels^[2]. It has two principal manifestations: a cystic lesion of the conjunctiva, which may mimic allergic chemosis^[3], and a beaded dilatation of lymphatic vessels with a string of pearl appearance. In our report, we found that the cystic lesion were consisted of many compartments and had intact cyst walls. The condition is usually unilateral unless associated with Turner syndrome. Symptoms may include ocular irritation, dryness, epiphora, blurred vision, and pain^[4]. Seven cases in our report, the symptoms described from patients were simple, they just found the lesions when had a look into the mirror. The etiology of lymphangiectasia is still unknown, and pathological reports are rare. The recent histopathologic report showed that excised conjunctiva with multiple markedly dilated conjunctival lymphatics distributed diffusely throughout the subepithelial tissue. Note the contrast between the dilated lymphatics with a clear lumen and adjacent blood vessels filled with erythrocytes^[5]. Another histopathology represented an abnormal dilatation of endothelial cell lined conjunctival lymphatic vessels in the absence of inflammation⁴, which was generally considered a minor disorder. However, in our report, histopathologic studies of 7 specimens showed the squamous epithelium were prominent, no erythrocytes could be found. The course of the different histopathologic reports may be on the result of different operation method.

Although conjunctival lymphangiectasia is a rare and benign disease not to worry about, if the condition is sufficiently

severe to require treatment, it has been proved to be eminently remediable by resection. There were many methods to choose, the only attempt was made to obliterate the abnormal lymphatics. Liquid nitrogen cryotherapy were performed to treat conjunctival lymphangiectasia, it was reported resolution of signs and symptoms occurred within 2 weeks of treatment in all 5 eyes and 3 of those had developed recurrent lesions, with an average time to recurrence of 18 months^[6]. Although cryotherapy would appear to be less invasive than surgical excision, it remains unclear from this report which method is least likely to lead to recurrence of lymphangiectasia.

Based on this case series, conjunctival resection described in our report for symptomatic lymphangiectasis could be considered an effective surgical alternative in the treatment of conjunctival lymphangiectasia because our surgical method seem to be less invasive and less recurrence.

REFERENCES

- 1 Arita R, Itoh K, Inoue K, Amano S. Noncontact infrared meibography to document age-related changes of the meibomian glands in a normal population. *Ophthalmology* 2008;115(5):911-915
- 2 Duke-Elder S. Conjunctival diseases. In: Diseases of the Outer Eye, Part 1. Vol. VIII, St. Louis: Mosby, 40
- 3 Kalin NS, Orlin SE, Wulc AE, Heffler KF, Frayer WC, Sulewski ME, Mitra RA, Cavanagh HD. Chronic localized conjunctival chemosis. *Cornea* 1996;15 (3): 295-300
- 4 Perry HD, Cossari AJ. Chronic lymphangiectasis in Turner's syndrome. *Br J Ophthalmol*1986; 70(5):396-399
- 5 Meisler DM, Eiferman RA, Ratliff NB, Burns CD. Surgical management of conjunctival lymphangiectasis by conjunctival resection. *Am J Ophthalmol* 2003; 136(4):735-736
- 6 Frederick W. Fraunfelder MD. Liquid nitrogen cryotherapy for conjunctival lymphangiectasia. *Trans Am Ophthalmol Soc* 2009;107:229-233