

# Osteo –odonto keratoprosthesis in Stevens –Johnson syndrome: a case report

Reddy SC<sup>1</sup>, Tajunisah I<sup>1</sup>, Tan DT<sup>2</sup>

<sup>1</sup>Department of Ophthalmology, Faculty of Medicine, University of Malaya, Kuala Lumpur, Malaysia

<sup>2</sup>Corneal services department, Singapore National Eye Centre & Department of Ophthalmology, Yong Loo Lin School of Medicine, National University of Singapore, Singapore

**Correspondence to:** Reddy SC. Department of Ophthalmology, UCSI School of Medicine, Terengganu Campus, Bukit Khor, 21600 Marang, Terengganu, Malaysia. profsreddy@gmail.com

Received:2011-01-11 Accepted:2011-03-10

## Abstract

• **AIM:** To report a successful osteo-odonto keratoprosthesis (OOKP) procedure in a case of end stage of corneal blindness due to Stevens-Johnson syndrome (SJS).

• **METHODS:** An interventional case report.

• **RESULTS:** We describe a 35-year-old Indian woman, a known case of SJS with bilateral dry eyes and corneal blindness (failed corneal graft with vascularised total corneal opacity in the right eye and non-healing corneal ulcer in the left eye). Vision was hand movement only in both eyes. The corneal ulcer healed with medical treatment resulting in vascularised total corneal opacity with no improvement in vision. OOKP was performed in the right eye and the vision was improved from hand movement to 6/6. The same vision was maintained in the right eye at the last follow-up 5 years after surgery.

• **CONCLUSION:** OOKP provides good visual rehabilitation with long-term anatomically stable prosthesis in patients with end-stage of ocular surface disorders and corneal blindness secondary to SJS.

• **KEYWORDS:** osteo-odonto keratoprosthesis; Stevens-Johnson syndrome; corneal blindness

DOI:10.3980/j.issn.2222-3959.2011.02.23

Reddy SC, Tajunisah I, Tan DT. Osteo–odonto keratoprosthesis in Stevens–Johnson syndrome: a case report. *Int J Ophthalmol* 2011;4(2):212–215

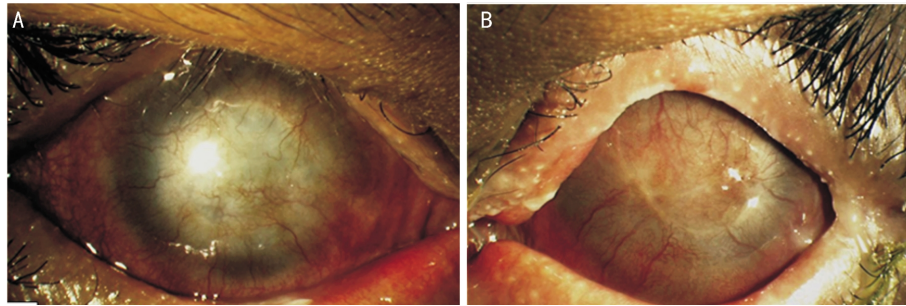
## INTRODUCTION

Corneal transplantation is not successful in all cases of Stevens-Johnson syndrome (SJS) because of dry ocular surface and additional amniotic membrane and stem cell

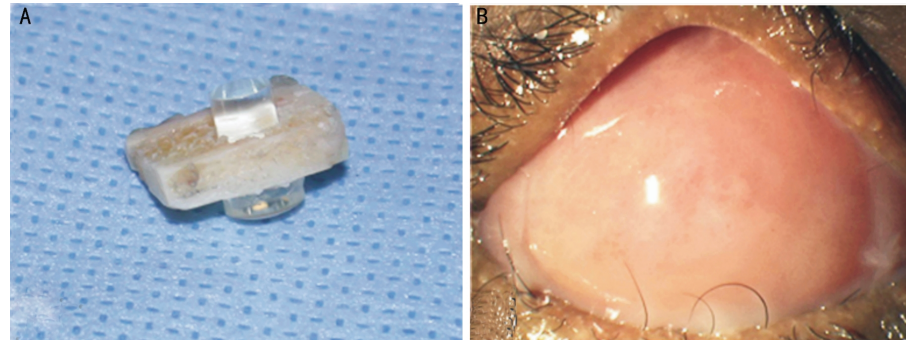
grafts may not help in such cases to provide useful vision. For such cases, osteo-odonto keratoprosthesis (OOKP) which was first described by Strampelli<sup>[1]</sup> and later on modified by Falcinelli *et al*<sup>[2]</sup> and Hull *et al*<sup>[3]</sup> is a useful method for visual rehabilitation because of its higher retention rate and better long-term visual outcome. This is a complex artificial corneal surgical procedure that is performed in two stages for visual rehabilitation in cases of corneal blindness with dry ocular surface in which corneal transplantation with amniotic membrane and limbal grafts have failed. In stage one, an autologous canine tooth is removed, modified to receive an optical polymethyl methacrylate cylinder; and implanted in a submuscular pocket under the lower eyelid for 2-4 months. The ocular surface is denuded and replaced with a full thickness buccal mucosa. In stage two, the tooth cylinder complex (osteo-odonto lamina) is retrieved and surrounding excess soft tissue is removed; and then implanted into the cornea after reflection of buccal mucosal flap, corneal trephination, total iridodialysis, cryoextraction of the lens and anterior vitrectomy. A window is made in the buccal mucosa corresponding to the optical cylinder, through which the patient recovers the vision<sup>[4]</sup>. In this report, we describe a patient with bilateral dry eyes and end-stage corneal blindness secondary to SJS in whom excellent visual recovery was achieved following OOKP surgery in the right eye.

## CASE REPORT

A 35-year-old Indian woman, a known case of SJS since 1985 secondary to ampicillin, presented with bilateral dry eyes and corneal blindness. One year after SJS affliction, she underwent penetrating keratoplasty in the more adversely affected right eye in 1986 in our hospital. However, there was no improvement of vision in the right eye due to graft failure. She was using artificial tear eye drops 4 times daily in both eyes. She was able to do daily routine work with the poor vision in the left eye. Because of visual disability, she underwent cataract surgery with intraocular lens implant in the left eye in 1995 in Chennai, India. Postoperatively, the vision in the left eye was good for many years. She was referred on February 6, 2004 to our eye clinic by a private ophthalmologist for non-healing corneal ulcer in the left eye. Right eye: vision was hand movement with good projection of light in all the quadrants. Failed corneal graft with total



**Figure 1 Ocular findings** A: Right eye showing vascularized total corneal opacity with a failed corneal graft; B: Left eye showing vascularized total corneal opacity and lateral tarsorrhphy



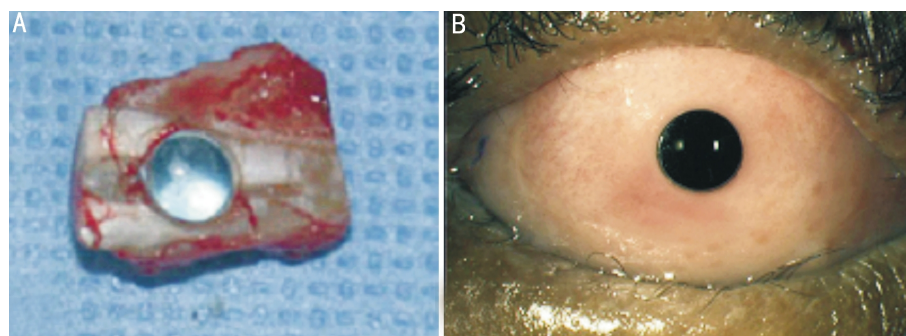
**Figure 2 Stage one operation** A: Optical cylinder fitted in the autologous canine tooth before its submuscular implantation under the lower eyelid; B: Buccal mucosa ocular surface of right eye at the end of stage one operation

vascularised corneal opacity with no details visible behind was noted. Intraocular pressure was normal. Left eye: vision was hand movement with good projection of light in all the quadrants. Lateral tarsorrhphy was present. Circum corneal congestion with central corneal ulcer (4mm), hypopyon and vascularization in the upper part of limbus were noted. There was thinning of central cornea with impending descemetocoele formation. Posterior chamber intraocular lens was stable. Patient was admitted into eye ward and treated with gentamycin fortified eye drops, atropine eye drops, timolol eye drops and carboxy methylcellulose tears eye drops. A bandage soft contact lens was also applied. The culture from the corneal scrapings showed *Mycobacterium abscessus* organism, sensitive to amikacin and cefoxitim. Amikacin eye drops 3% every hourly and systemic amikacin (300mg I.V. every 8 hours for 1 week) were added to the above treatment. As the ulcer started healing, the frequency of amikacin drops was tapered off slowly. The corneal ulcer healed completely, after 12 weeks of admission, resulting in vascularized corneal opacity with no improvement in vision. She was referred to Singapore National Eye Centre (SNEC) for advice regarding the possibility of keratoprosthesis surgery in right eye. Patient was examined in the corneal service unit of SNEC on August 5, 2004. Right eye: vision and anterior segment findings were same as before (Figure 1A). The intraocular pressure was 18mmHg. and ultrasound B-scan was normal. Left eye: vision and anterior segment findings were the same as before (Figure 1B). The intraocular pressure (IOP) was 13mmHg and ultrasound B-scan was normal.

After detailed evaluation of the patient, OOKP was advised in the right eye. Detailed examination of eye included slit-lamp biomicroscopy evaluation of ocular surface, tear film, fornicial status; corneal and anterior chamber status; ultrasound biomicroscopy, A- and B-scan ultrasonography, electrophysiological assessment of optic nerve and retinal function. Oral examination included examination of the buccal mucosa for preexisting scarring, general dental and periodontal status, and identification of the canine and premolar teeth with the aid of panoramic or peripheral radiographs.

The patient was explained about the multistage operation and informed consent was taken. The OOKP surgery was done in two stages: stage one operation on October 1, 2004- an autologous canine tooth was removed, modified to receive an optical polymethyl methacrylate cylinder, 4.0mm anterior diameter and 5.24mm posterior diameter (Figure 2A); and implanted in a submuscular pocket under the lower eyelid for 2-4 months. The ocular surface was denuded and replaced with a full thickness buccal mucosa (Figure 2B).

After 3 months, stage two operation on January 6, 2005- the tooth cylinder complex (osteo-odonto lamina) was retrieved and surrounding excess soft tissue was removed (Figure 3A); and then implanted into the cornea after reflection of buccal mucosal flap, corneal trephination, total iridodialysis, cryoextraction of the lens and anterior vitrectomy. A window was made in the buccal mucosa corresponding to the optical cylinder, through which the patient perceives the vision (Figure 3B).



**Figure 3 Stage two operation** A: Tooth cylinder complex implant recovered from the cheek during stage two operation; B: Final appearance of right eye after stage two operation

**Table 1 Frequency of SJS cases as indication for OOKP in the published literature**

Author	Year	Country	Total number of cases	Number of SJS cases	%
Marchi <i>et al</i> [10]	1994	Italy	85	10	11.8
Falcinelli <i>et al</i> [2]	2005	Italy	181	4	2.2
Hille <i>et al</i> [6]	2006	Germany	25	1	25.0
Tan <i>et al</i> [4]	2008	Singapore	16	7	44.4
Michael <i>et al</i> [7]	2008	Spain	145	22	15.1
Liu <i>et al</i> [8]	2008	UK	36	16	44.4
Fukuda <i>et al</i> [9]	2008	Japan	4	3	75.0
Iyer <i>et al</i> [5]	2010	India	50	24	48.0

The details of stage one operation procedure, stage two operation procedures, postoperative management and follow up were described by Tan *et al* [4]. On day 1 post operatively, the globe was slightly firm on digital palpation and vision was good. She was maintained on tab. Acetazolamide and oral potassium. She was followed up regularly in SNEC and in-between the visits in our hospital also. During 6 weeks visit, her vision was improved to 6/9 unaided. Fundus examination showed cup-disc ratio 0.7; visual field testing revealed superior nasal step in Humphry and Goldmann perimetry. Therefore, oral glycerol was added to diamox. Five months after the second stage operation her vision was noted 6/6 unaided. Patient was extremely happy about visual recovery in the right eye. Buccal mucosa was healthy. Optical cylinder was well centred. Pilocarpine in gelform was added to the glaucoma treatment. She was then followed up 6 monthly.

On review one year later, vision was maintained 6/6 unaided in right eye; eyeball was still slightly firm, but acceptable; buccal mucosa was healthy; CD ratio was 0.7 and visual field unchanged. Oral glycerol was stopped; Xalacom and Alphagan eye drops, tetracycline eye ointment were added. Then, she was followed up once in a year. During the follow-up visits, the glaucoma medication was changed to Gutt Lumigan, Gutt Azopt, Gutt Pilocarpine 2% and Tab Diamox 250mg bd. She was advised to consult our eye clinic immediately if there was any problem in the right eye.

The last follow-up was on April 20, 2010 (5 years after the operation). She was fully stable. She is still on the same

antiglaucoma medicines. Vision in the right eye was 6/9 unaided, but improved to 6/6 with +0.25 DS. Buccal mucosa was healthy. Optical cylinder was centered well. Her intraocular pressure by palpation appeared normal (in the high teens) with cup-disc ratio of 0.8; and there was no deterioration of the visual field. Her left eye vision remained hand movement only with total vascularized corneal opacity.

#### DISCUSSION

OOKP is an artificial corneal surgical procedure wherein the optical cylinder is fitted into the patients' own tooth and implanted into the eye for improvement of vision in hopeless bilateral corneal blindness cases with good functioning retina and optic nerve. The OOKP surgery can offer anatomically stable corneal prosthesis in the long term, as well as aid in visual rehabilitation in cases with bilateral ocular surface disease and corneal blindness but still having a functioning retina and optic nerve. The common conditions that lead to end-stage corneal blindness include SJS, severe chemical burns, ocular cicatricial pemphigoid, end stage trachoma, multiple failed grafts, graft-versus host disease, Sjogren syndrome, Lyelle syndrome, bullous keratopathy secondary to glaucoma, xerosis, corneal opacity secondary to interstitial keratitis and bullous keratopathy, burns from flames, molten metals and explosions, and multiple graft failures [1-10]. The contraindications for OOKP include lack of light perception vision, phthisis bulbi, end-stage glaucoma with advanced optic nerve disease, advanced macular disease or irreversible retinal pathology, and patients who have satisfactory vision for their daily activities [11].

Corneal blindness secondary to SJS is one of the common indications (2.2% to 75.0%) in the published reports on OOKP (Table 1). It constituted 44.4% in Singapore study and little more (48.0%) in Indian study.

Various complications reported following OOKP surgery include mucous membrane ulceration, mucous membrane overgrowth onto the optical cylinder, odontal lamina exposure, lamina resorption, tilting of optic cylinder, extrusion of optic cylinder, de novo post operative glaucoma, hypotony, sterile vitritis, endophthalmitis, retinal detachment, vitreous haemorrhage, choroidal detachment, expulsive haemorrhage, retroprosthetic membrane, shortening of fornix [1-10].

The OOKP has a synthetic optic (polymethyl methacrylate) with a biological haptic (patient's own tooth). It can withstand a very hostile ocular surface environment like dry eyes and that is why the OOKP is considered the best device (out of all available currently) capable of offering long-term visual rehabilitation in patients with severe tear deficiency, especially suitable for cases of SJS and ocular cicatricial pemphigoid. The patient should understand that they may require multiple procedures with subsequent risk of loss of sight [12].

The disadvantages of OOKP surgery include the irreversible destruction of residual ocular surface epithelium, iridodialysis, need for a comprehensive team of ophthalmic specialists (cornea, glaucoma, retina, oculoplasty), oral surgeon, radiologist limiting this form of surgery to major institutions with multidisciplinary specialization. Measurement of IOP, management of glaucoma, lifelong surveillance to detect possible osteodontal lamina erosion are other challenges in this surgery [4].

Glaucoma is the most frequent complication of OOKP surgery [10,13]. It is difficult to establish whether glaucoma is caused by surgery per se or related to preexisting abnormalities of the anterior segment involving trabecular meshwork and angle. In patients with OOKP, the diagnosis and monitoring glaucoma is done by ophthalmoscopic study of the optic disc and visual field in which it is impossible to measure IOP accurately.

Our patient fell into the category of corneal blindness with ocular surface problem (dry eye), not amenable to penetrating keratoplasty in the right eye and confirmed to the recommendations of Rome-Vienna Protocol [4] for OOKP surgery. Following surgery, there was excellent visual recover from hand movements to 6/6 with out much complications. The de novo glaucoma seen after surgery was well controlled with antiglaucoma medications, indicated by the normal IOP (measured by digital tonometry), stable optic cup disc ratio and visual field over a period of 5 years.

Moreover, our patients also suffered from corneal ulcer in the left eye caused by *Mycobacterium abscessus*, which healed after prolonged amikacin therapy. This is a rare

organism isolated from corneal scrapings in clinical practice. Before 1992, *M.abscessus* was designated as *M.chelonae* species *abscessus* Older literature, from the 1950s, described rapidly growing mycobacteria as *M.fortuitum* complex. Speciating isolates is critical for choosing therapy because antibiotic sensitivity varies from species to species [15]. Treatment of infections caused by this pathogen requires prolonged multidrug therapy. *M.absecessus*, resistant to conventional antituberculous agents, is usually sensitive to amikacin, azithromycin, clarithromycin and cefoxitin [16].

In conclusion, OOKP procedure offers a good visual rehabilitation with long-term survival of the prosthesis in patients with SJS and corneal blindness.

#### REFERENCES

- 1 Strampelli B. Keratoprosthesis with osteodontal tissue. *Am J Ophthalmol* 1963; 89:1029-1039
- 2 Falcinelli G, Falsini B, Taloni M, Colliardo P, Falcinelli G. Modified osteo-odonto keratoprosthesis for treatment of corneal blindness: long-term anatomical and functional outcomes in 181 cases. *Arch Ophthalmol* 2005;123(10): 1319-1329
- 3 Hull CC, Liu CS, Sciscio A, Eleftheriadis H, Herold J. Optical cylinder designs to increase the field of vision in the osteo-odonto-keratoprosthesis. *Graefes Arch Clin Exp Ophthalmol* 2000; 238(12):1002-1008
- 4 Tan DTH, Tay ABG, Theng JTS, Lye KW, Parthasarathy A, Por YM, Chan LL, Liu C. Keratoprosthesis surgery for end-stage corneal blindness in asian eyes. *Ophthalmology* 2008;115(3):503-510
- 5 Iyer G, Pillai VS, Srinivasan B, Falcinelli G, Padmanabhan P, Guruswami S, falcinelli G. Modified osteo-odonto keratoprosthesis-the Indian experience: results of first 50 cases. *Cornea* 2010; 29(7):771-776
- 6 Hille K, Hille A, Ruprecht KW. Medium term results in keratoprotheses with biocompatible and biological haptic. *Græf's Arch Clin Exp Ophthalmol* 2006;244 (6): 696-704
- 7 Michael R, Charoenrook V, de la Paz MF, Hitzl W, Temprano J, Barraquer RI. Long-term functional and anatomical results of osteo-and osteodontokeratoprosthesis. *Græf's Arch Clin Exp Ophthalmol* 2008;246(8):1133-1137
- 8 Liu C, Okera S, Tandon R, Heraold J, Hull C, Thorp S. Visual rehabilitation in end-stage inflammatory ocular surface disease with the oste-odonto-keratoprosthesis: results from the UK. *Br J Ophthalmol* 2008;92(9):1211-1217
- 9 Fukuda M, Hamada S, Liu C, Shimomura Y. Osteo-odonto-keratoprosthesis in Japan. *Cornea* 2008;27(Suppl.1): S56-S61
- 10 Marchi V, Ricci r, Pecorella I, Giardi A, Tondo UD. Osteo-odontoo keratoprosthesis-description of surgical technique with results in 85 patients. *Cornea* 1994;13(2): 125-130
- 11 Liu C, Paul B, Tandon R, Lee E, Fong K, Mavrikakis I, Herold J, Thorp S, Brittain P, Francis I, Ferrett C, Hull C, Lloyd A, Green D, Franklin V, Tighe B, Fukuda M, Hamada S. The osteo-odonto-keratoprosthesis (OOKP). *Semin Ophthalmol* 2005;20(2):113-128
- 12 Goma A, Comyn O, Liu C. Keratoprosthesis in clinical practice- a review. *Clin Exp Ophthalmol* 2010;38(2):211-224
- 13 Falcinelli GC, Falsini b, Taloni M, Piccardi M, Falcinelli G. Detection of glaucomatous damage in patients with osteo-odonto-keratoprosthesis. *Br J Ophthalmol* 1995;79(2):129-134
- 14 Hille K, Grabner G, Liu C, Colliardo P, Falcinelli G, Taloni M, Falcinelli G. Standards for modified osteo-odontokeratoprosthesis (OOKP) surgery according to Strampelli and falcinelli: the Rome-Vienna Protocol. *Cornea* 2005;24(8):895-908
- 15 Wallace RJ. Recent changes in taxonomy and disease manifestations of rapidly growing mycobacteria. *Eur J Clin Microbiol Infect Dis* 1994;13(11):953-960
- 16 Mushatt DM, witzig RS. Successful treatment of *Mycobacterium abscessus* infections with multidrug regimens containing clarithromycin. *Clin infect Dis* 1995;20(5):1441-1442