

# Arg124Cys mutation of the TGFBI gene in a Chinese pedigree of Reis-Bücklers corneal dystrophy

Qiao-Na Yang<sup>1</sup>, Yong-Wang Zhao<sup>2</sup>, Li-Heng Guo<sup>1</sup>, Nai-Hong Yan<sup>1</sup>, Xu-Yang Liu<sup>1</sup>,  
Su-Ping Cai<sup>1</sup>

**Foundation items:** Supported by grants from the National Natural Science Foundation of China (No. NNSF 81000370)

<sup>1</sup>Ophthalmic Laboratories & Department of Ophthalmology, West China Hospital, Sichuan University, Chengdu 610041, Sichuan Province, China

<sup>2</sup>Department of Ophthalmology, the Affiliated Hospital of Vocational Technology Institute of Yongzhou, Hunan Province, China

The first two authors contributed equally to this paper.

**Correspondence to:** Su-Ping Cai. Ophthalmic Laboratories and Department of Ophthalmology, West China Hospital, Sichuan University, Chengdu 610041, Sichuan Province, China. supingcai@126.com

Received: 2011-04-12 Accepted: 2011-05-04

## Abstract

• **AIM:** To analyze mutations in transforming growth factor beta-induced (TGFBI) gene in a Chinese pedigree with Reis-Bücklers corneal dystrophy (RBCD, also known as GCD3).

• **METHODS:** In a five-generation Chinese family, eight members were identified with RBCD and the rest were unaffected. All members of the family underwent complete ophthalmologic examinations. Exons of TGFBI were amplified by polymerase chain reaction, sequenced, and compared with a reference database.

• **RESULTS:** A single heterozygous C>T (R124C) point mutation was found in exon 4 of TGFBI in all the affected members of the pedigree, but not in the unaffected members.

• **CONCLUSION:** R124C which was a known mutation for lattice corneal dystrophy type I, segregated with the RBCD in this pedigree. This elucidated the correlation between genotype and phenotype in a Chinese family of RBCD.

• **KEYWORDS:** Reis-Bücklers corneal dystrophy; molecular genetics; mutation; TGFBI; R124C

DOI:10.3980/j.issn.2222-3959.2011.03.03

Yang QN, Zhao YW, Guo LH, Yan NH, Liu XY, Cai SP. Arg124Cys mutation of the TGFBI gene in a Chinese pedigree of Reis-Bücklers corneal dystrophy. *Int J Ophthalmol* 2011;4(3):235-238

## INTRODUCTION

Corneal dystrophies represent a group of inherited corneal diseases with progressive accumulation of deposits in different layers of the cornea, resulting in decreased corneal transparency and visual acuity<sup>[1]</sup>. A few genes have been identified to be responsible for corneal dystrophies, including transforming growth factor-beta-induced (TGFBI), carbohydrate sulfotransferase 6 (HST6), gelsolin (GSN), keratin 3 (KRT3), keratin 12 (KRT12), and chromosome 1, surface marker 1 (MIS1), and among those, TGFBI appeared to be most commonly associated with pathogenesis of human autosomal dominant corneal dystrophies<sup>[2]</sup>.

TGFBI (also known as keratoepithelin; MIM 601692) is an extracellular matrix protein induced by transforming growth factor-beta 1 and is highly expressed in the corneal epithelium. The human TGFBI encodes a 683-amino acid protein containing a highly conserved RGD (Arg-Gly-Asp) motif<sup>[3]</sup>, which acts as ligand recognition sequence for several integrins. It is thus associated with cell-collagen interactions with a role in the regulation of cell-adhesion. To date, TGFBI mutations have been reported to be involved with several subtypes of corneal dystrophies, including lattice, granular, Avellino, Reis-Bücklers, Thiel-Behnke corneal dystrophy and some others<sup>[2]</sup>. Molecular genetic studies of corneal dystrophies have demonstrated a clear genotype-phenotype correlation, as specific TGFBI gene mutation will cause defined forms of CD<sup>[2]</sup>. For example, R124C was reported as the most frequent mutation associated with the typical lattice corneal dystrophy<sup>[4-9]</sup>, while R124L was previously identified in patients with typical RBCD<sup>[10-12]</sup>, including Chinese RBCD pedigrees.

In this study, molecular genetic analysis was conducted in a Chinese family with RBCD, however R124C instead of R124L was identified to be the causative mutation. This finding expands the genotype-phenotype spectrum of RBCD and may facilitate the diagnosis of this disease in the future.

## MATERIALS AND METHODS

**Patients** The study was approved by West China Hospital, Sichuan University Institute Review Board, Chengdu,

Table 1 Primers used in Polymerase Chain Reaction for amplification of TGFBI			
Exon		Sequence (5'→3')	Annealing temperature(°C)
1	Forward:	GCTTGCCCGTCGGTTCGCTA	62
	Reverse:	TCCGAGCCCCGACTACCTGA	
2	Forward:	AGGCAAACACGATGGGAGTCA	60
	Reverse:	TAGCACGCAGGTCCCAGACA	
3	Forward:	CCAGATGACCTGTGAGGAACAGTGA	60
	Reverse:	CCTTTTATGTGGGTACTCCTCTCT	
4	Forward:	TCCTCGTCCTCTCCACCTGT	58
	Reverse:	CTCCCATTTCATCAGCCCCAC	
5 and 6	Forward:	CCTGGGCTCACGAGGGCTGAGAACAT	64
	Reverse:	GCCCCCTTTGGGAGGCAATGTGTCCC	
7	Forward:	GTGAGCTTGGGTTTGGCTTC	63
	Reverse:	ACCTCATGGCAGGTGGTATG	
8	Forward:	TGAGGTTATCGTGGAGTG	53
	Reverse:	CACATCAGTCTGGTCACA	
9	Forward:	ACTCACGAGATGACATTCCT	60
	Reverse:	TCCAGGGACAATCTAACAGG	
10	Forward:	TAGAAGATACCAGATGTTAAGG	56
	Reverse:	TGTCAGCAACCAGTTCTCAT	
11	Forward:	CCTGCTACATGCTCTGAACAA	58
	Reverse:	GAATCCCCAAGGTAGAAGAAAAG	
12	Forward:	GACTCTACTATCCTCAGTGGTG	58
	Reverse:	ATGTGCCAACTGTTTGCTGCT	
13	Forward:	CATTAGACAGATTGTGGGTCA	60
	Reverse:	GGGCTGCAACTTGAAGGTT	
14	Forward:	GCGACAAGATTGAAACTCCAT	58
	Reverse:	CTCTCCACCAACTGCCACAT	
15	Forward:	CCCTCAGTCACGGTTGTT	58
	Reverse:	GGAGTTGCCTTGGTTCTT	
16	Forward:	CTTGACAACTTATGTCTGC	58
	Reverse:	TGCACCATGATGTTCTTATC	
17	Forward:	AGTGAAGTTTCACAAACCAC	58
	Reverse:	CCACATTTGGGATAGGTC	

Sichuan Province, P.R. China. Six patients and four unaffected relatives from a five-generation family of Hunan Province, China were recruited to this study. Informed consent was obtained from all participants according to the tenets of Declaration of Helsinki.

### Methods

**Ophthalmologic Examination** All patients underwent ophthalmological examinations, including Snellen bestcorrected visual acuity and slit-lamp examination. Detailed clinical history such as the age of onset, initial signs, symptoms, progression of disease, and ocular therapeutic procedures was documented.

**Genetic Analysis** Peripheral blood was collected from each individual participated in this study. Genomic DNA was extracted from leukocytes using QIAamp DNA Blood Mini Kit (QIAGEN, Hilden, Germany) according to the manufacturer's protocol. DNA integrity was evaluated by 1% agarose gel electrophoresis.

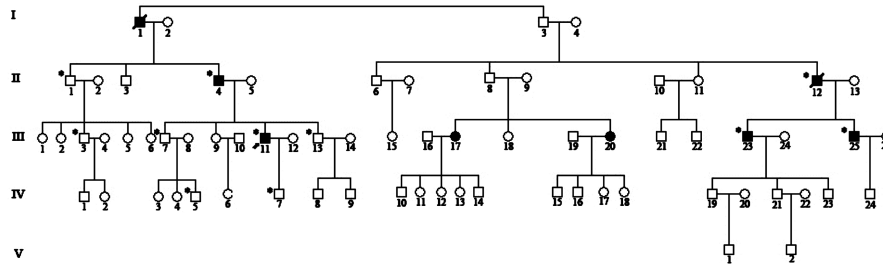
Intronic primers flanking the exons were designed based on gene sequence of TGFBI (GenBank NG\_012646.1) (primer sequences are listed in Table 1). Exons of the TGFBI gene were amplified from genomic DNA of each participant by polymerase chain reaction (PCR) using a MyCycler thermocycler (Bio-Rad, Hercules, CA). Briefly, PCR was performed using 30µL reaction mixtures, each containing 30-40ng genomic DNA, 1.0 pmol of each of the forward and

reverse primers, and 15µL 2 ×Taq Master Mix (SinoBio Biltech Co. Ltd, Shanghai, China). Cycling conditions included an initial denaturation at 94°C for 5 minutes, followed by 30 cycles of denaturation at 94 °C for 30 seconds, annealing at 52-62 °C for 30 seconds, extension at 72°C for 30 seconds, and a final extension at 72°C for 5 minutes. The amplified products were purified with Cycle-Pure Kit (OMEGA, Bio-Tek, USA) and sequenced on an ABI 3730XL automated DNA sequencer (Applied Biosystems, Foster City, CA). Nucleotide sequences were compared with the TGFBI sequence (GenBank NG\_012646.1).

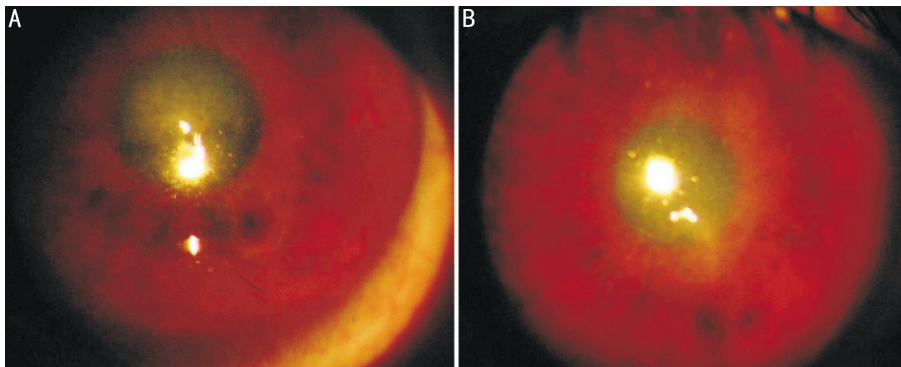
### RESULTS

**Clinical Findings** A five-generation was compiled and revealed dominant inheritance (Figure 1) .

The proband (a 47-year-old male, patient III:11) experienced recurrent photophobia, progressive vision loss and corneal erosion for more than 10 years. The best-corrected visual acuity was 0.25 J4 OD and 0.4 J4 OS. Corneal examination revealed confluent geographic opacities in the subepithelial area and Bowman's layer in the central cornea of both eyes (Figure 2). Patient III:23, a 51-year-old brother of the proband, manifested bilateral confluent geographic epithelial and stromal opacities in the central cornea. His best-corrected visual acuity was 0.4 J7 OD and 0.4 J7 OS. Patient III:25, a 47-year-old brother of the proband, presented with similar clinical symptoms, with best-corrected visual acuity



**Figure 1** Pedigrees of the Chinese family. The pedigree showed autosomal dominant inheritance of corneal dystrophies. The closed symbols represent subjects with RBCD and the open symbols represent the unaffected. Arrow indicates the probands. The asterisks indicate the individuals who had undergone molecular analysis in the study



**Figure 2** Slit-lamp photomicrographs of the proband III.11 A: Confluent geographic opacities in the central cornea of the left eye was noted in the proband; B: The same corneal opacities in the right eye

**Table 2** Clinical data and visual function (phenotype) of subjects. Visual acuity shows corrected visual acuity

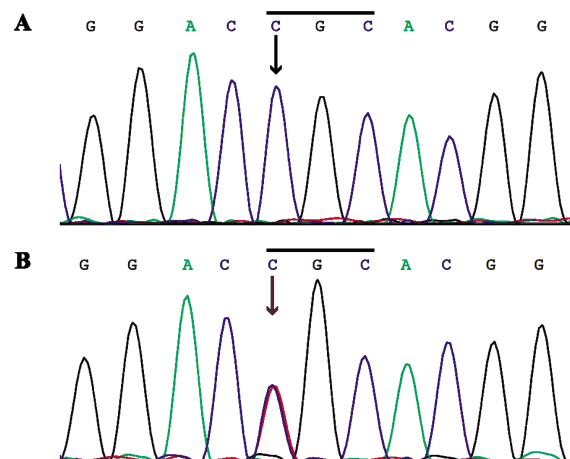
Family member	Age	Gender	Onset	Visual acuity (OD/OS)	Biomicroscopic observations
III.11	47	M	35	0.25 J4/0.4 J4	Confluent geographic opacities in the subepithelial area and Bowman's layer.
III.23	51	M	37	0.4 J7/0.4 J7	Bilateral irregular, patchy geographic epithelial and stromal opacities in the central cornea.
III.25	47	M	36	0.1 J7/0.12 J7	Irregular corneal surface and gray-white geographic opacities.

at 0.1 J7 OD and 0.1 J7 OS. Phenotypes of the patients were summarized in Table 2.

**TGFBI Mutational Analysis** A single heterozygous C>T missense mutation was found in exon 4 of TGFBI in all affected members of this pedigree (Figure 3), which resulted in an amino acid substitution from arginine to cysteine at codon 124 (R124C). This R124C mutation co-segregated with the disorder within the family. The results of the sequencing analysis were confirmed by reverse sequencing.

### DISCUSSION

TGFBI is closely involved with inherited corneal dystrophies, with Arg124 and Arg555 mutations accounting for over half of all cases of corneal dystrophy patients [2]. To date, more than 30 mutations of TGFBI has been identified to be responsible for various subtypes of corneal dystrophies[13]. Among those mutations, R124 appears to be a "hot-spot" point mutation, as the R124 mutation has been detected in three types of corneal dystrophies, including Avellino corneal dystrophy (R124H), lattice corneal dystrophy type I (R124C), and RBCD (R124L). Earlier, investigators



**Figure 3** R124C mutation in TGFBI A: No mutation was identified (black arrow) in unaffected individuals; B: A heterozygous mutation consisting of a C>T transversion in exon 4 (red arrow) was observed (red arrow) in affected members of this family

reported that the R124C mutation of the TGFBI gene is responsible for lattice corneal dystrophy type I. However,

R124C instead of R124L was found to be responsible for RBCD in this pedigree. We previously reported R124C mutation in TGFBI in another Chinese pedigree of RBCD for the first time [14]. The results obtained from these pedigrees suggested that RBCD families with R124C as the pathogenic mutation are not rare cases, or at least in Chinese families. In fact, R124C mutation was also found to be responsible for TBCD in some families [15]. These studies showed that R124C mutation in the TGFBI gene may induce different types of corneal dystrophies, and therefore, expanded the heterogeneity of the clinical spectrum.

However, phenotypes are different in this family from the one in our previous report, even though they carried the identical mutation. To be specific, the onset of disease is markedly late and the severity is mild in this family. Patients in this family reported decreased visual acuity at 30s on average, while typical RBCD has an onset at childhood and usually causes significant visual impairment. It would be interesting to clarify the reasons why the different phenotypes shared the same mutation or genotype. One is that the interaction between TGFBI and other genes may contribute to gene expression. The other is that certain environmental factors could have an effect on gene expression [15].

Corneal dystrophies caused by TGFBI mutations are divided into different subtypes based on the morphological and histopathological properties of the deposits and on the patients' clinical features [16]. Due to significant genetic heterogeneity of the disease, clinical features of the patients can vary a lot from family to family, or even within family members [13]. Patients with overlapping or atypical phenotypes were also found in some patients, and it is usually difficult to classify them into any subtypes, only based on morphologic and histopathological criteria. These prompted the need for a reevaluation of the classification of corneal disorders, particularly in the light of their known underlying molecular genetic mutation. The IC3D Classification of Corneal Dystrophies, which incorporates several aspects of the conventional definitions of corneal dystrophies with new genetic, clinical and pathologic information, suggested that the corneal dystrophies with common genetic basis in TGFBI should be grouped together as TGFBI corneal dystrophies [17]. That appears to be a more accurate approach to classifying corneal dystrophies. Since the mutations at hotspot residues 124 and 555 as well as several other reported mutations of TGFBI can be easily evaluated by PCR followed by sequencing of all exons, screening for these mutations can be done rapidly and cost-effectively.

Thus, with the help of molecular genetic analysis, more reasonable or accurate clinical diagnosis can be achieved.

**Acknowledgements:** The authors thank the family members for their participation in this study.

**REFERENCES**

- 1 Klintworth GK. The molecular genetics of the corneal dystrophies—current status. *Front Biosci* 2003;8:d687–713
- 2 Kannabiran C, Klintworth GK. TGFBI gene mutations in corneal dystrophies. *Hum Mutat* 2006;27:615–625
- 3 Mannis MJ, Desouza LB, Gross RH. The stromal dystrophies in: Krachmer JH, Holland EJ, Mannis MJ, editors. *Diseases of Cornea*. St. Louis: Mosby 1997: 1043–1062
- 4 Romero P, Vogel M, Diaz JM, Romero MP, Herrera L. Anticipation in familial lattice corneal dystrophy type I with R124C mutation in the TGFBI (BIGH3) gene. *Mol Vis* 2008;14:829–835
- 5 Chakravarthi SV, Kannabiran C, Sridhar MS, Vemuganti GK. TGFBI gene mutations causing lattice and granular corneal dystrophies in Indian patients. *Invest Ophthalmol Vis Sci* 2005;46:121–151
- 6 Munier FL, Frueh BE, Othenin-Girard P, Uffer S, Cousin P, Wang MX, Héon E, Black GC, Blasi MA, Balestrazzi E, Lorenz B, Escoto R, Barraquer R, Hoeltzenbein M, Gloor B, Fossarello M, Singh AD, Arsenijevic Y, Zografos L, Schorderet DF. BIGH3 mutation spectrum in corneal dystrophies. *Invest Ophthalmol Vis Sci* 2002;43:949–549
- 7 Kim HS, Yoon SK, Cho BJ, Kim EK, Joo CK. BIGH3 gene mutations and rapid detection in Korean patients with corneal dystrophy. *Cornea* 2001;20:844–849
- 8 Fujiki K, Hotta Y, Nakayasu K, Yamaguchi T, Kato T, Uesugi Y, Ha NT, Endo S, Ishida N, Lu WN, Kanai A. Six different mutations of TGFBI (BIGH3, Keratopithelin) gene found in Japanese corneal dystrophies. *Cornea* 2000; 19: 842–845
- 9 Gupta SK, Hodge WG, Damji KF, Guernsey DL, Neumann PE. Lattice corneal dystrophy type I in a Canadian kindred is associated with the Arg124Cys mutation in the keratopithelinge. *Am J Ophthalmol* 1998;125:547–549
- 10 Mashima Y, Nakamura Y, Noda K, Konishi M, Yamada M, Kudoh J. A novel mutation at codon 124 (R124L) in the BIGH3 gene is associated with a superficial variant of granular corneal dystrophy. *Arch Ophthalmol* 1999;117:90–93
- 11 Tian X, Liu ZG, Li Q, Li B, Wang W, Xie PY, Fujiki K, Murakami A, Kanai A. Analysis of gene mutation in Chinese patients with Reis–Bücklers corneal dystrophy. *Zhonghua Yanke Zazhi* 2005;41:239–242
- 12 Yu J, Zou LH, He JC, Liu NP, Zhang W, Lu L, Sun XG, Dong DS, Wu YY, Yin XT. Analysis of mutation of BIGH3 gene in Chinese patients with corneal dystrophies. *Zhonghua Yanke Zazhi* 2003;39:582–658
- 13 Liu Z, Wang YQ, Gong QH, Xie LX. An R124C mutation in TGFBI caused lattice corneal dystrophy type I with a variable phenotype in three Chinese families. *Mol Vis* 2008;14:1234–1239
- 14 Ma K, Liu G, Yang Y, Yu M, Sui R, Yu W, Chen X, Deng Y, Yan N, Cao G, Liu X. TGFBI gene mutation analysis in a Chinese pedigree of Reis–Bücklers corneal dystrophy. *Mol Vis* 2010;16:556–561
- 15 Chang L, Zhiqun W, Shijing D, Chen Z, Qingfeng L, Li L, Xuguang S. Arg124Cys mutation of the TGFBI gene in 2 Chinese families with Thiel–Behnke corneal dystrophy. *Arch Ophthalmol* 2009;127:641–644
- 16 Poulaki V, Colby K. Genetics of anterior and stromal corneal dystrophies. *Semin Ophthalmol* 2008;23:9–17
- 17 Weiss JS, Möller HU, Lisch W, Kinoshita S, Aldave AJ, Belin MW, Kivelä T, Busin M, Munier FL, Seitz B, Sutphin J, Bredrup C, Mannis MJ, Rapuano CJ, Van Rij G, Kim EK, Klintworth GK. The IC3D classification of the corneal dystrophies. *Cornea* 2008;27:S1–83