

Non–arteritic anterior ischaemic optic neuropathy in Malaysia: a 5 years review

Abdulrahman Bawazir, Reza Gharebaghi, Adil Hussein, Wan Hazabbah Wan Hitam

Department of Ophthalmology, School of Medical Sciences, Universiti Sains Malaysia, Health Campus, 16150 Kubang Kerian, Kelantan, Malaysia

Correspondence to: Wan Hazabbah Wan Hitam. Department of Ophthalmology, School of Medical Sciences, Universiti Sains Malaysia, Health Campus, 16150 Kubang Kerian, Kelantan, Malaysia. hazabbah@kb.usm.my

Received:2010-12-27 Accepted:2011-03-12

Abstract

- **AIM:** To evaluate the clinical presentations and visual outcomes of non-arteritic anterior ischaemic optic neuropathy (NAION).
- **METHODS:** A retrospective study was conducted involving 18 consecutive patients (20 eyes) with NAION attending Hospital Universiti Sains Malaysia from January 2005 until December 2009.
- **RESULTS:** Most patients were Malay (94.4%), and followed by Chinese (5.6 %). The female-to-male ratio was 3.5:1. The age of patients ranged from 36 to 85 years (mean, 57.1 years). The main risk factors in systemic diseases were hypertension (55.5%), diabetes mellitus (44.4%), and ischaemic heart disease (11.1%). Most patients (77.8%) presented with acute loss of vision while gradual onset was in 22.3% of cases. Majority had visual acuity worse than 1/60 (80%). The most common fundoscopic findings were peripapillary splinter haemorrhage (90%), sectorial swollen optic disc (60%) and hyperemic disc (60%). During follow up, 20% of the patients showed stabilization in visual acuity, and 80% showed worsening of vision.
- **CONCLUSION:** Majority of patients with NAION presented with acute poor vision involving middle-aged and elderly individuals. Hypertension and diabetes mellitus were among the main risk factors involved. NAION can lead to permanent visual loss despite treatment.
- **KEYWORDS:** non-arteritic anterior ischaemic optic neuropathy; hypertension; diabetes

DOI:10.3980/j.issn.2222-3959.2011.03.12

Bawazir A, Gharebaghi R, Hussein A, Wan Hitam WH. Non–arteritic anterior ischaemic optic neuropathy in Malaysia: a 5 years review. *Int J Ophthalmol* 2011;4(3):272–274

INTRODUCTION

Non-arteritic anterior ischaemic optic neuropathy (NAION) is a rare widespread visually disabling disorder in the middle aged and elderly population [1]. NAION is presumed to result from circulatory insufficiency within the optic nerve head, but the specific mechanism of the vasculopathy remains unproven [2]. The annual incidence of NAION has been estimated at 2.3 to 10.2 per 100 000 for persons 50 years and older [3]. Our aim was to determine the clinical presentations and assess visual outcome in patients presented with NAION.

MATERIALS AND METHODS

Subjects A retrospective study was conducted involving 18 consecutive patients with NAION attending Hospital Universiti Sains Malaysia, an academic tertiary care referral centre, from January 2005 till December 2009.

Methods The patients' particulars were obtained using NAION database and the medical records. All patients were evaluated in a standard fashion and underwent a systematic comprehensive neuro-ophthalmic history and examination, including visual acuity, checking for presentation of afferent pupillary defect, dilated fundoscopic examination with Slit Lamp biomicroscopy, basic blood investigation and colour fundus photographs. The exclusion criteria included any evidence suggestive of temporal arteritis such as history of scalp tenderness and patients with a history of multiple sclerosis with or without optic neuritis, collagen vascular disease, or any other systemic inflammatory disease. Patients also were excluded if they had clinical features that suggested disorders other than NAION, such as a significantly elevated sedimentation rate or elevated C-reactive protein level. A history of inflammatory or infectious diseases was also eliminated by detailed history-taking or relative systemic and laboratory examination. If other central nervous system lesions were suspected, imaging study was arranged. Follow up were performed from 6 months to 5 years. Patients who had typical symptoms and signs of NAION including acute loss of visual acuity, swelling of optic disc, blurring of disc margins with or without haemorrhage and field defect on computerised perimetry were selected for the study.

RESULTS

Eighteen patients (20 eyes) were included in the study with female-to-male ratio of 14: 4. Eighteen (94.4%) patients were Malay followed by Chinese (5.6 %). The ages ranged from 36 to 85 (mean, 57.1) years. The main risk factors in systemic diseases were hypertension (55.5%), diabetes mellitus (44.4%), and ischaemic heart disease (11.1%). Moreover, four patients (22.2%) had positive history of smoking. The visual acuity ranged between 6/30 to perception of light; majority of subjects were with vision of worse than 1/60 (80%, Figure 1). Most patients (77.8%) presented with acute loss of vision. Relative afferent pupillary defect (RAPD) was positive in 15 (75%) eyes while in the rest it was negative. The most common fundoscopic findings were hyperemic optic disc (60%), peripapillary splinter haemorrhage (90%) and sectorial disc pallor (60%). The visual outcome following treatment (at the last follow up) ranged between stabilization and deterioration (Figure 2); 14 patients (80%) had deterioration and 4 patients (20%) had stabilisation of vision despite treatment. Results showed no improvement in terms of visual acuity after treatment.

DISCUSSION

The pathological process in NAION is loss of perfusion affecting the ciliary circulation to the optic nerve head, causing axonal swelling leading to capillary dilatation and fluid leakage. When the axons die some weeks later, pallor becomes evident leading to optic atrophy^[4]. NAION typically occurs in white races after the age of 50 years, with most series reporting an average age between 60 and 70 years^[5], but cases in older or younger patients were documented^[6]. This is the first ever study performed in Malaysia, mostly Malay in race (94.4%), with the ages ranged from 36 to 85 years (mean of 57.1 years). Our study confirmed that NAION in the young is not uncommon and represents 33.3% of patients younger than 50 years. Females were more affected compare to males with the ratio of 3.5:1 which is not similar to the most of previous studies. It is interesting to quote that the incidence rate of NAION among men and women were almost equal in the previous studies^[7,8].

NAION has been reported to be associated with many conditions that may predispose to decreased optic nerve head perfusion. Examples of risk factors are role of vasculopathic diseases, such as diabetes, hyperlipidaemia, hypertension, hyperhomocysteinaemia, and prothrombotic diseases^[2]. Fifty-five percent of our patients had systemic hypertension, compared with 34% to 47% in other studies^[9,10] and 44% of our patients had diabetes mellitus, compared with 10% to 24% in other studies^[9,10]. However, our results were quite similar compared with the similar study in

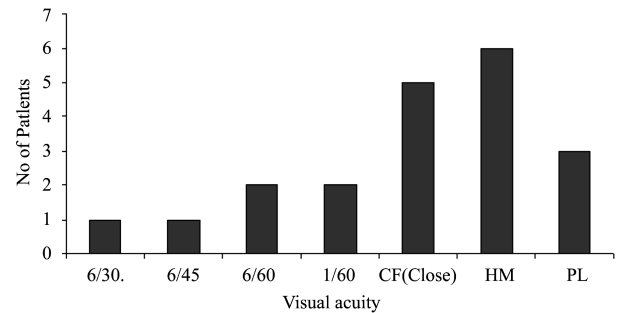


Figure 1 Visual acuity at presentation of NAION tested on Snellen visual acuity chart (CF: Counting finger; HM: Hand movement; PL: Perception of light)

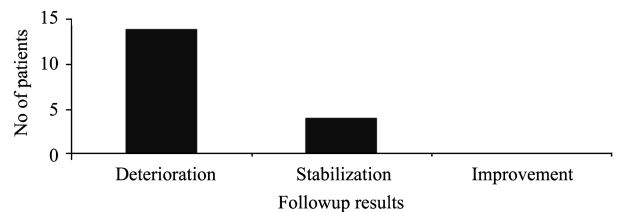


Figure 2 Progression of vision in NAION patients

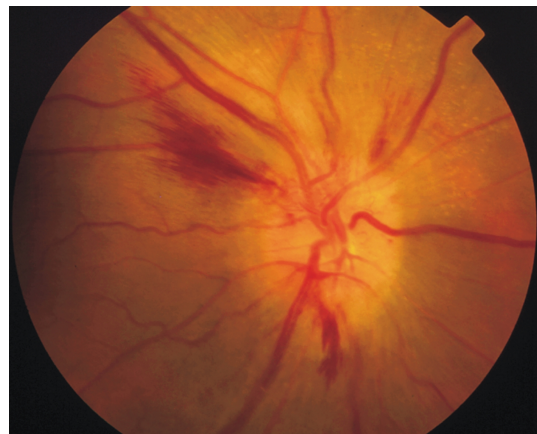


Figure 3 Photograph shows features of NAION with splinter haemorrhages in the right eye

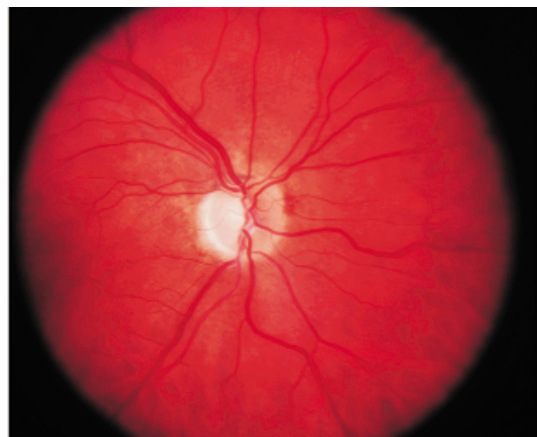

Figure 4 Photograph shows a pale optic disc (optic atrophy) following NAION

Taiwan in the Asian population^[11]. In this study, initial visual acuities in all affected eyes were poor ranging from 6/30 to light perception. At initial presentation, around 80% of the

patients had a visual acuity of 1/60 or worse and 75% had a positive RAPD. However, Beri et al ^[7] reported better visual acuity at initial presentation 6/12 or better. Studies showed in most cases of NAION, vision worsens progressively over 2 weeks and then remains stable over time ^[12]. In a study reported by Atkins et al ^[12], more than 50% of patients were left with visual acuity worse than 6/60. During follow-up 20% of patients in our study showed little and no improvement of final visual acuity and 80% had worsening of vision.

Several limitations of the present study should be addressed, most of which relate to its retrospective, hospital based and selection bias. Because of the low incidence of NAION, an adequately controlled prospective study would be difficult but worthy of further workup especially in measuring ocular parameters and visual field changes in a rare disease like NAION.

In summary, NAION may commonly affect middle-aged and elderly population in our area. Most of the patients presented with acute loss of vision. NAION was associated with systemic problem mainly hypertension and diabetes mellitus and may lead to permanent visual loss despite treatment.

REFERENCES

- 1 Jonas JB. Optic disc morphology and NAION. *Br J Ophthalmol* 2009;93(6):703
- 2 Arnold AC. Pathogenesis of nonarteritic anterior ischemic optic neuropathy. *J Neuroophthalmol* 2003;23(2):157–163
- 3 Hattenhauer MG, Leavitt JA, Hodge DO, Grill R, Gray DT. Incidence of nonarteritic anterior ischemic optic neuropathy. *Am J Ophthalmol* 1997;123(1):103–107
- 4 Cullen JF, Por YM. Ischaemic optic neuropathy: the Singapore scene. *Singapore Med J* 2007;48(4):281–286
- 5 Chutorian AM, Winterkorn JM, Geffner M. Anterior ischemic optic neuropathy in children: case reports and review of the literature. *Pediatr Neurol* 2002;26(5):358–364
- 6 Repka MX, Savino PJ, Schatz NJ, Sergott RC. Clinical profile and long-term implications of anterior ischemic optic neuropathy. *Am J Ophthalmol* 1983;96(4):478–483
- 7 Beri M, Klugman MR, Kohler JA, Hayreh SS. Anterior ischemic optic neuropathy. VII. Incidence of bilaterality and various influencing factors. *Ophthalmology* 1987;94(8):1020–1028
- 8 Guyer DR, Miller NR, Auer CL, Fine SL. The risk of cerebrovascular and cardiovascular disease in patients with anterior ischemic optic neuropathy. *Arch Ophthalmol* 1985;103(8):1136–1142
- 9 Preechawat P, Bruce BB, Newman NJ, Biousse V. Anterior ischemic optic neuropathy in patients younger than 50 years. *Am J Ophthalmol* 2007;144(6):953–960
- 10 Hayreh SS, Joos KM, Podhajsky PA, Long CR. Systemic diseases associated with nonarteritic anterior ischemic optic neuropathy. *Am J Ophthalmol* 1994;118(6):766–780
- 11 Lin MC, Hsu FM, Sheu SJ. Nonarteritic ischemic optic neuropathy. *J Chin Med Assoc* 2007;70(2):61–64
- 12 Atkins EJ, Bruce BB, Newman NJ, Biousse V. Treatment of nonarteritic anterior ischemic optic neuropathy. *Surv Ophthalmol* 2010;55(1):47–63