

Trends in the indications for penetrating keratoplasty in Shandong, 2005–2010

Jun-Yi Wang^{1,2}, Li-Xin Xie^{1,2}, Xiu-Sheng Song^{1,2}, Jing Zhao²

Foundation item: Supported by National Natural Science Foundation of China (No.30630063)

¹Department of Ophthalmology, Renmin Hospital of Wuhan University, Wuhan 430060, Hubei Province, China

² State Key Laboratory Cultivation Base, Shandong Provincial Key Laboratory of Ophthalmology, Shandong Eye Institute, Shandong Academy of Medical Sciences, Qingdao 266071, Shandong Province, China

Correspondence to: Li-Xin Xie. State Key Laboratory Cultivation Base, Shandong Provincial Key Laboratory of Ophthalmology, Shandong Eye Institute, Shandong Academy of Medical Sciences, Qingdao 266071, Shandong Province, China.lixin_xie@yahoo.com

Received:2011-09-19 Accepted:2011-10-08

DOI:10.3980/j.issn.2222-3959.2011.05.07

Wang JY, Xie LX, Song XS, Zhao J. Trends in the indications for penetrating keratoplasty in Shandong, 2005–2010. *Int J Ophthalmol* 2011;4(5):492–497

INTRODUCTION

Since the first full-thickness corneal transplantation reported by Zirm^[1], penetrating keratoplasty (PKP) has become one of the most popular and successful organ transplantation techniques used worldwide. It is widely used in the treatment of various corneal diseases. The indications for PKP vary by geographic regions along with economic development and social conditions. With the spread of phacoemulsification and intraocular lens (IOL) implantation, corneal edema following cataract surgery increased abruptly, and has been the leading indication in the developed countries (e.g, US and Europe) since the 1980s^[2-6]. At the same time, the leading indications for PKP in developing countries (e.g, China and India) have remained infectious keratitis, corneal scarring *etc*^[7-10]. Accompanying the improvement in surgical techniques by pioneering corneal surgeons and availability of surgical instruments, anterior lamellar keratoplasty (ALK) and Descemet-stripping endothelial keratoplasty (DSEK) have been developed and implemented worldwide. Correspondingly, there has been a decline in the indications for PKP in recent years. The Eye Bank Association of America (EBAA) retrospectively reviewed corneal transplantations over the past 5 years, and showed that the most common indications for PKP have shifted to corneal scars/interstitial keratitis (24%) and keratoconus (21%). In this context, there is a question what PKP indication changes in China have occurred? To investigate the current indications and the indication shifts for PKP in Shandong, which is one of the largest province in North China, we reviewed the PKP procedures performed at the Shandong Eye Institute in the past 5 years and contrasted the indications for PKP with those reported in our previous study (1997-2002)^[8].

MATERIALS AND METHODS

The charts of all patients who underwent PKP at Shandong Eye Institute, China, a tertiary referral centre, during the period from June 1, 2005, to May 31, 2010 were retrospectively reviewed. The medical data were analysed with respect to age, sex and preoperative clinical diagnosis.

Abstract

- **AIM:** To identify the current indications and the trend shifts for penetrating keratoplasty (PKP) in Shandong.
- **METHODS:** The medical charts of all patients who underwent PKP at Shandong Eye Institute from June 1, 2005 to May 31, 2010 were analysed retrospectively.
- **RESULTS:** A total of 875 patients (875 eyes) received PKP in this 5-year period, accounting for 61.6% of all corneal transplantation surgeries. The leading indications for PKP were infectious keratitis (37.1%), HSK (19.1%), keratoconus (11.2%), bullous keratopathy (8.5%), regrafting (6.7%) and corneal scarring (4.8%). The percentage of PKP for keratoconus declined year by year, whereas the percentage of bullous keratopathy had a mild annual increase. Fungal infections accounted for 65.2% of the infectious keratitis cases, remaining the leading cause of corneal infection. In addition, 54.1% of bullous keratopathy cases were associated with cataract surgery. The leading initial diagnoses associated with regrafting were infectious keratitis (38.9%), HSK (18.6%) and corneal burn (16.9%). The major causes of regrafting included graft endothelial dysfunction (39.0%), graft ulcer (28.8%) and primary disease recurrence (15.3%).
- **CONCLUSION:** Infectious keratitis remained the leading indication for PKP in Shandong, and fungal infections were still the major cause of corneal infections. There was an increasing trend in the percentage of PKP cases indicated for bullous keratopathy but a decline in the same for keratoconus. Even with a decline in the overall proportion among all corneal transplantation surgeries, PKP is still the major corneal transplant choice in Shandong.

• **KEYWORDS:** penetrating keratoplasty, indication, infectious keratitis

The indications for PKP were divided into 11 diagnostic categories. Among these categories, infectious keratitis was further classified according to pathogenic species (fungus, bacteria and Acanthamoeba). Herpes simplex keratitis included cases with both active herpetic keratitis and healed herpetic scars. The aetiology of bullous keratopathy was recorded. For regrafts, an additional analysis of the cause of the previous graft failure and the original diagnosis was also performed. The alteration of the preferred surgical approach was explored primarily according to the top three indications for PKP in our centre.

RESULTS

A total of 875 PKP cases were included in the study, which accounted for 61.6% of total keratoplasties. The ages ranged from 3 months to 82 years, with a mean age of 43.5±18.6 years. There were 583 males and 292 females.

Changes of frequencies of PKP in all keratoplasties PKP procedures accounted for 61.6% of keratoplasties during the 5 years of the study period, and this frequency represents a significant decline when compared to the results of our previous study (1996-2007) [11]. Conversely, there was a remarkable increase in LKP ($\chi^2=77.997, P=0.000$, Figure 1). Infectious keratitis, HSK and keratoconus served as the leading indications for PKP, however, a great number of patients suffering from these diseases received LKP rather than PKP. PKP accounted for 56.5%, 81.1% and 48.8% of keratoplasties associated with above diseases respectively. The PKP proportions for all three diseases represent a significant decline compared with the data in our previous study [12] ($\chi^2=79.209, P=0.000; \chi^2=80.396, P=0.000; \chi^2=85.168, P=0.000$; Figure 2).

Trends in indications for PKP Infectious keratitis (325 cases, 37.1%) was the leading indication for PKP, followed by HSK (167 cases, 19.1%), keratoconus(98 cases, 11.2%), bullous keratoplasty (74 cases, 8.5%), regrafting(59 cases, 6.7%) and corneal scarring(42 cases, 4.8%, Table 1).

The percentage of PKP procedures used to treat keratoconus decreased annually during the 5 years ($F=14.918, P=0.031$). Conversely, the percentage associated with bullous keratopathy demonstrated an increasing trend over the same period ($F=14.010, P=0.033$) and has now become the third major PKP indication as of June 1, 2008 (Figure 3).

Compared with the data of previous study [8], the percentage of PKP procedures performed increased for the treatment of infectious keratitis, HSK, bullous keratoplasty and regrafting, but decreased in regards to keratoconus, corneal scarring, corneal burn and trauma.

PKP for infectious keratitis Infectious keratitis was the leading indication for PKP. Fungal infection (65.2%) was still the most common indication for PKP among corneal infections, just as in our previous study [8] ($\chi^2=0.036, P=0.849$, Table 2,3). However, the proportion of bacterial infection (13.5%) increased ($\chi^2=22.098, P=0.000$, Table 2,3). Infectious keratitis related to an unidentified pathogen

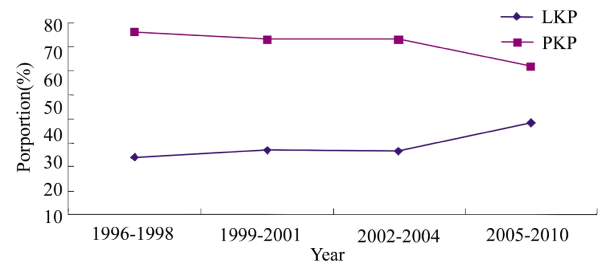


Figure 1 Proportions of penetrating keratoplasty (PKP) and lamellar keratoplasty (LKP) from 1996 to 2010. There was a significant decline in the frequency of PKP procedure, but a remarkable increase in the same of LKP compared the data in our previous study[12]

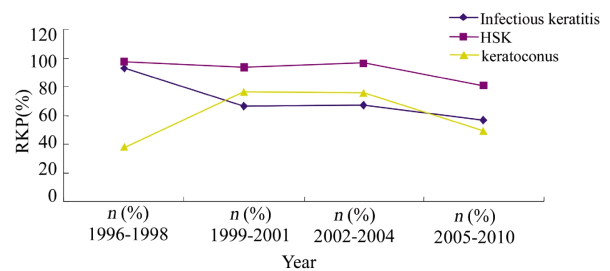


Figure 2 Percentage of PKP performed among eyes with the leading indications from 1996 to 2010 .The PKP proportions for all three diseases represent a significant decline compared with the data in our previous study[12]

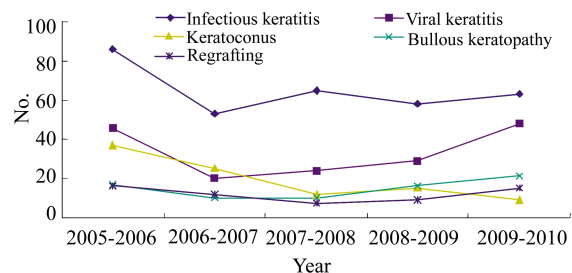


Figure 3 Clinical Indications for PKP between June 2005 and May 2010. Infectious keratitis remained the leading indication for PKP. There was an increasing trend in the percentage of PKP cases indicated for bullous keratopathy but a decline in the same for keratoconus

decreased from 28.6% to 18.8% ($\chi^2=11.194, P=0.001$, Table 2,3). There was a slight increase in the number cases of acanthamoebic keratitis because of the use of confocal microscopy and an increasing knowledge of how to identify the relevant cysts, but there was no statistical difference between our two studies due to the small sample size ($\chi^2=3.258, P=0.071$, Table 2, 3).

The aetiology of bullous keratopathy Intraocular surgery was the most common aetiology of bullous keratoplasty. In our current study, 32 cases (43.3%) were associated with cataract extraction, 9 cases (12.2%) with anti-glaucoma surgery, and 8 cases (10.8%) with combined glaucoma and cataract or anterior segment vitrectomy surgeries. Of these 40 cases, after cataract extraction, 25 cases received posterior chamber intraocular lens (PC-IOLs) implants, 7

Trends in the indications for penetrating keratoplasty

Table 1 Annual clinical indications for penetrating keratoplasty from June 2005 to May 2010 n(%)

Indication	June 2005- May 2006	June 2006- May 2007	June 2007- May 2008	June 2008- May 2009	June 2009- May 2010	Total
Infectious keratitis	86(35.7)	53(36.3)	65(48.9)	58(36.9)	63(31.8)	325(37.1)
Viral keratitis	46(19.1)	20(13.7)	24(18.0)	29(18.5)	48(24.2)	167(19.1)
Keratoconus	37(15.4)	25(17.1)	12(9.0)	15(9.6)	9(4.5)	98(11.2)
Bullous keratopathy	17 (7.1)	10(6.8)	10(7.5)	16(10.2)	21(10.6)	74(8.5)
Regrafting	16(6.6)	12(8.2)	7(5.3)	9(5.7)	15(7.6)	59(6.7)
Corneal scarring	15(6.2)	5(3.4)	1(0.8)	8(5.1)	13(6.6)	42(4.8)
Corneal dystrophy and degeneration	5(2.1)	2(1.4)	7(5.3)	10(6.4)	6(3.0)	30(3.4)
Corneal burn	7(2.9)	4(2.7)	4(3.0)	2(1.3)	8(4.0)	25(2.9)
Ocular trauma	4(1.7)	5(3.4)	1(0.8)	5(3.2)	4(2.0)	19(2.2)
Congenital keratitis	4(1.7)	3(2.1)	0(0)	2(1.3)	4(2.1)	13(1.5)
Others	4(1.7)	7(4.8)	2(1.5)	3(1.9)	7(3.5)	23(2.6)
Total	248(100)	146(100)	133(100)	154(100)	194(100)	875(100)

Table 2 Infectious keratitis for penetrating keratoplasty from June 2005 to May 2010 n(%)

Indication	June 2005- May 2006	June 2006- May 2007	June 2007- May 2008	June 2008- May 2009	June 2009- May 2010	Total
Fungal keratitis	62(72.1)	31(58.5)	43(66.2)	36(62.1)	40(43.5)	212(65.2)
Bacterial keratitis	14(16.3)	6(11.3)	9(13.8)	7(12.1)	8(12.7)	44(13.5)
Acanthamoebic keratitis	2(2.3)	2(3.8)	1(1.5)	2(3.4)	1(1.6)	8(2.5)
Infectious keratitis with unidentified pathogen	8(9.3)	14(26.4)	12(18.5)	13(22.4)	14(22.2)	61(18.8)
Total	86(100)	53(100)	65(100)	58(100)	63(100)	325(100)

Table 3 Shifts of each pathogen in infectious keratitis between 1997-2002 and 2005-2010 n(%)

Year	Fungal keratitis	Bacterial keratitis	Acanthamoebic keratitis	Infectious keratitis with uncertain pathogen	Total
1997-2002	357(65.9)	25(4.6)	5(0.9)	155(28.6)	542(100)
2005-2010	212(65.2)	44(13.5)	8(2.5)	61(18.8)	325(100)
χ^2	0.036	22.098	3.258	11.194	
<i>P</i>	0.849	0.000*	0.071	0.001*	

*means $P < 0.05$

cases received anterior chamber intraocular lens (AC-IOLs) implants, and 8 cases were aphakic.

Causes and original diagnosis of regrafting The causes for regrafting were graft endothelial dysfunction (39.0%), graft ulcer (28.8%), recurrence of the primary diseases (15.3%), graft opacities (8.5%), graft melt (8.5%). The major original diagnosis associated with regrafting remained infectious keratitis (38.9%), HSK (18.6%) and corneal burn (16.9%), but the proportion of infectious keratitis increased significantly, whereas the corneal burn percentage decreased.

DISCUSSION

Changes in the rate of PKP in whole corneal transplant procedures The predominance of PKP has been challenged by the diversification of the methods used for keratoplasty. In the past 10 years, annual PKP operations under the NHS Blood and Transplant (NHSBT) programme in the UK decreased from 1901 (1999/00) to 1473 (2008/9), and during the same period, deep anterior lamellar keratoplasty (DALK) operations increased from 91 to 327 per year, while endothelial keratoplasty (EK) operations increased from 2 to 569 per year [13]. Studies from EBAA

analysed the corneal transplantation operations over the past 5 years, and indicated that one of the most impressive changes has been the shift in eye banking procedures to accommodate EK. The volume of EK procedures has grown exponentially from only 1429 reported nationwide in 2005 to 17 468 in 2008 [11]. Another American study also indicated a persistent decline in the overall number of PKP procedure and that the average number of PKPs fell from a high of 397 in 1987 to 196 in 2005 [14]. We have analysed the PKP frequency in the whole corneal transplant procedures from 1996 to 2007 and found a persistent decline from 76.0% (1996-1998) to 61.8% (2005-2007) [12].

In the present study, we reviewed the PKP frequency in whole corneal transplant procedures, which declined significantly compared with the results of the previous study [12]. When analysing the cause of the declines, we observed that the proportion of PKP in corneal transplant procedures for the treatment of infectious keratitis and HSK decreased from 92.9% and 97.0% in 1996-1998 to 56.5% and 81.8% in 2005-2010, respectively. The PKP proportion in keratoconus treatment first increased and then declined

Table 4 Comparison of percentage of major indications for penetrating keratoplasty in different regions

Diagnosis	Faris <i>et al</i> ^[4] U.S (2001-2005)	Stephen <i>et al</i> ^[22] Canada (1996-2004)	Charalambos <i>et al</i> ^[6] Greece (1982-2006)	Claudia <i>et al</i> ^[25] Israel(1961-2000)
Bullous keratopathy	44.4%	39.3%	33.7%	14.0%
keratoconus	16.0%	12.0%	26%	28.4%
Scar	4.5%		7.7%	6.7%
regrafting	22.0%	26.9%	11.9%	13.4%
Infectious keratitis	4.0%	4.2%	8.4%	6.8%
HSK	2.7%	5.3%	4.6%	7.4%

Diagnosis	Kanavi <i>et al</i> ^[26] Iran (1994-2004)	Parul <i>et al</i> ^[7] India (1997-2003)	Zhang and Xu ^[9] China (2001-2003)	Previous study ^[8] China (1997-2002)	Present study China (2005-2010)
Bullous Keratopathy	15.3%	13.5%	15.7%	6.9%	8.5%
Keratoconus	34.5%	2.4%	5.7%	12.9%	11.2%
Scar	18.7%	38.0%	32.8%	9.6%	4.8%
Regrafting	5.28%	11.5%	10.5%	4.5%	6.7%
Infectious keratitis		28.4%	16.1%	31.9%	37.1%
HSK			19.2%	17.6%	19.1%

Bullous keratopathy including PBK, ABK, Fuch's dystrophy, Non-Fuch's dystrophy, ICE syndrome and corneal edema contributed to other diseases(PBK= pseudophakic bullous keratopathy, ABK= aphakic bullous keratopathy)

rapidly to 48.8%. However, the ratio of LKP increased inversely in the corresponding period. These trends were mainly attributed to changes in the treatment principle and procedural preference due the spread of the knowledge of the advantages of LKP. As a non-penetrating operation, LKP, especially DALK, holds advantages over PKP such as maintenance of globe integrity, nearly complete absence of graft rejection and a low rate of intraoperative/postoperative complications and acute/chronic endothelial cell loss. The low rate of endothelial cell loss has led to LKP becoming the option of choice for patients with normally functioning endothelial cells^[15]. In China, a diversified treatment system has formed for infectious keratitis, and earlier operative interventions done for further optical keratoplasties has become an important principle in this treatment system. Nevertheless, PKP is still the predominant procedure. PKP procedures represent more than half of all corneal transplant procedures in most countries^[2-14].

Trends of indications for PKP

Infectious keratitis As noted in our previous studies^[8,16], infectious keratitis was the most common indication for PKP overall and in each individual year. These results are similar to studies from India and the Taiwan region in China^[7,10] (Table 4). As a large agriculture province, there is a large proportion of farm workers with poor safety awareness and low level medical services in Shandong, which would be the reason for the higher prevalence of infectious keratitis. Moreover, a majority of these farm workers could not obtain effective treatment for their infection, leading to serious endophthalmitis that resulted in enucleation. In recent years, due to an improved referral system, patients with infectious keratitis now receive an early and accurate diagnosis. On the one hand, for patients with severe infectious keratitis,

PKP controls infection and rescues eyes. On the other hand, LKP is performed in a timely manner on mild patients in which infection has not yet involved the whole cornea. Thus, our results indicated that the proportion of infectious keratitis among the indications for PKP continuously increased compared with the results of our previous studies, 1993-1996^[16] and 1997-2002^[8]. Moreover, in all corneal transplant procedures for infectious keratitis, there was a corresponding increase in the selection of LKP to a decline in PKP. It is important that we also accept the reality of a critical shortage of cornea, large number of which have to be used for the emergency management of infectious keratitis each year. Given the fact that infectious keratitis is a preventable disease, there should be an emphasis on prevention over treatment.

The proportion of infectious keratitis caused by unidentified pathogens declined from 28.6% in 1997-2002 to 18.8% in the present study due to the improvement of pathogen culture and species identification techniques. Bacterial culture is the golden standard for the diagnosis of bacterial keratitis, but the positive rate is generally low throughout the world. Results from studies in our center indicate positive rate of 18.2%. Other reports from China indicate a positive rate from 14.1% to 22.1%^[17,18], both of which are generally lower than those reported by researchers in other countries (40%-60%)^[19]. In contrast, it is much easier to detect fungus. Studies have reported that the relevance ratio of microscopy is up to 90%^[20], and furthermore, confocal microscopy, fungal culture and pathological examination all contribute to diagnosis. In addition, the morbidity of Acanthamoebic keratitis is much lower than other forms of infectious keratitis, so the unidentified pathogen cases can be regarded as bacterial keratitis. As a result, in the present

study, the percentage of bacterial keratitis increased to 32.3%, which is similar to the results of our previous study in 1997-2002 (33.2%).

HSK HSK is regarded as a major cause of visual morbidity worldwide, especially in developed countries. The number of herpes simplex infection cases is increasing at a rapid rate, with about one in six adults now infected in the United States and similar rates in the rest of the developed world [21]. The annual incidence of herpetic ocular surface disease ranges from 5.9 to 20.7 per 100 000 people, with a prevalence of 149 per 100 000 people [22]. Although there is less information available, the prevalence and incidence of herpetic eye disease in developing countries may be even higher. In the present study, HSK was the second most common indication for PKP. The result was much higher than observed in of similar studies from other countries [46,1423] (Table 4). Many researchers have demonstrated that systemic oral acyclovir therapy is effective in preventing the recurrence of HSK [24]. However, during our study period, systemic anti-viral therapy was not available for most of the patients, which greatly increased the recurrence frequencies and led to severe corneal lesion and even to perforation. Those issues are likely why there was a much higher percentage of HSK indication for PKP.

Moreover, PKP was never the only option for patients with HSK. Multi-centre trials indicated that prophylactic oral acyclovir use pre- and postoperatively is effective in preventing recurrence [25,26]. DALK combined with anti-viral therapy thereby has become an alternative and safe procedure for the treatment of HSK in patients with healthy endothelium [27,28]. In the current study, 18.9% of patients with HSK received DALK but not PKP.

Keratoconus Percentage of keratoconus indications for PKP varied from 2.7% to 45.6% by geographic region [2-10,1422,29-31] (Table 4). Keratoconus is the leading indication for PKP according to reports from New Zealand, Israel and Iran [29-31]. In Shandong Province, the therapeutic methods for keratoconus have changed a lot in recent decades. In our previous study, the proportion of keratoconus indications for PKP increased continuously from 1997 through 2002, and had become the second leading indication for PKP since 2000, which might be explained by the increase of in presentation rate. However, in this study, the proportion of keratoconus indications in PKP cases presented a sustained decline and has been exceeded by bullous keratopathy since June 1, 2008. A systemic treatment engineering processes has gradually formed in the treatment of keratoconus in recent years. Frame glasses and RGP have been gradually received by more patients in an early disease stage. When Rigid Gas Permeable (RGP) can't be tolerated, nor visual acuity be corrected, DALK, instead of PKP, has become the best choice for patients with intact endothelium due to its similar visual improvement, lower risk of rejection and complications [32,33]. During the study period, PKP was only

performed on patients whose condition could not be resolved by DALK. The ratio of PKP was lower than that of DALK in the treatment of keratoconus during the period of 2005-2010.

Bullous keratopathy Bullous keratopathy after cataract surgery has been the leading indication for PKP in the developed countries since the 1980s and has accompanied the extension of phacoemulsification and intraocular lens (IOL) implantation [2-6]. In recent years, because of the significant advancement in cataract surgery techniques, viscoelastics, improvement of IOL technology, as well as the development of DSEK, bullous keratopathy is no longer the most common indication for PKP in developed countries [11,13]. However, in China, the situation is different. First, cataract surgery in China was never as popular as in developed countries. Second, as an important aetiology of bullous keratopathy, Fuchs' endothelial dystrophy in developed countries, when compared to China, represented a large percentage in PKP indications varying from 9.3% to 16.3% [2-5,14,24]. The proportion of bullous keratitis underlying corneal diseases in developed countries is much higher than that in China (Table 4). The latest research in the USA indicated that over 25000 corneal transplantations are performed yearly for endothelium dysfunction, which accounts for roughly 57% of all keratoplasties [34]. In the past, PKP was the only way to resolve this problem, but in recent years, the use of DSEK has increased dramatically due to its advantages of faster visual rehabilitation, reduced astigmatism, less suture-related infection and graft vascularisation, low likelihood of rejection and improved globe integrity. Reports from American researchers indicate that the number of DSEK surgeries has risen rapidly, increasing 3-fold between 2007-2008, and the number of DSEK procedures now accounts for 32% of all American corneal transplantation surgeries [34]. Thus, the appearance of DSEK brought great changes to the indications for PKP and to the distribution of all corneal transplantation surgeries [11,13]. However, most of the Chinese ophthalmologists take a wait-and-see approach to DSEK. Although there is a small increase, the use of the procedure for bullous keratopathy is still not as popular as that in developed countries. One consideration is that the number of cornea donors is still severely limited for the emergency rescue for infectious keratitis in China, and corneal sources are generally insufficient. DSEK would not in line with China's actual conditions in the short term due to a higher requirements for cornea sources and the larger risk rate of graft failure resulting from graft enfoldment or dislocation [34,35].

Regrafting Regrafting has been reported as the most common indication for corneal transplantation in Canada [23]. The proportion in different studies varied from 10.1% to 40.9% [2-7, 14,23,36,37] (Table 4). We observed regraft proportion of 6.7%, which was much lower than the results observed in other studies. Multiple factors contributed to the low

regrafting rate. First, improved surgical techniques and improvements in the skill of surgeons has benefited the PKP success rate, especially in eyes with infectious keratitis. As per our eye bank policy, a patient has to register on the waiting list for corneal transplantation, although he or she has priority. This may be another reason for the lower proportion of regrafts observed in our study. In addition, the cost of regrafting has remained a major problem, and some patients could not afford a secondary PKP when the grafts became opaque.

In the present series, only 4.8% of eyes with corneal scarring underwent PKP, a proportion that is much lower than what has been observed in the Indian, East China and Taiwanese regions [7-10] (Table 4). This might be associated with differences in classification. In the present study, corneal scarring was classified by their initial diseases. Only if patients with uncertain aetiology were classified as suffering corneal scarring.

In summary, infectious keratitis has remained the leading indication for PKP in Shandong over the last 5 years, and fungal infections are still the major cause of corneal infection. Over the long term there will be emphasis on the prevention over the treatment of infectious keratitis. There was a decreasing trend in the percentage of PKP procedures used in the treatment of keratoconus, but a mild increasing trend in the use of PKP to treat for bullous keratopathy. Even with its declined proportion in keratoplasties, PKP is still the major treatment choice in Shandong.

REFERENCES

- 1 Zirm EK. Eine erfolgreiche totale keratopastik (A successful total keratoplasty). *J Refract Corneal Surg* 1906;5:258-261
- 2 Lois N, Kowal VO, Cohen EJ, Rapuano CJ, Gault JA, Raber IM, Laibson PR. Indications for penetrating keratoplasty and associated procedures, 1989-1995. *Cornea* 1997;16:623-629
- 3 Cosar CB, Sridhar MS, Cohen EJ, Held EL, Alvim Pde T, Rapuano CJ, Raber IM, Laibson PR. Indications for penetrating keratoplasty and associated procedures, 1996-2000. *Cornea* 2002;21:148-151
- 4 Ghosheh FR, Cremona F, Ayres BD, Hammersmith KM, Cohen EJ, Raber IM, Laibson PR, Rapuano CJ. Indications for penetrating keratoplasty and associated procedures, 2001-2005. *Eye Contact Lens* 2008;34: 211-214
- 5 Poinard C, Tuppin P, Loty B, Delbosq B. The French national waiting list for keratoplasty created in 1999: patient registration, indications, characteristics, and turnover. *J Fr Ophthalmol* 2003;26:911-919
- 6 Siganos CS, Tsiklis NS, Miltsakakis DG, Georgiadis NS, Georgiadou IN, Kymionis GD, et al. Changing indications for penetrating keratoplasty in Greece, 1982-2006: a multicenter study. *Cornea* 2010;29:372-374
- 7 Sony P, Sharma N, Sen S, Vajpayee RB. Indications of penetrating keratoplasty in northern India. *Cornea* 2005;24:989-991
- 8 Xie L, Song Z, Zhao J, Shi W, Wang F. Indications for penetrating keratoplasty in north China. *Cornea* 2007;26:1070-1073
- 9 Zhang C, Xu J. Indications for penetrating keratoplasty in East China, 1994-2003. *Graefes Arch Clin Exp Ophthalmol* 2005;243:1005-1009
- 10 Chen WL, Hu FR, Wang JJ. Changing indications for penetrating keratoplasty in Taiwan from 1987 to 1999. *Cornea* 2001;20:141-144
- 11 Li JY, Mannis MJ. Eye banking and the changing trends in contemporary corneal surgery. *Int Ophthalmol Clin* 2010;50:101-112
- 12 Xie L, Qi F, Gao H, Wang T, Shi W, Zhao J. Major shifts in corneal transplantation procedures in north China: 5316 eyes over 12 years. *Br J Ophthalmol* 2009;93:1291-1295

- 13 Keenan TD, Carley F, Yeates D, Jones MN, Rushton S, Goldacre MJ. Trends in corneal graft surgery in the UK. *Br J Ophthalmol* 2011;95:468-472
- 14 Ghosheh FR, Cremona FA, Rapuano CJ, Cohen EJ, Ayres BD, Hammersmith KM, et al. Trends in penetrating keratoplasty in the United States 1980-2005. *Int Ophthalmol* 2008;28:147-153
- 15 Tan DT, Anshu A. Anterior lamellar keratoplasty: 'Back to the Future'- a review. *Clin Experiment Ophthalmol* 2010;38:118-127
- 16 Xie L, Cui Y, Dong X, Li S, Yang X. An epidemiological study of 432 cases of penetrating keratoplasty. *Yan Ke Yan Jiu* 1997;15:243-245
- 17 Sun X, Wang Z, Luo S, Jin X, Zhang W. Distribution and shifting trends of the pathogens for bacterial keratitis. *Zhonghua Yan Ke Za Zhi* 200;38:292-294
- 18 Zhang C, Liang Y, Deng S, Wang ZQ, Li R, Sun XG. Distribution of bacterial keratitis and emerging resistance to antibiotics in China from 2001 to 2004. *Clin Ophthalmol* 2008;2:575-579
- 19 Marangon FB, Miller D, Alfonso EC. Impact of prior therapy on the recovery and frequency of corneal pathogens. *Cornea* 2004;23:158-164
- 20 Bharathi MJ, Ramakrishnan R, Meenakshi R, Mittal S, Shivakumar C, Srinivasan M. Microbiological diagnosis of infective keratitis: comparative evaluation of direct microscopy and culture results. *Br J Ophthalmol* 2006;90:1271-1276
- 21 Liesegang TJ. Herpes simplex virus epidemiology and ocular importance. *Cornea* 2001;20:1-13
- 22 Norn MS. Dendritic (herpetic) keratitis. I. Incidence-seasonal variations-recurrence rate-visual impairment-therapy. *Acta Ophthalmol (Copenh)* 1970;48: 91-107
- 23 Dorrepaal SJ, Cao KY, Slomovic AR. Indications for penetrating keratoplasty in a tertiary referral centre in Canada, 1996-2004. *Can J Ophthalmol* 2007;42: 244-250
- 24 Young RC, Hodge DO, Liesegang TJ, Baratz KH. Incidence, recurrence, and outcomes of herpes simplex virus eye disease in Olmsted County, Minnesota, 1976-2007: the effect of oral antiviral prophylaxis. *Arch Ophthalmol* 2010;128: 1178-1183
- 25 Garcia DD, Farjo Q, Musch DC, Sugar A. Effect of prophylactic oral acyclovir after penetrating keratoplasty for herpes simplex keratitis. *Cornea* 2007;26:930-934
- 26 Ghosh S, Jhanji V, Lamoureux E, Taylor HR, Valpayee RB. Acyclovir therapy in prevention of recurrent herpetic keratitis following penetrating keratoplasty. *Am J Ophthalmol* 2008;145:198-202
- 27 Awan MA, Roberts F, Hegarty B, Ramaesh K. The outcome of deep anterior lamellar keratoplasty in herpes simplex virus-related corneal scarring, complications and graft survival. *Br J Ophthalmol* 2010;94:1300-1303
- 28 Sarnicola V, Toro P. Deep anterior lamellar keratoplasty in herpes simplex corneal opacities. *Cornea* 2010;29:60-64
- 29 Edwards M, Clover GM, Brookes N, Pendergrast D, Chaulk J, McGhee CN. Indications for corneal transplantation in New Zealand: 1991-1999. *Cornea* 2002; 21:152-155
- 30 Yahalom C, Mechoulam H, Solomon A, Raikup FD, Peer J, Frucht-Pery J. Forty years of changing indications in penetrating keratoplasty in Israel. *Cornea* 2005;24:256-258
- 31 Kanavi MR, Javadi MA, Sanagoo M. Indications for penetrating keratoplasty in Iran. *Cornea* 2007;26:561-563
- 32 Cohen AW, Goins KM, Sutphin JE, Wandling GR, Wagoner MD. Penetrating keratoplasty versus deep anterior lamellar keratoplasty for the treatment of keratoconus. *Int Ophthalmol* 2010;30:675-681
- 33 Han DC, Mehta JS, Por YM, Htoon HM, Tan DT. Comparison of outcomes of lamellar keratoplasty and penetrating keratoplasty in keratoconus. *Am J Ophthalmol* 2009;148:744-751
- 34 Straiko MD, Shamie N, Terry MA. Endothelial keratoplasty: past, present, and future directions. *Int Ophthalmol Clin* 2010;50:123-135
- 35 Mau K. What DSAEK is going on? An alternative to penetrating keratoplasty for endothelial dysfunction. *Optometry* 2009;80:513-523
- 36 Al-Yousuf N, Mavrikakis I, Mavrikakis E, Daya SM. Penetrating keratoplasty: indications over a 10 year period. *Br J Ophthalmol* 2004;88:998-1001
- 37 Dandona L, Ragu K, Janarthanan M, Naduvilath TJ, Shenoy R, Rao GN. Indications of penetrating keratoplasty in India. *Indian J Ophthalmol* 1997;45: 163-168