

# Clinical observation of removal of the necrotic corneal tissue combined with conjunctival flap covering surgery under the guidance of the AS-OCT in treatment of fungal keratitis

*Guang-Hua Sun<sup>1,2</sup>, Su-Xia Li<sup>2</sup>, Hua Gao<sup>2</sup>, Wen-Bo Zhang<sup>2</sup>, Mei-Ai Zhang<sup>1,2</sup>, Wei-Yun Shi<sup>1,2</sup>*

<sup>1</sup>Department of Ophthalmology, Qingdao University Medical College, Qingdao University, Qingdao 266071, Shandong Province, China

<sup>2</sup>State Key Laboratory Cultivation Base, Shandong Provincial Key Laboratory of Ophthalmology, Shandong Eye Hospital, Shandong Eye Institute, Shandong Academy of Medical Sciences, Jinan 250021, Shandong Province, China

**Correspondence to:** Wei-Yun Shi. State Key Laboratory Cultivation Base, Shandong Provincial Key Laboratory of Ophthalmology, Shandong Eye Hospital, Shandong Eye Institute, Shandong Academy of Medical Sciences, Jinan 250021, Shandong Province, China. weiyunshi@163.com

Received: 2011-10-25 Accepted: 2012-01-10

## Abstract

• **AIM:** To study the clinical observation of removal of the necrotic corneal tissue combined with conjunctival flap covering surgery under the guidance of the AS-OCT in treatment of fungal keratitis.

• **METHODS:** A retrospective study was done to 10 patients (10 eyes) who had accepted removal of the necrotic corneal tissue combined with conjunctival flap covering surgery for fungal keratitis, the diagnosis by corneal scraping and smear examination or confocal microscopy check hyphae. Local and systemic antifungal therapy more than one week for all patients, corneal ulcer enlarge or no shrink. Slit lamp microscope examination the diameter of corneal ulcer about 2mm-4mm. Anterior segment optical coherence tomography (AS-OCT) examine the depth of corneal ulcer between 1/3-1/2, infiltrate corneal stroma about 20um-80um, the diameter of corneal ulcer about 3mm-6mm. Type-B ultrasonic exclusion endophthalmitis. Complete removal lesions until transparent of stroma, make conjunctival flap equal or greater than ulcer 1mm nearby conjunctiva. Continued antifungal therapy. The vision, fungal recurrence, conjunctival flap rollback or desquamate were analysed.

• **RESULTS:** Ten patients had success done this surgery, the corneal ulcer was not enlarge and healing after operation. 7

cases were bridging conjunctival flap and 3 cases were single conjunctival flap. Preoperation vision above 0.1 had 8 cases, 7 cases had vision above 0.1 one week after surgery, while 1 cases vision dropped from 0.3 to 0.05. There was not recurrent for fungal, 2 cases conjunctival flap rollback: 1 case was bridging and 1 case was single flap, no conjunctival flap desquamate.

• **CONCLUSION:** It is safe and effective to perform removal of the necrotic corneal tissue combined with conjunctival flap covering surgery under the guidance of the AS-OCT in treatment of fungal keratitis which were not sensitive or aggravate for antifungal drugs.

• **KEYWORDS:** AS-OCT; removal of the necrotic corneal tissue; conjunctival flap covering surgery; fungal keratitis  
DOI: 10.3980/j.issn.2222-3959.2012.01.18

Sun GH, Li SX, Gao H, Zhang WB, Zhang MA, Shi WY. Clinical observation of removal of the necrotic corneal tissue combined with conjunctival flap covering surgery under the guidance of the AS-OCT in treatment of fungal keratitis. *Int J Ophthalmol* 2012;5(1):88-91

## INTRODUCTION

Fungal keratitis is a corneal disease by pathogenic fungus infect with high rate blind [1]. Surgery is an effective treatment, removal of the necrotic corneal tissue combined with conjunctival flap covering surgery is an effective simple economic surgery for treatment of fungal keratitis, and it can preserve of eye and vision. Because the death of the lesion and infiltration not clear before surgery, it is easy to make cornea perforation and resection incomplete and recurrence of fungal at previous. We report 10 patients (10 eyes) with fungal corneal who were treated successfully with removal of the necrotic corneal tissue combined with conjunctival flap covering surgery therapy under the guidance of the anterior segment optical coherence tomography (AS-OCT) from October 2009 to December 2010.

## PATIENTS AND METHODS

**Patients** Ten patients (10 eyes) with fungal corneal were

referred to our institution from October 2009 to December 2010. Eight were male and two female, and five were right eye and five left, with an age range of 32 to 63 years. Eight patients had a clear history of ocular trauma: five were plant trauma and three were intromitted in eyes with dust, iron filings, sand, while One had no obvious incentive and One had cold symptoms at premorbid. All patients visited us about 15 to 40 days after onset of fungal corneal. Diagnostic criteria were based on corneal scraping and smear examination or confocal microscopy check hyphae. These patients had been predisposed to antifungal treatment by local and systemic antifungal therapy more than one week, corneal ulcer enlarge or no shrink. Slit lamp microscope examination the diameter of corneal ulcer about 2mm-4mm, In the non-pupil, and three cases had hypopyon, the empyema is less than 3mm. Type-B ultrasonic exclusion endophthalmitis, AS-OCT examine the depth of corneal ulcer between 1/3-1/2, infiltrate corneal stroma about 20um-80um, the diameter of corneal ulcer about 3mm-6mm. The depth of corneal ulcers were determined by the AS-OCT (the company of Zeiss in Germany): taking four-lines scanning method scans and taking phase save, the distance from the deepest of ulcers to the endothelial and the depth of infiltration and peripheral corneal thickness and the diameter of ulcers were determined by the analysis system. All ulcers were given topical Fluconazole eyedrops every 15 minutes and Natamycin eyedrops once an hour and Ofloxacin eyedrops four times daily until 22:00, ofloxacin eye ointment at night. Systemic antifungal was administered 0.2g Fluconazole intravenous injection once a day that given double for the first time, 0.2g Itraconazole Capsules once a day.

The surgery indications: first topical and systemic antifungal therapy more than one week, corneal ulcer enlarge or no shrink; second AS-OCT examine the death of corneal ulcer between 1/3-1/2 and Slit lamp microscope examination the depth of corneal ulcer without descemet infiltration; third ulcers in the non-pupil.

Written informed consent was obtained from each patient. All surgeries were performed by the same surgeon. Topical anesthesia was given before the surgery. 0.2% Fluconazole injection wash eyes and gem cutter stripped ulcers layer by layer until transparent of stroma. Remove the corneal ulcer lesions greater than the range 0.5-1mm and the tissues of ulcer were examined by scraping and smear examination and bacteria fungal cultured. Make a stab at the edge of the cornea with 15° paracentesis knife and washed Anterior Chamber with 0.2% Fluconazole injection. Conjunctival flap was made adopt the principle of proximity nearby ulcer, lidocaine subconjunctival injection to conjunctiva swelling and separate conjunctiva that should be meager and non-Tenon's capsule, made conjunctival flap equal or

greater than ulcer 1mm nearby conjunctiva and the excision clean and dry. After the flap was secured to the ulceration with interrupted 10-0 nylon sutures, the knots were cut short but not buried into corneal stroma to avoid flap detachment at the time of suture removal.

Postoperatively, all eyes were given topical Fluconazole eyedrops 4 times daily, and Natamycin eyedrops 4 times daily, Ofloxacin eyedrops 4 times daily, ofloxacin eye ointment at night. Systemic antifungal was administered 0.2g Fluconazole intravenous injection once a day and Itraconazole Capsules once a day.

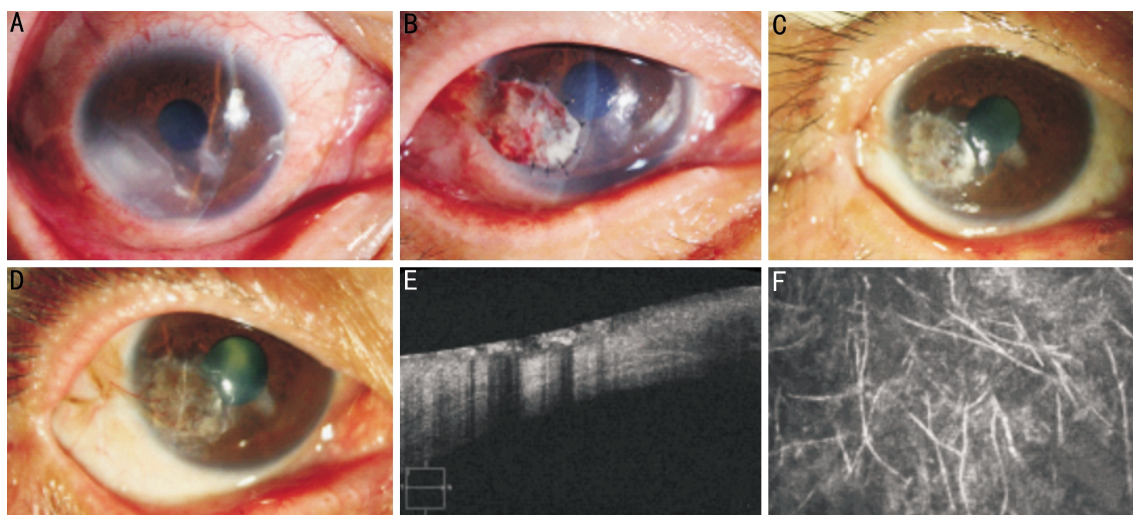
All patients were examined the first week and monthly until 6 month thereafter. Postoperative examination included visual acuity, corneal status (ulceration, edema, and opacification), and fungal recurrence, conjunctival flap transformation.

## RESULTS

Ten patients were found hyphae by the corneal scraping and smear examination, 5 cultivated fungal were 2 aspergillus and 3 fusarium in admission; 7 cultivated fungal were 3 aspergillus and 4 fusarium by cultivated intraoperative corneal ulcers' tissue. 10 patients were examined by confocal microscopy, we found that 5 had a large number of hyphae and 4 had little hyphae and 1 had a large number of necrotic tissue and Inflammatory cells. The shape of hyphae was short stick and fewer branches and a straight high reflective structure by confocal microscopy examined. The results of AS-OCT examined: the thickness of corneas were about  $658.4 \pm 99.92 \mu\text{m}$ , and the thickness of remaining corneas under the ulcer were about  $444.4 \pm 91.18 \mu\text{m}$ , the depth of ulcers were about  $214.0 \pm 61.02 \mu\text{m}$  and the depth of infiltrations were about  $46.1 \pm 19.13 \mu\text{m}$  (Table 1).

All patients had success done this surgery, the corneal ulcer was not enlarge and healing after operation. 7 cases were bridging conjunctival flap and 3 cases were single conjunctival flap. 4 cases' conjunctival flap were covered the pupil about 1/3, 3 were reached the edge of the pupil and 3 were in the non-pupil. There was not recurrent for fungal, 2 cases conjunctival flap rollback: 1 case was bridging and 1 case was single flap, no conjunctival flap desquamate. The first week after surgery the conjunctival flaps were red and thick and had thick tortuous blood vessels, the cornea were edema and opacity; 1 month later the conjunctival flaps were pink and thin and had small pink blood vessels, the cornea were mild edema; three month the conjunctival flaps were pale and almost transparent and thin and smooth and had white linear occlusion vascular, the cornea were transparent (Figure 1).

The results of vision: Preoperation vision above 0.1 had 8 cases, 7 cases had vision above 0.1 one week after surgery, while 1 cases vision dropped from 0.3 to 0.05, 1 month later 8 cases' vision above 0.1 until 3 month, all patients' vision had improved (Table 2).



**Figure 1** A: A fungal keratitis on the temporal of right eye which have satellite lesions; B: 7 days after surgery the conjunctival flap was red and thick, the cornea was edema; C: 1 month the conjunctival flap was pink and the cornea was mild edema; D: 3 month the conjunctival flap was pale and almost transparent and thin, the cornea was transparent. E: AS-OCT examined that the depth of the ulcer was about 144 $\mu$ m, infiltration was about 45 $\mu$ m; F:Confocal microscopy found a large number of hyphae.

**Table 1** The results of AS-OCT examined

$\mu$ m	1	2	3	4	5	6	7	8	9	10
corneal thickness	768	644	736	552	528	508	776	740	660	672
remaining cornea under the ulcer	464	408	584	300	400	364	588	464	396	476
ulcers' deep	304	236	152	252	128	144	188	276	264	196
infiltration's deep	26	43	29	28	62	45	78	36	39	75

**Table 2** The results of vision

Vision	1	2	3	4	5	6	7	8	9	10
Preoperative	0.3	0.6	0.3	FC/10cm	FC/20cm	0.3	0.5	0.5	0.3	0.15
1 week	0.3	0.3	0.3	FC/BE	FC/20cm	0.05	0.6	0.4	0.5	0.5
1month	0.5	0.5	0.4	0.02	0.04	0.2	0.6	0.5	0.5	0.6
3month	0.5	0.5	0.3	0.04	0.02	0.3	0.6	0.5	0.5	0.6

**DISCUSSION**

As the less antifungal agents and the poor penetration, made treatment very difficult at present, the drug cure rate declined significantly when cornea stroma infected and even some patients serious during the drug treated. Removed ulcer lesions was an effective means, while the corneal transplant was the most effective surgery and also it could improve vision [2]. However, As China's serious shortage of corneal donor, the majority of patients cannot surgery in the best time and ultimately corneal perforation and intraocular complications and so on. As the before mentioned, it is important that how to choose the surgical procedure to save patients' eyes and minimizing visual acuity. It is our ophthalmologists' hope that how to select a more simple and effective and rapid restore surgery for the peripheral superficial fungal corneal ulcer.

In this study, 10 patients were measured the depth of cornea

and ulcer and infiltration by the AS-OCT. There are many advantages of the AS-OCT: high resolution, non-contact and non-invasive, high repeatability, a wide range measuring and fast imaging. Adopted the AS-OCT could accurate measure the depth of ulcers under the cornea edema and poor transparency, while the slit lamp microscope had a larger error for this. In addition, postoperative observed the conjunctival flap attached to cornea and analyzed the profile of corneal ulcers. We could distinguish the various levels of the cornea because of the corneal layers had different light reflectivity in the AS-OCT, observed the range of the ulcer and analyzed the depth of invasion, made from the qualitative analysis of slit-lamp to quantitative analysis of corneal AS-OCT. As previously reported, we measured the corneal thickness by type-A ultrasonic, but the A-probe low frequency could not direct imaging and also it was not suitable for corneal ulcers for the probe placed directly on

the cornea that could make corneal perforation and prone to cross-infection. Wong *et al*<sup>[3]</sup> thought that it was significant correlation between the AS-OCT and the type-A ultrasonic for measuring the corneal thickness; Li *et al*<sup>[4]</sup> found the correlation coefficient was 0.97 by measuring the corneal thickness in 42 patients with myopia. Therefore, we choose the AS-OCT not the type-A ultrasonic to measure the cornea thickness in infectious corneal disease, it could avoid the limitations and possible complications for A ultrasonic application in infectious corneal disease, but also got the whole image of the cornea, so as to more accurate analysis of the depth of invasion of corneal ulcers.

We could judge the depth of corneal ulcers and the depth of the lesion infiltrating under the stroma by the AS-OCT at preoperative, also we could avoid removing incomplete and postoperative recurrence of fungi by relying only on the slit-lamp microscope to determine the depth of lesions. As previously reported, it was easy to make intraoperative corneal perforation and postoperative descemetocoele because not clear the depth of the ulcer before surgery. The AS-OCT could also be found the relationship between the ulcer and the infiltration of the cornea, and determined the range of excision, so as to not to remove too much normal corneal tissue to extend the healing time of corneal ulcers or incomplete remove to fungal recurrent. In this study, 10 patients the depth of ulcers about 1/3-1/2 of corneal thickness according to measurements by the AS-OCT, slit-lamp microscope found the deepest of infiltration were about half of stroma. We took penetrating keratoplasty for the deep stroma or descemet infecting, and lamellar keratoplasty for more than 1 / 2 stroma but less than the deep stroma or the wound was no significant infiltration after descemet stripped. Took a strict control of indications for surgery according to preoperative AS-OCT and slit lamp microscope checking, avoided descemetocoele and perforation for the ulcers were too deep<sup>[5]</sup>.

It was time to do this surgery that topical and systemic antifungal therapy more than one week and corneal ulcer enlarge or no shrink, also decided by fungal culture,

particularly aspergillus should be early resect and continue application of antifungal after surgery. The ulcers should be stripped layer by layer until the stroma transparent, the corneal wound should be keep dry to avoid reflective, if not it was prone to corneal perforation. The range of excision should larger than the size of ulcers about 0.5-1mm, we should be more attention that do not strip wear and result in artificial corneal perforation. Conjunctival flap should be meager and non-Tenon's capsule which equal or greater than ulcer 1mm nearby conjunctiva<sup>[6]</sup>, the tension should be as possible as small to prevent postoperative conjunctival flap back. Washed Anterior Chamber with 0.2% Fluconazole injection, it was an important guarantee for fungal non-recurrence that completely remove the ulcers and postoperative patients continue to apply antifungal agents. In summary, it was best to fully assess the depth and scope of resection to avoid remove not completely and do penetrating keratoplasty by the AS-OCT preoperative, completely remove the ulcers and antifungal agents were administered postoperative. It is safe and effective to perform removal of the necrotic corneal tissue combined with conjunctival flap covering surgery under the guidance of the AS-OCT in treatment of fungal keratitis which were not sensitive or aggravate for antifungal drugs.

#### REFERENCES

- 1 Ge J. Ophthalmology. Beijing: People's Medical Publishing House,2010; 180
- 2 Xie L. Corneal Transplantation. BeiJing: People's Medical Publishing House,2000;209
- 3 Wong AC, Wong CC, Yuen NS, Hui SP. Correlational study of central corneal thickness measurements on Hong Kong Chinese using optical coherence tomography, Orbscan and ultrasound pachymetry. *Eye* 2002,16 (6):715-721
- 4 Li Y, Sherhar R, Huang D. Corneal pachymetry mapping with high-speed optical coherence tomography. *Ophthalmology* 2006,113 (5): 792-799
- 5 Li S, Shi W, Liu M, Jin H. Conjunctival flap covering surgery in treatment of refractory Corneal Ulcer. *Yanke Xin Jizhan* 2007,27 (3): 207
- 6 Gundersen JH, Mannis MJ, Holland EJ. Cornea: surgery of the cornea and conjunctiva[M]. 2nd ed. ST. Louis: Mosby-Year Book, 2005:1763-1771