

# Is laser photocoagulation still effective in diabetic macular edema? Assessment with optical coherence tomography in Nepal

Arjun Shrestha<sup>1</sup>, Deepak Khadka<sup>1</sup>, Angira Karmacharya<sup>2</sup>, Nhukesh Maharjan<sup>2</sup>, Anand Shrestha<sup>3</sup>, Raba Thapa<sup>2</sup>, Govinda Poudyal<sup>2</sup>

**Foundation item:** Supported by Natinoal Academy of Medical Sciences, Bir Hospital, Nepal

<sup>1</sup>Geta Eye Hospital, Dhangadhi, Nepal

<sup>2</sup>Tilganga Institute of Ophthalmology, Kathmandu, Nepal

<sup>3</sup>Mountain Health Care and Education Foundation, Kathmandu, Nepal

**Correspondence to:** Arjun Shrestha. Geta Eye Hospital, Dhangadhi, Nepal. drarjuns@hotmail.com

Received: 2011-11-24 Accepted: 2012-03-10

## Abstract

• **AIM:** To find out the outcome of laser photocoagulation in clinically significant macular edema (CSME) by optical coherence tomography (OCT).

• **METHODS:** It was a prospective, non-controlled, case series study enrolling 81 eyes of 64 patients with CSME between August 2008 and January 2010. All patients received modified grid photocoagulation with frequency doubled Nd:YAG laser. Each patient was evaluated in terms of best-corrected visual acuity (BCVA) and regression or progression of maculopathy after laser therapy at 1, 3 and 6 months. Spearman's correlation test was used to show the correlation between BCVA and total macular volume (TMV). Analysis of variance (ANOVA) was used to compare among groups and independent t-test was used to compare in each group.

• **RESULTS:** There is high correlation between BCVA and TMV ( $P \leq 0.001$ ). BCVA improved in 50.6%, remained static in 39.5 % and deteriorated in 9.9% patients after 6 month of treatment. The Baseline TMV (mean and SD) were  $9.26 \pm 1.83$ ,  $10.4 \pm 2.38$ ,  $11.5 \pm 3.05$ ,  $8.89 \pm 0.75$  and  $9.47 \pm 1.98$  mm<sup>3</sup> for different OCT patterns, ST (sponge like thickening), CMO (cystoid macular edema), SFD (subfoveal detachment), VMIA (Vitreous macular interface abnormality) and average TMV respectively ( $P = 0.04$ ). After 6 months of laser treatment, the mean TMV decreased from  $9.47 \pm 1.98$  mm<sup>3</sup> to  $8.77 \pm 1.31$  mm<sup>3</sup> ( $P = 0.01$ ). In ST there was significant decrease in TMV,  $P = 0.01$ , Further within these groups at 6 months, they were significantly different,  $P = 0.01$ .

• **CONCLUSION:** OCT showed the different morphological variant of CSME while the response of treatment is different. TMV decreased the most and hence showed the improvement in vision after 6 months of laser treatment. In the era of Anti vascular endothelial growth factors (VEGFs), efficacy of laser seems to be in shadow but it is still first line of treatment in developing nation like Nepal where antiVEGFs may not be easily available and affordable.

• **KEYWORDS:** Clinically significant macular edema; Grid laser photocoagulation; Optical coherence tomography; Total macular volume

DOI:10.3980/j.issn.2222-3959.2012.02.20

Shrestha A, Khadka D, Karmacharya A, Maharjan N, Shrestha A, Thapa R, Poudyal G. *Int J Ophthalmol* 2012;5(2):217-221

## INTRODUCTION

Diabetic macular edema (DME) is the most common cause of visual loss among diabetic patients. Macular photocoagulation is the established mode of treatment for clinically significant macular edema (CSME) as defined by early treatment diabetic retinopathy study (ETDRS) group<sup>[1-3]</sup>. There is potential for considerable variability and possible lack of sensitivity in the art methods for identifying macular edema as determined by biomicroscopy examination or inspection of stereoscopic photographs that were used in previous clinical studies<sup>[4]</sup>.

Optical coherence tomography (OCT) is a noninvasive imaging technique used to obtain high-resolution cross-sectional images of the retina. The topographic mapping protocol is useful for longitudinally monitoring patients for the development of macular edema and for following the resolution of edema after laser treatment. The false-color map of retinal thickness provides an intuitive and efficient method of comparing retinal volume over several visits, which could be directly compared with slit-lamp observation<sup>[5]</sup>.

Several large multi center studies have shown that laser photocoagulation reduces the macular edema in most

## Is laser still effective in diabetic macular edema in Nepal?

patients and inhibits progression of vision loss in significant number of patients. However, there is limited information available regarding efficacy of macular laser treatment for CSME. The records maintained at Tilganga Institute of Ophthalmology showed more than 200 cases of CSME were treated in 2007 with laser photocoagulation and many cases needed the optical coherence tomography for the detection and comparison of finding in CSME but no study has been conducted to quote the significant application of the same. The predictive value of OCT after laser therapy in CSME is the first study of its kind in Nepal, and this study will be of great use both academically and clinically in modern ophthalmology. This study will address the both qualitative assessment of CSME and quantitative assessment of macular volume before and after the laser therapy in CSME. This study will also focus the visual outcome of laser photocoagulation in CSME.

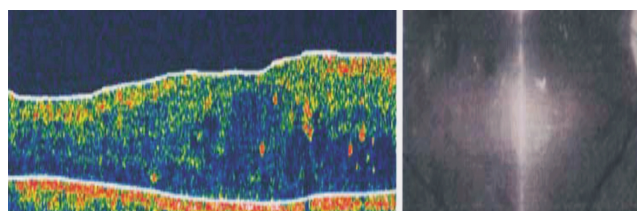
### MATERIALS AND METHODS

**Materials** This was a prospective, non-controlled, case series study done in Tilganga Institute of Ophthalmology (TIO), Kathmandu, Nepal between August 2008 and January 2010. Approval was obtained from institutional review board of TIO, Nepal and consent was taken from patients to enroll in the study. We strictly adhered to the tenets of declaration of Helsinki. Patients received modified grid photocoagulation with frequency doubled Nd: YAG laser at least once according to the ETDRS protocol. Best-corrected visual acuity (BCVA) was taken with Snellen's vision charts and converted into log MAR (logarithm of minimum angle of resolution) equivalent values. Patients were examined with slit-lamp biomicroscopy and dilated fundus was evaluated with +78 or 90 dioptres lens. At each follow-up visit, we assessed whether the patient had persistent, recurrent or new macular edema.

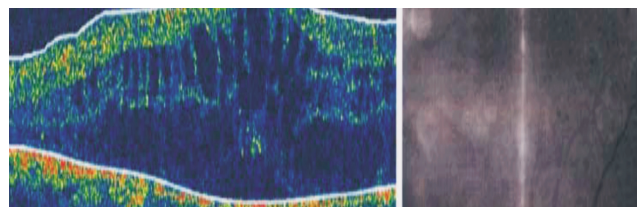
OCT was performed at first visit and every successive follow up visit (1, 3 and 6 months) with Stratus Zeiss Humphrey 3000 model. The specifications of this OCT model include the resolution in tissues of 20 microns in transverse scan and 10 microns in axial and longitudinal scans, the imaging speed of 400 A scans per seconds and image acquisition time of approximately 0.32 to 1.92 seconds (128 A scans minimum to 768 A scans maximum). Quantitative OCT measurement namely Total macular volume (TMV) was measured automatically using OCT retinal mapping software. TMV was defined as the volume ( $\text{mm}^3$ ) of the nine subfields covered in the macular thickness map.

### Methods

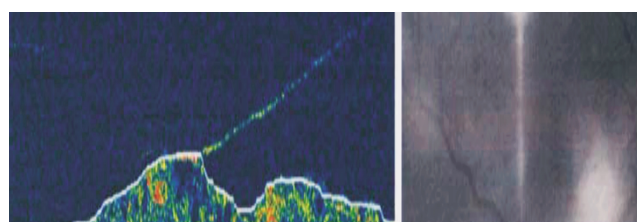
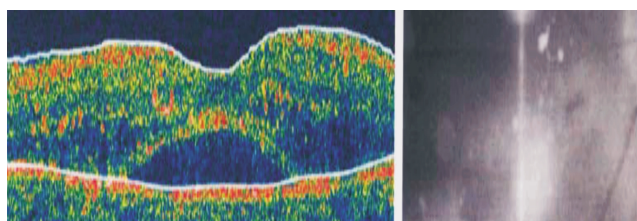
**Data collection** Especially designed Performa was used for the study. The data pertaining to patient demographics, visual acuity, symptoms and signs, investigations, treatment



modalities (types of laser photocoagulation) and the outcome



following laser therapy were collected.



**Figure 1** Sponge like thickening.

**Figure 2** Cystoid macular edema.

**Figure 3** Subfoveal detachment.

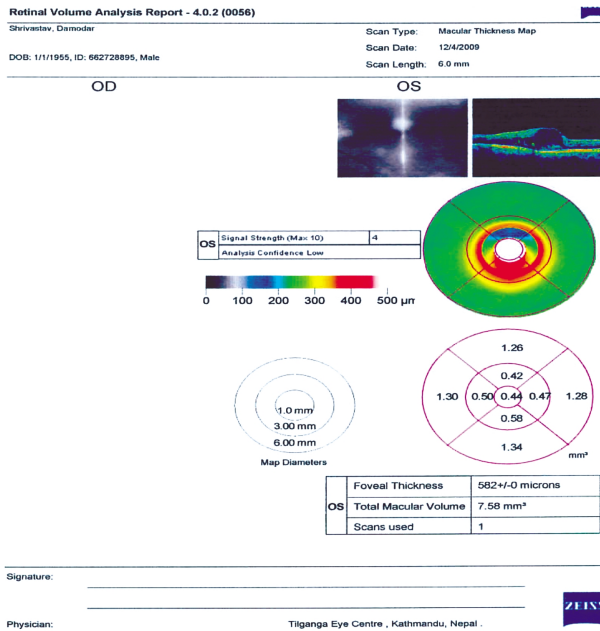
**Figure 4** Vitreomacular interface abnormality.

**Morphology** Different patterns of CSME by OCT are shown in figures. Figure 1 shows the sponge like thickening (ST) that appears as diffuse retinal thickening with areas of reduced intraretinal reflectivity. Figure 2 shows the cystoid macular oedema (CMO) which is characterized by intraretinal cystoid spaces. Figure 3 shows the subfoveal detachment (SFD) characterized by shallow elevation of the retina with an optically clear space between the retina and the retinal pigment epithelium and Figure 4 shows the vitreomacular interface abnormality (VMIA) characterized by a highly reflective band over the inner retinal surface and extending towards the optic nerve or peripherally. Our definition of ST allowed only pure ST. If ST and CMO or SFD were combined, the classifications were CMO or SFD, respectively; and when ST, CMO and SFD were present, the classification was SFD. Regardless of pattern combinations, cases with Epiretinal membrane (ERM) or Vitreomacular traction (VMT) were classified as VMIA. TMV was defined as the volume ( $\text{mm}^3$ ) of the nine subfields covered in the macular thickness map as shown in Figure 5.

**Table 1 Basic characteristics of patients**

Age (yr)	Sex	Duration of diabetes	Diabetes status	Hypertension	Laser Treatment
55.76 (Mean)	Male(61.7%)	9.89 years (Mean)	Controlled (59.2%)	Yes (51.8%)	Modified Grid(64 eyes)
9.107(SD)	Female(38.3%)	5.100 years (SD)	Uncontrolled (40.8%)	No (48.2%)	Modified Grid and pan retinal(17 eyes)

SD: standard deviation.



**Figure 5 OCT showing the Total macular volume.**

**Statistical Analysis** Statistical analysis was performed with SPSS program (version 11.5). Data were expressed in frequency, percentage, mean and standard deviation as applicable. Correlation between vision status and TMV was done with Spearman's correlation test. Analysis of variance (ANOVA) was used to compare among groups and independent t-test was used to compare in each group. The criterion for statistical significance was taken as  $P \leq 0.05$ .

To compare the visual outcomes of eyes with the four patterns, we defined "improved vision" as improvement of vision by at least one line or "deteriorated vision" as diminution of vision by one line and other cases in the snellen's chart as "Static vision". This criterion of vision was followed as mentioned by Zafar *et al* [6].

**RESULTS**

Eighty-one eyes of 65 patients were enrolled in the study. Table 1 describes the basic characteristics of patients. The OCT revealed the ST pattern in 67.9 % followed by CMO in 19.7 % (Table 2). Table 3 shows, TMV decreased in majority of patients after 6 months of laser treatment. In table 4, the effect of treatment on TMV according to OCT patterns are summarized. At 6 months, the mean TMV decreased from  $9.47 \pm 1.98 \text{ mm}^3$  to  $8.77 \pm 1.31 \text{ mm}^3$ , ( $P=0.01$ ). We found significant decrease in TMV in ST ( $P=0.01$ ) but not in CMO and SFD ( $P=0.68$  and  $0.63$  respectively).

**Table 2 OCT finding on first visit**

Morphology	Percentages
ST	67.9
CMO	19.7
ST+ SFD	2.2
ST+VMIA	4.0
CMO+SFD	2.2
CMO+ VMIA	4.0

OCT: optical coherence tomography, ST: sponge like thickening, CMO: cystoid macular edema, SFD: subfoveal detachment, VMIA: vitreo macular interface abnormalities.

Moreover, TMV increased in VMIA ( $P=0.91$ ). Further within these groups at 6 months, they were significantly different ( $P=0.01$ ).

According to Table 5, BCVA improved in 50.6 %, remained static in 39.5 % and deteriorated in 9.9 % after 6 months of laser treatment. There is high correlation between improved vision status and TMV ( $P<0.001$ ).

**DISCUSSION**

Laser photocoagulation remains the standard of care and the only treatment with proven efficacy for CSME according to a large-scale clinical trial. Our study revealed ST pattern in 67.9% followed by CMO in 19.7%. Rivellesse *et al* [7] reported almost similar finding of morphology on OCT as ours. Ferreira *et al* [8] in 2007 found a different baseline incidence, with 57.5% of scans demonstrating CMO, 47.9% ST and 20.5% SFD. Discrepancy for this finding could be first due to inclusion of DME patients who took the intravitreal Triamcilon injection only and second due to collection of data using a newer version of OCT, with higher resolution.

In patients with diabetic retinopathy, laser treatment is directed at prevention of visual loss rather than visual improvement. In our study, we followed the study definitions of ETDRS with respect to diagnosis and treatment of CSME. BCVA improved in 50.6 %, remained static in 39.5 % and deteriorated in 9.9 % after 6 months of treatment. There is highly correlation between improved vision status and TMV ( $P<0.001$ ). The criterion of improved vision was one line in our study. This is almost similar to the study by Zaidi *et al* [6] who found that 29.7% of patients maintained their baseline visual acuity and 35.6% of patients showed improvement in vision. Olk *et al* [9] showed that macular laser treatment resulted in visual improvement in 33% of cases taking the

**Table 3 TMV among eyes with laser treatment**

Month	Decreased (No. of eyes/ %)			Increased (No. of eyes/ %)		
	1	3	6	1	3	6
TMV	39(48.1)	47(58.0)	57(70.4)	42(51.9)	34(42.0)	24(29.6)

TMV: total macular volume.

**Table 4 Change in TMV from baseline**

TMV (mm <sup>3</sup> )	ST	CMO	SFD	VMIA	All	Mean ± SD	P value
Baseline TMV	9.26 ± 1.83	10.4 ± 2.38	11.5 ± 3.05	8.89 ± 0.75	9.47 ± 1.98		0.04
6 Month TMV	8.59 ± 1.10	9.86 ± 2.43	10.74 ± 0.81	8.95 ± 0.91	8.77 ± 1.31		0.01
P value	0.01	0.68	0.63	0.91	0.01		

TMV: total macular volume, SD: standard deviation, mm<sup>3</sup>: cubic millimeters, ST: sponge like thickening, CMO: cystoid macular edema, SFD: subfoveal detachment, VMIA: vitreo macular interface abnormalities.

**Table 5 Visual outcome among eyes with laser treatment**

Vision status	Month 1(%)	Month 3(%)	Month 6(%)
Improved	28.4	30.9	50.6
Static	46.9	54.3	39.5
Deteriorated	24.7	14.8	9.9
Total	100	100	100

criteria for visual improvement as at least two lines of Snellen's vision chart. ETDRS showed that photocoagulation decreased persistent macular edema and significant visual loss (doubling of visual angle) by 50% [10].

To our knowledge, the significance of patterns in terms of predicting response to modified grid laser photocoagulation has not been properly studied. The baseline TMV were 9.26 ± 1.83mm<sup>3</sup>, 10.40 ± 2.38mm<sup>3</sup>, 11.50 ± 3.05mm<sup>3</sup> and 8.89 ± 0.75mm<sup>3</sup> for different OCT patterns ST, CMO, SFD and VMIA respectively (*P* = 0.04). At 6 months, the mean TMV decreased from 9.47 ± 1.98mm<sup>3</sup> to 8.77 ± 1.31mm<sup>3</sup>, (*P* = 0.01). In ST there was significant decrease in TMV, *P* = 0.01, while in other morphologic variants changes in TMV was not significant. Further within these groups at 6 months, they were significantly different, *P* = 0.01. We hypothesize that this is explained by different CSME patterns.

Yamamoto *et al* [11] found that visual acuity is significantly better in ST eyes than in CMO eyes regardless of laser photocoagulation. Chronic macular edema causes liquefaction necrosis of müller cells, which forms cystoid cavities leading to CMO. These spaces exist in the outer retinal layers initially but progressively extend to all retinal layers. It was reported recently that OCT-based retinal volumes and central macular thickness are equally effective at detecting CSME [12]. In the present study, we also found that retinal volume could represent decreases in macular edema after modified grid laser photocoagulation. We suggest that an understanding of structural changes evident by OCT in the macula of ST patients before laser

photocoagulation would help predict treatment outcome.

There are also some limitations in this study. Anti VEGFs are in use nowadays and are found more suitable for decreasing macular edema than laser photocoagulation but anti VEGFs are not easily available and affordable in developing country like Nepal. Glycated hemoglobin could not be done in every patient. We did not use ETDRS vision chart but Snellen's vision is converted in to Log MAR equivalent. We have not excluded patients from our study if grade 1 cataract had progressed to grade 2 according to Lens opacity classification system (LOCS) 2 and this could have affected the final visual acuity, however if grade 3 cataract progressed to grade 4, they were excluded. A large prospective randomized controlled trial is required to investigate this relationship further.

In conclusion, TMV decreased the most and hence showed the improvement in vision after 6 months of laser treatment. This report had addressed the both qualitative and quantitative assessment of CSME before and after the laser therapy. The response of treatment is different for different morphological features of CSME. Although, this time domain OCT is still valuable in the context of developing country like Nepal, new generation OCT like spectral domain has already come in practice in other developed countries. This will be replaced in future by new generation OCT. Evaluation of TMV and visual outcome after laser therapy in CSME is the first study of its kind in Nepal, and this study will be of great use both academically and clinically in modern ophthalmology.

Acknowledgments: I am grateful to Prof. Sanduit Ruit, Medical Director, and Dr Reeta Gurung, Deputy Medical Director, for allowing me to conduct this study in Tilganga Institute of Ophthalmology, Nepal. I am also grateful to Dr. Purusottam Dhungana and his team for helping me in taking vision and refraction and Dr. Rajya Laxmi Gurung, Mr RK Suwal and Mr Bhai Saran Thapa for helping me in data

collection and OCT recording. Last but not the least; I must not forget the co-operation received from all patients and their visitors who voluntarily agreed for this study.

#### REFERENCES

- 1 Early Treatment Diabetic Retinopathy Research group. Photocoagulation for diabetic macular edema: ETDRS report No 1. *Arch Ophthalmology* 1985;103:1796-1806
- 2 Manual of Ocular diagnosis and therapy-4th Ed. Pavan-Langston D. Little Brown and Company 1996:162-165
- 3 Yanof M, Duker JS. Diabetic Retinopathy. Ophthalmology, 2 nd Ed, Mosby 2004:877-885
- 4 Gianni Virgili, Francesca Menchini, Andrea F. Dimastrogiovanni, Emilio Rapizzi, Ugo Menchini, Francesco Bandello, Optical Coherence Tomography Versus Stereoscopic Fundus Photography or Biomicroscopy for Diagnosing Diabetic Macular Edema: A Systematic Review. *Invest Ophthalmol Vis Sci* 2007;48:4963-4973
- 5 P Sony, P Venkatesh, S Garg, H Tewari, Step by step Optical coherence tomography 2007
- 6 Zafar A Zaidi, Mary K Jacob, Effect of macular photocoagulation on visual acuity of Omani patients with clinically significant macular edema. *Oman Journal of Ophthalmology* 2009;2(2):62-66
- 7 Rivellesse M, George A, Sulkes D, Reichel E, Puliafito C. Optical Coherence Tomography after Laser Photocoagulation for Clinically Significant Macular Edema, Ophthalmic Surgery and Lasers ;ISSN 1082-3069
- 8 Oswaldo Ferreira, Moura Brasil, Scott D Smith, Anat Galor, Careen Y Lowder, Jonathan E Sears, Peter K Kaiser. Predictive factors for short-term visual outcome coherence tomography study for diabetic macular oedema: an optical after intravitreal triamcinolone acetanide injection. *Br J Ophthalmol* 2007 91: 761-765
- 9 Olk RJ. Modified grid argon laser photocoagulation for diffuse diabetic macular edema. *Ophthalmology* 1986;93:938-950
- 10 Early treatment Diabetic Retinopathy Study Research Group. Technique for scatter and local photocoagulation treatment of diabetic retinopathy: Early diabetic retinopathy study report No. 3. *Int Ophthalmol Clin* 1987;27:254-264
- 11 Yamamoto S, Yamamoto T, Hayashi M, et al. Morphological and functional analyses of diabetic macular edema by optical coherence tomography and multifocal electroretinograms. *Graves Arch Clin Exp Ophthalmol* 2001;2(39):96-101
- 12 Fine BS, Brucker AJ. Macular edema and cystoid macular edema. *Am J Ophthalmology* 1981; 92:466-481