

# Primary 23 –gauge vitreoretinal surgery for rhegmatogenous retinal detachment

*Ates Yanyali<sup>1</sup>, Gokhan Celik<sup>2</sup>, Alper Dinciyildiz<sup>2</sup>, Fatih Horozoglu<sup>3</sup>, Ahmet F. Nohutcu<sup>2</sup>*

<sup>1</sup>Private Practice, Bagdat Cad. Alantar Ap. No: 302/6, Istanbul, Turkey

<sup>2</sup>Department of Ophthalmology, Haydarpaşa Numune Education and Research Hospital, Istanbul, Turkey

<sup>3</sup>Department of Ophthalmology, Namik Kemal University Faculty of Medicine, Tekirdag, Turkey

**Correspondence to:** Ates Yanyali. Private Practice, Bagdat Cad. Alantar Ap. No: 302/6, Istanbul, Turkey. dr@atesyanyali.com

Received: 2011-10-13 Accepted: 2012-03-16

## Abstract

- **AIM:** To report the effectiveness and safety of primary 23-Gauge (G) vitreoretinal surgery for rhegmatogenous retinal detachment (RRD).

- **METHODS:** In this retrospective study, 49 eyes of 49 consecutive patients who underwent primary 23-G transconjunctival sutureless vitrectomy (TSV) for RRD between January 2007 and July 2009 at our institution were evaluated.

- **RESULTS:** Mean follow-up time was 8.9± 7.7 months (1-28 months). Retinal reattachment was achieved with a single operation in 47 (95.9%) of 49 eyes. In two eyes (4.1%), retinal redetachment due to new breaks was successfully treated with reoperation using the 23-G TSV system. Mean logMAR visual acuity was 2.01 ± 0.47 preoperatively and 1.3 ± 0.5 postoperatively ( $P < 0.001$ , Paired  $t$ -test). Mean preoperative intraocular pressure (IOP) was 14.1± 2.8mmHg. Mean postoperative IOP was 12.3± 3.6mmHg at 1 day, 13.1± 2.1mmHg at 1 week, 14.3± 2.2mmHg at 1 month. Iatrogenic peripheral retinal break was observed in 1 eye (2.0%) intraoperatively. No sutures were required to close the scleral or conjunctival openings, and no eyes required conversion of surgery to 20-G vitrectomy.

- **CONCLUSION:** Primary 23-G TSV system was observed to be effective and safe in the treatment of RRD.

- **KEYWORDS:** pars plana vitrectomy; retinal detachment; rhegmatogenous retinal detachment; transconjunctival sutureless vitrectomy; vitreoretinal surgery; 23-gauge vitrectomy

DOI:10.3980/j.issn.2222-3959.2012.02.22

Yanyali A, Celik G, Dinciyildiz A, Horozoglu F, Nohutcu AF. Primary 23–gauge vitreoretinal surgery for rhegmatogenous retinal detachment. *Int J Ophthalmol* 2012;5(2):226–230

## INTRODUCTION

Primary pars plana vitrectomy (PPV), pneumatic retinopexy and scleral buckling are the treatment options in rhegmatogenous retinal detachment (RRD). The choice of surgical procedure is dependent on the location and number of breaks, quadrant of retinal detachment and presence of proliferative vitreoretinopathy<sup>[1-7]</sup>.

Machemer *et al*<sup>[8]</sup> first performed PPV in 1971 and standard three-port PPV was developed soon after this innovation<sup>[9]</sup>. Fujii *et al*<sup>[10,11]</sup> introduced the 25-G transconjunctival sutureless vitrectomy (TSV) in 2002 to minimize surgically induced trauma. Recently, Eckardt<sup>[12]</sup> developed 23-G TSV using an obliquely entering trocar cannular system and this evolution in vitreoretinal surgery has become increasingly popular in the last few years. Primary 23-Gauge TSV for rhegmatogenous retinal detachment was previously reported in only small number of patients<sup>[13,14]</sup>. The purpose of this study was to report the effectiveness and safety of the primary 23-G TSV in the treatment of RRD.

## MATERIALS AND METHODS

**Materials** In this retrospective non-control study, we evaluated 49 eyes of 49 consecutive patients who underwent primary 23-G TSV for RRD between January 2007 and July 2009 at our institution. Patients with previous retinal detachment surgery were excluded. In our institution, we do not perform scleral buckling surgery in recent years. If the eye is not suitable for pneumatic retinopexy, we perform primary vitrectomy. The indications of primary 23-G TSV for RRD were listed in Table 1. Vitreous hemorrhage in 5 eyes (10.2%), choroidal detachment in 4 eyes (8.2%) and macular hole in 1 eye (2.0%) were the concurrent conditions with RRD.

Main outcome measures were anatomical and functional outcomes as well as intraoperative and postoperative complications. Visual acuity improvement was defined as improvement by 2 or more lines. Stable visual acuity was defined as no change or 1 line change in visual acuity. Visual acuity impairment was defined as impairment by 2 or more lines.

**Table 1 Indications of primary 23-G TSV for RRD**

Indications	n (%)
Pseudophakic retinal detachment	21(42.8%)
Phakic retinal detachment not suitable for pneumatic retinopexy	15(30.6%)
Retinal detachment with giant tear	3(6.1%)
Aphakic retinal detachment	2(4.1%)
Grade C or worse preoperative PVR	8(16.3%)

The possible merits and risks of the treatment were explained to the patient and an informed consent was obtained in accordance with the Helsinki Declaration prior to inclusion in the study. Institutional Review Board approval was not required for this study.

All patients received a best-corrected Snellen visual acuity measurement, anterior segment examination, intraocular pressure (IOP) measurement with Goldmann applanation tonometry and biomicroscopic evaluation with both fundus non-contact and contact lenses. All IOPs were taken at 08.00-10.00 am. B-scan ultrasonography was performed in all eyes in which visualization of the fundus was not attained. Best-corrected Snellen visual acuities were converted into logMAR (logarithm of the minimum angle of resolution) units. Inferior breaks were located in the inferior 4 clock hours (4-8 o'clock [inclusive]).

## Methods

**Surgical technique** All of the operations were performed by the same surgeon (A.Y.) under sub-Tenon anesthesia. The 2-step 23-G vitrectomy system (Dutch Ophthalmic Research Center, Zuidland, The Netherlands) was used in all cases. The microcannulas were inserted transconjunctivally with the help of the insertion trocars in the inferotemporal, superotemporal, and superonasal quadrants, 3.5mm posterior to the limbus in pseudophakic and aphakic eyes, and 4mm posterior to the limbus in phakic eyes. A special pressure plate was used to laterally displace the conjunctiva in the three sites where the trocars were placed and to hold the conjunctiva against the sclera. A 23-G MVR was inserted tangentially at an angle of approximately 30° parallel to the limbus. The infusion cannula was placed in the inferotemporal quadrant, and plugs were used to temporarily close the other entry sites. High speed vitrectomy probe (2267.NMD06) of surgical system (DORC Associate 2500, Zuidland, The Netherlands) with a cutting rate of 1500-2500 cuts per minute and a vacuum level of 400mmHg to 500 mmHg was used during PPV. The balanced salt solution (BSS) bottle height was set at 50 cm. Retinal reattachment with perfluorocarbon liquid (PFCL, Okta-line, Bausch&Lomb Surgical, Claremont, California, USA), endolaser photocoagulation (around the tear (s) and 360° peripheral retina), air-PFCL exchange and internal tamponade were performed in all cases. The internal tamponades that were

**Table 2 Internal tamponades used in treatment of RRD**

Internal tamponade	n (%)
Silicone oil	33 (67.3%)
Heavy silicone oil	2 (4.1%)
Sulfur hexafluoride (SF6) gas	12 (24.5%)
Perfluoropropane (C3F8) gas	2 (4.1%)

used in the treatment of RRD are silicone oil (Siluron 1000, Fluoron, GmbH, Ulm, Germany), heavy silicone oil (Densiron 68 LV, Fluoron, GmbH, Ulm, Germany), SF6 gas (GOT SF6 multi, Alchimia, Ponte S.Nicolo, Italy), and C3F8 gas (GOT C3F8 multi, Alchimia, Ponte S.Nicolo, Italy.) (Table 2). Silicone oil was used as internal tamponade for patients who will fly, who will not be able to do the head position after gas injection or who need to have early visual rehabilitation. Epiretinal membrane peeling was performed when required. Insertion trocars were removed slightly from the eye at the end of the operation. A gentle massage to the sclerotomy site with a muscle hook was performed to avoid leakage. The conjunctiva overlying the sclerotomy was slightly displaced to disrupt the alignment between both entry sites, and an antibiotic and corticosteroid combination was injected into the subconjunctival space.

Silicone oil was removed within 2 months after the surgery in all eyes that received silicone oil injection. Single operation success was defined as complete retinal reattachment after silicone oil removal and after complete resorption of the gas following primary 23-G TSV surgery for RRD. Postoperative 1<sup>st</sup> day, 1<sup>st</sup> week, 1<sup>st</sup> month, 3<sup>rd</sup> month and 3 months intervals thereafter were the time points for examination.

**Statistical Analysis** Statistical analysis was performed using the Statistical Package for Social Sciences software (SPSS for Windows, Version 17.0, SPSS Inc., Chicago, IL.). Kolmogorov-Smirnov test was used in testing whether the variables have depicted a normal distribution or not. The repeated one-way ANOVA and the paired samples *t* test were used for statistical analysis. *P*<0.05 was defined as statistically significant.

## RESULTS

Mean follow-up time was 8.9± 7.7 months (range, 1 to 28 months). Preoperative characteristics of patients: mean age, gender, visual acuity, lens status and duration of retinal detachment were listed in Table 3. Most of the retinal breaks were single and located in superior quadrants. The macula was detached in most of the eyes (Table 4).

Single operation success was achieved in 47 (95.9%) of 49 eyes. Retinal redetachment due to a new break was observed postoperative one week in 1 eye and postoperative three weeks in the other eye. These eyes were successfully treated with reoperation using the 23-G TSV system.

Mean best-corrected logMAR visual acuity ±SD was

## Primary 23-G TSV for RRD

**Table 3 Preoperative characteristics of patients underwent primary 23-G TSV for RRD**

Characteristics	
Age (y)*	55.4±16.8
Sex, n(%)	
Female	28(57.2%)
Male	21(42.8%)
Eye, n(%)	
Right	29(59.2%)
Left	20(40.8%)
Preoperative logMAR visual acuity*	2.01±0.47
Mean follow-up time (m)*	8.9±7.7
Lens status, n(%)	
Phakic	26(53.1%)
Pseudophakic	21(42.8%)
Aphakic	2(4.1%)
Duration of retinal detachment (d)*	49±85(4-365)

\*Mean ± SD; Y = year; m = month; d = day

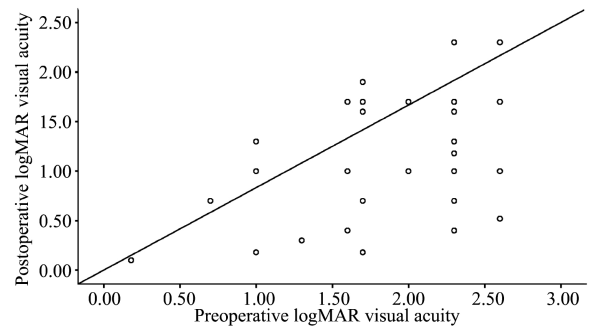
**Table 4 Preoperative characteristics of RRD and retinal break**

Characteristics	n (%)
Location of breaks	
Superior	27 (55.1%)
Inferior	10 (20.4%)
Superior and Inferior*	12 (24.5%)
Number of retinal breaks	
One	28 (57.2%)
Multiple	18 (36.7%)
Giant	3 (6.1%)
Quadrant of retinal detachment	
1 quadrant	-
2 quadrant	14 (28.6%)
3 quadrant	14 (28.6%)
Total	21 (42.8%)
Macular detachment	
Macula off	40 (81.6%)
Macula on	9 (18.4%)

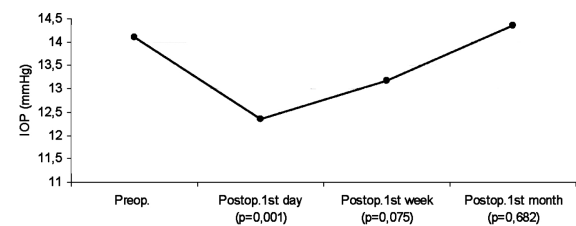
\* Patients with breaks in both superior and inferior quadrants

2.01±0.47 (counting fingers equivalent) preoperatively and 1.3±0.5 (20/400 equivalent) postoperatively ( $P < 0.001$ , Paired  $t$ -test) (Figure 1). Postoperative visual acuity improved in 41 eyes (83.7%), was stable in 7 eyes (14.3%), and impaired in 1 eye (2.0%). Postoperative visual acuity was 20/40 or better in 4 eyes (8.2%).

Mean preoperative IOP was 14.1 ± 2.8 mmHg. Mean postoperative IOP was 12.3 ± 3.6 mmHg at 1 day, 13.1 ± 2.1 mmHg at 1 week and 14.3 ± 2.2 mmHg at 1 month (Figure 2). As there were differences between repeated measurements ( $P < 0.05$ , one-way ANOVA test), pairwise comparisons were performed and the results of analysis of IOP changes were given in Table 5. Postoperative hypotony (<8 mmHg), which was observed in 1 eye (2.0%) normalized spontaneously within the first postoperative week.



**Figure 1 Preoperative and postoperative logMAR visual acuities in 49 eyes which underwent 23-G PPV for RRD. Postoperative visual acuity improved in 41 eyes, was stable in 7 eyes, and impaired in 1 eye.**



**Figure 2 IOP changes after 23-G TSV.**

**Table 5 Analysis of IOP changes**

IOP	$P^*$
Preoperative- postoperative 1 <sup>st</sup> day	0.001
Preoperative- postoperative 1 <sup>st</sup> week	0.075
Preoperative- postoperative 1 <sup>st</sup> month	0.682
Postoperative 1 <sup>st</sup> day- postoperative 1 <sup>st</sup> week	0.045
Postoperative 1 <sup>st</sup> day- postoperative 1 <sup>st</sup> month	0.000
Postoperative 1 <sup>st</sup> week- postoperative 1 <sup>st</sup> month	0.002

\* Paired samples  $t$ -test,  $P < 0.05$  is statistically significant

**Table 6 Intraoperative and postoperative complications of primary 23-G TSV for RRD**

Complications	n (%)
Intraoperative	
Iatrogenic retinal tear	1(2.0%)
Postoperative	
Cataract formation or progression	10(38.5%)
Redetachment	2(4.1%)
Macular pucker	3(6.1%)
Silicone oil droplets in anterior chamber	5(10.2%)
Glaucoma controlled by topical medication	2(4.1%)
Transient hypotony	1(2.0%)

No major intraoperative complication was encountered except for iatrogenic peripheral retinal break in 1 eye (2.0%). PPV, epiretinal membrane peeling, endolaser photocoagulation, air-PFCL exchange and internal tamponade injection were performed easily. Postoperative complications were cataract formation or progression, macular pucker, silicone oil droplets in anterior chamber, glaucoma controlled by topical medication and transient hypotony (Table 6). Cataract formation or progression was observed in 10 eyes. All of them received cataract surgery

during the follow-up period. Subconjunctival leak of silicone oil was not seen in any cases. Leakage, extension, dehiscence and hemorrhage, or vitreous or retinal incarceration at the external side of the sclerotomies was not observed in any eye. The internal side of the sclerotomies was not evaluated by ultrasound biomicroscopy. No sutures were required to close the scleral or conjunctival openings and no eyes required conversion of surgery to 20-G PPV.

## DISCUSSION

In a previous prospective study, in which primary 23-G PPV with intraocular gas tamponade was performed in 24 eyes with RRD, primary and final anatomical success rate was 91.7% and 100%, respectively. Visual acuity improved in 82%, was stable in 9%, and impaired in 9% of eyes [13]. In another study, in which primary 23-G PPV with silicone oil tamponade was performed in 10 eyes with complex RRD, primary success rate was 90% and visual acuity improved in 90% of eyes [14]. Similarly, primary anatomical success rate was 95.9% and final anatomical success rate was 100% in our study. Visual acuity improved in 83.7%, was stable in 14.3%, and impaired in 2% of eyes. Visual acuity was 20/40 or better in 8.2% of eyes after surgery.

The primary and final anatomical success rates of primary PPV in RRD have been reported as 62.6-98.3% [1,7] and 93-100% [2,3] with 20-G, 72.2-92.9% [15,16] and 91.6-100% [17,18] with 25-G, respectively. Most of these studies did not use silicone oil as the primary tamponade. In our study, silicone oil was used as an internal tamponade in 67.3% of eyes.

The potential advantages of 20-G PPV without scleral buckling over conventional scleral buckling are expected to be the advantages of TSV. These are less operation time, accurate diagnosis of breaks, controlled drainage of subretinal fluid and no postoperative axial length changes. There are several advantages of TSV over 20-G PPV including reduced postoperative inflammatory reaction, absence of suture related irritation and local inflammatory reaction at the sclerotomy sites, reduced postoperative conjunctival injection and pain, improved patient comfort, faster postoperative recovery, reduced surgically induced trauma, insignificant corneal surface and astigmatic changes, and less conjunctival scarring [11,19-21]. Furthermore, there is no limbal stem cell damage due to conjunctival dissection, so it may be advantageous in eyes with corneal or conjunctival diseases such as dry eye.

Therefore, if a primary PPV is appropriate in the management of retinal detachment, it may be logical to perform it with a TSV system.

In our study no major intraoperative complication was encountered except for peripheral retinal break that was observed in 1 eye (2.0%). Postoperative complications were cataract formation or progression (38.5%), macular pucker (6.1%), silicone oil droplets in anterior chamber (10.2%), glaucoma controlled by topical medication (4.1%) and transient hypotony (2.0%). Intraoperative retinal break,

scleral suture requirement, hypotony, cataract, macular pucker, cystoid macular edema, vitreous hemorrhage, retinal redetachment, choroidal detachment, endophthalmitis and glaucoma have been previously reported in several studies with 20-G PPV, 23 and 25-G TSV [1,3,7,13-15,18-51].

Short follow-up time and lack of comparison of eyes treated with 20-G PPV and 25-G TSV were the primary limitations of this study. Our study design was retrospective and postoperative evaluation could not be performed at predetermined time points. Therefore, we could not evaluate the functional outcomes and anatomical results at each follow-up.

In conclusion, 23-G TSV was observed to be safe and effective in the treatment of RRD with or without severe PVR in 49 eyes. Further studies comparing the 23-G TSV system to standard 20-G PPV, 25-G TSV and scleral buckling for RRD with a long follow-up time are required to make a more reliable conclusion.

## REFERENCES

- 1 Ahmadi H, Moradian S, Faghihi H, Parvaresh MM, Chanbari H, Mehryar M, Heidari E, Behboudi H, Banaee T, Golestan B; Anatomic and visual outcomes of scleral buckling versus primary vitrectomy in pseudophakic and aphakic retinal detachment: six month follow-up results of a single operation-report no.1. *Ophthalmology* 2005;112(8):1421-1429
- 2 Escoffery RF, Olk RJ, Grand MG, Boniuk I. Vitrectomy without scleral buckling for primary rhegmatogenous retinal detachment. *Am J Ophthalmol* 1985; 99(3): 275-281
- 3 Sharma YR, Karunanithi S, Azad RV, Vohra R, Pal N, Singh DV, Chandra P. Functional and anatomic outcome of scleral buckling versus primary vitrectomy in pseudophakic retinal detachment. *Acta Ophthalmol Scand* 2005; 83(3): 293-297
- 4 Oshima Y, Emi K, Motokura M, Yamanishi S. Survey of surgical indications and results of primary pars plana vitrectomy for rhegmatogenous retinal detachments. *Jpn J Ophthalmol* 1999;43(2): 120-126
- 5 Tornambe PE, Hilton GF, the Retinal Detachment StudyGroup. Pneumatic retinopexy: a multicenter randomized controlled clinical trial comparing pneumatic retinopexy with scleral buckling. *Ophthalmology* 1989; 96(6): 772-784
- 6 Tornambe PE, Hilton GF, Kelly NF, Salzano TC, Wells JW, Wendel RT. Expanded indications for pneumatic retinopexy. *Ophthalmology* 1988; 95 (5): 597-600
- 7 Martinez-Castillo V, Zapata MA, Boixadera A, Fonollosa A, García-Arumí J. Pars plana vitrectomy, laser retinopexy, and aqueous tamponade for pseudophakic rhegmatogenous retinal detachment. *Ophthalmology* 2007; 114(2): 297-302
- 8 Machemer R, Buettner H, Norton EW, Parel JM. Vitrectomy: a pars plana approach. *Trans Am Acad Ophthalmol Otolaryngol* 1971;75(4):813-820
- 9 O'Malley C, Heintz RM Sr. Vitrectomy with an alternative instrument system. *Ann Ophthalmol* 1975; 7(4): 585-588, 591-594
- 10 Fujii GY, De Juan E Jr, Humayun MS, Pieramici DJ, Chang TS, Awh C, Ng E, Barnes A, Wu SL, Somerville DN. A new 25-Gauge instrument system for transconjunctival sutureless vitrectomy surgery. *Ophthalmology* 2002; 109(10): 1807- 1812
- 11 Fujii GY, De Juan E Jr, Humayun MS, Chang TS, Pieramici DJ, Barnes A, Kent D. Initial experience using the transconjunctival sutureless vitrectomy system for vitreoretinal surgery. *Ophthalmology* 2002; 109(10): 1814-1820
- 12 Eckardt C. Transconjunctival sutureless 23-gauge vitrectomy. *Retina* 2005; 25(2): 208-211

- 13 Tsang CW, Cheung BT, Lam RF, Lee GK, Yuen CY, Lai TY, Lam DS. Primary 23-gauge transconjunctival sutureless vitrectomy for rhegmatogenous retinal detachment. *Retina*2008; 28(8): 1075–1081
- 14 Oliveira LB, Reis PA. Silicone oil tamponade in 23-gauge transconjunctival sutureless vitrectomy. *Retina*2007; 27(8): 1054–1058
- 15 Shah CP, Ho AC, Regillo CD, Fineman MS, Vander JF, Brown GC. Short-term outcomes of 25-gauge vitrectomy with silicone oil for repair of complicated retinal detachment. *Retina*2008;28(5):723–728
- 16 Miller DM, Riemann CD, Foster RE, Petersen MR. Primary repair of retinal detachment with 25-gauge pars plana vitrectomy. *Retina*2008; 28 (7): 931–936
- 17 Kapran Z, Acar N, Altan T, Unver YB, Yurttaser S . 25-Gauge sutureless vitrectomy with oblique sclerotomies for the management of retinal detachment in pseudophakic and phakic eyes. *Eur J Ophthalmol* 2009(5);19: 853–860
- 18 Von Fricken MA, Kunjukunju N, Weber C, Ko G. 25-Gauge sutureless vitrectomy versus 20-gauge vitrectomy for the repair of primary rhegmatogenous retinal detachment. *Retina*2009;29(4):444–450
- 19 Wimpissinger B, Kellner L, Brannath W, Krepler K, Stolba U, Mihalics C, Binder S. 23-gauge versus 20-gauge system for pars plana vitrectomy: a prospective randomised clinical trial. *Br J Ophthalmol*2008;92 (11): 1483–1487
- 20 Yanyali A, Celik E, Horozoglu F, Nohutcu AF. Corneal topographic changes after transconjunctival (25-gauge) sutureless vitrectomy. *Am J Ophthalmol* 2005;140(5):939–941
- 21 Fine HF, Iranmanesh R, Iturralde D, Spaide RF. Outcomes of 77 consecutive cases of 23-gauge transconjunctival vitrectomy surgery for posterior segment disease. *Ophthalmology* 2007;114(6): 1197–1200
- 22 Yamamoto T, Hitani K, Tsukahara I, Yamamoto S, Kawasaki R, Yamashita H, Takeuchi S. Early postoperative retinal thickness changes and complications after vitrectomy for diabetic macular edema. *Am J Ophthalmol*2003; 135(1): 14–19
- 23 Braziiikos PD, Androudi S, D'Amico DJ, Papadopoulos N, Dimitrakos SA, Derekliis DL, Alexandridis A, Lake S, Stangos NT. Perfluorocarbon liquid utilization in primary vitrectomy repair of retinal detachment with multiple breaks. *Retina*2003; 23(5): 615–621
- 24 Konstantinidis L, Berguiga M, Beknazar E, Wolfensberger TJ. Anatomic and functional outcome after 23-gauge vitrectomy, peeling, and intravitreal triamcinolone for idiopathic macular epiretinal membrane. *Retina*2009; 29(8): 1119–1127
- 25 Kusahara S, Ooto S, Kimura D, Itoi K, Mukuno H, Miyamoto N, Akimoto M, Kuriyama S, Takagi H. Outcomes of 23- and 25-gauge transconjunctival sutureless vitrectomies for idiopathic macular holes. *Br J Ophthalmol*2008; 92(9): 1261–1264
- 26 Guyomarch J, Delyfer MN, Korobelnik JF. Outcomes of 110 consecutive 25-gauge transconjunctival sutureless pars plana vitrectomies. *J Fr Ophthalmol* 2008; 31(5): 473–480
- 27 Gupta OP, Weichel ED, Regillo CD, Fineman MS, Kaiser RS, Ho AC, McNamara JA, Vander JE . Postoperative complications associated with 25-gauge pars plana vitrectomy. *Ophthalmic Surg Lasers Imaging*2007; 38(4): 270–275
- 28 Lott MN, Manning MH, Singh J, Singh J, Zhang H, Singh H, Marcus DM . 23-gauge vitrectomy in 100 eyes: short-term visual outcomes and complications. *Retina*2008; 28(9): 1193–1200
- 29 Yanyali A, Celik E, Horozoglu F, Oner S, Nohutcu AF. 25-Gauge transconjunctival sutureless pars plana vitrectomy. *Eur J Ophthalmol* 2006; 16(1): 141–147
- 30 Oshima Y, Ohji M, Tano Y. Surgical outcomes of 25-gauge transconjunctival vitrectomy combined with cataract surgery for vitreoretinal diseases. *Ann Acad Med Singapore* 2006; 35(3): 175–180
- 31 Misra A, Ho-Yen G, Burton RL. 23-gauge sutureless vitrectomy and 20-gauge vitrectomy:a case series comparison. *Eye*2009;23(5): 1187–1191
- 32 La Heij EC, Hendrikse F, Kessels AG. Results and complications of temporary silicone oil tamponade in patients with complicated retinal detachments. *Retina*2001; 21(2): 107–114
- 33 Singh CN, Lezzi R, Mahmoud TH. Intraocular pressure instability after 23-gauge vitrectomy. *Retina*2010; 30(4): 629–634
- 34 Schweitzer C, Delyfer MN, Colin J, Korobelnik JF. 23-Gauge transconjunctival sutureless pars plana vitrectomy: results of a prospective study. *Eye*2009; 23(12): 2206–2214
- 35 Horozoglu F, Yanyali A, Celik E, Aytug B, Nohutcu AF. Primary 25-gauge transconjunctival sutureless vitrectomy in pseudophakic retinal detachment. *Indian J Ophthalmol*2007; 55(5): 337–340
- 36 O' Reilly P, Beatty S. Transconjunctival sutureless vitrectomy: initial experience and surgical tips. *Eye*2007; 21(4): 518–521
- 37 Azad RV, Chanana B, Sharma YR, Vohra R. Primary vitrectomy versus conventional retinal detachment surgery in phakic rhegmatogenous retinal detachment. *Acta Ophthalmol Scand*2007; 85(5): 540–545
- 38 Rizzo S, Genovesi-Ebert F, Vento A, Cresti F, Di Bartolo E, Belting C. A new heavy silicone oil (HWS 46–3000) used as a prolonged internal tamponade agent in complicated vitreoretinal surgery: a pilot study. *Retina* 2007; 27(5): 613–620
- 39 Tewari A, Shah GK, Fang A. Visual outcomes with 23-gauge transconjunctival sutureless vitrectomy. *Retina*2008; 28(2): 258–262
- 40 Ibarra MS, Hermel M, Prenner JL, Hassan TS. Longer-term outcomes of transconjunctival sutureless 25-gauge vitrectomy. *Am J Ophthalmol* 2005; 139(5): 831–836
- 41 Campo RV, Sipperley JO, Sneed SR, Park DW, Dugel PU, Jacobsen J, Flindall RJ. Pars plana vitrectomy without scleral buckle for pseudophakic retinal detachments. *Ophthalmology*1999; 106(9): 1811–1815
- 42 Lai MM, Ruby AJ, Sarrafzadeh R, Urban KE, Hassan TS, Dresner KA, Garretson BR. Repair of primary rhegmatogenous retinal detachment using 25-gauge transconjunctival sutureless vitrectomy. *Retina* 2008; 28 (5): 729–734
- 43 Haas A, Seidel G, Steinbrugger I, Maier R, Gasser-Steiner V, Wedrich A, Weger M. Twenty-three-gauge and 20-gauge vitrectomy in epiretinal membrane surgery. *Retina*2010; 30(1): 112–116
- 44 Parolini B, Prigione G, Romanelli F, Cereda MG, Sartore M, Pertile G. Postoperative complications and intraocular pressure in 943 consecutive cases of 23-gauge transconjunctival pars plana vitrectomy with 1-year follow-up. *Retina*2010; 30(1): 107–111
- 45 Millsap CM, Peyman GA, Mehta NJ, Greve MD, Lee KJ, Ma PE, Dunlap WA. Perfluoroperhydrophenanthrene (Vitreon) in the management of giant retinal tears: results of a collaborative study. *Ophthalmic Surg* 1993; 24(11): 759–763
- 46 Cheung BT, Lai TY, Yuen CY, Lai WW, Tsang CW, Lam DS. Results of high-density silicone oil as a tamponade agent in macular hole retinal detachment in patients with high myopia. *Br J Ophthalmol*2007; 91 (6): 719–721
- 47 Lommatzsch A, Heimes B, Trieschmann M, Spital G, Pauleikhoff D. Long-term results after pars plana vitrectomy with 25 gauge technique. *Ophthalmologie*2008; 105(5): 445–451
- 48 Valmaggia C. Pars plana vitrectomy with 25-gauge instruments in the treatment of idiopathic epiretinal membranes. *Klin Monbl Augenheilkd* 2007; 224(4): 292–296
- 49 Scott IU, Flynn HW Jr, Dev S, Shaikh S, Mitra RA, Arevalo JF, Kychenthal A, Acar N. Endophthalmitis after 25-gauge and 20-gauge pars plana vitrectomy: incidence and outcomes. *Retina* 2008;28(1): 138–142
- 50 Wolf S, Schön V, Meier P, Wiedemann P. Silicone oil–RMN3 mixture ("heavy silicone oil") as internal tamponade for complicated retinal detachment. *Retina*2003; 23(3): 335–342
- 51 Honavar SG, Goyal M, Majji AB, Sen PK, Naduvilath T, Dandona L. Glaucoma after pars plana vitrectomy and silicone oil injection for complicated retinal detachments. *Ophthalmology*1999; 106(1): 169–176