

Bilateral capsule contraction syndrome following pathological myopic cataract surgeries

Zong-Duan Zhang, Zhen Song, Ding Chen, Fang Huang

Eye Hospital of Wenzhou Medical College, Wenzhou 325017, Zhejiang Province, China

Correspondence to: Zong-Duan Zhang. Eye Hospital of Wenzhou Medical College, Wenzhou 325027, Zhejiang Province, China. zzduan@163.net

Received: 2011-09-26 Accepted: 2012-05-09

DOI:10.3980/j.issn.2222-3959.2012.03.31

Zhang ZD, Song Z, Chen D, Huang F. Bilateral capsule contraction syndrome following pathological myopic cataract surgeries. *Int J Ophthalmol* 2012;5(3):406–408

Dear Sir,

I am Dr Zong-Duan Zhang, from the Eye Hospital of Wenzhou Medical College, Wenzhou, Zhejiang Province, China. I write to present a case report of bilateral capsule contraction syndrome (CCS).

CCS is a well-recognized postoperative complication of cataract surgery which occurs predominantly after continuous curvilinear capsulorhexis (CCC)^[1]. It comprises capsule opacification, capsulorhexis shrinkage and secondary intraocular lens (IOL) deformation, decentration and tilt. Effectiveness of the Neodymium:YAG (Nd:YAG) laser treatment to this postoperative complication has been confirmed. We reported a case of CCS with both anterior and posterior capsular shrinkage after implantation of IOL with relatively high stability performance, and treated with both anterior and posterior capsulotomy using Nd:YAG laser. To our knowledge, this is the first described case of bilateral CCS with both anterior and posterior capsule shrinkage after a single-piece hydrophilic acrylic IOL (Akreos Adapt) implantation that successfully treated anterior and posterior capsulotomy with Nd:YAG laser.

A 55-year-old woman with pathological myopia in both eyes underwent uneventful phacoemulsification cataract extraction in the left eye. A CCC of 5.0 mm diameter was performed followed by in-the-bag implantation of a +6.0D Akreos Adapt (Bausch&Lomb) IOL. Routine phacoemu-

lsification and in-the-bag implantation of a +9.0 D IOL with the same type was performed in the right eye. The immediate postoperative period was uneventful. After 2 months, the uncorrected distance visual acuity (UDVA) was 20/160 (OD) and 20/125 (OS), and the CDVA was 20/100 with -2.25-2.00×115 (OD) and 20/40 with -2.25-1.75×75 (OS).

One year postoperatively, the corrected distance visual acuity (CDVA) decreased to 20/125 (OD) and 20/500 (OS). Clinical examination showed significant bilateral anterior capsule opacification (ACO) and posterior capsule opacification (PCO) and shrinkage of the capsular bags. The capsulorhexis opening appeared to be fibrous metaplasia, and there were multiple capsular bag folds of both anterior and posterior capsules. In the left eye, decentration and tilt of the IOL was noted. One of the 4 closed loops at 2 o'clock position appeared to be flexed anteriorly within the capsular bag in association with capsular fibrosis, more prominent at the corresponding side (Figure 1A,B). Similar changes were observed in the right eye with flexed haptic at the 10 o'clock position (Figure 1C). Radial relaxing capsulotomy of the anterior capsule and circular capsulotomy of the posterior capsule with Nd:YAG laser was performed in both eyes. Radial incision was carried out at the most prominent segment. The treatment reduced the displacing force of the contracting capsule on the IOL and relieved traction on the zonules in the mostly affected segment, resulting in stabilization and recentering of the IOL (Figure 1D, E, F). The CDVA increased to 20/100 (OD) and 20/40 (OS).

CCS is associated with ocular pathologies which can compromise blood-aqueous barrier, including pseudoexfoliation syndrome, retinitis pigmentosa, advanced age, high myopia, myotonic muscular dystrophy and uveitis^[1-4]. The fact that the patient in this case had advanced age and high myopia might account for this postoperative complication.

The CCC has been proposed to be a predisposing factor of CCS in the light of the size and shape of the opening^[1]. CCC has been confirmed to be associated with contraction of capsulorhexis opening much higher than can-opener

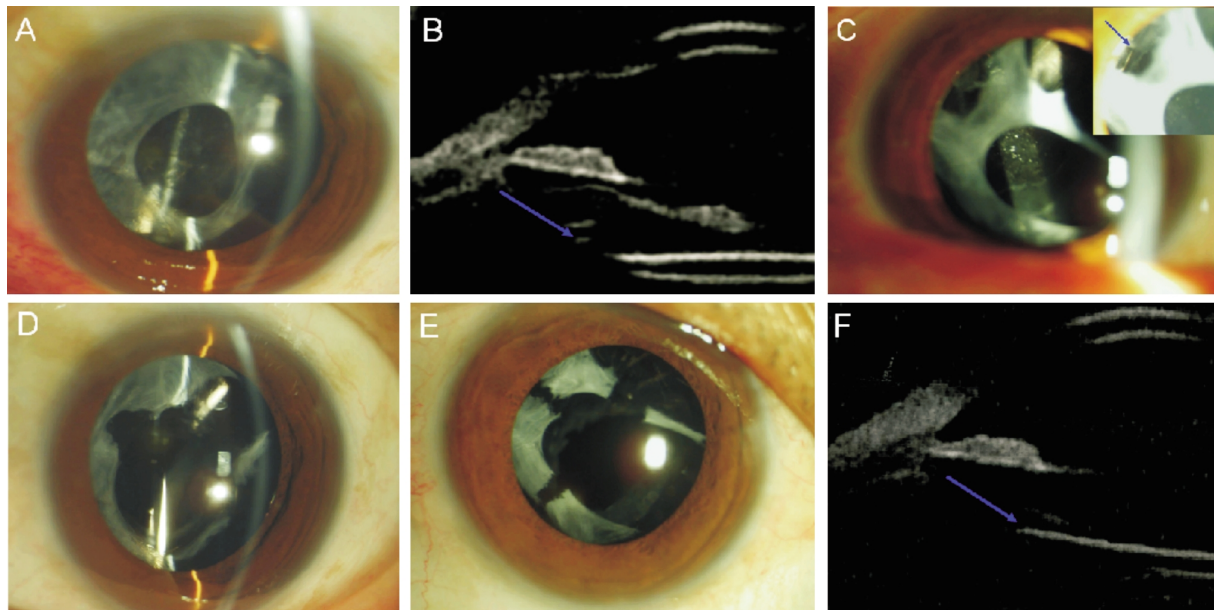


Figure 1 Photographs of bilateral CCC before and after Nd:YAG laser treatment A: One of the 4 closed loops flexed anteriorly within the capsular bag at the 2 o'clock position in the left eye; B: UBM scan showed the tilt and anterior flexing of the haptic (arrow); C: Multiple posterior capsular bag folds of the capsular bags with PCO in the right eye, with one flexed haptic (arrow) at the 10 o'clock position; D: The replacement of the IOL in the left eye after relaxing Nd:YAG laser anterior and posterior capsulotomy; E: The IOL in the right eye recentered after the same procedure; F: UBM scan showed the replacement and stability of the haptic (arrow) after relaxing Nd:YAG laser anterior and posterior capsulotomy.

capsulotomy. It is well-recognized that the optimal diameter of the opening is 5.5-6.0cm. The capsulorhexis opening in this presented case was a little smaller than the proposed optimal diameter. Additionally, the fibrous membrane is resulted from the fibrous metaplasia of the lens epithelial cells at the inner surface of the anterior capsule^[5], so careful polishing of the anterior capsule can improve the stability of the capsule by avoiding the persistence of the lens epithelial cells^[6]. As the capsulorhexis opening size is too small, it is not viable to have the inner surface of the anterior capsule of the IOL carefully polished.

We also believe that the complication of cataract surgery described in this case might have implications for the design of the IOL implanted^[7]. Akreos Adapt is a biconvex single-piece hydrophilic acrylic IOL with 4 haptics of closed loops providing 4 points of fixation to the capsular bag. The movement of the 4 haptics is limited by adhesion between the anterior and posterior leaves of the capsular bag around the fixation points. The double-square edges minimize cell migration leading to PCO^[7]. This design ensures stability performance of the IOL. Qatarneh *et al*^[8] described three cases of marked capsule fibrosis with anterior flexion of the haptics of this IOL style, two of which were associated with hyperopic shift. Another two cases of capsulorhexis phimosis with anterior flexing of 4-looped single-piece hydrophilic acrylic intraocular lenses were recently reported

by Zaug *et al*^[9]. The overall design of the described IOL was similar to Akreos Adapt.

Surgical intervention has been adopted in certain cases to treat CCS^[3,9]. In the event of severe shrinkage and opacification of the capsular bag, the operation of anterior capsulotomy tearing is preferred^[10]. Nd:YAG laser anterior capsulotomy has been proven to be safe and effective to treat CCS^[1,2]. Chawla and Shaikh^[2] reported the use of an alternate technique of an Nd:YAG laser parabolic anterior capsulotomy in extreme cases of CCS with complete occlusion of the capsulorhexis, which resulted in a clear visual axis with stabilization of the IOL in the bag. In our case, radial relaxing capsulotomy of the anterior capsule and circular capsulotomy of the posterior capsule with Nd:YAG laser was successfully performed in both eyes, resulting in recentering of the IOL and clearance of the visual axis. This combination of both anterior and posterior capsulotomy with Nd:YAG laser as an effective treatment of CCS has rarely been reported.

These and similar cases could help surgeons to better understand the characteristics of this type of IOL, the potential problems that may occur after its implantation, and the treatment approaches that can be considered. It is important to examine and document changes in the anterior capsule in the follow up because ACO generally occurs much earlier in comparison with PCO^[10], and it can help to

choose the treatment method when CCS occurs.

REFERENCES

- 1 Davison JA. Capsule contraction syndrome. *J Cataract Refract Surg* 1993; 19:582–589
- 2 Chawla JS, Shaikh MH. Neodymium: YAG laser parabolic anterior capsulotomy in extreme capsule contraction syndrome. *J Cataract Refract Surg* 1999; 25:1415–1417
- 3 Michael K, O'Colmain U, Vallance JH, Cormack TG.. Capsule contraction syndrome with haptic deformation and flexion. *J Cataract Refract Surg* 2010; 36:686–689
- 4 Xiao W, Zhao DX, Xue LQ. Rapid bilateral anterior capsule contraction following high myopic cataract surgeries: a case report. *Int J Ophthalmol* 2011;4(2):207–209
- 5 Kurosaka D, Ando I, Kato K, Oshima T, Kurosaka H, Yoshino M, Nagamoto T, Ando N. Fibrous membrane formation at the capsular margin in capsule contraction syndrome. *J Cataract Refract Surg* 1999; 25: 930–935
- 6 Cochener B, Jacq PL, Colin J. Capsule Contraction after continuous curvilinear capsulorhexis: Poly (methyl methacrylate) versus silicone intraocular lenses. *J Cataract Refract Surg* 1999; 25:1362–1369
- 7 Sacu S, Menapace R, Findl O. Effect of optic material and haptic design on anterior capsule opacification and capsulorhexis contraction. *Am J Ophthalmol* 2006; 141:488–493
- 8 Qatarneh D, Hau S, Tuft S. hyperopic shift from posterior migration of hydrophilic acrylic intraocular lens optic. *J Cataract Refract Surg* 2010; 36:161–163
- 9 Zaig B, Werner L, Neuhann T, Burrow M, Davis D, Mamalis N, Tetz M. Clinicopathologic correlation of capsulohexis phimosis with anterior flexing of single-piece hydrophilic acrylic intraocular lens haptics. *J Cataract Refract Surg* 2010; 36:1605–1609
- 10 Izak AM, Werner L, Pandey SK, Apple DJ, Vargas LG, Davison JA. Single-piece hydrophobic acrylic intraocular lens explanted within the capsular bag: case report with clinicopathological correlation. *J Cataract Refract Surg* 2004; 30:1356–1361