

Descemet membrane detachment after trabeculectomy

Yue-Hua Li, Jing-Ming Shi, Fang Fan, Xuan-Chu Duan, Song-Bai Jia

Department of Ophthalmology, the 2nd Xiangya Hospital, Central South University, Changsha 410011, Hunan Province, China

Correspondence to: Song-Bai Jia. Department of Ophthalmology, the 2nd Xiangya Hospital, Central South University, Changsha 410011, Hunan Province, China. jsb88cn@126.com

Received: 2012-05-04 Accepted: 2012-07-17

Abstract

• Descemet's membrane detachment (DMD) can be a potentially serious complication of intraocular surgery or ocular trauma. The cause is not very clear. We are trying to remind an awareness of the spectrum of DMD resulting from trabeculectomy by presenting a case of extensive DMD after trabeculectomy which was successfully repaired.

• **KEYWORDS:** Descemet membrane detachment; trabeculectomy; glaucoma; cornea

DOI: 10.3980/j.issn.2222-3959.2012.04.24

Li YH, Shi JM, Fan F, Duan XC, Jia SB. Descemet membrane detachment after trabeculectomy. *Int J Ophthalmol* 2012;5(4):527-529

INTRODUCTION

Detachment of Descemet's membrane (posterior limiting lamina), first reported in 1927, occurs when there is a separation of the endothelium-Descemet membrane complex from the posterior corneal stroma [1] is a potentially serious complication of intraocular surgery or trauma [2-6]. It can result in corneal edema, double anterior chamber, decreased vision and corneal decom- pensation. Documentation of Descemet's membrane detachment during trabeculectomy is unusual. We present a long-term follow-up of a case of Descemet's membrane detachment (DMD) post-trabeculectomy which was delayedly diagnosed and successfully repaired without suture fixation. It is important for ophthal- mologists to maintain an awareness of the spectrum of DMD resulting from trabeculectomy.

TYPICAL CASE

A 62-year-old female patient had suffered an acute attack of angle closure glaucoma in her left eye of 2 days duration. Examinations showed severe cornea edema and intraocular pressure (IOP) was 8mmHg in her right eye (RE) and 54mmHg in left eye (LE) measured by Goldmann applanation tonometer. Best-corrected visual acuity (BCVA)

was 20/40 OD and counting fingers at 1 foot OS. Ultrasound biomicroscopy (UBM) showed 360° of anterior chamber angle closure. The central cornea thickness was 771µm. Topical and systemic medications were prescribed to lower the IOP and alleviate the inflammation. After treatment, BCVA was 20/600 and IOP was 14mmHg with 360° anterior chamber angle closure presented by UBM and gonioscopy (both static and dynamic) in her left eye. The thickness of left lens was 5.07mm and the depth of the left anterior chamber was 2.2mm. So trabeculectomy was performed accompanied by laser releasable sutures and antimetabolite adjunctive therapy. The anterior chamber was reformed with balanced salt solution after the surgery.

On the first day postoperatively, the BCVA was 20/100 and the IOP was 14mmHg in left eye. Severe cornea edema was noted. Topical tropicamide 0.5% was used to dilate the pupil and topical corticosteroids were applied. On the 4th day, laser suturolysis was performed to enhance the reformation of post trabeculectomy bleb. At 10-day follow-up, there was moderate cornea edema and a membrane detected in the anterior chamber that was adherent to the peripheral cornea. UBM showed Descemet's membrane detachment close to the lens (Figure 1). Surgical repair was performed as follows. A partial thickness paracentesis was intentionally created at the lower part of the detachment pocket using B-D syringe. The liquid in the detachment pocket was extracted through the paracentesis, and intracameral gas was injected to restore the membrane. At the 2nd week follow-up, cornea edema had decreased and slit lamp showed a detached Descemet's membrane and double anterior chambers clearly (Figure 2). Then the same treatment was repeated with intracameral sodium hyaluronate injection as a temponade to move the Descemet's membrane forward for a longer time. After 2 intracameral injections, UBM showed partially resolved Descemet's membrane. During the following eleven days, we performed one sodium hyaluronate and two air injections.

One month after the surgery, the cornea edema completely subsided with the BCVA 20/50 and IOP 10mmHg in left eye without medication. Unfortunately, Descemet's folds remained in the inferonasal part of the clear cornea (Figure 3). The Descemet membrane remained attached at 70-day follow-up examination. And specular microscopy revealed a cornea endothelial cell count of 1506/mm² compared with 2427/mm² before surgery (Figures 4, 5). At a 10-month

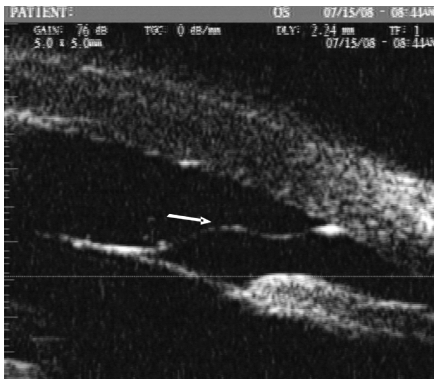

Figure 1 UBM: detached Descemet's membrane.




Figure 2 SLE: detached Descemet's membrane and double anterior chambers.

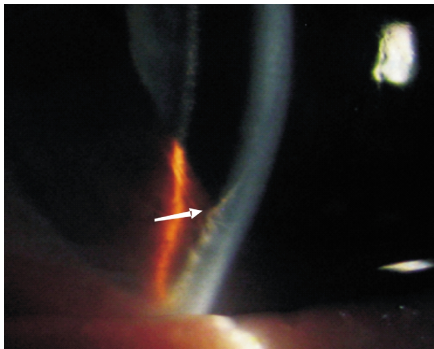


Figure 3 SLE: Descemet's membrane scar.

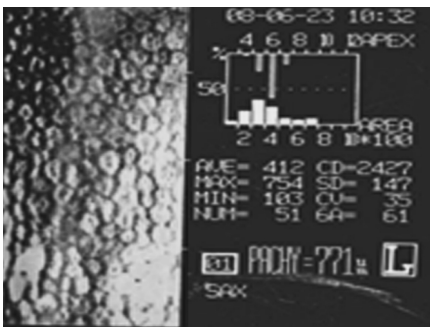


Figure 4 Preoperative endothelial cell count.

follow-up examination, BCVA was 20/40 and IOP was 6mmHg in left eye without medication, but the Descemet's fold was still visible. The endothelial cell count decreased to 1079/mm² with increased size and shapes of the endothelial cells. In the 3-year follow-up, BCVA was 20/60 and IOP was 10mmHg in left eye without medication, and the Descemet's fold was still visible. The endothelial cell count had decreased to 763/mm² and the central cornea thickness




Figure 5 Endothelial cell count 70-day after the surgery.

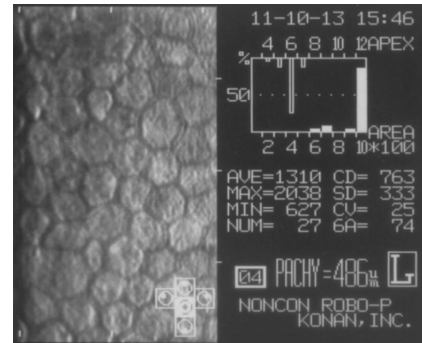


Figure 6 Endothelial cell count 3-year after the surgery.

was 486µm OS (Figure 6). And cataract in the left eye had progressed.

DISCUSSION

Pathogenesis DMD occurs as a rare complication of ocular trauma or intraocular surgery. Although the cause is not clear, several probable reasons are as follows: shallow anterior chamber; accidental insertion of the instruments between stroma and the Descemet's membrane; use of blunt microkeratomes; shelved incisions; inadvertent injection of saline or viscoelastic into the space between the deep stroma and the Descemet's membrane [7, 8] or weak adhesions between the stroma and the DM, which may be caused by a genetic disorder^[9]. In this case, the shallow anterior chamber and cornea edema before surgery were considered as a predisposition and detachment might happen when inadvertent intracameral balanced salt solution injection was used to restore anterior chamber. This means it is very important to carefully observe the tip of the cannula to make sure it is completely inside of the anterior chamber before the injection. But a retrospective study by Mahmood *et al*^[10] reported no identified risk factors associated with Descemet's membrane detachments.

Clinical Presentation Once DMD occurs, the stroma next to the detachment becomes edematous. If the central cornea is involved, significant reduction in visual acuity and cornea edema may occur. DMD may progress to induce the whole cornea. Slit-lamp showed a detached Descemet's membrane including the central and inferiornasal cornea and double anterior chambers. UBM would help in case with severe cornea edema.

Diagnosis While DMD may be evident upon slit lamp examination, *in vivo* confocal microscopy provides a definitive diagnosis and serves as an effective method to monitor microstructural changes in the cornea over time. UBM would help. The main problem delayed diagnosis and appropriate treatment in this case was the edematous cornea since it was reasonable for patient experienced acute attack.

Treatment Minor DMD may resolve spontaneously without medical intervention [11], detectable Descemet's membrane detachments should be repaired in a timely manner for its potential damage to the cornea. Management includes both medical and surgical treatments, depending on the size and severity of the detachment. Medical treatment with topical hyperosmotics and steroids is effective for small Descemet's membrane detachments that do not affect vision acuity [6, 12]. Large, central Descemet's membrane detachments are unlikely to resolve with topical medical treatment and usually require surgical intervention [3-5, 13, 14]. However, successful repair of large Descemet's membrane detachment with topical medications only has been reported [6]. Surgical intervention include intracameral injection of a tamponading agent, suturing the membrane into place, or penetrating keratoplasty or Descemet's Stripping Endothelial Keratoplasty (DSEK). tamponading agent includes air, slow-resorbing gas or viscoelastic material. Air tends to be absorbed quickly. Intracameral injection of slow-resorbing gas is also reported [12,13,15,16], such as perfluoropropene(C3F8) or non-expansile sulfur hexafluoride (SF6). But perfluoropropene (C3F8) should be avoided because of potential endothelial toxicity [17]. Cycloplegia should be used to avoid pupillary block when gas injection is performed. If intracameral injection does not work, suture fixation would be the next treatment [4]. When cornea decompensation happened, penetrating keratoplasty or DSEK would be performed. Our reposition was successful by tamponading material into anterior chamber. Air resorbed too rapidly to allow the Descemet's membrane to reattach, so viscoelastic material was used. After 5 injections, Descemet's membrane reattached and cornea edema subsided.

Complication Repeated injections may result in intraocular pressure elevation and increased risk of intraocular inflammation or infection. This case was free of those complications. Some reports described decreased endothelial cell count [3, 12] which agree with our finding. A reasonable explanation for rapidly loss in endothelial cell density is mainly from Descemet's detachment except aging and filtering surgery which is mild. And endothelial pleomorphism and polymegathism improve over time after re-attachment of a DMD [18]. And also one complication happened in this case was Descemet's fold. Correct and immediate treatment would help to alleviate since it was really hard to get rid of Descemet's fold once it happened. DMD after trabeculectomy is an uncommon complication and can be masked by severe and extensive corneal edema

which should be distinguished from that caused by surgery and/or acute attack. It is important to consider this possibility since delayed diagnosis and treatment may lead to cornea scarring and decreased visual acuity. Furthermore, it is important to understand that Descemet's membrane detachment may persist days to weeks after the precipitating event. An awareness of the spectrum of injuries resulting from trabeculectomy should facilitate early diagnosis and treatment, particularly in situations where the etiology of the presenting eye condition is not readily apparent.

REFERENCES

- 1 Weve H. Separation of the membrane of Descemet after extraction of the lens. *Dutch J Med* 1927;72:398-400
- 2 Liu DT, Lai JS, Lam DS. Descemet's membrane detachment after sequential argon-neodymium: YAG laser peripheral iridotomy. *Am J Ophthalmol* 2002;134(4):621-622
- 3 Potter J, Zalatimo N. Descemet's membrane detachment after cataract extraction. *Optometry* 2005;76(12):720-724
- 4 Amaral CE, Palay DA. Technique for repair of Descemet membrane detachment. *Am J Ophthalmol* 1999;127(1):88-90
- 5 Fujimoto H, Mizoguchi T, Kuroda S, Nagata M. Intracorneal hematoma with Descemet membrane detachment after viscocanalostomy. *Am J Ophthalmol* 2004;137(1):195-196
- 6 Moehnke T, Wagner H. Descemet's membrane detachment attributed to the mechanical forces of airbag deployment. *Cont Lens Anterior Eye* 2009; 32(1):27-30
- 7 Mannan R, Jhanji V, Sharma N, Titiyal JS, Vajpayee RB. Intracameral C3F8 injection for Descemet membrane detachment after phacoemulsification in deep anterior lamellar keratoplasty. *Cornea* 2007;26(5):636-638
- 8 Mackool RJ, Holtz SJ. Descemet's membrane detachment. *Arch Ophthalmol* 1977;95:459-63
- 9 Hirano K, Kojima T, Nakamura M, Hotta Y. Triple anterior chamber after full thickness lamellar keratoplasty for lattice corneal dystrophy. *Cornea* 2001;20(5):530-533
- 10 Mahmood MA, Teichmann KD, Tomey KF, al-Rashed D. Detachment of Descemet's membrane. *J Cataract Refract Surg* 1998;24(6):827-833
- 11 Tu KL, Ibrahim M, Kaye SB. Spontaneous resolution of Descemet membrane detachment after deep anterior lamellar keratoplasty. *Cornea* 2006;25(1):104-106
- 12 Assi EI, Levkovich-Verbin H, Blumenthal M. Management of Descemet's membrane detachment. *J Cataract Refract Surg* 1995;21 (6): 714-717
- 13 Zusman NB, Waring III GO, Najarian LV, Wilson LA. Sulfur hexafluoride gas in the repair of intractable Descemet's membrane detachment. *Am J Ophthalmol* 1987;104(6):660-662
- 14 Acharjee HB, Acharjee KB, Medhi J, Altaf A. Descemet membrane detachment caused by inadvertent vancomycin injection. *Indian J Ophthalmol* 2008;56(3):241-243
- 15 Ellis DR, Cohen KL. Sulfur hexafluoride gas in the repair of Descemet's membrane detachment. *Cornea* 1995;14(4):436-437
- 16 Marcon AS, Rapuano CJ, Jones MR, Laibson PR, Cohen EJ. Descemet's membrane detachment after cataract surgery: management and outcome. *Cornea* 2002;109(12):2325-2330
- 17 Foulks GN, De Juan E, Hatchell DL, McAdoo T, Hardin J. The effect of perfluoropropane on the cornea in rabbits and cats. *Arch Ophthalmol* 1987;105(2):256-259
- 18 Patel DV, Phang KL, Grupcheva CN, Best JS, McGhee CN. Surgical detachment of Descemet's membrane and endothelium imaged over time by *in vivo* confocal microscopy. *Clin Exp Ophthalmol* 2004;32(5):539-544