

# Application of sustained delivery microsphere of cyclosporine A for preventing posterior capsular opacification in rabbits

Cheng Pei<sup>1</sup>, Yi Xu<sup>2</sup>, Jean Xin. Jiang<sup>3</sup>, Li-Jun Cui<sup>1</sup>, Li Li<sup>1</sup>, Li Qin<sup>1</sup>

**Foundation items:** National Natural Science Foundation of China (No. 81070721); Fundamental Research Funds for the Central Universities

<sup>1</sup> Department of Ophthalmology, the First Affiliated Hospital of Xi'an Jiaotong University, Xi'an 710061, Shaanxi Province, China

<sup>2</sup> Disease Control Center of Shaanxi Province, Xi'an 710054, Shaanxi Province, China

<sup>3</sup> University of Texas Health Science Center at San Antonio, Texas 78229, USA

**Correspondence to:** Cheng Pei. Department of Ophthalmology, the First Affiliated Hospital of Xi'an Jiaotong University, Xi'an 710061, Shaanxi Province, China. peich71@163.com

Received: 2012-08-06 Accepted: 2012-12-20

## Abstract

• **AIM:** To explore the inhibitory effect of a sustained cyclosporin A (CsA) delivery microsphere (CsA-MS) on posterior capsular opacification (PCO) in rabbit eyes after cataract extraction.

• **METHODS:** Twenty New Zealand white rabbits accepted cataract extraction plus intraocular lens implantation and their left eyes were intraoperatively injected CsA-MS prepared using polymer poly(lactid)glycolic acid (PLGA) as a carrier and their right eyes were injected with empty MS. The changes in cornea, anterior chamber reaction, intraocular pressure, PCO and CsA concentration in aqueous humor were examined postoperatively and all the eyes were enucleated 3 months after surgery for histopathological and morphological examination with light microscopy and electron microscopy.

• **RESULTS:** Conjunctival hyperemia, corneal edema, intraocular pressure and anterior chamber response of experimental and control eyes were similar, while PCO in CsA-MS injected eyes was greatly improved compared with that in control eyes. Posterior capsules in CsA-MS injected eyes were smooth and lens epithelial cells (LEC) did not proliferate significantly ( $P > 0.05$ ), while LEC in posterior capsule of control eyes had different degrees of proliferation and cortical regeneration. LEC in CsA-MS injected eyes were not functionally active and underwent apoptosis, whereas LEC in control eyes were functionally active ( $F$ -test,  $P = 0.025$ ). In addition, the corneal

ultrastructure showed no differences between CsA-MS and MS injected eyes.

• **CONCLUSION:** CsA-MS has high bioavailability in rabbit eyes and could inhibit postoperative PCO occurrence and development during the study period, suggesting that CsA-MS may be a promising, effective and safe administration route to prevent PCO in clinic.

• **KEYWORDS:** sustained cyclosporine A delivery microsphere; posterior capsular opacification; rabbit eyes

DOI:10.3980/j.issn.2222-3959.2013.01.01

Pei C, Xu Y, Jiang JX, Cui LJ, Li L, Qin L. Application of sustained delivery microsphere of cyclosporine A for preventing posterior capsular opacification in rabbits. *Int J Ophthalmol* 2013;6(1):1-7

## INTRODUCTION

Posterior capsular opacification (PCO) is the leading cause for visual acuity decrease after cataract extraction and intraocular lens implantation [1]. Postoperative PCO is resulted from proliferation and degenerative fibrosis of residue lens epithelial cells (LEC) [2]. Thus, how to remove or suppress the proliferation and migration of LEC is the key for PCO treatment.

Currently, a variety of drugs such as anti-metabolites, anti-inflammatory drugs, heparin, etc. have been proved to be effective in preventing PCO. Particularly, anti-metabolites have drawn great attention due to their reliable effects [3,4]. Cyclosporine A (CsA) is a lipophilic cyclic polypeptide composed of 11 amino acids and with strong, specific immune inhibitory effect. A large number of studies have shown that CsA also has a regulatory role in cell apoptosis. Cortina *et al* [5] reported that CsA could inhibit human LEC proliferation in a dose dependent manner when its concentration is greater than  $2.5 \mu\text{mol/L}$ , but the underlying mechanisms are not yet clear. Recent *in vitro* studies [6,7] have indicated that besides its immunosuppressive effects on T lymphocyte proliferation and differentiation due to inhibiting IL-2 gene expression, the molecular mechanism of pharmacological effects of CsA as an immunosuppressive agent is related to its stimulating effect on expression of TGF- $\beta$ , which not only is the most important immunosuppressive cytokine in aqueous humor and vitreous body, but also plays a key role in the process of inducing

anterior chamber-associated immune deviation (ACAID), providing a new evidence for topical application of CsA in eyes.

Although many drugs have been confirmed in *in vitro* and *in vivo* experiments to have good suppressive effects on LEC proliferation, their delivery carriers normally have poor drug carrying ability, leading to instability of drug binding and molecular conformation changes, which inevitably decreases their efficacy. We hope to find a drug carrier that not only can effectively bind to drugs, but also preserve or improve drugs' therapeutic effects.

Application of sustained CsA release formulations in ophthalmology has entered the animal testing stage. The sustained drug delivery system is a long-term, quantitative, new drug-implanting agent. It can be prepared in different size and shape using degradable or non-degradable materials and placed in the targeted position in eyes, thus maintaining an effective, therapeutic drug concentration suitable for eye diseases that require long-term drug administration. CsA-containing eye implanting agents will help to release CsA slowly and maintain its effective concentration at certain level for a longer period, by which avoiding systemic administration caused toxicity and effectively enhancing its topical efficacy.

In present study, we utilized polymer poly(lactic-glycolic acid) (PLGA) as the encapsulation material, prepared CsA as PLGA microsphere, observed its feasibility as a drug carrier and further explored the effects of CsA microsphere (CsA-MS) on PCO after cataract extraction and its toxicity to other eye tissues in rabbits.

### MATERIALS AND METHODS

**Materials** Waters Alliance high performance liquid chromatography (HPLC) was from Waters Company, USA. MS1 Minivortex was from Guangzhou Laboratory Co., Ltd. Anke TGL-16G centrifuge was from Shanghai Anting Scientific Instrument Factory. BF-2000 Nitrogen Drier was from Beijing Octagon Century Technology Co., Ltd. Ophthalmic surgical microscope was Suzhou Crane Brand YZ-III. Haag-Streit900 slit lamp was from Switzerland. Zeiss optical microscope was from German. Hitachi H-600 electron microscope was from Japan. Topcon non-contact tonometer was from Japan. AMO-EP intraocular lens were from USA. CsA-MS was prepared by Tianjin Medicine Institute. Control CsA with purity  $\geq 98.5\%$  was from Sigma. HPLC grade methanol and acetonitrile were from TEDIA. 3% hydroxypropyl methylcellulose from Tianjing Jinming Eye Inc. was used as viscoelastic.

### Methods

**Animal grouping and treatment** Twenty healthy adult male and female New Zealand rabbits weighing 2-3kg from Animal Experimental Center of Xi'an Jiaotong University were used in the study. Their eyes were normal in slit lamp

examination. Their left eyes were served as experimental group and right eyes were used as the control. All eyes were treated with cataract extraction plus intraocular lens implantation. CsA-MS was injected postoperatively into the lens capsular sac in experimental eyes or empty MS in the control eyes.

**CsA-MS Microspheres (MS)** were provided by the Biomedical Engineering Institute of Chinese Academy of Medical Sciences. CsA-MS composed of CsA and its carrier PLGA prepared from polylactic acid (PLA) and polyglycolic acid (PGA), and had mass percentage of 20%, encapsulation rate of 97.5% and expected CsA releasing time of 12 weeks. Blank MS were white particulate PLGA. All MS were disinfected with 24 hours of ethylene oxide fumigation, and reserved for 1 week for future use.

**Preparation of CsA-MS** CsA-MS was prepared using the solvent extraction-evaporation technique. Briefly, aluminium stearate was dissolved in the soybean oil (20g/L) by heating up to 140°C, which was then cooled down to room temperature and used as the oil phase. 1g of CsA (dried powder) was dispersed in 3 125g of the oil phase (including 40g/L Span80) to form a smooth S/O type suspension. 1g of the suspension was then added into 7g of PLGA-ACN solution to form S/O/O emulsion. The emulsion was then sprayed into 70g of mineral oil which contained 1.5g/L Span 80 to get the S/O/O emulsion which was mixed thoroughly by continuous stirring at 400-500r/min for 24 hours, followed by evaporating of CAN. The hardened microspheres containing CsA were filtered through the 50 $\mu$ m nylon membrane and washed with n-hexane, 20g/L Tween-80 and water 3 times respectively, which was then followed by vacuum drying for 24 hours. The average particle size of the CsA-MS was 63.22 $\mu$ m, the span was 1.57 $\mu$ m, with the drug loading dosage of 7.50% and the entrapment efficiency of 37.5%. CsA-MS was then suspended in hydroxypropyl methyl cellulose (0.2mg CsA-MS per 0.1mL suspension medium) and administered to rabbit eyes as described. While 0.2mg of the empty MS per 0.1mL suspension medium was used in the control group.

**Operation procedure** Rabbit eyes were preoperatively dilated with tropine lactam compound every 10 minutes for three times. Rabbits were anesthetized by intramuscularly injecting 1-1.5mg/kg 2:1 (v/v) mixture of ketamine hydrochloride and chlorpromazine. Eyelids were opened with blepharostat. Conjunctiva sac was fully flushed with diluted gentamicin solution. A 3.2mm transparent corneal incision and an auxiliary incision were created at 11 and 2 positions, respectively. About 0.1mL of 3% hydroxypropyl methylcellulose viscoelastic was injected into anterior chamber and a continuous circular capsulorhexis with mouth diameter of about 3-4mm was created. After fully separated with water, lens nucleus and residual cortex were extracted.

**Table 1 Postoperative response evaluation criteria**

Grade	Corneal edema	Opacity of aqueous humor	Posterior capsule
Grade 0 (-)	No corneal edema	No cells in anterior chamber	No capsular opacity
Grade 1 (±)	Mild corneal edema, corneal thickness increased by 1.25-fold	Cells seen in aqueous humor	Mild capsular opacity, but fundus can be seen
Grade 2 (+)	Moderate corneal edema, corneal thickness increased by 1.33-fold	Formation of fibrinous exudation in anterior chamber	Moderate capsular opacity, partial fundus can be seen
Grade 3 (++)	Severe corneal edema, corneal thickness increased by 1.5-fold	Hypopyon seen in anterior chamber	Obvious capsular opacity, fundus cannot be seen or peripheral cortex hyperplasia

**Table 2 Postoperative comparison of cornea and aqueous humor of experimental and control eyes**

Group	2 days	5 days	7 days	14 days	1 month	2 months
Experimental eyes						
Corneal edema	+	+	±	-	-	-
Aqueous humor opacity	+	+	±	-	-	-
Control eyes						
Corneal edema	+	+	±	-	-	-
Aqueous humor opacity	+	±	±	-	-	-

**Table 3 Comparison of preoperative and postoperative intraocular pressure**

Group	Preop. IOP (mmHg)	Postop. IOP (mmHg)			
		1 day	3 days	5 days	15 days
Experimental eyes	14.67±1.65	20.76±3.06	15.10±1.78	14.41±1.42	13.48±1.88
Control eyes	13.72±2.07	21.25±3.56	14.74±0.97	14.57±0.78	13.29±1.69

3% hydroxypropyl methylcellulose viscoelastic was again injected into anterior chamber and conjunctiva sac to expand the transparent corneal incision. Artificial lens were intraocularly implanted into capsular sac. After adjusting the position of artificial lens, CsA-MS or MS was injected into capsular sac.

One day after surgery, tobramycin and dexamethasone eye drops were given 4 times a day and 1% atropine eye drops was given twice a day for 2 weeks. The cornea, anterior and posterior capsules were observed by slit-lamp examination 1 day-14 days, 1 month, 2 months and 3 months after the surgery. Intraocular pressure was measured at 2, 5, 15 days, 1 month and 2 months after surgery. CsA concentration in aqueous humor was determined at 1 week, 2, 4, 6, 8 and 10 weeks after surgery using HPLC.

**Measurement of CsA concentration in the aqueous humor by HPLC** Chromatography was used to determine the concentration of CsA in the aqueous humor of rabbit eyes. Briefly, 0.2mL aqueous humor sample was added into a 1.5mL centrifuge tube, which was followed by adding 600µL of ether. The tube was vortexed thoroughly for 1 minute to extract the organic phase which contains CsA. The extraction procedure was repeated again. The organic solution was then dried at 35°C by N<sub>2</sub> gas and dissolved in 200µL nitrile-water (v:v=67:33). The solution was then centrifuged at 9 000r/min for 3 minutes, supernatant was collected and added to the chromatography column (Century SIL C18-BDS, 4.6mm×150mm, 5µm) with nitrile-water (v:v=67:33) as the elution buffer at the flow rate of 1.0mL/min and column temperature was kept at 60°C. Finally, collected samples were examined using detection wavelength at 210nm.

**Observation and assessment criteria** Rabbit cornea, anterior chamber and lens posterior capsule were examined

using slit lamp method and fundus was examined using ophthalmoscopy. Postoperative response evaluation criteria are listed in Table 1.

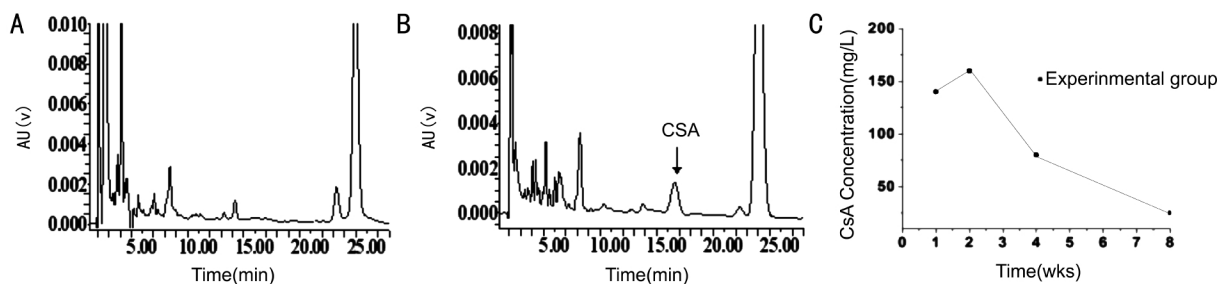
**Tissue collection and specimen treatment** Twelve weeks after surgery, rabbits were sacrificed by injecting 10mL air embolism, their eyeballs were rapidly extracted and their cornea and posterior capsules were evenly cut into two pieces. One piece was fixed with 10% formaldehyde at 4°C for 24 hours, watered for 8 hours, dehydrated with gradient alcohol, waxed, embedded, sliced to 4-5µm, stained with HE and examined under a light microscope. The other piece was fixed with 4% glutaraldehyde for 3 hours followed by 1% osmium tetroxide, dehydrated with gradient alcohol acid, epoxy resin-embedded, sliced, stained lead citrate-uranyl acetate and observed by transmission electron microscopy.

**Statistical Analysis** Data were analyzed by the Statistical Package for the Social Sciences version 13.0 (SPSS 13.0). Numerical variable was presented as mean ±SD, repeated measures analysis of variance (ANOVA) test was performed and nonparametric test was conducted with ranked data.  $P < 0.05$  was assumed to be statistically significant.

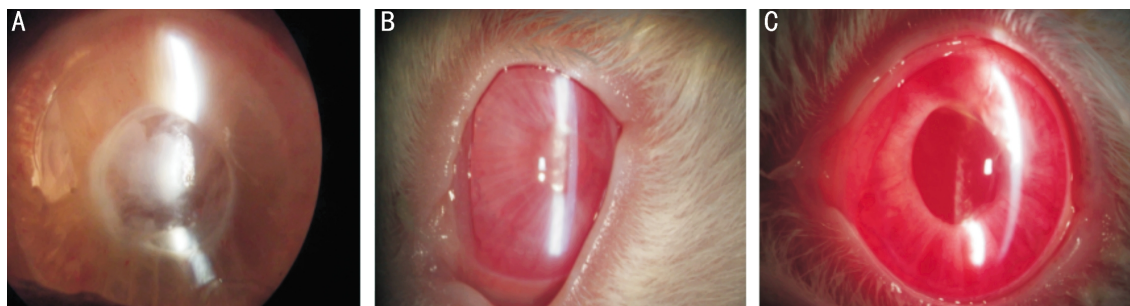**RESULTS**

**Slit Lamp Observation** After surgery, fibrinous exudation was found in anterior chamber of both experimental and control eyes especially at 2-7 days of post-operation and gradually absorbed within 2 weeks. In addition, different degree of corneal edema was found in some eyes, and cornea restored transparent at 1 week of post-operation (Table 2).

**Intraocular Pressure** Intraocular pressure in both experimental and control eyes was increased one day after surgery ( $F=6.27$ ,  $P < 0.05$ ), and rapidly returned to normal ( $P > 0.05$ ). In addition, intraocular pressure was not different between the experimental and control eyes ( $P > 0.05$ ), as shown in Table 3.



**Figure 1 HPLC map of CsA in aqueous humor samples** A: MS control group; B: CsA-MS experimental group; C: Postoperative CsA concentration in aqueous humor with time.



**Figure 2 Images of posterior capsule of control and experimental eyes after operation** A: Dense fibrosis of posterior capsule of control eyes 3 months after operation; B: Posterior capsular epithelial cell lay of control eyes 3 months after operation; C: Images of posterior capsule of experimental eyes 4 weeks after operation, showing mild opacity.

**CsA Concentration**

**System suitability** Under the HPLC conditions described in the Materials and Methods, we observed a good distinctive peak of CsA. The resolution of sample peak and impurity peak was larger than 1.5, theoretical plate number was bigger than 2 400, while the retention time of CsA was 15.23 minutes (Figures 1A and B). The data suggest that our designed HPLC system was able to detect CsA concentration in a very small volume of samples such as aqueous humor. Pharmacokinetic parameters of CsA in aqueous humor of rabbit eyes were shown (Table 4). As shown in Figure 1C, CsA concentration in aqueous humor was 146mg/L at 1 week of post-operation, reached its peak at 2 weeks of post-operation and then gradually decreased to 0.15mg/L at 10 weeks of post-operation.

**PCO** PCO appeared in control eyes at 2 weeks of post-operation, showing localized capsular folds and fibrosis, expanded at 2 months of post-operation, showing pearl-type PCO and developed rapidly. At three months of post-operation, most control eyes showed dense fibrosis (Figure 2A) or obvious epithelial opacity (Figure 2B). By contrast, only mild PCO appeared in 6 experimental eyes at 4 weeks of post-operation and developed very slowly (Figure 2C). The dynamic changes in anterior segment of experimental eyes relative to the landmark suture are shown in Figures 3A-G.

Twelve weeks after surgery, 13 out of 20 experimental eyes had no PCO, accounting for 65% , and 7 had PCO, accounting for 35%. Among them, 6 had grade 1 PCO and 1 had grade 2 PCO. In control eyes, 5 out of 20 had no PCO,

**Table 4 Pharmacokinetic parameters of CsA in aqueous humor of rabbit eyes**

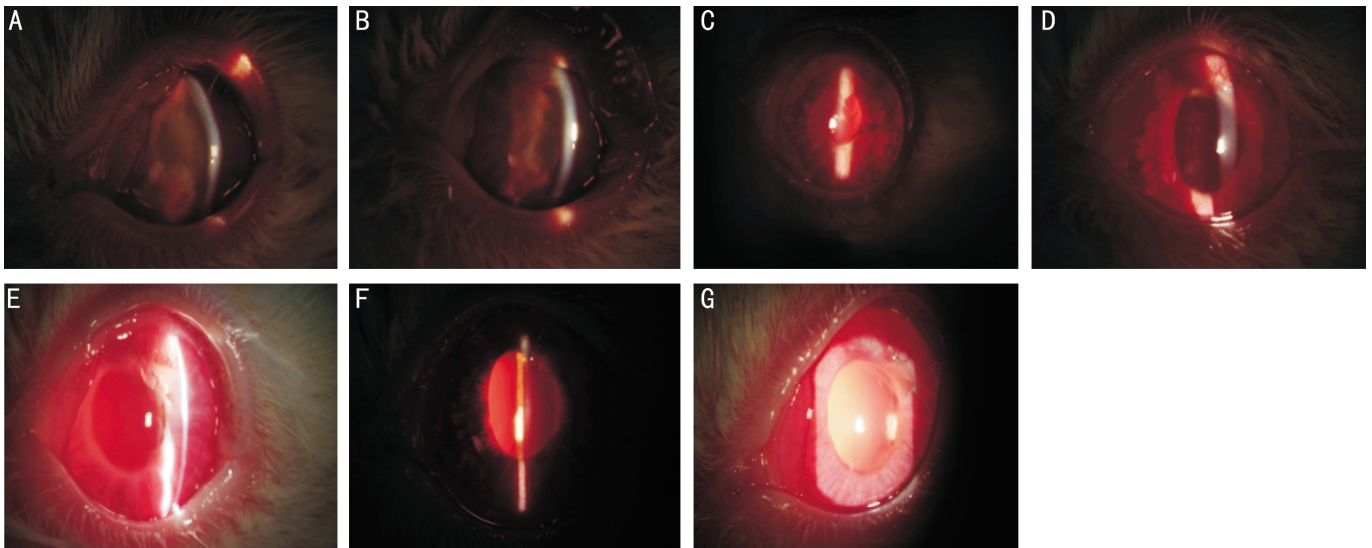
Parameters	Unit	Experimental group
t1/2 $\alpha$ (distribution half-life)	hour	69.32±0.01
t1/2 $\beta$	hour	69.32±0.01
CL	mL/h/kg	13.67±0.82
AUC0-X	mg/L·h	70.32±7.35
AUC0- $\infty$	mg/L·h	111.88±8.32
K12 (Distribution rate constant)	1/h	0.02
Ka (Constant of uptake rate)	1/h	0.01
Cmax	mg/L	0.24±0.01

**Table 5 PCO formation in rabbit eyes 12 weeks after ECCE plus IOL**

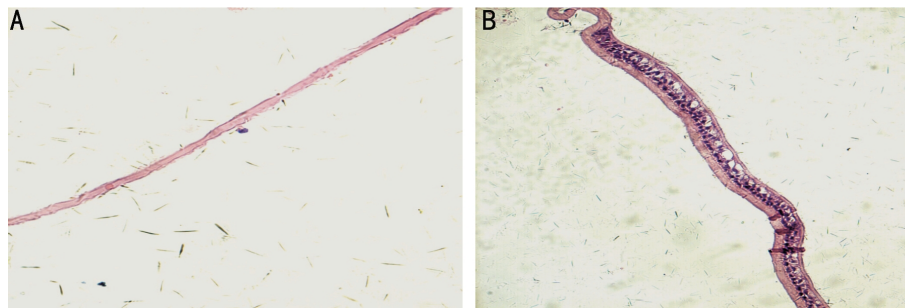
Group	Grade 0	Grade 1	Grade 2	Grade 3	n
Experimental eyes	13	6	1	0	
Control eyes	5	8	4	3	

accounting for 25%, and 15 had PCO, accounting for 75%. Among them, 8 eyes had grade 1 PCO, 4 had grade 2, and 3 had grade 3 PCO. The incidence of PCO significantly differed between the experimental and control eyes (*F*-test, *P*=0.025), as shown in Table 5.

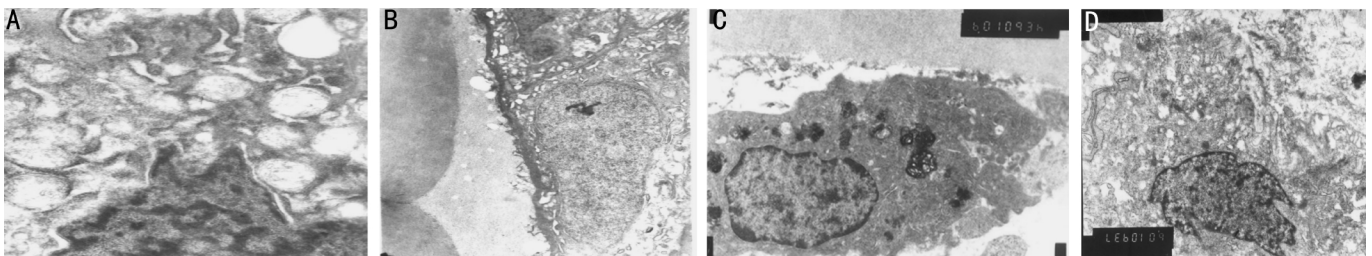
**Histopathological Observation** HE staining indicated that 12 weeks after surgery, corneal endothelial cell layer of experimental and control eyes was smooth, continuous, and intact. Posterior capsule of experimental eyes was smooth. Lens epithelial cells showed no obvious proliferation. Residual cells markedly degenerated. Cell membrane was incomplete and cell-cell contact was not found (Figure 4A). By contrast, control eyes showed significant lens epithelial cell proliferation and migration (Figure 4B).



**Figure 3** The dynamic changes in anterior segment of experimental eyes relative to the landmark suture marked on the temporal conjunctiva A: One day after operation; B: Three days after operation; C: One week after operation; D: Two weeks after operation; E: Four weeks after operation; F: Six weeks after operation; G: Eight weeks after operation.



**Figure 4** HE staining of posterior capsule at 12 weeks after operation ( $\times 400$ ) A: Experimental eyes; B: Control eyes.



**Figure 5** Electron microscopical observation at 12 weeks of post-operation ( $\times 10000$ ) A: Lens epithelial cells in experimental eyes; B: Lens epithelial cells in control eyes; C: Corneal endothelial cells in experimental eyes; B: Corneal endothelial cells in control eyes.

**Electron Microscopic Observation** Twelve weeks after surgery, lens epithelial cells of experimental eyes showed smaller size, significantly reduced nuclear volume, condensed nuclear chromatin, higher electron density, swollen mitochondria, and expansion of rough endoplasmic reticulum (Figure 5A). By contrast, lens epithelial cells of control eyes showed oval-shaped nucleus, clear nuclear membrane boundaries, clear nuclear filament and its attached chromatins in different sizes of block, rough reticulum in cytoplasm, free ribosome, mitochondria, Golgi apparatus, microtubules and microfilaments, intact structural organelles as well as close connections between cells (Figure 5B). Corneal endothelial cells of experimental and control eyes were flat and contained many cytoplasmic organelles and abundant Golgi apparatus (Figures 5C and D).

## DISCUSSION

Eyeball is a relatively exposed organ. Its diseases are normally treated with topical drug administration. Currently, topical CsA is mainly administrated in the form as eye drops. Because CsA is a hydrophobic compound with large molecular weight, its permeability in eyes is poor [8,9]. Because its poor permeability to hydrophilic substrate layer, its concentration in aqueous humor and other tissues is relatively low compared to the required therapeutic concentration [10,11], affecting its topical therapeutic effects. Several studies [9,12] have reported that only 8% of CsA in eye drops could reach corneal endothelium, only 1% could reach anterior chamber, with concentration in the posterior chamber such as aqueous humor and vitreous far less than the required therapeutic level. Moreover, 50%-90% of drugs

given through conventional administration lost their effects due to tear drainage, absorption of nasopharyngeal mucosa and other factors. Low bioavailability and short action duration affect the topical efficacy of CsA. CsA subconjunctivally implanted also has low permeability to eye tissues. With the development of medical technology, more and more new sustained CsA release formulations have been developed, which significantly broadened CsA application in eyes. New ophthalmic preparations as carriers of sustained CsA release formulations can effectively enhance the topical effect of CsA in eyes, especially CsA-containing implants is conducive to the slow release of CsA in eyes and could maintain an effective concentration for long time and avoid the side effects of systemic CsA administration. Thus, it is important for inhibiting high-risk corneal graft rejection<sup>[13,14]</sup>, treatment of chronic grapes meningitis<sup>[11,15]</sup>, proliferative vitreoretinopathy<sup>[16,17]</sup> and other chronic diseases that require long-term medication.

In addition, limited by tear drainage, medication time and methods, patient cooperating degree, etc., it is hard to maintain stable drug concentrations within the eyes using traditional eye drops. Other delivery methods to prevent PCO are mainly administrating drugs by intra-operatively lavaging drugs once into capsular sac or injecting drugs subconjunctivally. Drug concentration is significantly decreased short after the surgery with aqueous humor discharging, which can greatly reduce the effective concentration. PLGA is a biological engineering copolymer synthesized from polylactic acid (PLA) and polyglycolic acid (PGA). It possesses good drug release function and has been widely used recently<sup>[18]</sup>, such as orthopedic, urology and others. Furthermore, the sustained drug delivery system can gradually release drugs along with degradation of biodegradable carriers within a certain period of time, which provides a relatively stable drug concentration within eyes. Microspheres of CsA and indomethacin have good compatibility with eyes, and can steadily release drugs into eyes, thus effectively inhibiting corneal transplant rejection, uveitis, etc. Up to date, no toxic effects on the anterior and posterior chambers have been reported<sup>[19,20]</sup>.

To our knowledge, this study is the first report using PLGA as a carrier to postoperatively deliver CsA into capsular sac after extra-capsular cataract extraction plus intraocular lens implantation. CsA accounts for 20% of microspheres, which can maintain long-term drug release<sup>[21]</sup>. The results indicated that CsA reached its maximal concentration of  $(71.32 \pm 5.90)$  ng/mL 2 weeks after surgery in anterior chamber and kept being released at 4, 8 and 10 weeks, consistent with a previous report<sup>[22]</sup>. The sustained CsA concentration is possibly related to the release process of microspheres. In

detail, at the early implantation stage, CsA on the surface of microsphere was first dissolved, and internal CsA was gradually released with the carrier biodegrading, together leading to CsA concentration reached its peak at 2 weeks od post-operation. Both experimental and control eyes showed mild corneal edema, anterior chamber Tyndall (++~+++), and anterior chamber fibrinous exudation. Experimental eyes showed slightly more severe symptoms, possibly due to poorer blood-aqueous barrier function and transient response to CsA-MS. Two weeks after the surgery, cornea of both experimental and control eyes became transparent, fibrinous exudation in the anterior chamber was absorbed. There was no difference between the experimental and control eyes. Intraocular pressure in both experimental and control eyes was temporarily increased at 2 days of post-operation due to postoperative response, but there was no significant difference between them ( $P > 0.05$ ).

Twelve weeks after surgery, experimental and control eyes had significantly different PCO ( $P < 0.01$ ). Histopathological examination showed that experimental eyes had significantly less proliferation of lens epithelial cells and fibrin deposition than control eyes. Electron microscopy confirmed that the morphological characteristics of lens epithelial cells in the experimental eyes were severe mitochondria vacuolization and shortened crest, irregular cell shape, ceased mitosis, inactive cellular function and partial cell apoptosis. By contrary, those in the control eyes were larger lens epithelial nuclei, enriched euchromatin and active cellular function. The results indicated that injecting CsA-MS into anterior chamber is an effective drug delivery method and 20% CsA-MS is not significantly toxic to cornea.

Taking together, injecting CsA-MS into capsular sac significantly inhibited rabbit lens PCO after extra-capsular cataract extraction. CsA-MS had no toxicity to the surrounding tissues and only caused mild chronic inflammatory reaction of rabbit ocular tissues, which was waned away with time, indicating that CsA-MS has good biocompatibility in eyes. Meanwhile, the CsA-MS delivery system has the following advantages: 1) drug is economically delivered and had higher bioavailability. The topical application of CsA-MS may not only avoid systemic side effects, but also maximize the use of drugs; 2) Drug can be stably released for a long time. Since the drug release rate and period is closely related to the ratio of drug/carrier, drug content and CsA-MS shape and volume, adjusting the preparation process based on the clinical need can obtain the most satisfactory release effect. CsA-MS can be released in a certain period of time with the biodegradable carrier gradually degrading and provide relatively stable and sustained intraocular drug concentration within the eyes; 3)

the method is non-invasive and convenient. CsA-MS injection is conducted intraoperatively and easy to perform. Because the carrier is degraded naturally in the eye, no further surgery is needed to remove the carrier. In addition, the method can avoid inconvenience caused by frequently applying eye drops, and is especially suitable for infants and young kids who normally have strong lens epithelial cell proliferation and high incidence of post-cataract. In the future, we will gradually improve the PLGA molecular weight and drug configuration to further extend the sustained release time and CsA concentration in aqueous humor, hoping this new CsA-MS sustained release system can be a more effective topical drug administrating route in PCO prevention and treatment in clinic.

#### REFERENCES

- 1 Schaumberg DA, Dana MR, Christen WG, Glynn RJ. A systematic overview of the incidence of posterior capsular opacification. *Ophthalmology* 1998;105(7):1213-1221
- 2 Apple DJ, Solomon KD, Tetz MR, Assia EI, Holland EY, Legler UF, Tsai JC, Castaneda VE, Hoggatt JP, Kostick AM. Posterior capsule opacification. *Surv Ophthalmol* 1992;37(2):73-116
- 3 You YS, Lim SJ, Chung HS, Lee YG, Kim CY, Hong YJ. The effective concentration and exposure time of mitomycin-C for the inhibition of lens epithelial cell proliferation in rabbit eyes. *Yonsei Med J* 2000;41 (2): 185-189
- 4 Inan UU, Oztürk F, Kaynak S, Kurt E, Emiroglu L, Ozer E, Ilker SS, Güler C. Prevention of posterior capsule of a dexamethasone anterior segment drug delivery system in patients opacification by intraoperative single dose pharmacologic agents. *J Cataract Refract Surg* 2001;27 (7): 1079-1087
- 5 Cortina P, Gómez-Lechón MJ, Navea A, Menezo JL, Terencio MC, Diaz-Llopis M. Diclofenac sodium and cyclosporin A inhibit human lens epithelial cell proliferation in culture. *Gracés Arch Clin Exp Ophthalmol* 1997;235(3):180-185
- 6 Prashar Y, Khanna A, Sehajpal P, Sharma VK, Suthanthiran M. Stimulation of transforming growth factor-beta 1 transcription by cyclosporine. *FEBS Lett* 1995;358(2):109-112
- 7 Shin GT, Khanna A, Ding R, Sharma VK, Lagman M, Li B, Suthanthiran M. *In vivo* expression of transforming growth factor-beta1 in humans: stimulation by cyclosporine. *Transplantation* 1998;65(3):313-318
- 8 BenZera D Maftzir G. Ocular penetration of cyclosporin A. The rabbit eye. *Invest Ophthalmol Vis Sci* 1990;31(7):1362-1366
- 9 BenEzra D, Maftzir G, de Courten C, Timonen P. Ocular penetration of cyclosporin A. III: The human eye. *Br J Ophthalmol* 1990;74(6):350-352
- 10 Mosteller MW, Gebhardt BM, Hamilton AM, Kaufman HE. Penetration of topical cyclosporine into the rabbit cornea, aqueous humor, and serum. *Arch Ophthalmol* 1985;103(1):101-102
- 11 Nussenblatt RB, Dinning WJ, Fujikawa LS, Chan CC, Palestine AG. Local cyclosporine therapy for experimental autoimmune uveitis in rats. *Arch Ophthalmol* 1985;103(10):1559-1562
- 12 Larkin DF. Corneal allograft rejection. *Br J Ophthalmol* 1994;78 (8): 649-652
- 13 Milani JK, Pleyer U, Dukes A, Chou HJ, Lutz S, Rückert D, Schmidt KH, Mondino BJ. Prolongation of corneal allograft survival with liposome-encapsulated cyclosporine in the rat eye. *Ophthalmology* 1993; 100(6):890-896
- 14 Oh C, Apel AJ, Saville BA, Cheng YL, Rootman DS. Local efficacy of cyclosporine in corneal transplant therapy. *Curr Eye Res* 1994;13 (5): 337-343
- 15 Pearson PA, Jaffe GJ, Martin DF, Cordahi GJ, Grossniklaus H, Schmeisser ET, Ashton P. Evaluation of a delivery system providing long-term release of cyclosporine. *Arch Ophthalmol* 1996;114(3):311-317
- 16 Charteris DG, Hiscott P, Robey HL, Gregor ZJ, Lightman SL, Grierson I. Inflammatory cells in proliferative vitreoretinopathy subretinal membranes. *Ophthalmology* 1993;100(1):43-46
- 17 Enyedi LB, Pearson PA, Ashton P, Jaffe GJ. An intravitreal device providing sustained release of cyclosporine and dexamethasone. *Curr Eye Res* 1996;15(5):549-557
- 18 Chen YJ, Xu XY, Zhou JP. Progresses in lactic acid/glycolic acid microspheres research. *Zhongguo Yaoke Daxue Xuebao* 2007;38(2):186-189
- 19 Salgueiro A, Egea MA, Espina M, Valls O, García ML. Stability and ocular tolerance of cyclophosphamide-loaded nanospheres. *J Microencapsul* 2004;21(2):213-223
- 20 Pignatello R, Bucolo C, Puglisi G. Ocular tolerability of eudragit RS100 and RL100 nanosuspensions as carriers for ophthalmic controlled drug delivery. *J Pharm Sci* 2002;91(12):2636-2641
- 21 Yan L, Sun JD, Bi DZ. Progresses in preparation of polylactic acid/poly(lactic glycolic acid) copolymer microspheres and its quality affecting factors. *Foreign Medical Sciences (Section on Pharmacy)* 2001;28 (3):165-167
- 22 Liu ZS, Xie LX, Shi WY, Li SW, Cai Q, Bei JZ, Wang SG. Drug release and biocompatibility of cyclosporine A drug delivery system implanting into the anterior chamber. *Zhonghua Yanke Zazhi* 2004;40(2):110-112