

# Green –light fundus autofluorescence in diabetic macular edema

*Lukas Reznicek, Simeon Dabov, Christos Haritoglou, Anselm Kampik, Marcus Kernt, Aljoscha S Neubauer*

Department of Ophthalmology, Ludwig Maximilians University, Mathildenstr. 8, Munich 80336, Germany

**Correspondence to:** Lukas Reznicek. Department of Ophthalmology, Ludwig-Maximilians-University, Klinikum der Universität München, Campus Innenstadt, Mathildenstrasse 8, D-80336 Munich, Germany. Lukas.Reznicek@med.uni-muenchen.de

Received: 2012-09-20 Accepted: 2013-12-30

## Abstract

- **AIM:** To evaluate the role of central green–light fundus autofluorescence (FAF) in diabetic macular edema(DME).
- **METHODS:** A consecutive series of 92 study eyes with diabetic retinopathy were included. Out of those, 51 diabetic eyes had DME and were compared to 41 diabetic eyes without DME. In all subjects, green –light FAF images were obtained, quantified and classified into various FAF patterns. Cross–sectional optical coherence tomography (OCT) scans were obtained for evaluation of Inner/Outer segment (IS/OS) layer integrity, measurements of central RPE –IS/OS layer thickness as well as classification of DME into various subtypes.
- **RESULTS:** Mean central green–light FAF intensity of eyes with DME ( $1.289 \pm 0.140$ )log did not significantly differ from diabetic patients without DME ( $1.317 \pm 0.137$ )log. Most classifiable FAF patterns were seen in patients with cystoid DME. Mean central retinal thickness (CRT) of all study eyes with DME was ( $501.9 \pm 112.4$ ) $\mu$ m compared to ( $328.2 \pm 27.0$ ) $\mu$ m in diabetic patients without DME. Patients with DME had significantly more disrupted photoreceptor IS/OS layers than diabetic patients without DME (28/51 vs 5/41,  $P < 0.001$ ). Mean RPE –IS/OS thickness of patients with DME ( $60.7 \pm 14.1$ ) $\mu$ m was significantly ( $P < 0.001$ ) lower than in diabetic eyes without DME ( $73.5 \pm 9.4$ ) $\mu$ m. Correlation analysis revealed non–significant correlations of green –light FAF intensity and OCT parameters in all subtypes of DME.
- **CONCLUSION:** Our results indicate a poor correlation of central green–light FAF intensity with CRT, IS/OS layer integrity or RPE –IS/OS layer thickness in diabetic patients with or without DME and its various subtypes. Thus, central green –light FAF is not suitable for detection of retinal thickening in DME.

• **KEYWORDS:** diabetic macular edema; fundus autofluorescence; optical coherence tomography

**DOI:10.3980/j.issn.2222-3959.2013.01.16**

Reznicek L, Dabov S, Haritoglou C, Kampik A, Kernt M, Neubauer AS. Green–light fundus autofluorescence in diabetic macular edema. *Int J Ophthalmol* 2013;6(1):75–80

## INTRODUCTION

Diabetic macular edema (DME) as a common complication of diabetic retinopathy is known to be the leading cause for visual impairment for the diabetic patient [1–4]. The most common clinical presentations of DME are blurred vision, metamorphopsias, floaters, changes in contrast sensitivity, photophobia, changes in color vision and scotoma. DME can be classified descriptively into focal and diffuse DME. The latter subtype is supposed to be an extensive or generalized leakage from the posterior capillary bed due to a breakdown of the inner blood-retinal barrier whereas focal DME results from extravasated fluid from individual microaneurysms [5]. A clear distinction between focal and diffuse edema is not always possible [6]. The pathophysiology of DME is not completely understood. Biochemical changes are supposed to lead to endothelial damage with altered leucocyte function with a consecutive breakdown of the blood-retinal barrier, dilated capillaries, microaneurysms and loss of pericytes. Resulting vascular leakage of fluid and serum proteins, plasma constituents and lipids into the intraretinal space lead to increased retinal thickness and DME [7–11]. Ophthalmologic treatment options additionally to glycemic control and adjustment of hypertension and hyperlipidaemia are laser photocoagulation, intravitreal Anti-VEGF, intravitreally injected or implanted steroids and pars-plana vitrectomy for refractory cases or proven traction [12–16]. Assessment of DME can be done by slit-lamp biomicroscopy or by stereoscopic macular photographs. Non-invasive imaging techniques such as optical coherence tomography (OCT) are of high value for diagnosis of DME and provide qualitative and quantitative data useful as progression parameters [17–19]. Fundus autofluorescence (FAF) has been shown to be a valuable tool for detection and monitoring of diabetic

maculopathy, hereditary retinal disorders, geographic atrophy secondary to AMD and uveitic CME [20-24].

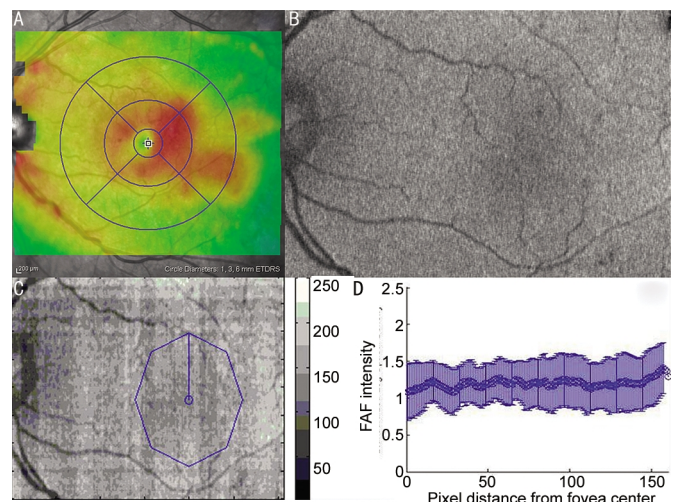
Previous works suggest blue-light FAF to be a non-invasive imaging technique to detect CME in diabetic retinopathy. Specific FAF patterns observed in diabetic patients with DME seem to correlate with various OCT patterns rather than with visual acuity [25-27]. Recent works assume a more accurate FAF analysis of pathological changes on RPE level when obtained with green-light vs blue-light FAF [28]. If confirmed, FAF might help in screening for diabetic macular edema.

The aim of this study is to investigate the role of green-light FAF in DME by analyzing for possible FAF patterns and correlations between green-light FAF intensity and central retinal thickness (CRT), photoreceptor Inner/Outer segment (IS/OS) layer integrity and RPE-IS/OS layer thickness in diabetic study eyes with and without DME.

**SUBJECTS AND METHODS**

A consecutive series of 92 study eyes with diabetic retinopathy were included in this study. The mean age was 63 years (range: 37-81 years), 18 women and 33 men were included, 48 right and 44 left eyes. Forty-three patients had DM Type 2, 2 patients had DM Type 1, both known for at least three years. Out of those, 51 study eyes had DME known for at least 3 months compared to 41 study eyes without DME. DME was defined as central macular subfield thickness greater than 372µm obtained with HRA2 (Heidelberg Retina Angiograph-Optical Coherence Tomography, Heidelberg engineering, Germany) [29] approximating 250µm obtained with Stratus OCT [30,31]. Exclusion criteria were previous laser treatment in the analyzed field, degenerative disorders of the posterior pole and significant media opacities.

After informed consent, non-mydratic Optomap® green-light FAF images were obtained (Figure 1). Basic operation of the Optomap® Panoramic 200Tx is a scanning laser ophthalmoscope (SLO) with two laser wavelengths scanning at 532nm ("green laser separation") and 633nm ("red laser separation"). The two images can be viewed separately or superimposed by specific software (Vantage V2, Optos PLC, Dunfermline, Fife, Scotland, UK) to yield semi-realistic color imaging. For green-light FAF images an excitatory laser beam is produced at 532nm wavelength, emitting light within the range from 540nm to 800nm detected by the machine. Then pupils were dilated and a full retinal examination was performed by a retinal specialist. An SD-OCT volume scan (using eye tracking feature ART, standard averaging frame number: 9) of the macula covering the edematous areas was performed in mydriasis for each study eye to visualize pathomorphologic changes and measure the central macular thickness in µm and obtain the extent and characteristic pattern of the DME (Figure 1). Wavelengths of HRA



**Figure 1** A: OCT volume scan of one left study eye with overlaid retinal thickness map, red/orange indicate higher values vs green/blue which indicate lower values; B: Green-light FAF image of left study eye, various grayscale intensities indicate various FAF signal intensities (0=black to 255=white). C and D: Quantification of FAF intensity using Matlab based software with marking of the fovea (C) and obtained FAF intensity scale ranging from 0 (black) to 255 (white) shown as function of pixel distance from the marked fovea center in logarithmic scale.

SD-OCT are 870nm. Optical resolution is approximately 3.8µm axial and 6µm lateral in high resolution mode. Acquisition speed for OCT is approximately 40 000 A-scans per second, scan depth is 1.9mm.

All research was conducted in accordance with institutional guidelines and board approval and conformed to the tenets of the World Medical Association Declaration of Helsinki.

**OCT measurements** According to literature integrity of photoreceptor layers is of high importance for prognostic evaluation of DME [32,33]. Therefore, obtained cross-sectional OCT scans from each study eye were made anonymous and evaluated for integrity of photoreceptor Inner/Outer segment layer (0=continuous, 1=partly interrupted, 2=completely interrupted, Figure 2). RPE-IS/OS thickness consisting of RPE and IS/OS band was measured with Image J (NIH; <http://rsb.info.nih.gov/ij/disclaimer.html>).

**OCT based subclassification of DME** Each diabetic study eye with OCT based diagnosis of DME (CRT measured with SD-OCT ≥372µm equals Stratus OCT ≥250µm) was subdivided into various subtypes as suggested in previous published studies [30,31,34]. Focal DME showed locally defined retinal thickening compared to extensive retinal thickening within at least two OCT subfields in diffuse DME. Cystoid DME was classified due to presence of cysts within the outer retinal layers seen on cross-sectional scans through the central subfield. Non-cystoid DME had none or showed minimal detectable cysts in cross-sectional OCT scans (Figure 3, 4).

**FAF quantification** Obtained green-light Optomap FAF

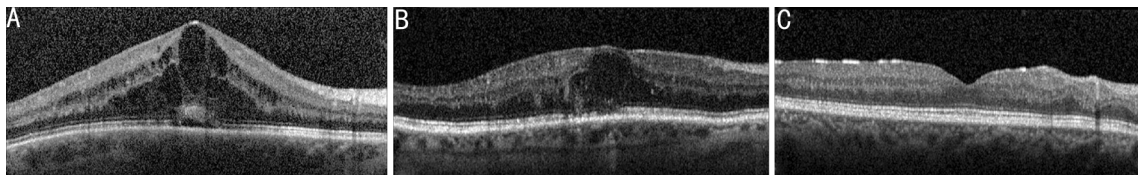


Figure 2 Interrupted (A) and partially interrupted (B) IS/OS layer band in patient with cystoid DME compared to continuous (C) IS/OS layer band in patient without DME in cross-sectional OCT scans.

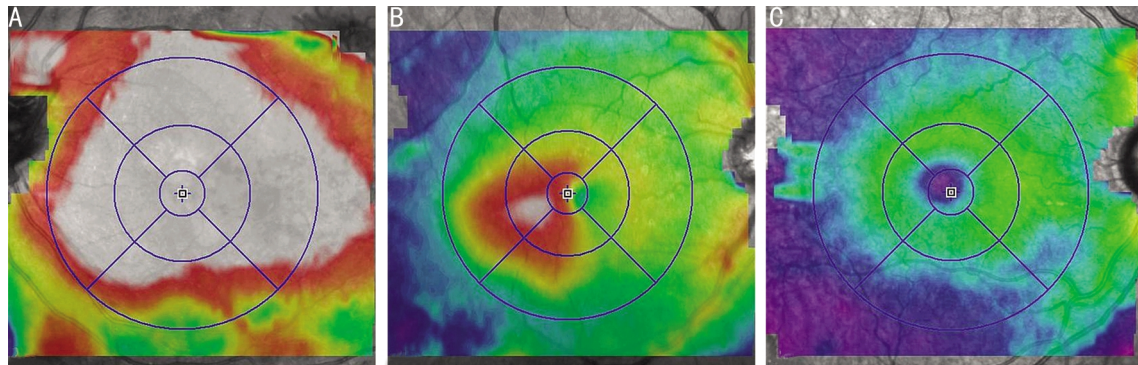


Figure 3 OCT volume scan pattern based classification of DME into diffuse (A) and focal (B) DME compared to non DME group (C).

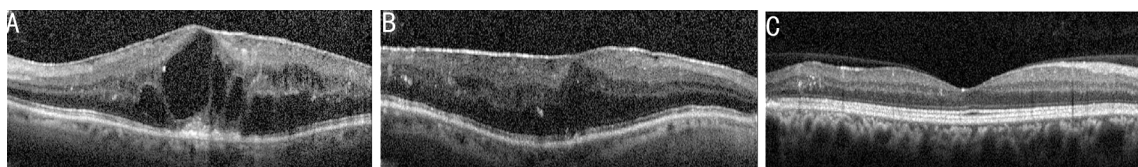


Figure 4 OCT cross-sectional scan based classification of DME into cystoid (A) and non-cystoid (B) DME compared to non DME group (C).

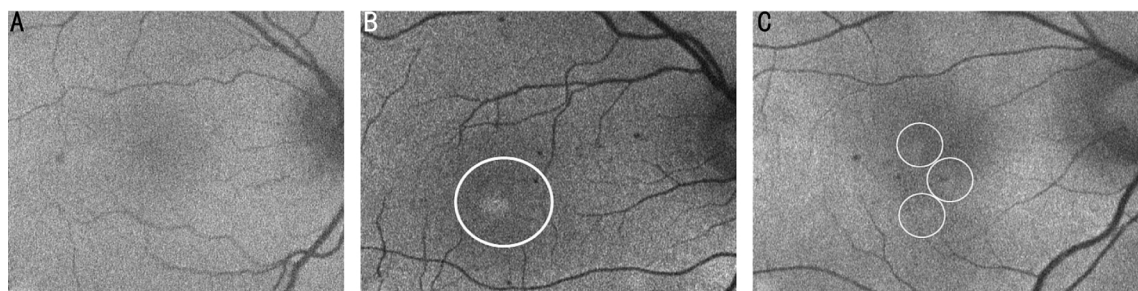


Figure 5 Normal (A), single-spot (B) and multi-spot (C) increased FAF pattern of included patients with DME.

images were analyzed with a Stand-alone-Software based on Matlab (Matlab 7.0 R14, Mathworks Inc., Natick, MA, USA). FAF images were uploaded, the fovea center marked and their brightness values histogram-based normalized with values ranging between 0 (black) and 255 (white). A quantitative analysis was performed calculating the optical density values in logarithmic scale in the central macular area (fovea) of each study eye and correlating the results with CRT measured with HRA (Figure 1B, C, and D).

**Qualitative analysis of FAF** FAF images of all 92 study eyes were classified into a normal/unremarkable FAF pattern vs single-spot increased FAF or multi-spot increased FAF pattern as suggested in previous works published by Vujosevic *et al*<sup>[26]</sup> (Figure 5).

**Statistical Analysis** Data were collected and analyzed using SPSS Version 17.0 (SPSS Inc, Chicago, IL, USA). A *P* value of <0.05 was considered as statistically significant. Univariate

parametric analyses and non-parametric correlation analyses were applied.

## RESULTS

**OCT Measurements** Fifty-one study eyes with OCT based diagnosis of DME were compared to 41 included study eyes with diabetic retinopathy but without DME. Mean CRT of all 92 study eyes was  $(424.5 \pm 121.7) \mu\text{m}$ . Mean CRT of all study eyes with DME was  $(501.9 \pm 112.4) \mu\text{m}$  compared to  $(328.2 \pm 27.0) \mu\text{m}$  in diabetic patients without DME ( $P < 0.001$ ). Subclassification into different OCT patterns resulted in 21 study eyes with focal vs 30 study eyes with diffuse DME with a mean CRT of  $(463.1 \pm 84.8) \mu\text{m}$  and  $(529.0 \pm 122.4) \mu\text{m}$  respectively ( $P = 0.038$ ). Forty-five study eyes with DME had cystoid and 6 had non-cystoid DME with a mean CRT of  $(514.5 \pm 113.2) \mu\text{m}$  and  $(407.3 \pm 39.1) \mu\text{m}$  respectively ( $P = 0.027$ ). Diabetic patients with DME had a significantly more disrupted photoreceptor IS/OS layer than patients without

DME. Twenty-eight of 51 study eyes with DME had a partially or completely disrupted photoreceptor IS/OS layer compared to 5 out of 41 study eyes without DME ( $P < 0.001$ ). Mean central thickness of RPE-IS/OS band consisting of the RPE and IS/OS layer band of all study eyes was  $(66.1 \pm 13.9) \mu\text{m}$  (Figure 6). Mean RPE-IS/OS thickness of patients with DME ( $n=51$ ) was  $(60.7 \pm 14.1) \mu\text{m}$  and significantly lower than in diabetic eyes without DME ( $n=41$ ) with  $(73.5 \pm 9.4) \mu\text{m}$  ( $P < 0.001$ ). CRT correlated significantly with RPE-IS/OS thickness (Figure 7, Spearman's coefficient: 0.532,  $P < 0.001$ ).

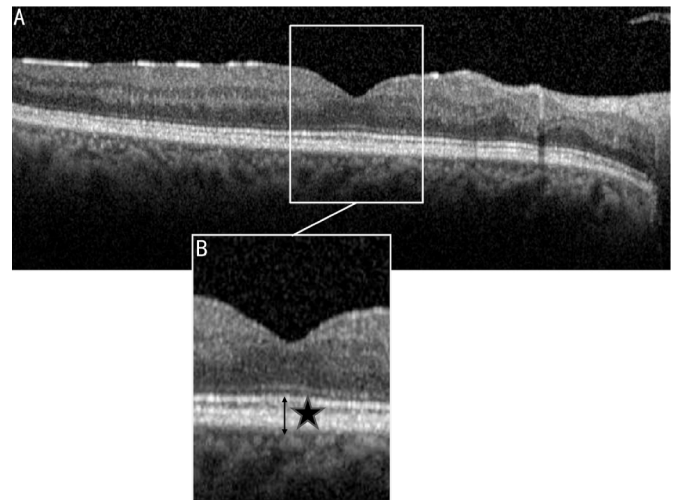
**FAF Analysis** Mean central FAF intensity of eyes with DME was  $(1.289 \pm 0.140) \log$  and not significantly ( $P = 0.33$ ) different from the FAF intensity of  $(1.317 \pm 0.137) \log$  in diabetic patients without DME. FAF intensity did not differ significantly in both DME subgroups focal vs diffuse [ $(1.282 \pm 0.107) \log$  vs  $(1.293 \pm 0.161) \log$ ,  $P = 0.794$ ] and cystoid vs non-cystoid [ $(1.285 \pm 0.220) \log$  vs  $(1.289 \pm 0.129) \log$ ,  $P = 0.97$ ]. On total, 83 out of 92 diabetic study eyes showed unremarkable FAF patterns, 43 out of 51 (84.3%) with DME and 40 out of 41 (97.6%) without DME. Seven out of 51 patients with DME had classifiable FAF patterns, 3 (5.9%) single-spot and 5 (9.8%) multi-spot increased FAF in analogy to previously published works by Vujosevic *et al*<sup>[26]</sup>. One out of 41 study eyes without DME had 1 (2.4%) classifiable single-spot increased FAF.

Of all 21 focal DME patients 1 (4.8%) had single-spot and 2 (9.5%) multi-spot increased FAF compared to 2 (6.7%) single-spot and 3 (10%) multi-spot increased FAF out of 30 patients with diffuse DME. Most classifiable FAF patterns were seen in patients with cystoid DME ( $n=45$ ). Three (6.7%) had single-spot and 5 (11.7%) had multi-spot increased FAF. No classifiable FAF pattern was found in non-cystoid DME ( $n=6$ ).

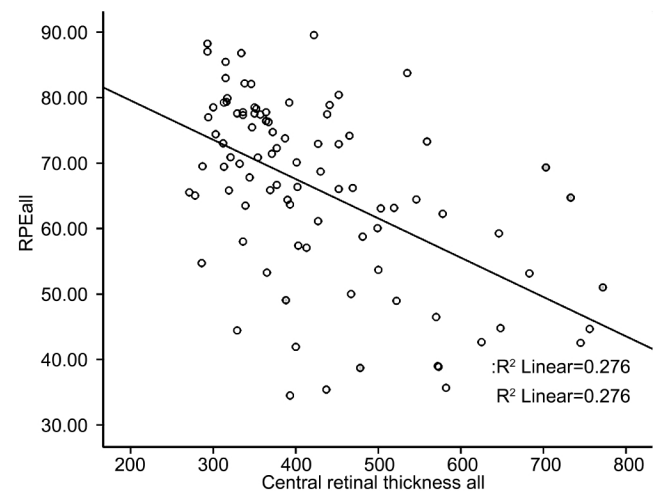
**Correlation Analyses Between FAF Intensity and OCT Parameters** No significant correlation was observed between green-light FAF and CRT (Spearman's coefficient 0.038,  $P = 0.72$ ), IS/OS integrity (Spearman's coefficient 0.201,  $P = 0.054$ ) and RPE-IS/OS thickness (Spearman's coefficient 0.035,  $P = 0.741$ ) in all included study eyes. Analog subgroup correlation analyses in the DME and non-DME group as well as focal, diffuse, cystoid and non-cystoid DME subgroup revealed non-significant ( $P > 0.05$ ) correlations of FAF intensity and CRT, IS/OS integrity and RPE-IS/OS thickness with a Spearman's correlation coefficient in the range between 0.005 and 0.772.

## DISCUSSION

In our study, based on our observations, green-light FAF did not show to be a useful tool in detection or classification of DME. The FAF observed in healthy eyes is a cumulative signal of a variety of fluorophores, each with its assumed own excitation and emission spectra including lipofuscin, which itself is a mixture of different compounds and is



**Figure 6** Cross-sectional OCT scan (A) through macula of study eye without DME and detail (B) of its foveal region with RPE-IS/OS measurement (asterisk).



**Figure 7** Significant correlation with regression curve between central retinal thickness (CRT) and RPE layer thickness in  $\mu\text{m}$  in all 92 study eyes.

considered to be the strongest fluorophore of the ocular fundus<sup>[35-37]</sup>. Additionally to that, FAF properties vary according to age, media opacities and excitation wavelengths<sup>[38]</sup>.

The underlying pathophysiology for the observed increased FAF in DME is not completely understood. Holz *et al*<sup>[39]</sup> have suggested that altered FAF in macular edema might be related to fluorophores, *i.e.* retinoids, in extracellular intra- or subretinal fluid, rather than to altered lipofuscin patterns on RPE level. Another possible explanation is that intra-retinal edema may result in lateral displacement of either macular pigments of the RPE layer or luteal pigment with a reduction of their density and a subsequent higher FAF due to a decreased blockage<sup>[40,41]</sup>.

FAF has been suggested as a convenient non-invasive diagnostic tool for detection of cystoid macular edema<sup>[41]</sup>. Based on those observations of altered FAF in CME, efforts have been made to classify DME into various subtypes according to specific FAF patterns<sup>[26]</sup>.

A limitation of our study is the fact that we are not able to

identify and exclude other fluorophores due to pathologic changes of the RPE that might alter the detected autofluorescence signals and herewith measured central FAF intensities. Slight to moderate changes of lens opacities in phasic patients also might contribute to a modified FAF. The cross-sectional character of this study does not allow any conclusions of a possible development or alteration of central FAF of DME with its various phenotypes, stages and durations.

In our study, central green-light FAF intensity did not significantly correlate with central retinal thickness. Subgroup correlation analyses revealed a lack of significant correlation of FAF intensity and CRT in patients with or without DME as well as in the focal, diffuse, cystoid and non-cystoid DME subgroup. All included patients with DME showed various stages and phenotypes depending on duration and severity the underlying diabetic retinopathy. That fact enables us to classify it into different OCT patterns such as diffuse *vs* focal or cystoid *vs* non-cystoid and results in diverging retinal and possibly also choroidal tissue characteristics with various FAF properties. This might explain our non-significant correlation findings of our cross-sectional study in diabetic patients with or without DME and its various subtypes.

We were not able to relate OCT patterns of OCT based classified DME subtypes to green-light FAF patterns successfully which can be explained with the inconsistent tissue characteristics found in DME. Progressed cystoid DME was the only exceptional FAF pattern that showed a higher percentage of altered and classifiable FAF patterns in the sense of an increased single-spot or multi-spot FAF.

The negative significant correlation between CRT and RPE-IS/OS layer thickness points towards a DME thickness dependent alteration of the RPE and photoreceptor band and may be interpreted as an additional progression parameter for OCT based evaluation of DME over the course compared to our observed non-significant correlation between FAF intensity and RPE-IS/OS layer thickness. Regarding the evaluation of IS/OS integrity, we were not able to rule out scattering artifacts introduced by overlying cystic spaces, which might influence the classification of IS/OS integrity and therefore our correlation analyses, especially in progressed DME.

Another important aspect worthy to be mentioned is the fact that all previously published studies on central FAF in patients with DME used HRA as their standard device thus exciting with 488nm to obtain "blue-light" FAF images. In our study we excited with 533nm using the only recently commercially available device Optomap® Panoramic 200Tx. Green-light autofluorescence signals obtained with Optomap can be attributed to a higher proportion of "lipofuscin-autofluorescence" and are supposed to be more sensitive and

more accurate in detecting pathophysiologic changes due to lipofuscin accumulation in the RPE layer such as in patients with AMD [28]. Excitation with lower wavelengths than 533nm might more likely detect signals from other fluorophores which are supposed to play an important role in various subtypes of DME [28,42-44].

In conclusion our results indicate a poor correlation of central FAF excited with 533nm with CRT, IS/OS integrity and RPE-IS/OS layer thickness in diabetic patients with or without DME and its various subtypes. Thus, green-light FAF excited with 533nm is not suitable for the detection of retinal thickening in DME.

#### REFERENCES

- 1 Chew EY, Klein ML, Ferris FL 3<sup>rd</sup>, Remaley NA, Murphy RP, Chantry K, Hoogwerf BJ, Miller D. Association of elevated serum lipid levels with retinal hard exudate in diabetic retinopathy. Early Treatment Diabetic Retinopathy Study (ETDRS) Report 22. *Arch Ophthalmol* 1996;114 (9): 1079-1084
- 2 Ferris FL 3<sup>rd</sup>, Patz A. Macular edema: a complication of diabetic retinopathy. *Surv Ophthalmol* 1984;28(Suppl):452-461
- 3 Klein R, Klein BE, Moss SE, Cruickshanks KJ. The Wisconsin Epidemiologic Study of Diabetic Retinopathy. XV. The long-term incidence of macular edema. *Ophthalmology* 1995;102(1):7-16
- 4 Moss SE, Klein R, Klein BE. The 14-year incidence of visual loss in a diabetic population. *Ophthalmology* 1998;105(6):998-1003
- 5 Photocoagulation for diabetic macular edema. Early Treatment Diabetic Retinopathy Study report number 1. Early Treatment Diabetic Retinopathy Study research group. *Arch Ophthalmol* 1985;103(12):1796-1806
- 6 Browning DJ, Altaweel MM, Bressler NM, Bressler SB, Scott IU. Diabetic macular edema: what is focal and what is diffuse? *Am J Ophthalmol* 2008; 146(5):649-655 e6
- 7 Caldwell RB, Bartoli M, Behzadian MA, El-Remessy AE, Al-Shabrawey M, Platt DH, Liou GI, Caldwell RW. Vascular endothelial growth factor and diabetic retinopathy: role of oxidative stress. *Curr Drug Targets* 2005;6(4): 511-524
- 8 Ciulla TA, Amador AG, Zinman B. Diabetic retinopathy and diabetic macular edema: pathophysiology, screening, and novel therapies. *Diabetes Care* 2003;26(9):2653-2664
- 9 Kunisaki M, Bursell SE, Clermont AC, Ishii H, Ballas LM, Jirousek MR, Umeda F, Nawata H, King GL. Vitamin E prevents diabetes-induced abnormal retinal blood flow *via* the diacylglycerol-protein kinase C pathway. *Am J Physiol* 1995;269(2 Pt 1):E239-246
- 10 Morigi M, Angioletti S, Imberti B, Donadelli R, Micheletti G, Figliuzzi M, Remuzzi A, Zoja C, Remuzzi G. Leukocyte-endothelial interaction is augmented by high glucose concentrations and hyperglycemia in a NF- $\kappa$ B-dependent fashion. *J Clin Invest* 1998;101(9):1905-1915
- 11 Nishikawa T, Edelstein D, Du XL, Yamagishi S, Matsumura T, Kaneda Y, Yorek MA, Beebe D, Oates PJ, Hammes HP, Giardino I, Brownlee M. Normalizing mitochondrial superoxide production blocks three pathways of hyperglycaemic damage. *Nature* 2000;404(6779):787-790
- 12 Early Treatment Diabetic Retinopathy Study Research Group. Treatment techniques and clinical guidelines for photocoagulation of diabetic macular edema. Early Treatment Diabetic Retinopathy Study Report Number 2. *Ophthalmology* 1987;94(7):761-774
- 13 Amsterdam A, Tajima K, Sasson R. Cell-specific regulation of apoptosis by glucocorticoids: implication to their anti-inflammatory action. *Biochem*

- Pharmacol* 2002;64(5-6):843-850
- 14 Yilmaz T, Weaver CD, Gallagher MJ, Cordero-Coma M, Cervantes-Castaneda RA, Klisovic D, Lavaque AJ, Larson RJ. Intravitreal triamcinolone acetonide injection for treatment of refractory diabetic macular edema: a systematic review. *Ophthalmology* 2009;116(5):902-911; quiz 912-903
- 15 Jonas JB, Harder B, Kamppeiter BA. Inter-eye difference in diabetic macular edema after unilateral intravitreal injection of triamcinolone acetonide. *Am J Ophthalmol* 2004;138(6):970-977
- 16 Gillies M. Diabetic macular edema. *Ophthalmology* 2009;116(3):595
- 17 Chung EJ, Roh MI, Kwon OW, Koh HJ. Effects of macular ischemia on the outcome of intravitreal bevacizumab therapy for diabetic macular edema. *Retina* 2008;28(7):957-963
- 18 Goebel W, Kretzchmar-Gross T. Retinal thickness in diabetic retinopathy: a study using optical coherence tomography (OCT). *Retina* 2002;22(6):759-767
- 19 Kook D, Wolf A, Kreutzer T, Neubauer A, Strauss R, Ulbig M, Kampik A, Haritoglou C. Long-term effect of intravitreal bevacizumab (avastin) in patients with chronic diffuse diabetic macular edema. *Retina* 2008;28(8):1053-1060
- 20 Roesel M, Henschel A, Heinz C, Dietzel M, Spital G, Heiligenhaus A. Fundus autofluorescence and spectral domain optical coherence tomography in uveitic macular edema. *Graefes Arch Clin Exp Ophthalmol* 2009;247(12):1685-1689
- 21 Dandekar SS, Jenkins SA, Peto T, Scholl HP, Sehmi KS, Fitzke FW, Bird AC, Webster AR. Autofluorescence imaging of choroidal neovascularization due to age-related macular degeneration. *Arch Ophthalmol* 2005;123(11):1507-1513
- 22 Barr DB, Beirouty ZA. Autofluorescence in a patient with adult vitelliform degeneration. *Eur J Ophthalmol* 1995;5(3):155-159
- 23 Boon CJ, Jeroen Klevering B, Keunen JE, Hoyng CB, Theelen T. Fundus autofluorescence imaging of retinal dystrophies. *Vision Res* 2008;48(26):2569-2577
- 24 Datta A, Maiti A, Uparkar M. Autofluorescence imaging. *Ophthalmology* 2008;115(10):1853-1854; author reply 1854
- 25 Pece A, Isola V, Holz F, Milani P, Brancato R. Autofluorescence imaging of cystoid macular edema in diabetic retinopathy. *Ophthalmologica* 2010;224(4):230-235
- 26 Vujosevic S, Casciano M, Pilotto E, Boccassini B, Varano M, Midena E. Diabetic macular edema: fundus autofluorescence and functional correlations. *Invest Ophthalmol Vis Sci* 2011;52(1):442-448
- 27 Yeung L, Lima VC, Garcia P, Landa G, Rosen RB. Correlation between spectral domain optical coherence tomography findings and fluorescein angiography patterns in diabetic macular edema. *Ophthalmology* 2009;116(6):1158-1167
- 28 Wolf-Schnurrbusch UE, Wittwer VV, Ghanem R, Niederhauser M, Enzmann V, Framme C, Wolf S. Blue-light versus green-light autofluorescence: lesion size of areas of geographic atrophy. *Invest Ophthalmol Vis Sci* 2011;52(13):9497-9502
- 29 Giani A, Cigada M, Choudhry N, Deiro AP, Oldani M, Pellegrini M, Invernizzi A, Duca P, Miller JW, Staurenghi G. Reproducibility of etinal thickness measurements on normal and pathologic eyes by different optical coherence tomography instruments. *Am J Ophthalmol* 2010;150(6):815-824
- 30 Mitchell P, Bandello F, Schmidt-Erfurth U, Lang GE, Massin P, Schlingemann RO, Sutter F, Simader C, Burian G, Gerstner O, Weichselberger A, RESTORE study group. The RESTORE study: ranibizumab monotherapy or combined with laser versus laser monotherapy for diabetic macular edema. *Ophthalmology* 2011;118(4):615-625
- 31 Diabetic Retinopathy Clinical Research Network (DRCR.net), Beck RW, Edwards AR, Aiello LP, Bressler NM, Ferris F, Glassman AR, Hartnett E, Ip MS, Kim JE, Kollman C. Three-year follow-up of a randomized trial comparing focal/grid photocoagulation and intravitreal triamcinolone for diabetic macular edema. *Arch Ophthalmol* 2009;127(3):245-251
- 32 Sakamoto A, Nishijima K, Kita M, Oh H, Tsujikawa A, Yoshimura N. Association between foveal photoreceptor status and visual acuity after resolution of diabetic macular edema by pars plana vitrectomy. *Graefes Arch Clin Exp Ophthalmol* 2009;247(10):1325-1330
- 33 Shin HJ, Lee SH, Chung H, Kim HC. Association between photoreceptor integrity and visual outcome in diabetic macular edema. *Graefes Arch Clin Exp Ophthalmol* 2012;250(1):61-70
- 34 Aiello LP, Beck RW, Bressler NM, Browning DJ, Chalam KV, Davis M, Ferris FL 3<sup>rd</sup>, Glassman AR, Maturi RK, Stockdale CR, Topping TM. Rationale for the diabetic retinopathy clinical research network treatment protocol for center-involved diabetic macular edema. *Ophthalmology* 2011;118:e5-e14
- 35 Delori FC, Dorey CK, Staurenghi G, Arend O, Goger DG, Weiter JJ. *In vivo* fluorescence of the ocular fundus exhibits retinal pigment epithelium lipofuscin characteristics. *Invest Ophthalmol Vis Sci* 1995;36(3):718-729
- 36 Eldred GE, Katz ML. Fluorophores of the human retinal pigment epithelium: separation and spectral characterization. *Exp Eye Res* 1988;47(1):71-86
- 37 Stitt AW. Advanced glycation: an important pathological event in diabetic and age related ocular disease. *Br J Ophthalmol* 2001;85(6):746-753
- 38 Arend O, Weiter JJ, Goger DG, Delori FC. *In vivo* fundus fluorescence measurements in patients with age related macular degeneration. *Ophthalmology* 1995;92(5):647-653
- 39 Holz FG. Autofluorescence imaging of the macula. *Ophthalmology* 2001;98(1):10-18
- 40 Su DH, Friedman DS, See JL, Chew PT, Chan YH, Nolan WP, Smith SD, Huang D, Zheng C, Li Y, Foster PJ, Aung T. Degree of angle closure and extent of peripheral anterior synechiae: an anterior segment OCT study. *Br J Ophthalmol* 2008;92(1):103-107
- 41 Kaplan J, Gerber S, Larget-Piet D, Rozet JM, Dollfus H, Dufier JL, Odent S, Postel-Vinay A, Janin N, Briard ML, Frézal J, Munnich A. A gene for Stargardt's disease (fundus flavimaculatus) maps to the short arm of chromosome 1. *Nat Genet* 1993;5(3):308-311
- 42 Hammer M, Konigsdorffer E, Liebermann C, Framme C, Schuch G, Schweitzer D, Strobel J. Ocular fundus auto-fluorescence observations at different wavelengths in patients with age-related macular degeneration and diabetic retinopathy. *Graefes Arch Clin Exp Ophthalmol* 2008;246(1):105-114
- 43 Srinivasan VJ, Adler DC, Chen Y, Gorczynska I, Huber R, Duker JS, Schuman JS, Fujimoto JG. Ultrahigh-speed optical coherence tomography for three-dimensional and en face imaging of the retina and optic nerve head. *Invest Ophthalmol Vis Sci* 2008;49(11):5103-5110
- 44 Kagemann L, Ishikawa H, Wollstein G, Brennen PM, Townsend KA, Gabriele ML, Schuman JS. Ultrahigh-resolution spectral domain optical coherence tomography imaging of the lamina cribrosa. *Ophthalmic Surg Lasers Imaging* 2008;39(4 Suppl):S126-131