

Treatment of intractable orbital implant exposure with a large conjunctival defect by secondary insertion of the implant after preceding dermis fat graft

Hyun Kyung Kim, Tae Yoon La

Department of Ophthalmology, St. Vincent's Hospital, College of Medicine, The Catholic University of Korea, Gyunggi-do, 442-723, Korea

Correspondence to: Tae-Yoon La. Department of Ophthalmology, St. Vincent's Hospital, College of Medicine, the Catholic University of Korea, 93 Ji-dong, Paldal-gu, Suwon-si, Gyunggi-do, 442-723, Korea. laty@catholic.ac.kr
Received: 2012-07-03 Accepted: 2013-03-10

Abstract

• **AIM:** To report a procedure and results of a two-stage operation to manage intractable extensive orbital implant exposure with a large conjunctival defect which was difficult to treat with dermis fat grafts due to repeated graft necrosis.

• **METHODS:** A retrospective chart review of four patients who had extensive orbital implant exposures with large conjunctival defects and had past histories of repeated autologous or preserved dermis graft failures was done. As a first-stage operation, the problematic pre-existing orbital implants were removed and autologous dermis fat grafts alone were performed on the defect area. Four months later, new orbital implants were secondarily inserted after confirmation of graft survival. The size of the conjunctival defects and state of the extraocular muscles were checked preoperatively. Success of the operations and complications were investigated.

• **RESULTS:** The mean size of the conjunctival defects was 17.3mm×16.0mm, and the mean time from the initial diagnosis of orbital implant exposure to implant removal and autologous dermis fat graft was 20.8 months. After implant removal and autologous dermis fat graft, no graft necrosis was observed in any patients. Also, implant exposure or fornix shortening was not observed in any patients after new orbital implant insertion.

• **CONCLUSION:** The secondary insertion of a new orbital implant after pre-existing implant removal and preceding dermis fat graft is thought to be another selective management of intractable orbital implant exposure in which dermis fat grafts persistently fail.

• **KEYWORDS:** conjunctival defect; dermis fat graft; orbital implant exposure

DOI:10.3980/j.issn.2222-3959.2013.02.17

Kim HK, La TY. Treatment of intractable orbital implant exposure with a large conjunctival defect by secondary insertion of the implant after preceding dermis fat graft. *Int J Ophthalmol* 2013;6(2):193-197

INTRODUCTION

When the orbital implant exposure is small, it is usually observed by using only topical antibiotics, or direct closure of the exposed area can be attempted. However, when direct closure is not possible or a risk of severe infection is present, autologous or preserved dermis grafts are usually done^[1]. For survival of transplanted autologous or preserved dermis grafts, sufficient blood supply and nutrients from underlying healthy tissues are essential. Provided that sufficient vascularization exists inside the implant and no infection is present, the graft usually survives well and covers the exposed area. Otherwise, the graft will fail, and necrosis will occur. In this case, some surgeons try to do burring to the orbital implant until the vascularized area is exposed or try another attempt with new grafts^[1,2], and some successful cases have been reported. Nevertheless, we sometimes experience difficulties in treating the orbital implant exposure due to graft failure despite several attempts. Eventually, an infected or exposed orbital implant must be removed, and a new orbital implant is inserted. When the conjunctival defect is not large and enough conjunctival redundancy exists, it is feasible to suture the conjunctiva directly after the insertion of a new orbital implant. When the defect area is too extensive to perform direct closure, however, a graft is essential to reconstruct the defect area prior to insertion of a new orbital implant. But, if an autologous or preserved dermis graft is simultaneously transplanted with a new orbital implant insertion, it is more likely to fail because no healthy, vascularized tissues are present underneath^[3].

We carried out a two-stage operation to manage intractable extensive orbital implant exposure with a large conjunctival defect which was difficult to treat with repeated dermis fat grafts due to the repeated necrosis of the graft. We report the procedures and the results.

SUBJECTS AND METHODS

Subjects The subjects were four patients who had extensive orbital implant exposures with large conjunctival defects and had past histories of repeated autologous or preserved dermis graft failures (Figures 1 and 2). As a first-stage operation, the problematic pre-existing orbital implants were removed, and autologous dermis fat grafts alone were done on the defect area. Then, a new orbital implant was secondarily inserted at four months after confirmation of graft survival. A retrospective study was performed through the analysis of medical records. Preoperatively, the size of the conjunctival defects was measured, and the state of extraocular muscles and orbital spaces were checked by orbit computed tomography. The patients were followed up for at least 6 months after the secondary orbital implant insertion and observed for success of the operation and potential complications.

Surgical technique All operations were performed by one surgeon. As for the first-stage operation, the space between the conjunctiva and wrapped implant was dissected inwardly from the melted boundary with Wescott scissors to find the extraocular muscles. After finding the extraocular muscles, they were separated from the insertion site and tied with 6-0 vicryl sutures. Then, the implant was removed from the orbital space. For the patients who had evisceration previously, the implant was removed with optic nerve cutting. After removing the orbital implant, the orbital space was filled in with 1:100 000 epinephrine gauze to stop bleeding by compression, and the ends of the separated rectus muscles were put together and sewn to the edges of the dermis fat graft to allow them to be found again later, and to give movement and vascularity to the edges of the dermis fat graft. After making sure that no signs of bleeding remained, the defect area was measured, and the dermis fat graft was obtained from the buttock. At this time, considering postoperative contraction, the graft was harvested 30% larger than the measurement of the defect area. The maximum thick layer of fat underneath the dermis was obtained to fill in the empty orbital space as much as possible so that the grafted dermis is retracted and contracted less towards the intraorbital space during the recovery. The epidermal layer of obtained dermis fat graft was sharply dissected off and the graft was transplanted to the defect area with 6-0 vicryl suture. The patients were instructed to instill ofloxacin and tobramycin eye drops four times a day; steroid eye drops were not used because they might cause a delay in wound healing. The follow ups took place weekly for the first month and monthly for the following 4 months. During the periods, we observed the graft survival and potential complications (Figure 3).

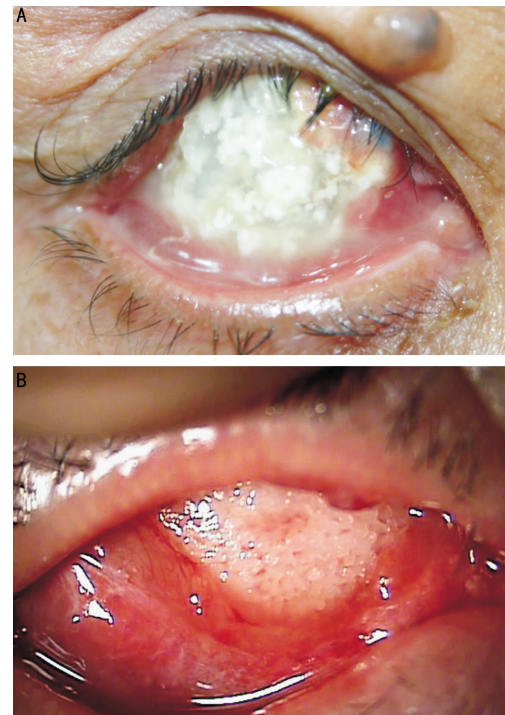


Figure 1 Photographs show exposed orbital implants with wide conjunctival defects before failed dermis fat grafts A: Hydroxyapatite implant; B: Medpor® implant.

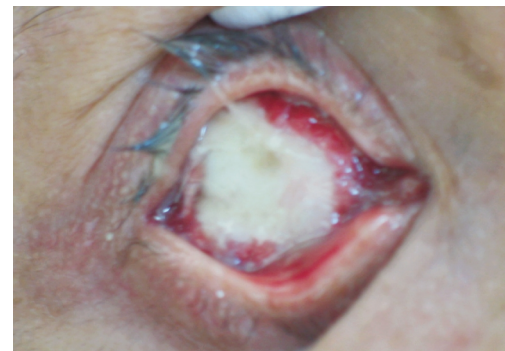

Figure 2 Photographs show melted and failed dermis fat graft on the exposed Medpor® orbital implant.

Four months after confirmation of successful grafting and conjunctivalization, a new orbital implant was secondarily inserted. As for the second-stage operation, the grafted dermis was incised horizontally from the medial canthus to the lateral canthus at the center of the conjunctiva (Figure 4A). The intraorbital fat and tissues were dissected and placed out of the way. Then, the possible intraorbital space that could be secured was confirmed (Figure 4B). If the rectus muscles that had been ligated together previously were visible, they were dissected and separated. The secured empty intraorbital space was filled in with 1:100 000 epinephrine gauze to stop bleeding, and once no signs of bleeding were observed, either a general or smooth surface tunnel type (SST type) of Medpor® orbital implant was inserted by plunger or disposable plastic insertion device (Figure 4C). The implant was inserted as deep as possible so that it did not cause tension at the grafted dermis incision site. Each separated

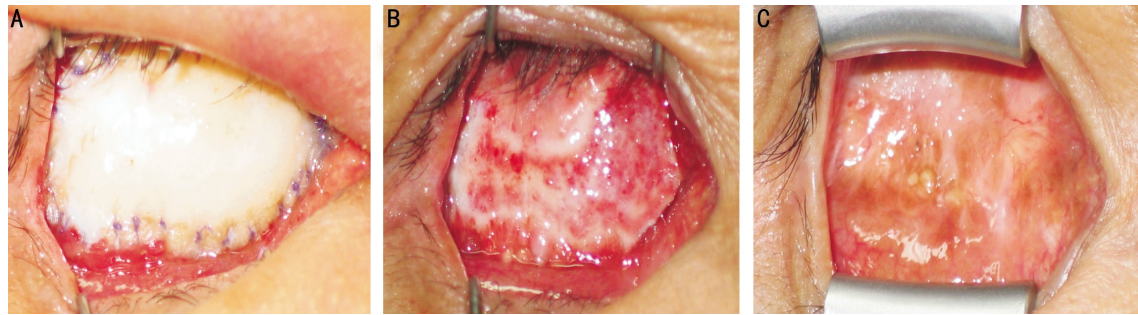

Figure 3 Photographs show a well-grafted and surviving dermis fat graft performed after exposed orbital implant removal and before new orbital implant insertion A: Immediately after graft; B: 2 weeks after graft; C: 2 months after graft.

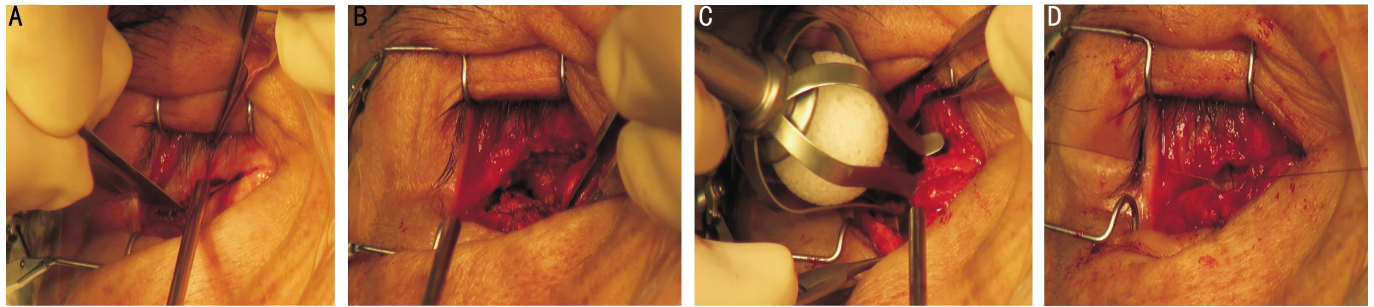


Figure 4 Procedures of new orbital implant insertion after preceding dermis fat graft success A: Horizontal incision line from the medial canthus to the lateral canthus was drawn on the well-grafted and conjunctivalized dermis, and an incision was performed along the line on the dermis; B: The intraorbital space was secured by meticulous dissection of orbital fat and surrounding tissue; C: A new Medpor® orbital implant was inserted into the intraorbital space; D: After insertion of the new orbital implant, the incised dermis was sutured with 6-0 Vicryl.

rectus muscle was connected to the implant again once the implant was inserted. Finally, the incised dermis was sutured with 6-0 vicryl (Figure 4D). The patients were instructed to instill ofloxacin and tobramycin eye drops four times a day as previously. An ocular prosthesis was fitted at 2 months after the operation if no specific complications occurred. The patients were followed up for at least 6 months after the new secondary orbital implant insertion and observed for the success of the operation and potential complications.

RESULTS

Three of the four patients were male. The average age of the patients was 47.5 years old, ranging from 38 years to 57 years old. As a previous first operation, three patients underwent evisceration, and the remaining patient underwent enucleation with preserved sclera wrapping orbital implant. Three of the removed orbital implants were Medpor®, and the other was hydroxyapatite. Two out of four patients had preserved dermis grafts as a first operation for orbital implant exposure, but the grafts failed. Autologous dermis fat grafts were performed twice afterwards, but both of the grafts failed again for a total of three failed grafts. The remaining two patients had autologous dermis fat grafts twice for extensive orbital implant exposure and infections, but both grafts failed (Table 1). All patients were observed for longer than 15 months postoperatively, ranging from 15 months to 28 months, and the mean observation period was 20.3 months. The size of the conjunctival defect in orbital implant

exposure ranged from a minimum of 15.0mm×16.0mm to a maximum of 19.0mm×17.0mm; the mean size was 17.3mm×16.0mm. The mean time from the initial diagnosis of orbital implant exposure to implant removal and autologous dermis fat graft was 20.8 months, ranging from 16 to 26 months.

During the first-stage operation of removing the pre-existing orbital implant, some of the rectus muscles could not be found in all patients because the conjunctival and scleral defects extended to the muscle insertion site, and the previous operations also caused severe adhesion. In two patients, the medial rectus muscle and the superior rectus muscle were not found, respectively, and both muscles were not found in the other two patients. During the operation, 20mm of the measurement sphere was tentatively inserted into all patients after removing the pre-existing orbital implant, and the conjunctiva or tenon was pulled together for covering the sphere. Then it was checked if it was possible to perform direct closure and if fornix shortening occurred. However, the result was that too much tension was present in the tenon and conjunctiva for direct closure, and fornix shortening occurred in all patients. So, the dermis fat graft alone was performed without simultaneous insertion of a new orbital implant. The grafted dermis survived well in all patients, but clear signs of enophthalmos were present, such as deep superior sulcus deformity, after 2 months postoperatively, which stemmed from the absence of an orbital implant. The conjunctivalization took about 4-6 weeks, and no signs of inflammation, such as

Treatment of intractable orbital implant exposure

Table 1 Patients characteristics and clinical results of secondary insertion of orbital implant (Medpor®) after preceding dermis fat graft.

Number	Sex	Age	Preoperative Dx	Initial implant type	Past operative Hx	Implant exposure size	Time from first visit to implant removal	Intraoperative state of rectus m.	Result of PDFG	Time from PDFG to implant reinsertion
1	M	38	Implant exposure	Medpor	Enu+PDG+ADFG(X2)	17mm×16mm	19 months	Med. rectus loss	Well survived	4 months
2	M	46	Implant infection	Medpor	Evi+ADFG(X2)	15mm×16mm	22 months	Sup. rectus loss	Well survived	4 months
3	F	49	Implant infection	HA	Evi+ADFG(X2)	19mm×17mm	26 months	Med and sup. rectus loss	Well survived	4.5 months
4	M	57	Implant exposure	Medpor	Evi+PDG+ADFG(X2)	18mm×15mm	16 months	Med. rectus loss	Well survived	4 months

Number	State of orbital tissue at implant reinsertion	Size and type of new implant	Result of implant reinsertion	Postoperative prosthesis wearing	Complications	Period of postoperative F/U
1	Moderate adhesion and fibrosis	18mm, general type	Successful	8 weeks	none	18 months
2	Mild adhesion and fibrosis	20mm, SST type	Successful	10 weeks	none	20 months
3	Mild adhesion and fibrosis	20mm, general type	Successful	8 weeks	none	15 months
4	Mild adhesion and fibrosis	20mm, SST type	Successful	9 weeks	none	28 months

PDFG: Preceding dermis fat graft; Enu: Enucleation; PDG: Preserved dermis; ADFG(X2): Autologous dermis fat graft (twice); Evi: Evisceration, SST: Smooth surface tunnel.

discharge, were observed in any of the patients for 4 months postoperatively.

At the time of secondary orbital implant insertion, the sizes of used orbital implants were 18mm and 20mm for 1 and 3 patients, respectively. Since the rectus muscles in two of the patients were not found, the general type of Medpor® implant was inserted without connection to the rectus muscle instead of the SST type Medpor®. When grafted dermis was incised to insert a new orbital implant, severe fibrosis occurred on the orbital fat tissue and around tenon's capsule in a patient who previously underwent enucleation. Therefore, it was difficult to insert an optimal size of orbital implant at once. To solve this problem, the part of the fibrous tissue on fat and tenon's capsule was removed. In the three other patients who underwent evisceration previously, the fibrosis was not severe, and relatively enough space was available for implant insertion. Subsequently, a new orbital implant was easily inserted only after a few radial incisions in tenon's capsule without removal of fat or tissue. During the postoperative follow-up period of 15 months, complications such as orbital implant exposure, inflammation, or prosthesis escape due to inadequate fornix were not observed in any of the patients (Figure 5).

DISCUSSION

Orbital implant exposures have been reported in varying frequencies between 1.6%-22% depending on the surgeons^[4,5]. Kim *et al*^[1] reported that an orbital implant exposure larger than 4mm did not improve with conservative management and needed more aggressive treatment. When the orbital implant exposure is small, tenon or conjunctiva can be pulled and sutured directly, but if direct closure is difficult, it could be covered with a preserved sclera, autologous or preserved dermis, hard palate mucosa, temporal fascia, muller muscle flap or tarsal flap^[6-9]. Regardless of grafted tissue type, sufficient blood supply and nutrients from the healthy host bed are essential for a successful graft; otherwise, the graft will fail.

Preserved or autologous dermis grafts are being currently used mostly as a treatment for orbital implant exposure. But if an exposure or infection in the implant occurs before

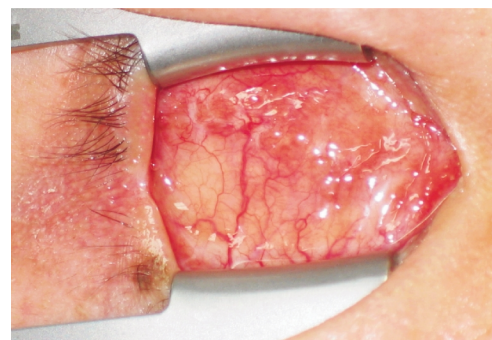


Figure 5 Photographs show well healed and conjunctivalized dermis at 4 months after operation.

sufficient vascularization to the inside of the implant occurs, the graft is likely to fail^[10]. Despite a graft failure, most surgeons tend to try another graft with another tissue or a different type of tissue after burring the implant until the vascularized area is exposed.

However, some cases are difficult to treat despite several attempts due to graft failure. In these cases, repeating the same operation that has a high probability of failure is not the ultimate solution. For this reason, the exposed or infected orbital implant has to be removed eventually, and new orbital implant insertion is needed^[11,12]. However, after removing the problematic pre-existing implant, if a preserved or autologous dermis graft is transplanted onto the defect area with simultaneous insertion of a new orbital implant, the graft is likely to fail because no vascularized tissue is underneath^[1,2]. On the other hand, after removing the pre-existing implant, if the graft is transplanted in advance without simultaneous insertion of a new orbital implant, like our method, sufficient vascularized orbital fat and tissues will be available at the graft site, and these will be a newly established and reliable host bed for a successful graft implantation.

It is possible to attempt direct closure of the defect area instead of a dermis fat graft after removing the exposed orbital implant or inserting a new orbital implant, but it is only feasible if the defect area is not extensive. If too much tension is in the suture site of the defect area, the site can be disrupted, even if the suture site healed well. Additionally, fornix shortening, eyelid ectropion, or deep superior sulcus

deformity can occur due to forniceal conjunctiva traction^[13,14]. If fornix shortening happens, it might be necessary to widen the fornix through another operation because an inadequate fornix makes it difficult to wear an ocular prosthesis. Actually, Salour *et al*^[15] attempted direct closure at the time of a new orbital implant insertion after removing the infected orbital implant and reported the results of the secondary dermis graft to reconstruct the resultant fornix shortening. However, it is impossible to do direct closure by pulling conjunctiva after inserting a new orbital implant if the orbital implant exposure and the conjunctival defect are extensive, like in the patients in our study. Thus, it is necessary to transplant the graft to the defect area first. Elabjer *et al*^[14] reported the results of dermis fat graft alone without inserting a new orbital implant after removing the exposed or infected implant. Although the problem of orbital implant exposure or infection can be solved by dermis fat graft, other problems can remain. Severe enophthalmos can occur later due to the fat layer contraction of graft and the absence of an implant that fills in the empty orbital space. And authors thought that there were limitations in cosmetic improvement to solve this problem only by prosthesis fitting. Also, without orbital implant, the patients have to wear thick and heavy prosthesis, and it can cause complications such as lower lid sagging or socket contracture syndrome later. Thus, authors inserted secondary orbital implant after dermis fat graft.

Even though this operation method was inconvenienced by a two-stage approach, we were able to maintain the conjunctival fornix first of all by transplanting the dermis fat graft to the defect area, instead of performing direct conjunctival closure, which can cause fornix shortening. Complications such as enophthalmos, which also might be expected in a dermis fat graft without implant insertion, were prevented by inserting a new orbital implant several months later. Also, there are some cases that the defect area is not extensive, so performing direct closure with simultaneous insertion of a new orbital implant is possible. But, if the defect area is directly closed without being restored by graft, inserting an enough sized orbital implant can be difficult due to the risk of wound dehiscence by tension. However, our operation method allows for a safe orbital implant insertion of the correct size without high tension concerns, as the

defect area was first sufficiently reconstructed with a dermis fat graft.

In conclusion, we believe that the secondary insertion of a new orbital implant after pre-existing implant removal and preceding dermis fat graft is an another selective management of intractable orbital implant exposure, in which dermis fat grafts persistently fail.

REFERENCES

- 1 Kim YD, Goldberg RA, Shorr N, Steinsapir KD. Management of exposed hydroxyapatite orbital implants. *Ophthalmology*1994;101(10):1709-1715
- 2 Oestreicher JH. Treatment of exposed coral implant after failed scleral patch graft. *Ophthalm Plast Reconstr Surg*1994;10(2):110-113
- 3 Guberina C, Hornblass A, Smith B. Pitfalls of autogenous lipodermal implantation to the orbit. *Ophthalm Plast Reconstr Surg*1987;3(2):65-70
- 4 Custer PL, Trinkaus KM. Porous implant exposure: incidence, management, and morbidity. *Ophthalm Plast Reconstr Surg*2007;23(1):1-7
- 5 Yoon JS, Lew H, Kim SJ, Lee SY. Exposure rate of hydroxyapatite orbital implants a 15-year experience of 802 cases. *Ophthalmology*2008;115(3):566-572
- 6 Pelletier CR, Jordan DR, Gilberg SM. Use of temporalis fascia for exposed hydroxyapatite orbital implants. *Ophthalm Plast Reconstr Surg*1993;14(3):198-203
- 7 Rosen CE. The Müller muscle flap for repair of an exposed hydroxyapatite orbital implant. *Ophthalm Plast Reconstr Surg*1998;14(3):204-207
- 8 Soparkar CN, Partrinely JR. Tarsal patch-flap for orbital implant exposure. *Ophthalm Plast Reconstr Surg*1998;14(6):391-397
- 9 El-Shahed FS, Sherif MM, Ali AT. Management of tissue breakdown and exposure associated with orbital hydroxyapatite implants. *Ophthalm Plast Reconstr Surg*1995;11(2):91-94
- 10 Nunery WR, Heinz GW, Bonnin JM. Exposure rate of hydroxyapatite spheres in the anophthalmic socket: histopathologic correlation and comparison with silicone sphere implants. *Ophthalm Plast Reconstr Surg*1993;9(2):96-104
- 11 Sagoo MS, Rose GE. Mechanisms and treatment of extruding intraconal implants: socket aging and tissue restitution (the "Cactus syndrome"). *Arch Ophthalmol*2007;125(12):1616-1620
- 12 Goldberg RA, Holds JB, Ebrahimpour J. Exposed hydroxyapatite orbital implant. Report of six cases. *Ophthalmology*1992;99(5):831-836
- 13 Kaltreider SA, Newman SA. Prevention and management of complications associated with hydroxyapatite implants. *Ophthalm Plast Reconstr Surg*1996;12(1):18-31
- 14 Kuzmanovic Elabjer B, Busic M, Bosnar D. Our experience with dermofat graft in reconstruction of anophthalmic socket. *Orbit*2010;29(4):209-212
- 15 Salour H, Owji N, Farahi A. Two-stage procedure for management of large exposure defects of hydroxyapatite orbital implant. *Eur J Ophthalmol*2003;13(9-10):789-793